

World Journal of *Clinical Oncology*

World J Clin Oncol 2019 November 24; 10(11): 358-381



**ORIGINAL ARTICLE****Observational Study**

- 358** Germline mutations in Thai patients with nonmucinous epithelial ovarian cancer
Manchana T, Phowthongkum P, Teerapakpinyo C

CASE REPORT

- 369** Breathing adapted radiation therapy for leukemia relapse in the breast: A case report
Sager O, Dincoglan F, Demiral S, Uysal B, Gamsiz H, Ozcan F, Colak O, Elcim Y, Dirican B, Beyzadeoglu M
- 375** Radiation-induced malignant rhabdoid tumour of the hypothalamus in an adult: A case report
Ng PM, Low PH, Liew DNS, Wong ASH

ABOUT COVER

Editorial Board Member of *World Journal of Clinical Oncology*, Wei-Ren Luo, MD, PhD, Associate Professor, Department of Pathology, The Third People's Hospital of Shenzhen, Southern University of Science and Technology, Shenzhen 518112, Guangdong Province, China

AIMS AND SCOPE

The primary aim of *World Journal of Clinical Oncology* (WJCO, *World J Clin Oncol*) is to provide scholars and readers from various fields of oncology with a platform to publish high-quality basic and clinical research articles and communicate their research findings online.

WJCO mainly publishes articles reporting research results and findings obtained in the field of oncology and covering a wide range of topics including art of oncology, biology of neoplasia, breast cancer, cancer prevention and control, cancer-related complications, diagnosis in oncology, gastrointestinal cancer, genetic testing for cancer, gynecologic cancer, head and neck cancer, hematologic malignancy, lung cancer, melanoma, molecular oncology, neurooncology, palliative and supportive care, pediatric oncology, surgical oncology, translational oncology, and urologic oncology.

INDEXING/ABSTRACTING

The WJCO is now abstracted and indexed in PubMed, PubMed Central, Emerging Sources Citation Index (Web of Science), China National Knowledge Infrastructure (CNKI), China Science and Technology Journal Database (CSTJ), and Superstar Journals Database.

RESPONSIBLE EDITORS FOR THIS ISSUE

Responsible Electronic Editor: *Mei-Yi Liu*

Proofing Production Department Director: *Xiang Li*

NAME OF JOURNAL

World Journal of Clinical Oncology

ISSN

ISSN 2218-4333 (online)

LAUNCH DATE

November 10, 2010

FREQUENCY

Monthly

EDITORS-IN-CHIEF

Hiten Patel

EDITORIAL BOARD MEMBERS

<https://www.wjnet.com/2218-4333/editorialboard.htm>

EDITORIAL OFFICE

Ruo-Yu Ma, Director

PUBLICATION DATE

November 24, 2019

COPYRIGHT

© 2019 Baishideng Publishing Group Inc

INSTRUCTIONS TO AUTHORS

<https://www.wjnet.com/bpg/gerinfo/204>

GUIDELINES FOR ETHICS DOCUMENTS

<https://www.wjnet.com/bpg/GerInfo/287>

GUIDELINES FOR NON-NATIVE SPEAKERS OF ENGLISH

<https://www.wjnet.com/bpg/gerinfo/240>

PUBLICATION MISCONDUCT

<https://www.wjnet.com/bpg/gerinfo/208>

ARTICLE PROCESSING CHARGE

<https://www.wjnet.com/bpg/gerinfo/242>

STEPS FOR SUBMITTING MANUSCRIPTS

<https://www.wjnet.com/bpg/GerInfo/239>

ONLINE SUBMISSION

<https://www.f6publishing.com>

Radiation-induced malignant rhabdoid tumour of the hypothalamus in an adult: A case report

Pei-Meng Ng, Peh-Hueh Low, Donald Ngian-San Liew, Albert Sii-Hieng Wong

ORCID number: Pei-Meng Ng (0000-0001-6017-4027); Peh-Hueh Low (0000-0003-0679-3833); Donald Ngian-San Liew (0000-0001-5473-9407); Albert Sii-Hieng Wong (0000-0001-5170-3345).

Author contributions: Ng PM and Low PH reviewed the literature and contributed to manuscript drafting; Wong ASH and Liew DNS were responsible for the revision of the manuscript for important intellectual content; all authors issued final approval for the version to be submitted.

Informed consent statement: Informed written consent was obtained from the patient's parent for publication of this report and any accompanying images.

Conflict-of-interest statement: The authors declare that they have no conflicts of interest.

CARE Checklist (2016) statement: The authors have read the CARE Checklist (2016), and the manuscript was prepared and revised according to the CARE Checklist (2016).

Open-Access: This article is an open-access article which was selected by an in-house editor and fully peer-reviewed by external reviewers. It is distributed in accordance with the Creative Commons Attribution Non Commercial (CC BY-NC 4.0) license, which permits others to distribute, remix, adapt, build upon this work non-commercially, and license their derivative works on different terms, provided the original work is properly cited and

Pei-Meng Ng, Peh-Hueh Low, Donald Ngian-San Liew, Albert Sii-Hieng Wong, Department of Neurosurgery, Sarawak General Hospital, Kuching 93586, Sarawak, Malaysia

Corresponding author: Peh-Hueh Low, MBBS, Neurosurgeon, Department of Neurosurgery, Sarawak General Hospital, Kuching 93586, Sarawak, Malaysia. peh.hueh@gmail.com
Telephone: +60-19-2188599

Abstract

BACKGROUND

Rhabdoid tumours of the central nervous system are highly malignant and extremely rare in adults. To the best of our knowledge, only 87 cases of malignant rhabdoid tumour have been reported to date, inclusive of 4 cases with presumed radiation-induced aetiology. We report a case of malignant rhabdoid tumour in an adult with presumed radiation-induced aetiology to enrich the armamentarium of this disease entity, which may have some implications for early diagnosis and treatment of this rare disease in the future.

CASE SUMMARY

A 27-year-old male, who was exposed to cranial irradiation at the age of 4 years as part of the treatment for acute lymphoblastic leukaemia, presented with symptoms of raised intracranial pressure for one week. Brain magnetic resonance imaging revealed a heterogeneously enhancing lesion at the hypothalamus. Stereotactic biopsy was performed. Histopathological examination of the lesion showed malignant rhabdoid tumour. The disease progressed rapidly, with manifestation of leptomeningeal spread. He was started on craniospinal irradiation but treatment was suspended after 5.4 Gy, as he developed myelosuppression. His clinical condition deteriorated rapidly, and he succumbed to his illness within 2 mo.

CONCLUSION

This fifth case of radiation-induced central nervous system rhabdoid tumour re-enforces the aggressive nature of this disease with poor prognosis.

Key words: Malignant rhabdoid tumour; Atypical teratoid rhabdoid tumour; Radiation induced malignancy; Case report

©The Author(s) 2019. Published by Baishideng Publishing Group Inc. All rights reserved.

Core tip: Malignant rhabdoid tumours of the central nervous system are highly

the use is non-commercial. See:
<http://creativecommons.org/licenses/by-nc/4.0/>

Manuscript source: Unsolicited manuscript

Received: May 23, 2019

Peer-review started: May 23, 2019

First decision: August 2, 2019

Revised: October 10, 2019

Accepted: October 15, 2019

Article in press: October 15, 2019

Published online: November 24, 2019

P-Reviewer: Gheita TA, Yang LY

S-Editor: Ma RY

L-Editor: A

E-Editor: Liu MY



malignant, with a grave prognosis. Occurrence in adults is extremely rare. Due to the paucity of available data, treatment recommendations for adults are derived mainly from paediatric data. Despite being a dismal disease, prognosis in children has been more encouraging recently due to the continuous refinement of treatment strategies. We report a case of malignant rhabdoid tumour in an adult with presumed radiation-induced aetiology, with the hope to enrich the armamentarium of this disease entity and provide some implications for early diagnosis and treatment of this disease in the future.

Citation: Ng PM, Low PH, Liew DNS, Wong ASH. Radiation-induced malignant rhabdoid tumour of the hypothalamus in an adult: A case report. *World J Clin Oncol* 2019; 10(11): 375-381

URL: <https://www.wjgnet.com/2218-4333/full/v10/i11/375.htm>

DOI: <https://dx.doi.org/10.5306/wjco.v10.i11.375>

INTRODUCTION

The advancement in therapeutic measures in the oncology field has led to a significant improvement in the overall survival of cancer patients. Hence, we are facing more complications from those therapeutic measures, including an increase in the number of radiation-induced malignancies. Malignant rhabdoid tumour (MRT) of the central nervous system (CNS) in adult is very rare, and the literature available consists mainly of case reports or series. Despite the rarity of this disease entity, 4 cases^[1-4] of presumed radiation-induced MRT in the brain have been reported to date. We present herein a case of hypothalamic tumour in an adult patient diagnosed with MRT following prophylactic irradiation for acute lymphoblastic leukaemia during childhood.

CASE PRESENTATION

Chief complaints

A 27-year-old male presented with headache, vomiting and blurring of vision for 1 wk duration.

History of present illness

The patient's headache was of gradual onset, throbbing in nature, worse in the morning with associated projectile vomiting and blurring of vision. The headache was relieved temporarily by analgesia but progressively worsened over the course of a week.

History of past illness

The patient had history of acute lymphoblastic leukaemia at the age of four and was treated according to the Berlin-Frankfurt-Munster Protocol.

Physical examination

Neurological examination on the day of admission revealed bilateral reduction in visual acuity. Visual acuity for the right eye was light perception and for the left eye was 6/6. No other neurological deficit was noted. Systemic examinations were unremarkable.

Laboratory examinations

Blood investigation findings were normal.

Imaging examinations

Magnetic resonance imaging of the brain revealed a heterogeneously enhanced hypothalamic tumour (Figure 1). The lesion measured 2 cm × 1.5 cm, located mainly at the hypothalamus with extension into the optic chiasm. No pituitary stalk and pituitary gland involvement was detected.

Further diagnostic work-up

Stereotactic biopsy of the tumour was performed. Histopathological examination of the specimen showed focus of tumour infiltration that displayed rhabdoid

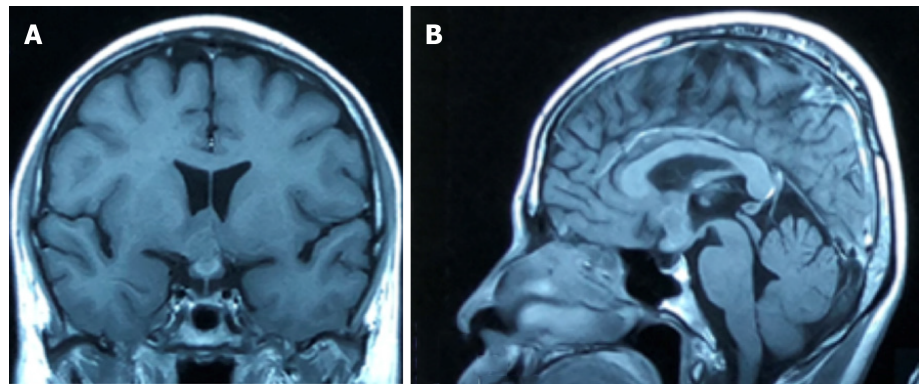


Figure 1 Magnetic resonance imaging of the brain, T1-weighted gadolinium-enhanced. Coronal (A) and sagittal (B) view showing a heterogeneously enhanced lesion at the hypothalamic region with extension into the optic chiasm.

morphology (Figure 2). Nuclei were eccentrically placed, hyperchromatic and pleomorphic with coarse chromatin. There was an ample amount of eosinophilic cytoplasm. Mitotic figures were seen. The cells stained positive for vimentin, cytokeratin (CK) AE1/AE3, glial fibrillary acidic protein (GFAP), cluster of differentiation (CD) 68 and CD138. Synaptophysin, human melanoma black 45, CK7, CK20, desmin, smooth muscle actin, CD79, CD30, terminal deoxynucleotidyl transferase, placental alkaline phosphatase, and leucocyte common antigen were negative upon staining. Ki67 was more than 20%.

FINAL DIAGNOSIS

The final diagnosis of the presented case was MRT of the CNS.

TREATMENT

The patient's clinical condition deteriorated rapidly, with manifestation of leptomeningeal dissemination. He lost his vision within 5 d and developed multiple cranial neuropathies over the subsequent week. This started off with right eye ptosis, followed by bilateral lateral gaze palsy, loss of the left frontal furrow upon upward gaze with loss of the left nasolabial fold and drooping of the left angle of the mouth. His voice became softer, and he coughed upon swallowing both liquid and food. His tongue showed fasciculation with deviation to the right. This was followed by progressive bilateral lower limb weakness over the next week. The spinal magnetic resonance imaging showed leptomeningeal spread. Lumbar puncture was performed, and cerebrospinal fluid analysis revealed dispersed cells with rhabdoid features. The treatment plan was to administer 36 Gy of craniospinal radiation (20 fractions). However, treatment was halted after 5.4 Gy as he developed myelosuppression.

OUTCOME AND FOLLOW-UP

The patient's general condition deteriorated rapidly after the radiotherapy was halted, and he succumbed to his illness within 2 mo from the onset of the illness.

DISCUSSION

MRTs of the brain were first described in 1987^[5]. They have been characterised by diffuse growth of rhabdoid cells with typical paranuclear, glassy eosinophilic inclusions. Their nuclei are eccentrically placed, vesicular and with occasional prominent nucleoli, and mitosis is commonly found^[6,7].

According to the World Health Organization classification of tumours of the CNS^[8], MRT of the CNS with polyphenotypic (epithelial, mesenchymal, neuroendocrine) features by histology or immunohistochemical staining can be categorised into atypical teratoid rhabdoid tumour (ATRT) or CNS embryonal tumour with rhabdoid features based on their integrase interactor 1 (INI 1) status. In ATRT, there must be

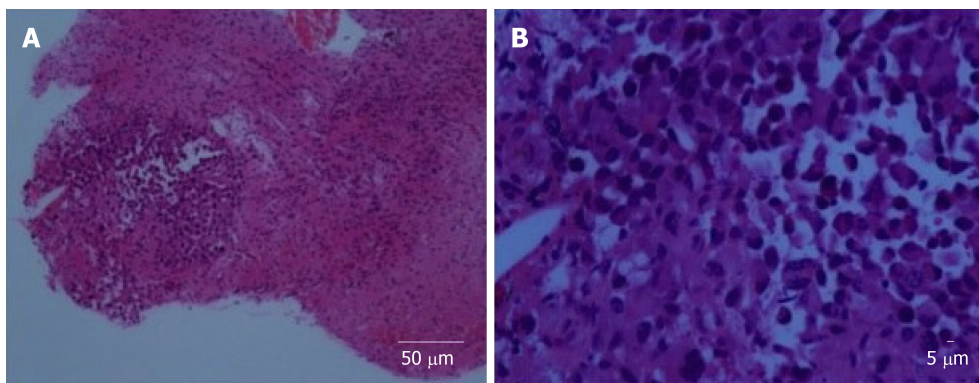


Figure 2 Histopathological examination. A: Glial tissue infiltrated by a focus of singly dispersed malignant cells (40 ×); B: At high magnification, the lesion is composed of rhabdoid cells with hyper chromatic nuclei, coarse chromatin and abundant eosinophilic cytoplasm (400 ×).

SMARCB1 (INI1) or SMARCA4 (BRG1) inactivation. Those with expression of SMARCB1 (INI1) and SMARCA4 (BRG1) or in which SMARCB1 and SMARCA4 status cannot be confirmed fall into the group of CNS embryonal tumour with rhabdoid features, despite having the same pathological features as ATRTs.

Eighty-seven cases of MRT of the brain in adult has been reported,, with 39 of them located at midline and 47 cases off midline. The location was not mentioned in one case. For those located at the midline, 31 cases of sellar and suprasellar tumour were reported. Another 8 cases were located at the pineal region. Our case is the first in the literature to report an MRT located at the hypothalamus. This supports the hypothesis of Dardis *et al*^[9], which states that the residual undifferentiated ectoderm in the circumventricular organ can be an origin for this tumour.

The appearances of rhabdoid tumour in the lung and ileum 20 years after radiation therapy (RT) for Wilms' tumour have been reported by Litman *et al*^[10], raising the possibilities of radiation-induced rhabdoid tumour. Four adult cases of presumed RT-induced MRT of the CNS have been reported in the literature^[1-4]. The clinicopathological and imaging features of these cases and our case are summarised in Table 1, Table 2 and Table 3. Genetic analysis was performed in 1 of the 5 cases, which demonstrated loss of both SMARCB1 alleles at chromosome 22. Four cases showed inactivation of INI 1. The average age at the time of previous irradiation was 5.4 years, with a mean total radiation dose of 28 Gy and an average latency period of 23 years (Table 4). Overall prognosis is poorer compared to non-RT-induced MRT in adults, with a mean survival of 12 mo compared to 38 mo in the non-RT-induced group^[1-4].

Imaging features for MRT of the CNS are non-specific. A combination of intratumoral haemorrhage, peripherally localised cysts, high cellularity seen as low T2 and apparent diffusion coefficient signal, as well as band-like or wavy enhancement can be seen. Around 15% of patients display meningeal dissemination at diagnosis^[11]. For the 5 cases of presumed RT-induced MRT, all of them were located at the supratentorial compartment. Two cases were located at midline, and three cases were located off midline. Peritumoral oedema was more pronounced in the 3 cases located off midline, and peripheral tumour cysts were found in those 3 cases only. All cases demonstrated heterogenous contrast enhancement, with 3 of them showing the characteristic band-like enhancement. Leptomeningeal spread was present in 1 out of the 5 cases during the first presentation.

In the present case, the diagnosis of ATRT was suspected initially, but due to the rarity of this disease in adult this differential was deprioritized. A wide range of immunohistochemical stains were employed to exclude other possibilities first. Because of this, we found that our case was positive for CD138, which has never been reported for other cases in the past. CD138 is involved in molecular pathways that are dysregulated during carcinogenesis, and it can be an attractive target for immunotherapy in cancer treatment^[12]. Other immunohistochemical stains that were positive in our case included vimentin, CKAE1/AE3, CD68, and GFAP. Staining for synaptophysin, human melanoma black 45, CK7, CK20, desmin, leucocyte common antigen, CD79, CD30, terminal deoxynucleotidyl transferase, and placental alkaline phosphatase were negative. Ki67 was increased (more than 20%).

GFAP staining in MRT of the CNS has been found to be strongly correlated with leptomeningeal spread and predicts a worse prognosis^[9]. Our case further re-enforces this evidence, as the patient's specimen was positive for GFAP staining and he manifested leptomeningeal spread early in the course of his disease with rapid

Table 1 Summary of patients, symptoms, treatments, and outcomes of radiation-induced malignant rhabdoid tumour

Case	Age (yr)	Gender	Symptom	Location	Treatment	Survival	Outcome
Padua <i>et al</i> ^[1]	17	Male	Headache	Right frontal	Surgery (partial resection), radiotherapy	15 mo	Alive
Kuge <i>et al</i> ^[2]	20	Female	Severe headache, increased ICP symptoms	Pineal	Surgery (biopsy), gamma knife radiosurgery	27 mo	Died
Gorayski <i>et al</i> ^[3]	58	Female	Headache, recurrent syncopal events, behavioural changes	Right parietotemporal	Surgery (gross total resection), radiotherapy	20 mo	Died
Oliveira <i>et al</i> ^[4]	22	Female	headache, nausea, vomiting	Frontal	Surgery (partial resection)	4 d	Died
Our case	27	Male	Headache, vomiting, visual disturbance	Hypothalamus	Surgery (biopsy), radiotherapy	2	Died

ICP: Intracranial pressure.

deterioration.

Multimodal therapy has been the proposed treatment strategy for MRT, by combining RT and chemotherapy following surgical resection^[13,14]. Improved disease survival has been shown in patients given a total RT dose of more than 50 Gy^[15]. However, treatment strategies in the group of patients with a history of irradiation might need to be modified as re-irradiation can expose them to the risk of central nervous toxicity. The impact of toxicity depends on the dose, volume and time between exposures. Hence, re-irradiation in a patient with a history of RT requires tedious planning and good patient selection. Consideration should be given to other modes of treatment, such as stereotactic radiosurgery, which provide more precise and targeted tissue damage^[16], or to local conformal proton therapy, which has shown encouraging results^[17]. For candidates not suitable for re-irradiation, high-dose chemotherapy with autologous stem cell rescue may also be an option^[18].

CONCLUSION

In summary, MRT of the CNS in adults remains a rare disease with an aggressive course and poor prognosis. Treatment recommendations for adults have been derived from paediatric data, due to the paucity of data available from adults. Despite being a dismal disease, prognosis in children has been more encouraging recently compared to 10 years ago, due to the continuous development and refinement of treatment strategies. We report a case of MRT in an adult with presumed radiation-induced aetiology, with the hope of enriching the armamentarium of this disease entity, which may have some implications for early diagnosis and treatment of this rare disease in the future.

Table 2 Summary of immunohistological findings of radiation-induced malignant rhabdoid tumour

Case	Padua <i>et al</i> ^[1]	Kuge <i>et al</i> ^[2]	Gorayski <i>et al</i> ^[3]	Oliveira <i>et al</i> ^[4]	Our case
Vimentin	+	+	+	+	+
EMA	+	+	+	+	-
SMA	NA	+	+	NA	-
INI 1	-	-	-	-	NA
GFAP	-	-	-	+	+
NFP	NA	-	+	+	NA
S100	NA	+	-	NA	NA
CK:	-	NA	-	NA	
CKAE1/AE3					+
CK7					
CK20					
Chromosome 22q deletion	NA	NA	NA	+	NA
Desmin	-	NA	-	NA	-
LCA	-	NA	-	NA	-
Ki67	NA	7.8%	NA	NA	>20%
Others (stain positive)	Neuron-specific enolase	NA	CD99	NA	CD138, CD68,
Others (stain negative)	CD99, Tdt, myeloperoxidase	NA	HMB45, CD34, CD31, CD10, PLAP, MelanA, MYOD1, myogenin, chromogranin, p63	NA	Synaptophysin, HMB45, CD117, CD79, CD30, Tdt, PLAP

CD: Cluster of differentiation; CK: Cytokeratin; EMA: Epithelial membrane antigen; GFAP: Glial fibrillary acidic protein; HMB: Human melanoma black; INI 1: Integrase interactor 1; LCA: Leukocyte common antigen; MYOD: Myoblast determination protein; NA: Not applicable; NFP: Neurofilament protein; PLAP: Placental alkaline phosphatase; SMA: Smooth muscle actin; Tdt: Terminal deoxynucleotidyl transferase.

Table 3 Imaging features of radiation-induced malignant rhabdoid tumour

MRI	Padua <i>et al</i> ^[1]	Kuge <i>et al</i> ^[2]	Gorayski <i>et al</i> ^[3]	Oliveira <i>et al</i> ^[4]	Our case
Oedema	Yes	No	Yes	Yes	No
Peripheral cyst	Yes	No	Yes	Yes	No
Calcification	Yes	No	Yes	Yes	No
Contrast enhancement	Heterogenous	Heterogenous	Heterogenous, band-like	Heterogenous, band-like	Heterogenous, band-like
T2 signal	NA	NA	Hyperintense	NA	Hyperintense
FLAIR	NA	NA	Hyperintense	NA	Hyperintense
Leptomeningeal spread at first presentation	No	No	No	No	Yes
CT	Mix density: iso to hyperdense with foci of calcification and necrosis	Isodense	Mix density: isodense with foci of calcification and cyst	NA	Isodense to hyperdense

CT: Computed tomography; MRI: Magnetic resonance imaging; NA: Not available.

Table 4 Previous treatment details for radiation-induced malignant rhabdoid tumour

Case	Padua <i>et al</i> ^[1]	Kuge <i>et al</i> ^[2]	Gorayski <i>et al</i> ^[3]	Oliveira <i>et al</i> ^[4]	Our case
Latency period in yr	11	18	55	10	23
Age of previous RT in year	6	2	3	12	4
Dose of previous RT	NA	24 Gy	35 Gy	34 Gy	20 Gy
Reason for previous RT	Acute lymphoblastic leukaemia treatment: prophylactic cranial irradiation	Acute lymphoblastic leukaemia treatment: prophylactic cranial irradiation	Right ear sarcoma	Subtotal surgical removal of craniopharyngioma	Acute lymphoblastic leukaemia treatment: prophylactic cranial irradiation

RT: Radiation therapy.

REFERENCES

- 1 **De Padua M**, Reddy V, Reddy M. Cerebral atypical teratoid rhabdoid tumour arising in a child treated for acute lymphoblastic leukaemia. *BMJ Case Rep* 2009; **2009** [PMID: [21686729](#) DOI: [10.1136/bcr.08.2008.0601](#)]
- 2 **Kuge A**, Sato S, Sakurada K, Takemura S, Kayama T. Atypical teratoid rhabdoid tumor located in the pineal region following prophylactic irradiation for acute lymphoblastic leukemia. *Brain Tumor Pathol* 2012; **29**: 177-181 [PMID: [22218708](#) DOI: [10.1007/s10014-011-0075-8](#)]
- 3 **Gorayski P**, Boros S, Ong B, Olson S, Foote M. Radiation-induced primary cerebral atypical teratoid/rhabdoid tumour in an adult. *J Clin Neurosci* 2013; **20**: 1466-1468 [PMID: [24018258](#) DOI: [10.1016/j.jocn.2013.03.041](#)]
- 4 **Oliveira E**, Lavrador JP, Roque L, Pimentel J, Miguéns J. Atypical teratoid/rhabdoid tumour following craniopharyngioma radiotherapy during childhood. *Childs Nerv Syst* 2016; **32**: 1573-1575 [PMID: [27461272](#) DOI: [10.1007/s00381-016-3187-y](#)]
- 5 **Biggs PJ**, Garen PD, Powers JM, Garvin AJ. Malignant rhabdoid tumor of the central nervous system. *Hum Pathol* 1987; **18**: 332-337 [PMID: [3030922](#)]
- 6 **Rorke LB**, Packer RJ, Biegel JA. Central nervous system atypical teratoid/rhabdoid tumors of infancy and childhood: definition of an entity. *J Neurosurg* 1996; **85**: 56-65 [PMID: [8683283](#) DOI: [10.3171/jns.1996.85.1.0056](#)]
- 7 **Fisher BJ**, Siddiqui J, Macdonald D, Cairney AE, Ramsey D, Munoz D, Del Maestro R. Malignant rhabdoid tumor of brain: an aggressive clinical entity. *Can J Neurol Sci* 1996; **23**: 257-263 [PMID: [8951203](#)]
- 8 **Louis DN**, Ohgaki H, Wiestler OD, Cavenee WK, Ellison DW, Figarella-Branger D, Perry A, Reifenberger G, Deimling AV. WHO Classification of Tumours of the Central Nervous System. 4th ed. Lyon: IARC Press 2016; 209-212
- 9 **Dardis C**, Yeo J, Milton K, Ashby LS, Smith KA, Mehta S, Youssef E, Eschbacher J, Tucker K, Dawes L, Lambie N, Algar E, Hovey E. Atypical Teratoid Rhabdoid Tumor: Two Case Reports and an Analysis of Adult Cases with Implications for Pathophysiology and Treatment. *Front Neurol* 2017; **8**: 247 [PMID: [28676785](#) DOI: [10.3389/fneur.2017.00247](#)]
- 10 **Litman DA**, Bhuta S, Barsky SH. Synchronous occurrence of malignant rhabdoid tumor two decades after Wilms' tumor irradiation. *Am J Surg Pathol* 1993; **17**: 729-737 [PMID: [8391222](#)]
- 11 **Warmuth-Metz M**, Bison B, Dannemann-Stern E, Kortmann R, Rutkowski S, Pietsch T. CT and MR imaging in atypical teratoid/rhabdoid tumors of the central nervous system. *Neuroradiology* 2008; **50**: 447-452 [PMID: [18345534](#) DOI: [10.1007/s00234-008-0369-7](#)]
- 12 **Palaologou M**, Delladetsima I, Tiniakos D. CD138 (syndecan-1) expression in health and disease. *Histol Histopathol* 2014; **29**: 177-189 [PMID: [24150912](#) DOI: [10.14670/HH-29.177](#)]
- 13 **Buscariollo DL**, Park HS, Roberts KB, Yu JB. Survival outcomes in atypical teratoid rhabdoid tumor for patients undergoing radiotherapy in a Surveillance, Epidemiology, and End Results analysis. *Cancer* 2012; **118**: 4212-4219 [PMID: [22213196](#) DOI: [10.1002/cncr.27373](#)]
- 14 **Ginn KF**, Gajjar A. Atypical teratoid rhabdoid tumor: current therapy and future directions. *Front Oncol* 2012; **2**: 114 [PMID: [22988546](#) DOI: [10.3389/fonc.2012.00114](#)]
- 15 **Chen YW**, Wong TT, Ho DM, Huang PI, Chang KP, Shiao CY, Yen SH. Impact of radiotherapy for pediatric CNS atypical teratoid/rhabdoid tumor (single institute experience). *Int J Radiat Oncol Biol Phys* 2006; **64**: 1038-1043 [PMID: [16406394](#) DOI: [10.1016/j.ijrobp.2005.10.001](#)]
- 16 **Nieder C**, Andrasschke NH, Grosu AL. Re-irradiation for Recurrent Primary Brain Tumors. *Anticancer Res* 2016; **36**: 4985-4995 [PMID: [27798857](#) DOI: [10.21873/anticancer.11067](#)]
- 17 **De Amorim Bernstein K**, Sethi R, Trofimov A, Zeng C, Fullerton B, Yeap BY, Ebb D, Tarbell NJ, Yock TI, MacDonald SM. Early clinical outcomes using proton radiation for children with central nervous system atypical teratoid rhabdoid tumors. *Int J Radiat Oncol Biol Phys* 2013; **86**: 114-120 [PMID: [23498870](#) DOI: [10.1016/j.ijrobp.2012.12.004](#)]
- 18 **Biswas A**, Kashyap L, Kakkar A, Sarkar C, Julka PK. Atypical teratoid/rhabdoid tumors: challenges and search for solutions. *Cancer Manag Res* 2016; **8**: 115-125 [PMID: [27695363](#) DOI: [10.2147/CMAR.S83472](#)]



Published By Baishideng Publishing Group Inc
7041 Koll Center Parkway, Suite 160, Pleasanton, CA 94566, USA
Telephone: +1-925-2238242
E-mail: bpgoffice@wjgnet.com
Help Desk: <https://www.f6publishing.com/helpdesk>
<https://www.wjgnet.com>

