

# World Journal of *Clinical Oncology*

*World J Clin Oncol* 2020 December 24; 11(12): 968-1083



## Contents

Monthly Volume 11 Number 12 December 24, 2020

## EDITORIAL

- 968** COVID-19 and information and communication technology in radiation oncology: A new paradigm  
*Fernández C, Ruiz V, Couñago F*
- 976** Practice change in the management of metastatic urothelial carcinoma after ASCO 2020  
*Gajate P, Torres-Jiménez J, Bueno-Bravo C, Couñago F*
- 983** Stereotactic body radiation therapy: A good dance partner of oligometastatic non-small cell lung cancer to the sound of SINDAS study  
*Mielgo-Rubio X, Garde-Noguera J, Juan O, Couñago F*
- 990** New standard in locally advanced rectal cancer  
*Solé S, Baeza R, Gabler C, Couñago F*

## MINIREVIEWS

- 996** Predictive indicators of successful tyrosine kinase inhibitor discontinuation in patients with chronic myeloid leukemia  
*Stuckey R, López-Rodríguez JF, Sánchez-Sosa S, Segura-Díaz A, Sánchez-Farías N, Bilbao-Sieyro C, Gómez-Casares MT*
- 1008** Fluoropyrimidine-induced cardiotoxicity  
*Deac AL, Burz CC, Bocsan IC, Buzoianu AD*

## ORIGINAL ARTICLE

## Retrospective Study

- 1018** Forkhead box P3 and indoleamine 2,3-dioxygenase co-expression in Pakistani triple negative breast cancer patients  
*Asghar K, Loya A, Rana IA, Bakar MA, Farooq A, Tahseen M, Ishaq M, Masood I, Rashid MU*
- 1029** Overall and cause-specific survival for mucoepidermoid carcinoma of the major salivary glands: Analysis of 2210 patients  
*Taylor ZC, Kaya EA, Bunn JD, Guss ZD, Mitchell BJ, Fairbanks RK, Lamoreaux WT, Wagner AE, Peressini BJ, Lee CM*

## Prospective Study

- 1045** Assessment of burden and coping strategies among caregivers of cancer patients in sub-Saharan Africa  
*Akpan-Idiok PA, Ehiemere IO, Asuquo EF, Chabo JAU, Osuchukwu EC*

## CASE REPORT

- 1064** Latent brain infection with *Moraxella osloensis* as a possible cause of cerebral gliomatosis type 2: A case report  
*Strojnik T, Kavalari R, Gornik-Kramberger K, Rupnik M, Robnik SL, Popovic M, Velnar T*

- 1070** Preoperative rectal tumor embolization as an adjunctive tool for bloodless abdominoperineal excision: A case report  
*Feitosa MR, de Freitas LF, Filho AB, Nakiri GS, Abud DG, Landell LM, Brunaldi MO, da Rocha JJR, Feres O, Parra RS*
- 1076** Endometrial clear cell carcinoma invading the right oviduct with a cooccurring ipsilateral oviduct adenomatoid tumor: A case report  
*Hu ZX, Tan MH, Li QZ, Xu JL, Chen W, Xie ZH, Zhou YJ, Liang Q, An JH, Shen H*

**ABOUT COVER**

Editorial board member of *World Journal of Clinical Oncology*, Dr. Ramon Andrade de Mello is Professor of Medical Oncology, Federal University of São Paulo (UNIFESP) in São Paulo, Brazil, and University of Algarve in Faro, Portugal. He also serves as Head of the Medical Oncology discipline at UNIFESP. Professor de Mello performs both basic and clinical research on biomarkers, gastrointestinal cancer, and lung cancer; further, he maintains an active office working in medical oncology. He is editor of three books and author of several scientific articles, chapters and comments on basic and clinical research. He has presented more than 100 papers at congresses and conferences in several countries. Furthermore, he serves as editorial board member of several reputed scientific journals. (L-Editor: Filipodia)

**AIMS AND SCOPE**

The primary aim of *World Journal of Clinical Oncology* (WJCO, *World J Clin Oncol*) is to provide scholars and readers from various fields of oncology with a platform to publish high-quality basic and clinical research articles and communicate their research findings online.

WJCO mainly publishes articles reporting research results and findings obtained in the field of oncology and covering a wide range of topics including art of oncology, biology of neoplasia, breast cancer, cancer prevention and control, cancer-related complications, diagnosis in oncology, gastrointestinal cancer, genetic testing for cancer, gynecologic cancer, head and neck cancer, hematologic malignancy, lung cancer, melanoma, molecular oncology, neurooncology, palliative and supportive care, pediatric oncology, surgical oncology, translational oncology, and urologic oncology.

**INDEXING/ABSTRACTING**

The WJCO is now abstracted and indexed in PubMed, PubMed Central, Emerging Sources Citation Index (Web of Science), China National Knowledge Infrastructure (CNKI), China Science and Technology Journal Database (CSTJ), and Superstar Journals Database.

**RESPONSIBLE EDITORS FOR THIS ISSUE**

Production Editor: Li-Li Wang; Production Department Director: Yun-Xiao Jian Wu; Editorial Office Director: Ze-Mao Gong.

**NAME OF JOURNAL**

*World Journal of Clinical Oncology*

**ISSN**

ISSN 2218-4333 (online)

**LAUNCH DATE**

November 10, 2010

**FREQUENCY**

Monthly

**EDITORS-IN-CHIEF**

Hiten RH Patel

**EDITORIAL BOARD MEMBERS**

<https://www.wjgnet.com/2218-4333/editorialboard.htm>

**PUBLICATION DATE**

December 24, 2020

**COPYRIGHT**

© 2020 Baishideng Publishing Group Inc

**INSTRUCTIONS TO AUTHORS**

<https://www.wjgnet.com/bpg/gerinfo/204>

**GUIDELINES FOR ETHICS DOCUMENTS**

<https://www.wjgnet.com/bpg/GerInfo/287>

**GUIDELINES FOR NON-NATIVE SPEAKERS OF ENGLISH**

<https://www.wjgnet.com/bpg/gerinfo/240>

**PUBLICATION ETHICS**

<https://www.wjgnet.com/bpg/GerInfo/288>

**PUBLICATION MISCONDUCT**

<https://www.wjgnet.com/bpg/gerinfo/208>

**ARTICLE PROCESSING CHARGE**

<https://www.wjgnet.com/bpg/gerinfo/242>

**STEPS FOR SUBMITTING MANUSCRIPTS**

<https://www.wjgnet.com/bpg/GerInfo/239>

**ONLINE SUBMISSION**

<https://www.f6publishing.com>

## Retrospective Study

## Forkhead box P3 and indoleamine 2,3-dioxygenase co-expression in Pakistani triple negative breast cancer patients

Kashif Asghar, Asif Loya, Iftikhar Ali Rana, Muhammad Abu Bakar, Asim Farooq, Muhammad Tahseen, Muhammad Ishaq, Iqra Masood, Muhammad Usman Rashid

**ORCID number:** Kashif Asghar 0000-0002-6855-5008; Asif Loya 0000-0003-2716-5027; Iftikhar Ali Rana 000-0001-9012-3706; Muhammad Abu Bakar 0000-0001-9387-6287; Asim Farooq 0000-0002-4309-3353; Muhammad Tahseen 0000-0002-5240-7721; Muhammad Ishaq 0000-0003-2230-0330; Iqra Masood 0000-0001-6000-6656; Muhammad Usman Rashid 0000-0002-7684-3122.

**Author contributions:** Asghar K generated the hypotheses, designed experiments, carried out lab work and data analysis, and wrote the manuscript; Loya A evaluated the IHC slides and scored them, analyzed the data, and contributed to manuscript writing; Rana IA evaluated the IHC slides and scored them; Bakar MA and Farooq A conducted statistical analysis, analyzed data, and participated in writing the manuscript; Tahseen M and Ishaq M retrieved the blocks and performed IHC; Masood I performed patient data collection and verification from the electronic hospital information system and contributed to manuscript writing; Rashid MU assisted in hypothesis generation and critical appraisal of data.

**Institutional review board statement:** The study was

**Kashif Asghar, Muhammad Usman Rashid**, Department of Basic Science Research, Shaukat Khanum Memorial Cancer Hospital and Research Centre, Lahore, Punjab 54000, Pakistan

**Asif Loya, Iftikhar Ali Rana, Muhammad Tahseen, Muhammad Ishaq**, Department of Pathology, Shaukat Khanum Memorial Cancer Hospital and Research Centre, Lahore, Punjab 54000, Pakistan

**Muhammad Abu Bakar**, Department of Cancer Registry and Clinical Data Management, Shaukat Khanum Memorial Cancer Hospital and Research Centre, Lahore, Punjab 54000, Pakistan

**Asim Farooq, Iqra Masood**, Department of Clinical Research, Shaukat Khanum Memorial Cancer Hospital and Research Centre, Lahore, Punjab 54000, Pakistan

**Corresponding author:** Kashif Asghar, DVM, PhD, Research Scientist, Department of Basic Science Research, Shaukat Khanum Memorial Cancer Hospital and Research Centre, 7A, Block R3, Johar Town, Lahore, Punjab 54000, Pakistan. [drkashifasghar@gmail.com](mailto:drkashifasghar@gmail.com)

## Abstract

## BACKGROUND

Forkhead box P3 (FOXP3) is a specific marker for immunosuppressive regulatory T (T-reg) cells. T-regs and an immunosuppressive enzyme, indoleamine 2,3-dioxygenase (IDO), are associated with advanced disease in cancer.

## AIM

To evaluate the co-expression of FOXP3 and IDO in triple negative breast cancer (TNBC) with respect to hormone-positive breast cancer patients from Pakistan.

## METHODS

Immunohistochemistry was performed to analyze the expression of FOXP3, IDO, estrogen receptor, progesterone receptor, and human epidermal growth factor receptor on tissues of breast cancer patients ( $n = 100$ ): Hormone-positive breast cancer ( $n = 51$ ) and TNBC ( $n = 49$ ). A total of 100 patients were characterized as FOXP3 negative *vs* positive and further categorized based on low, medium, and high IDO expression score. Univariate and multivariate logistic regression models were used.

## RESULTS

reviewed and approved by the Shaukat Khanum Memorial Cancer Hospital and Research Centre Institutional Review Board.

#### Conflict-of-interest statement:

Authors declare no conflict of interests for this manuscript.

**Data sharing statement:** Technical appendix, statistical code, and dataset available from the corresponding author at

[kashifasghar@skm.org.pk](mailto:kashifasghar@skm.org.pk). Consent was not obtained but the presented data are anonymized and risk of identification is low. No additional data are available.

**Open-Access:** This article is an open-access article that was selected by an in-house editor and fully peer-reviewed by external reviewers. It is distributed in accordance with the Creative Commons Attribution NonCommercial (CC BY-NC 4.0) license, which permits others to distribute, remix, adapt, build upon this work non-commercially, and license their derivative works on different terms, provided the original work is properly cited and the use is non-commercial. See: <http://creativecommons.org/licenses/by-nc/4.0/>

**Manuscript source:** Unsolicited manuscript

**Specialty type:** Oncology

**Country/Territory of origin:** Pakistan

**Peer-review report's scientific quality classification**

Grade A (Excellent): 0  
Grade B (Very good): 0  
Grade C (Good): C, C  
Grade D (Fair): 0  
Grade E (Poor): 0

**Received:** April 13, 2020

**Peer-review started:** April 13, 2020

**First decision:** August 9, 2020

**Revised:** August 24, 2020

**Accepted:** October 27, 2020

**Article in press:** October 27, 2020

**Published online:** December 24, 2020

Out of 100 breast tumors, 25% expressed FOXP3 positive T-regs. A significant co-expression of FOXP3 and IDO was observed among patients with TNBC ( $P = 0.01$ ) compared to those with hormone-positive breast cancer. Two variables were identified as significant independent risk factors for FOXP3 positive: IDO expression high (adjusted odds ratio (AOR) 5.90; 95% confidence interval (CI): 1.22-28.64;  $P = 0.03$ ) and TNBC (AOR 2.80; 95%CI: 0.96-7.95;  $P = 0.05$ ).

#### CONCLUSION

Our data showed that FOXP3 positive cells might be associated with high expression of IDO in TNBC patients. FOXP3 and IDO co-expression may also suggest its involvement in disease, and evaluation of FOXP3 and IDO expression in TNBC patients may offer a new therapeutic option.

**Key Words:** Forkhead box P3; Indoleamine 2,3-dioxygenase; Triple negative breast cancer; T-regs; Immunotherapy; Cancer

©The Author(s) 2020. Published by Baishideng Publishing Group Inc. All rights reserved.

**Core Tip:** Forkhead box P3 (FOXP3) positive cells might be associated with high expression of indoleamine 2,3-dioxygenase (IDO) in triple negative breast cancer (TNBC) patients. Evaluation of FOXP3 and IDO expression in TNBC patients may provide a novel effective therapeutic strategy.

**Citation:** Asghar K, Loya A, Rana IA, Bakar MA, Farooq A, Tahseen M, Ishaq M, Masood I, Rashid MU. Forkhead box P3 and indoleamine 2,3-dioxygenase co-expression in Pakistani triple negative breast cancer patients. *World J Clin Oncol* 2020; 11(12): 1018-1028

**URL:** <https://www.wjgnet.com/2218-4333/full/v11/i12/1018.htm>

**DOI:** <https://dx.doi.org/10.5306/wjco.v11.i12.1018>

#### INTRODUCTION

Forkhead box P3 (FOXP3) is a part of the forkhead/winged-helix family of transcription regulators<sup>[1]</sup>. FOXP3 is a specific marker for regulatory T cells (T-regs)<sup>[2]</sup>, which are crucial mediators of peripheral tolerance<sup>[3]</sup>. FOXP3 expression has been reported in breast cancer<sup>[4-6]</sup>, and its quantification in this malignancy can be used as an effective tool to monitor disease progression and predict prognosis<sup>[7]</sup>. The cell count of FOXP3 expressing T-regs increases steadily in breast cancer with increasing stage of disease<sup>[7]</sup>. The mechanisms underlying are still not clear. High numbers of FOXP3 expressing T-regs provide poor prognosis for relapse-free survival in patients with invasive carcinoma<sup>[7]</sup>, but Lee *et al*<sup>[8]</sup> observed the prognostic significance of FOXP3-positive T-regs compared to FOXP3-negative T-regs in triple negative breast cancer (TNBC). Furthermore, they found that improved survival was linked with FOXP3-positive T-regs in TNBC. This finding was in contrast with other types of cancers<sup>[8]</sup>. Therefore, further studies are required to link FOXP3-positive T-regs to good or worse prognosis.

An immunosuppressive enzyme, indoleamine 2,3-dioxygenase (IDO), catabolizes tryptophan into kynurenines<sup>[9,10]</sup>. IDO has the ability to inhibit the immune responses and produce immunosuppression through the differentiation and maturation of T-regs<sup>[11]</sup>. On the other hand, tryptophan depletion by IDO affects the cytotoxicity of T cells<sup>[12]</sup>. It has been reported that tryptophan downstream metabolites induce apoptosis of T cells *in vitro*<sup>[13]</sup>. IDO plays a role in the cancer immune-escape mechanism<sup>[14,15]</sup>. Evidence has suggested that overexpression of IDO has been observed in both antigen-presenting cells and tumor cells in tumor draining lymph nodes<sup>[16]</sup>. IDO overexpression may lead to recruitment of T-regs in breast tumor microenvironment and promote metastasis<sup>[17]</sup>.

TNBC is characterized by lack of expression of estrogen receptor (ER), progesterone receptor (PR), and human epidermal growth factor receptor (HER2)<sup>[18]</sup>. TNBC is a more aggressive tumor than other breast cancers types<sup>[19]</sup>. Our goal was to quantify FOXP3 expression in relation with IDO expression in patients diagnosed with breast cancer



**P-Reviewer:** Scaggiante B**S-Editor:** Fan JR**L-Editor:** Filipodia**P-Editor:** Wang LL

from Pakistan. Pakistan has the highest incidence of breast cancer cases in its region. We further investigated the numbers of FOXP3-positive T-regs in TNBC patients compared to hormone-positive breast cancer patients.

## MATERIALS AND METHODS

### *Sampling and patient data*

For this retrospective analysis, archived formalin-fixed paraffin-embedded (FFPE) blocks of 100 breast cancer patients were retrieved from the pathology department. The study was conducted at Shaukat Khanum Memorial Cancer Hospital and Research Center (SKMCH&RC) Lahore, Pakistan. All the patients were diagnosed with breast cancer between 2007 and 2009, and all patients selected were treatment naïve. Tumor grade was allocated using the Nottingham Histologic Score. Immunohistochemistry was performed to identify the expression of ER, PR, and HER2 by using standard methods<sup>[20]</sup>. Clinico-pathological data were obtained from medical reports of the patients. The current study was approved by the Institutional Review Board (IRB) of the SKMCH&RC (#IRB-16-08) and was exempted from informed consent in agreement with the Declaration of Helsinki Guidelines. We used the specimens of hospital registered patients. The data were recorded in such a manner that the individual identity could not be recognized. This study does not include any procedures that would normally require informed consent outside the context of the study.

### *Immunohistochemical staining of FOXP3 and IDO*

Bond III Leica automated system (Leica Biosystems Melbourne, Australia) was used to perform the immunohistochemistry. Briefly, two sections of FFPE blocks of the same patients were obtained. Bond Dewax solution (#AR922, Leica) was used to deparaffinize the slides. Bond ER-2 (#AR9640, Leica) was used to perform heat induced epitope retrieval on the automated system for 20 min. The primary antibodies FOXP3 (Abcam, #ab22510, Cambridge, United Kingdom) or IDO1 (Abcam, #ab55305) were used at a 1:50 and 1:200 dilution, respectively, in primary antibody diluent and incubated for 5 min. Bond™ polymer refine detection kit was used to visualize FOXP3 and IDO labeling. Peroxidase block was applied for 5min. The slides were then incubated with post primary rabbit anti mouse immunoglobulin G for 8 min, followed by incubation with polymer anti-rabbit poly-horseradish peroxidase-immunoglobulin G for 8 min. Three prime-diaminobenzidine tetrahydrochloride hydrate was applied for 10 min. Counterstaining was performed with hematoxylin for 5 min. Two pathologists were involved in the study, and they conducted a blind histopathologic assessment. The discrepancies between the two pathologists were reviewed mutually to reach the consensus. The mean score of both pathologists was considered as the final score. Staining of at least 25% of cells was considered positive for FOXP3. FOXP3 expression had nuclear localization<sup>[6]</sup>. IDO staining evaluation was based on two factors: (1) Intensity of cytoplasmic staining (0 to 3); and (2) Percentage of cells staining positive (0 to 3). They were categorized as low (1-3), medium (4-6), and high (7-9).

### *Statistical analysis*

Statistical analysis was carried out using SPSS software (version 20.0; SPSS, Armonk, NY, United States). For continuous variables, mean and standard deviation were used. For categorical variables, percentages (proportions) were used. Chi-square or Fisher exact test was performed for bivariate analysis. Independent *t*-test was performed for continuous explanatory variables such as age. Risk factors were identified by using the univariable and multivariable logistic regression model.

## RESULTS

### *Patient baseline characteristics*

A total of 100 breast cancer patients were included in this study with an average age of 48 years. Majority of patients belonged to the Punjab region (88%). Fifty-seven percent of tumors were T2/T3, and 7% tumors were T1 (Tumor Node Metastasis classification). According to the grade distribution, 56% presented grade III. Fifty percent of patients were positive for node, and 49% were positive for metastasis. PR (26%), HER2-neu (26%), and ER (31%) were expressed in the tumor tissue (Table 1).

**Table 1** Baseline characteristics of breast cancer patients

Variables	Levels	Total, n %
Age	mean $\pm$ SD	48.28 $\pm$ 11.83
Region	Punjab	88 (88.0%)
	Khyber Pakhtunkhwa	7.0 (7.0%)
	Kashmir	3.0 (3.0%)
	Sindh	2.0 (2.0%)
Histology	Ductal	91 (91.0%)
	Others	9.0 (9.0%)
Grade	II	35 (35.0%)
	III	56 (56.0%)
	UNK	09 (9.0%)
Tumor size	T1	7.0 (7.0%)
	T2/T3	57 (57.0%)
	UNK	36 (36.0%)
Nodes	Negative	37 (37.0%)
	Positive	50 (50.0%)
	UNK	13 (13.0%)
Metastasis	Negative	38 (38.0%)
	Positive	49 (49.0%)
	UNK	13 (13.0%)
Estrogen receptor	Negative	69 (69.0%)
	Positive	31 (31.0%)
Progesterone receptor	Negative	74 (74.0%)
	Positive	26 (26.0%)
HER2 status	Negative	74 (74.0%)
	Positive	26 (26.0%)
TNBC	No	51 (51.0%)
	Yes	49 (49.0%)
Status	Alive	50 (50.0%)
	Death	35 (35.0%)
	Lost to follow-up	15 (15.0%)
FOXP3	Negative	75 (75.0%)
	Positive	25 (25.0%)
IDO score	Low	24 (24.0%)
	Medium	27 (27.0%)
	High	49 (49.0%)

UNK: Indicates missing data. FOXP3: Forkhead box P3; HER2: Human epidermal growth factor receptor; IDO: Indoleamine 2,3-dioxygenase; TNBC: Triple negative breast cancer; SD: Standard deviation.

We have further categorized baseline characteristics based on TNBC and hormone positive breast cancer in [Table 2](#).



**Table 2** Comparative characteristics of triple negative breast cancer and hormone positive breast cancer patients

Variables	Levels	Triple negative breast cancer, <i>n</i> (%)	Hormone positive breast cancer, <i>n</i> (%)
Age	mean $\pm$ SD	47.24 $\pm$ 11.5	49.27 $\pm$ 12.0
Histology	Ductal	46 (50.5)	45 (49.5)
	Others	3 (33.3)	6 (66.7)
	Total	49 (49.0)	51 (51.0)
Grade	II	9 (25.7)	26 (74.3)
	III	37 (66.1)	19 (33.9)
	UNK	3 (33.3)	6 (66.7)
	Total	49 (49.0)	51 (51.0)
Tumor size	T1	4 (57.1)	3 (42.9)
	T2/T3	26 (45.6)	31 (54.4)
	UNK	19 (52.8)	17 (47.2)
	Total	49 (49.0)	51 (51.0)
Nodes	Negative	23 (62.1)	14 (37.8)
	Positive	21 (42.0)	29 (58.0)
	UNK	5 (38.4)	8 (61.6)
	Total	49 (49.0)	51 (51.0)
Metastasis	Negative	23 (60.5)	15 (39.5)
	Positive	21 (42.8)	28 (57.2)
	UNK	5 (38.4)	8 (61.6)
	Total	49 (49.0)	51 (51.0)

UNK: Indicates missing data. SD: Standard deviation.

**Clinicopathological characteristics of breast cancer patients with FOXP3 expression**

There were 25 out of 100 FOXP3 positive cases (Table 3). Based on immunohistochemistry analysis, FOXP3 expression had nuclear localization. All the cases were invasive ductal carcinoma. Furthermore, 18 out of 25 were TNBC patients. The data of 75 out of 100 FOXP3 negative cases are provided in supplementary data (Supplementary Table 1).

**FOXP3 and IDO co-expression is associated with TNBC**

In order to validate the immunosuppressive effect of FOXP3 and IDO co-expression, we categorized the patients into TNBC and hormone-positive breast cancer groups. The mean age at diagnosis of FOXP3 positive *vs* negative breast cancer cases was 47.32  $\pm$  14.19 years and 48.60  $\pm$  11.02 years, respectively ( $P = 0.64$ ). The majority of patients had grade III tumor ( $n = 18$ ) and grade II tumor ( $n = 07$ ). There was a statistically significant association between FOXP3 and high expression of IDO ( $P = 0.01$ ) and TNBC ( $P = 0.01$ ), respectively. Remaining explanatory variables are presented in Table 4.

**FOXP3 and IDO immunostaining**

To evaluate the expression of FOXP3 and IDO, we selected FFPE tumor specimens of the same patients ( $n = 100$ ). Out of 100 patients, 25 expressed FOXP3-positive T-regs, and 75 expressed FOXP3-negative T-regs (Figure 1). IDO positivity was found in all breast tumor specimens. Synchronal expression of FOXP3 and IDO is shown in Figure 1. Immunostaining of low, medium, and high IDO expression is provided in supplementary data (Figure 1).

**Univariable and multivariable analysis**

Table 5 summarizes the several clinicopathological features that were included in

Table 3 Clinicopathological characteristics of breast cancer patients with nuclear forkhead box P3 expression

Case	Histology	Age in yr	Grade	Nodes	Metastasis	ER	PR	HER2	TNBC
1	Ductal	28	3	0	-	-	-	-	+
2	Ductal	54	3	14	+	-	-	-	+
3	Ductal	67	3	1	+	-	-	-	+
4	Ductal	65	2	UNK	UNK	-	-	-	+
5	Ductal	45	3	13	+	-	-	-	+
6	Ductal	45	3	0	-	-	-	-	+
7	Ductal	55	3	0	-	-	-	-	+
8	Ductal	23	3	0	-	-	-	-	+
9	Ductal	47	2	0	-	-	-	-	+
10	Ductal	73	3	2	+	-	-	-	+
11	Ductal	35	3	0	-	-	-	-	+
12	Ductal	35	3	0	-	-	-	-	+
13	Ductal	52	3	UNK	UNK	-	-	-	+
14	Ductal	39	3	0	-	-	-	-	+
15	Ductal	48	3	0	-	-	-	-	+
16	Ductal	70	3	2	+	-	-	-	+
17	Ductal	40	3	13	+	-	-	-	+
18	Ductal	35	3	13	+	-	-	-	+
19	Ductal	43	3	0	UNK	-	-	+	-
20	Ductal	36	2	1	+	-	-	+	-
21	Ductal	45	3	UNK	UNK	+	+	-	-
22	Ductal	71	2	6	+	+	-	-	-
23	Ductal	30	2	17	+	+	+	-	-
24	Ductal	40	2	UNK	UNK	-	-	+	-
25	Ductal	62	2	0	-	+	+	+	-

UNK: Indicates missing data; Grade: Nottingham Histologic Score; Nodes: No. of nodes involved. ER: Estrogen receptor; HER2: Human epidermal growth factor receptor; PR: Progesterone receptor; TNBC (+): Triple negative breast cancer; TNBC (-): Hormone-positive breast cancer.

unadjusted and adjusted logistic regression model to identify the FOXP3 correlation with IDO expression and TNBC. Two variables were identified as significant independent risk factors for FOXP3 positive: IDO expression high [adjusted odds ratio (AOR) 5.90; 95% confidence interval (CI): 1.22-28.64;  $P = 0.03$ ] and TNBC (AOR 2.80; 95%CI: 0.96-7.95,  $P = 0.05$ ) in multivariable analysis.

## DISCUSSION

The role of immunosuppression in cancer progression is currently evaluated in various cancers<sup>[21-23]</sup>. It has been established that immunological factors such as T-regs are involved in the progression of tumor through induction of immune tolerance in the tumor microenvironment<sup>[7,22]</sup>. T-regs are effective inhibitors of the immune system<sup>[22]</sup>. T-regs create immunosuppressive environment by suppressing effector immune cells<sup>[22]</sup>. They are also associated with poor clinical outcomes in various tumors<sup>[4,7]</sup>. FOXP3 is a specified marker for T-regs<sup>[2]</sup>. Several studies identified that FOXP3<sup>+</sup> T-regs infiltration in tumor microenvironment may affect breast cancer progression<sup>[7,24]</sup>. Bates *et al*<sup>[7]</sup> demonstrated that a high ratio of FOXP3 cells predict worse relapse-free survival and shorten overall survival in patients with invasive breast carcinoma<sup>[7]</sup>. In another

**Table 4 Patients and tumor characteristics of forkhead box P3 negative vs positive**

Variables	Characteristics	FOXP3 negative 75 (75.0%)	FOXP3 positive 25 (25.0%)	P value
Age (yr)	mean $\pm$ SD	48.60 $\pm$ 11.02	47.32 $\pm$ 14.20	0.64
IDO score	Low	22 (91.7%)	2 (8.3%)	0.01 <sup>a</sup>
	Medium	23 (85.2%)	4 (14.8%)	
	High	30 (61.2%)	19 (38.8%)	
Grade	II	28 (80.0%)	7 (20.0%)	0.21
	III	38 (67.9%)	18 (32.1%)	
Metastasis	Negative	27 (71.1%)	11 (28.9%)	0.45
	Positive	39 (79.6%)	10 (20.4%)	
Tumor size	T1	4 (57.1%)	3 (42.9%)	0.15
	T2/T3	46 (80.7%)	11 (19.3%)	
Lymph nodes involvement	Negative	26 (70.3%)	11 (29.7%)	0.29
	Positive	40 (80.0%)	10 (20.0%)	
Estrogen receptor	Negative	48 (69.6%)	21 (30.4%)	0.06
	Positive	27 (87.1%)	4 (12.9%)	
Progesterone receptor	Negative	52 (70.3%)	22 (29.7%)	0.06
	Positive	23 (88.5%)	3 (11.5%)	
HER2-neu receptor	Negative	53 (71.6%)	21 (28.4%)	0.19
	Positive	22 (84.6%)	4 (15.4%)	
Triple negative breast cancer	No	44 (86.3%)	7 (13.7%)	0.01 <sup>a</sup>
	Yes	31 (63.3%)	18 (36.7%)	

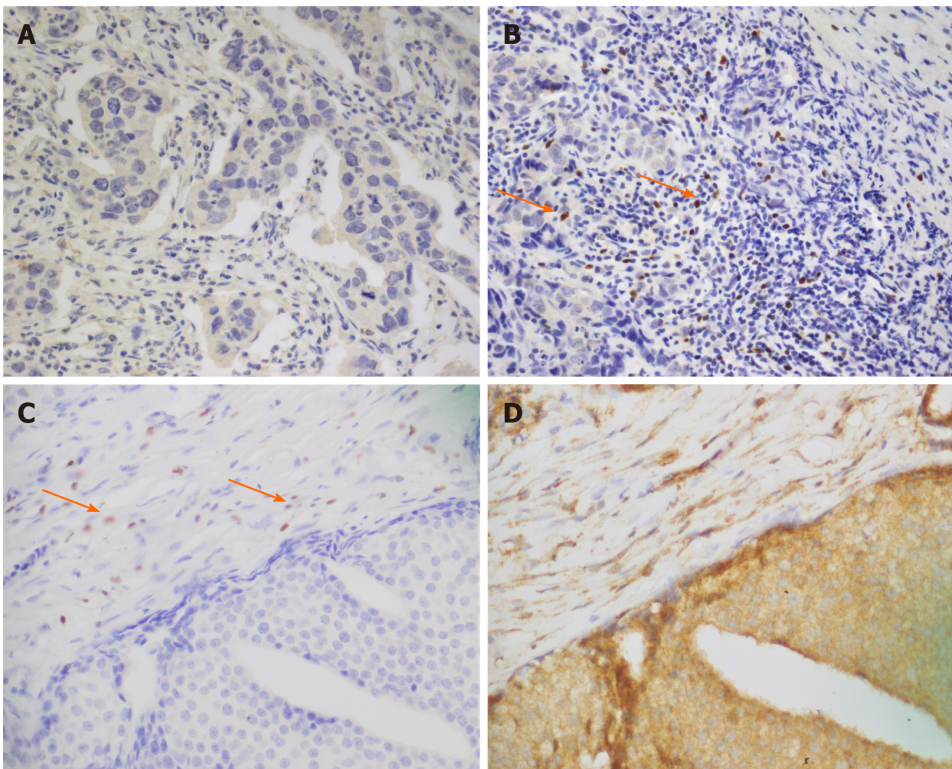
<sup>a</sup>P < 0.05. IDO: Indoleamine 2,3-dioxygenase; HER2: Human epidermal growth factor receptor; FOXP3: Forkhead box P3; SD: Standard deviation.

**Table 5 Univariable and multivariable logistic regression analysis for forkhead box P3-negative (reference) vs forkhead box P3-positive**

Variables	Characteristics	Univariable analysis odds ratio (95%CI), P value	Multivariable analysis odds ratio (95%CI), P value
IDO score	Low	Ref.	Ref.
	Medium	1.91 (0.32-11.52), 0.50	2.32 (0.37-14.50), 0.37
	High	6.97 (1.50-33.10), 0.01 <sup>a</sup>	5.90 (1.22-28.64), 0.03 <sup>a</sup>
Triple negative breast cancer	No	Ref.	Ref.
	Yes	3.65 (1.36-9.80), 0.01 <sup>a</sup>	2.80 (0.96-7.95), 0.05 <sup>a</sup>

<sup>a</sup>P < 0.05. IDO: Indoleamine 2,3-dioxygenase.

study the researchers observed no difference in overall survival among patients expressing high or low FOXP3<sup>[25]</sup>. There is contradictory data regarding the involvement of FOXP3<sup>+</sup> T-regs in breast cancer patients. Nevertheless, we investigated FOXP3 positive *vs* negative expression in the current study. FOXP3 expression was identified in 25 breast cancer patients, and a majority of these patients displayed TNBC phenotype. Overall, 36.73% of TNBC patients expressed FOXP3 positive cells, while 13.72% of hormone positive breast cancer patients expressed FOXP3 positive cells. On the other hand, FOXP3 expression was not detected in 63.26% of TNBC patients and 86.27% of hormone positive breast cancer patients. Our findings of FOXP3 T-regs infiltration in TNBC patients is similar to several studies published before that identified the involvement of FOXP3 positive cells in breast cancer progression<sup>[7,24]</sup>.



**Figure 1** Formalin-fixed paraffin-embedded tumor specimens. A and B: Forkhead box P3 (FOXP3) immunohistochemical staining; A: Invasive ductal carcinoma with FOXP3-negative expression; B: FOXP3-positive lymphocytic infiltration in invasive ductal carcinoma. The staining was nuclear; C and D: Co-expression of FOXP3 and indoleamine 2,3-dioxygenase (IDO), FOXP3 and IDO expression in breast cancer tissues ( $n = 100$ ) were evaluated; C: FOXP3 positive cells infiltrated in invasive ductal carcinoma (nuclear staining). Sections from matched breast cancer patients were stained for IDO; D: Strong and diffuse IDO staining in invasive ductal tumor cells (cytoplasmic staining). Images were captured at  $\times 40$  magnification.

FOXP3<sup>+</sup> T-regs can restrain effector T cells by an IDO dependent mechanism<sup>[9]</sup>. IDO plays a critical role in the pathogenesis of breast cancer<sup>[26]</sup>. IDO overexpression is linked with shorter overall survival and poor prognosis<sup>[27-34]</sup>. FOXP3<sup>+</sup> T-regs have prognostic implications in TNBC<sup>[8]</sup>. IDO expression is also associated with TNBC<sup>[26]</sup>. Previously we showed high IDO expression in TNBC patients from Pakistan<sup>[35]</sup>. The aim of our current study was to identify the substantial association between FOXP3-positive T-regs and IDO in TNBC patients. There was a statistically significant association of FOXP3 with high IDO expression ( $P = 0.01$ ) and TNBC ( $P = 0.01$ ) respectively. Two variables were recognized as significant independent risk factors for FOXP3 positive: IDO expression high (AOR 5.90; 95%CI: 1.22-28.64;  $P = 0.03$ ) and TNBC (AOR 2.80; 95%CI: 0.96-7.95;  $P = 0.05$ ) in multivariable analysis. Although several studies focus on the role of immunosuppression in TNBC, our data provide some insight regarding immunosuppression in association with simultaneous expression of FOXP3 and IDO in TNBC patients.

Our study has some limitations, which have to be mentioned. The study population ( $n = 100$ ) did not permit us to draw any strong conclusion. Forthcoming projects on breast cancer patients from Pakistan with inclusive cohort studies are required to authenticate conclusive associations.

Identification of an appropriate immunotherapeutic target for TNBC is currently a hot-topic. FOXP3 and IDO co-expression has the ability to inhibit anti-tumor immune responses and may be considered one of the hurdles in the development of successful immunotherapy for cancer. The role of FOXP3 and IDO co-expression is still a subject of rigorous research in breast cancer.

## CONCLUSION

In conclusion, the current data revealed that FOXP3 positive cells might be associated with high IDO expression in TNBC patients. FOXP3 and IDO expression monitoring in TNBC patients may provide an effective therapeutic strategy.

## ARTICLE HIGHLIGHTS

**Research background**

Forkhead box P3 (FOXP3) and indoleamine 2,3-dioxygenase (IDO) are associated with advanced disease in cancer (*e.g.*, breast cancer).

**Research motivation**

To quantify FOXP3 expression in relation with IDO expression in patients diagnosed with breast cancer from Pakistan.

**Research objectives**

Our objective was to identify the co-expression of FOXP3 and IDO in triple negative breast cancer (TNBC) patients.

**Research methods**

Immunohistochemistry was performed to analyze the expression of FOXP3, IDO, estrogen receptor, progesterone receptor, and human epidermal growth factor receptor in human breast cancer tissues.

**Research results**

A significant association of FOXP3 and IDO co-expression was observed among patients with TNBC ( $P = 0.01$ ).

**Research conclusions**

FOXP3 positive cells might be associated with high expression of IDO in TNBC patients.

**Research perspectives**

Evaluation of FOXP3 and IDO expression in TNBC patients may be implemented in the future as a therapeutic strategy.

## REFERENCES

- 1 **Coffier PJ**, Burgering BM. Forkhead-box transcription factors and their role in the immune system. *Nat Rev Immunol* 2004; **4**: 889-899 [PMID: [15516968](#) DOI: [10.1038/nri1488](#)]
- 2 **Curjel TJ**. Regulatory T cells and treatment of cancer. *Curr Opin Immunol* 2008; **20**: 241-246 [PMID: [18508251](#) DOI: [10.1016/j.coi.2008.04.008](#)]
- 3 **Watanabe MA**, Oda JM, Amarante MK, Cesar Voltarelli J. Regulatory T cells and breast cancer: implications for immunopathogenesis. *Cancer Metastasis Rev* 2010; **29**: 569-579 [PMID: [20830504](#) DOI: [10.1007/s10555-010-9247-y](#)]
- 4 **Ladoire S**, Arnould L, Mignot G, Coudert B, Rébé C, Chalmin F, Vincent J, Bruchard M, Chauffert B, Martin F, Fumoleau P, Ghiringhelli F. Presence of Foxp3 expression in tumor cells predicts better survival in HER2-overexpressing breast cancer patients treated with neoadjuvant chemotherapy. *Breast Cancer Res Treat* 2011; **125**: 65-72 [PMID: [20229175](#) DOI: [10.1007/s10549-010-0831-1](#)]
- 5 **Zuo T**, Wang L, Morrison C, Chang X, Zhang H, Li W, Liu Y, Wang Y, Liu X, Chan MW, Liu JQ, Love R, Liu CG, Godfrey V, Shen R, Huang TH, Yang T, Park BK, Wang CY, Zheng P, Liu Y. FOXP3 is an X-linked breast cancer suppressor gene and an important repressor of the HER-2/ErbB2 oncogene. *Cell* 2007; **129**: 1275-1286 [PMID: [17570480](#) DOI: [10.1016/j.cell.2007.04.034](#)]
- 6 **Merlo A**, Casalini P, Carcangiu ML, Malventano C, Triulzi T, Ménard S, Tagliabue E, Balsari A. FOXP3 expression and overall survival in breast cancer. *J Clin Oncol* 2009; **27**: 1746-1752 [PMID: [19255331](#) DOI: [10.1200/JCO.2008.17.9036](#)]
- 7 **Bates GJ**, Fox SB, Han C, Leek RD, Garcia JF, Harris AL, Banham AH. Quantification of regulatory T cells enables the identification of high-risk breast cancer patients and those at risk of late relapse. *J Clin Oncol* 2006; **24**: 5373-5380 [PMID: [17135638](#) DOI: [10.1200/JCO.2006.05.9584](#)]
- 8 **Lee S**, Cho EY, Park YH, Ahn JS, Im YH. Prognostic impact of FOXP3 expression in triple-negative breast cancer. *Acta Oncol* 2013; **52**: 73-81 [PMID: [23075422](#) DOI: [10.3109/0284186X.2012.731520](#)]
- 9 **Mansfield AS**, Heikkilä PS, Vaara AT, von Smitten KA, Vakkila JM, Leidenius MH. Simultaneous Foxp3 and IDO expression is associated with sentinel lymph node metastases in breast cancer. *BMC Cancer* 2009; **9**: 231 [PMID: [19604349](#) DOI: [10.1186/1471-2407-9-231](#)]
- 10 **Muller AJ**, DuHadaway JB, Donover PS, Sutanto-Ward E, Prendergast GC. Inhibition of indoleamine 2,3-dioxygenase, an immunoregulatory target of the cancer suppression gene Bin1, potentiates cancer chemotherapy. *Nat Med* 2005; **11**: 312-319 [PMID: [15711557](#) DOI: [10.1038/nm1196](#)]
- 11 **Mellor AL**, Munn DH. Tryptophan catabolism and T-cell tolerance: immunosuppression by



- starvation? *Immunol Today* 1999; **20**: 469-473 [PMID: [10500295](#) DOI: [10.1016/s0167-5699\(99\)01520-0](#)]
- 12 **Lee GK**, Park HJ, Macleod M, Chandler P, Munn DH, Mellor AL. Tryptophan deprivation sensitizes activated T cells to apoptosis prior to cell division. *Immunology* 2002; **107**: 452-460 [PMID: [12460190](#) DOI: [10.1046/j.1365-2567.2002.01526.x](#)]
  - 13 **Munn DH**, Shafizadeh E, Attwood JT, Bondarev I, Pashine A, Mellor AL. Inhibition of T cell proliferation by macrophage tryptophan catabolism. *J Exp Med* 1999; **189**: 1363-1372 [PMID: [10224276](#) DOI: [10.1084/jem.189.9.1363](#)]
  - 14 **Mellor AL**, Munn DH. IDO expression by dendritic cells: tolerance and tryptophan catabolism. *Nat Rev Immunol* 2004; **4**: 762-774 [PMID: [15459668](#) DOI: [10.1038/nri1457](#)]
  - 15 **Grohmann U**, Fallarino F, Puccetti P. Tolerance, DCs and tryptophan: much ado about IDO. *Trends Immunol* 2003; **24**: 242-248 [PMID: [12738417](#) DOI: [10.1016/s1471-4906\(03\)00072-3](#)]
  - 16 **Katz JB**, Muller AJ, Prendergast GC. Indoleamine 2,3-dioxygenase in T-cell tolerance and tumoral immune escape. *Immunol Rev* 2008; **222**: 206-221 [PMID: [18364004](#) DOI: [10.1111/j.1600-065X.2008.00610.x](#)]
  - 17 **Yu J**, Sun J, Wang SE, Li H, Cao S, Cong Y, Liu J, Ren X. Upregulated expression of indoleamine 2, 3-dioxygenase in primary breast cancer correlates with increase of infiltrated regulatory T cells in situ and lymph node metastasis. *Clin Dev Immunol* 2011; **2011**: 469135 [PMID: [22110525](#) DOI: [10.1155/2011/469135](#)]
  - 18 **Curigliano G**, Goldhirsch A. The triple-negative subtype: new ideas for the poorest prognosis breast cancer. *J Natl Cancer Inst Monogr* 2011; **2011**: 108-110 [PMID: [22043054](#) DOI: [10.1093/jncimonographs/lgr038](#)]
  - 19 **Penault-Llorca F**, Viale G. Pathological and molecular diagnosis of triple-negative breast cancer: a clinical perspective. *Ann Oncol* 2012; **23** Suppl 6: vi19-vi22 [PMID: [23012297](#) DOI: [10.1093/annonc/mds190](#)]
  - 20 **Chen X**, Cho DB, Yang PC. Double staining immunohistochemistry. *N Am J Med Sci* 2010; **2**: 241-245 [PMID: [22574297](#) DOI: [10.4297/najms.2010.2241](#)]
  - 21 **Disis ML**, Lysterly HK. Global role of the immune system in identifying cancer initiation and limiting disease progression. *J Clin Oncol* 2005; **23**: 8923-8925 [PMID: [16339754](#) DOI: [10.1200/JCO.2005.10.007](#)]
  - 22 **Kalathil SG**, Thanavala Y. High immunosuppressive burden in cancer patients: a major hurdle for cancer immunotherapy. *Cancer Immunol Immunother* 2016; **65**: 813-819 [PMID: [26910314](#) DOI: [10.1007/s00262-016-1810-0](#)]
  - 23 **Penn I**, Starzl TE. Immunosuppression and cancer. *Transplant Proc* 1973; **5**: 943-947 [PMID: [4735211](#)]
  - 24 **Ladoire S**, Arnould L, Apetoh L, Coudert B, Martin F, Chauffert B, Fumoleau P, Ghiringhelli F. Pathologic complete response to neoadjuvant chemotherapy of breast carcinoma is associated with the disappearance of tumor-infiltrating foxp3+ regulatory T cells. *Clin Cancer Res* 2008; **14**: 2413-2420 [PMID: [18413832](#) DOI: [10.1158/1078-0432.CCR-07-4491](#)]
  - 25 **Wolf AM**, Rumpold H, Wolf D, Gastl G, Reimer D, Jenewein N, Marth C, Zeimet AG. Role of forkhead box protein 3 expression in invasive breast cancer. *J Clin Oncol* 2007; **25**: 4499-500; author reply 4500 [PMID: [17906214](#) DOI: [10.1200/JCO.2007.13.2092](#)]
  - 26 **Kim S**, Park S, Cho MS, Lim W, Moon BI, Sung SH. Strong Correlation of Indoleamine 2,3-Dioxygenase 1 Expression with Basal-Like Phenotype and Increased Lymphocytic Infiltration in Triple-Negative Breast Cancer. *J Cancer* 2017; **8**: 124-130 [PMID: [28123606](#) DOI: [10.7150/jca.17437](#)]
  - 27 **Brandacher G**, Perathoner A, Ladurner R, Schneeberger S, Obrist P, Winkler C, Werner ER, Werner-Felmayer G, Weiss HG, Göbel G, Margreiter R, Königsrainer A, Fuchs D, Amberger A. Prognostic value of indoleamine 2,3-dioxygenase expression in colorectal cancer: effect on tumor-infiltrating T cells. *Clin Cancer Res* 2006; **12**: 1144-1151 [PMID: [16489067](#) DOI: [10.1158/1078-0432.CCR-05-1966](#)]
  - 28 **Okamoto A**, Nikaido T, Ochiai K, Takakura S, Saito M, Aoki Y, Ishii N, Yanaihara N, Yamada K, Takikawa O, Kawaguchi R, Isonishi S, Tanaka T, Urashima M. Indoleamine 2,3-dioxygenase serves as a marker of poor prognosis in gene expression profiles of serous ovarian cancer cells. *Clin Cancer Res* 2005; **11**: 6030-6039 [PMID: [16115948](#) DOI: [10.1158/1078-0432.CCR-04-2671](#)]
  - 29 **Ino K**, Yoshida N, Kajiyama H, Shibata K, Yamamoto E, Kidokoro K, Takahashi N, Terauchi M, Nawa A, Nomura S, Nagasaka T, Takikawa O, Kikkawa F. Indoleamine 2,3-dioxygenase is a novel prognostic indicator for endometrial cancer. *Br J Cancer* 2006; **95**: 1555-1561 [PMID: [17117179](#) DOI: [10.1038/sj.bjc.6603477](#)]
  - 30 **Huang A**, Fuchs D, Widner B, Glover C, Henderson DC, Allen-Mersh TG. Serum tryptophan decrease correlates with immune activation and impaired quality of life in colorectal cancer. *Br J Cancer* 2002; **86**: 1691-1696 [PMID: [12087451](#) DOI: [10.1038/sj.bjc.6600336](#)]
  - 31 **Ino K**, Yamamoto E, Shibata K, Kajiyama H, Yoshida N, Terauchi M, Nawa A, Nagasaka T, Takikawa O, Kikkawa F. Inverse correlation between tumoral indoleamine 2,3-dioxygenase expression and tumor-infiltrating lymphocytes in endometrial cancer: its association with disease progression and survival. *Clin Cancer Res* 2008; **14**: 2310-2317 [PMID: [18413819](#) DOI: [10.1158/1078-0432.CCR-07-4144](#)]
  - 32 **Astigiano S**, Morandi B, Costa R, Mastracci L, D'Agostino A, Ratto GB, Melioli G, Frumento G. Eosinophil granulocytes account for indoleamine 2,3-dioxygenase-mediated immune escape in human

- non-small cell lung cancer. *Neoplasia* 2005; **7**: 390-396 [PMID: [15967116](#) DOI: [10.1593/neo.04658](#)]
- 33 **Weinlich G**, Murr C, Richardsen L, Winkler C, Fuchs D. Decreased serum tryptophan concentration predicts poor prognosis in malignant melanoma patients. *Dermatology* 2007; **214**: 8-14 [PMID: [17191041](#) DOI: [10.1159/000096906](#)]
- 34 **Takao M**, Okamoto A, Nikaido T, Urashima M, Takakura S, Saito M, Saito M, Okamoto S, Takikawa O, Sasaki H, Yasuda M, Ochiai K, Tanaka T. Increased synthesis of indoleamine-2,3-dioxygenase protein is positively associated with impaired survival in patients with serous-type, but not with other types of, ovarian cancer. *Oncol Rep* 2007; **17**: 1333-1339 [PMID: [17487387](#) DOI: [10.3892/or.17.6.1333](#)]
- 35 **Asghar K**, Loya A, Rana IA, Tahseen M, Ishaq M, Farooq A, Bakar MA, Masood I. Indoleamine 2,3-dioxygenase expression and overall survival in patients diagnosed with breast cancer in Pakistan. *Cancer Manag Res* 2019; **11**: 475-481 [PMID: [30655699](#) DOI: [10.2147/CMAR.S184221](#)]





Published by **Baishideng Publishing Group Inc**  
7041 Koll Center Parkway, Suite 160, Pleasanton, CA 94566, USA

**Telephone:** +1-925-3991568

**E-mail:** [bpgoffice@wjgnet.com](mailto:bpgoffice@wjgnet.com)

**Help Desk:** <https://www.f6publishing.com/helpdesk>

<https://www.wjgnet.com>

