

World Journal of *Clinical Oncology*

World J Clin Oncol 2021 November 24; 12(11): 966-1088



Contents

Monthly Volume 12 Number 11 November 24, 2021

REVIEW

- 966 Modulation of the immune response by heterogeneous monocytes and dendritic cells in lung cancer
Kwiecień I, Rutkowska E, Raniszewska A, Rzepecki P, Domagala-Kulawik J
- 983 New challenges in the combination of radiotherapy and immunotherapy in non-small cell lung cancer
Luna J, Zafra J, Areses Manrique MC, Rodríguez A, Sotoca A, Fírvila JL, Chicas-Sett R, Mielgo X, Reyes JCT, Couñago F

MINIREVIEWS

- 1000 Consensus molecular subtypes of colorectal cancer in clinical practice: A translational approach
Valenzuela G, Canepa J, Simonetti C, Solo de Zaldívar L, Marcelain K, González-Montero J

ORIGINAL ARTICLE

Retrospective Cohort Study

- 1009 Real-world evaluation of upfront docetaxel in metastatic castration-sensitive prostate cancer
Isaksson J, Green H, Papantoniou D, Pettersson L, Anden M, Rosell J, Ávall-Lundqvist E, Elander NO
- 1023 Uptake and outcomes of small intestinal and urinary tract cancer surveillance in Lynch syndrome
DeJesse J, Vajravelu RK, Dudzik C, Constantino G, Long JM, Wangenstein KJ, Valverde KD, Katona BW

Retrospective Study

- 1037 First-line pazopanib in patients with advanced non-clear cell renal carcinoma: An Italian case series
Buti S, Bersanelli M, Massari F, De Giorgi U, Caffo O, Aurilio G, Basso U, Carteni G, Caserta C, Galli L, Boccardo F, Procopio G, Facchini G, Fornarini G, Berruti A, Fea E, Naglieri E, Petrelli F, Iacovelli R, Porta C, Mosca A
- 1047 Pathological response to neoadjuvant therapy with chemotherapy vs chemoradiotherapy in stage III NSCLC. Contribution of IASLC recommendations
Muñoz-Guglielmetti D, Sanchez-Lorente D, Reyes R, Martinez D, Lucena C, Boada M, Paredes P, Parera-Roig M, Vollmer I, Mases J, Martin-Deleon R, Castillo S, Benegas M, Muñoz S, Mayoral M, Cases C, Mollà M, Casas F

Observational Study

- 1064 Modulated electro-hyperthermia in stage III and IV pancreatic cancer: Results of an observational study on 158 patients
Fiorentini G, Sarti D, Ranieri G, Gadaleta CD, Fiorentini C, Milandri C, Mambrini A, Guadagni S

CASE REPORT

- 1072 Anaplastic myxopapillary ependymoma: A case report and review of literature
Kanno H, Kanetsuna Y, Shinonaga M

- 1083** Foreign body granulomas mimic peritoneal dissemination caused by incarcerated femoral hernia perforation: A case report

Ogino S, Matsumoto T, Kamada Y, Koizumi N, Fujiki H, Nakamura K, Yamano T, Sakakura C

ABOUT COVER

Editorial Board Member of *World Journal of Clinical Oncology*, Mehmet Yildirim, MD, PhD, Professor, Department of Surgery, University of Health Sciences, Izmir Bozyaka Education and Research Hospital, Izmir 35900, Turkey. mehmetyildi@gmail.com

AIMS AND SCOPE

The primary aim of *World Journal of Clinical Oncology* (WJCO, *World J Clin Oncol*) is to provide scholars and readers from various fields of oncology with a platform to publish high-quality basic and clinical research articles and communicate their research findings online.

WJCO mainly publishes articles reporting research results and findings obtained in the field of oncology and covering a wide range of topics including art of oncology, biology of neoplasia, breast cancer, cancer prevention and control, cancer-related complications, diagnosis in oncology, gastrointestinal cancer, genetic testing for cancer, gynecologic cancer, head and neck cancer, hematologic malignancy, lung cancer, melanoma, molecular oncology, neurooncology, palliative and supportive care, pediatric oncology, surgical oncology, translational oncology, and urologic oncology.

INDEXING/ABSTRACTING

The WJCO is now abstracted and indexed in PubMed, PubMed Central, Emerging Sources Citation Index (Web of Science), China National Knowledge Infrastructure (CNKI), China Science and Technology Journal Database (CSTJ), and Superstar Journals Database. The 2021 edition of Journal Citation Reports® cites the 2020 Journal Citation Indicator (JCI) for WJCO as 0.48.

RESPONSIBLE EDITORS FOR THIS ISSUE

Production Editor: Ying-Yi Yuan; Production Department Director: Yu-Jie Ma; Editorial Office Director: Ze-Mao Gong.

NAME OF JOURNAL

World Journal of Clinical Oncology

ISSN

ISSN 2218-4333 (online)

LAUNCH DATE

November 10, 2010

FREQUENCY

Monthly

EDITORS-IN-CHIEF

Hiten RH Patel, Stephen Safe

EDITORIAL BOARD MEMBERS

<https://www.wjnet.com/2218-4333/editorialboard.htm>

PUBLICATION DATE

November 24, 2021

COPYRIGHT

© 2021 Baishideng Publishing Group Inc

INSTRUCTIONS TO AUTHORS

<https://www.wjnet.com/bpg/gerinfo/204>

GUIDELINES FOR ETHICS DOCUMENTS

<https://www.wjnet.com/bpg/GerInfo/287>

GUIDELINES FOR NON-NATIVE SPEAKERS OF ENGLISH

<https://www.wjnet.com/bpg/gerinfo/240>

PUBLICATION ETHICS

<https://www.wjnet.com/bpg/GerInfo/288>

PUBLICATION MISCONDUCT

<https://www.wjnet.com/bpg/gerinfo/208>

ARTICLE PROCESSING CHARGE

<https://www.wjnet.com/bpg/gerinfo/242>

STEPS FOR SUBMITTING MANUSCRIPTS

<https://www.wjnet.com/bpg/GerInfo/239>

ONLINE SUBMISSION

<https://www.f6publishing.com>

Foreign body granulomas mimic peritoneal dissemination caused by incarcerated femoral hernia perforation: A case report

Shinpei Ogino, Tatsuya Matsumoto, Yosuke Kamada, Noriaki Koizumi, Hiroshi Fujiki, Kenji Nakamura, Takeshi Yamano, Chouhei Sakakura

ORCID number: Shinpei Ogino 0000-0001-9867-7623; Tatsuya Matsumoto 0000-0002-1191-1729; Yosuke Kamada 0000-0002-9592-6900; Noriaki Koizumi 0000-0003-4455-5588; Hiroshi Fujiki 0000-0001-7072-4387; Kenji Nakamura 0000-0002-5301-7557; Takeshi Yamano 0000-0003-3195-4870; Chouhei Sakakura 0000-0003-4404-6740.

Author contributions: Ogino S was a major contributor; Matsumoto T, Yamano T and Sakakura C supervised in writing the manuscript; Ogino S, Kamada Y, Koizumi N, Fujiki H and Nakamura K performed patient treatment; Yamano T performed the pathological diagnosis; all authors read and approved the final manuscript.

Informed consent statement: The study participant provided informed written consent prior to their treatments and study enrollment.

Conflict-of-interest statement: All authors declare no conflict of interest related to this study or its publication.

CARE Checklist (2016) statement: The authors have read the CARE Checklist (2016), and the manuscript was prepared and revised according to the CARE

Shinpei Ogino, Tatsuya Matsumoto, Yosuke Kamada, Noriaki Koizumi, Hiroshi Fujiki, Kenji Nakamura, Chouhei Sakakura, Department of Surgery, Akashi City Hospital, Akashi 673-8501, Hyogo, Japan

Takeshi Yamano, Department of Pathology, Akashi City Hospital, Akashi 673-8501, Hyogo, Japan

Corresponding author: Shinpei Ogino, MD, PhD, Doctor, Surgeon, Department of Surgery, Akashi City Hospital, 1-33 Takasho-machi, Akashi 673-8501, Hyogo, Japan.
s-ogino@koto.kpu-m.ac.jp

Abstract

BACKGROUND

Foreign body granuloma (FBG) is a well-known type of granulomatous formation, and intraabdominal FBG (IFBG) is primarily caused by surgical residues. Multifocal IFBGs caused by gastrointestinal perforation is an extremely rare and interesting clinicopathological condition that resembles peritoneal dissemination. Here, we present a case of IFBGs mimicking peritoneal dissemination caused by bowel perforation and describe the value of intraoperative pathological examinations for rapid IFBG diagnosis.

CASE SUMMARY

An 86-year-old woman with an incarcerated femoral hernia was admitted to the hospital and underwent operation. During the operation, the incarcerated ileum was perforated during repair due to hemorrhage necrosis, and a small volume of enteric fluid leaked from the perforation. The incarcerated ileum was resected, and the femoral hernia was repaired without mesh. Four months later, a second operation was performed for an umbilical incisional hernia. During the second operation, multiple small, white nodules were observed throughout the abdominal cavity, resembling peritoneal dissemination. The results of peritoneal washing cytology in Douglas' pouch and the examination of frozen nodule sections were compatible with IFBG diagnosis, and incisional hernia repair was performed.

CONCLUSION

IFBGs can mimic malignancy. Intraoperative pathological examinations and operation history are valuable for the rapid diagnosis to avoid excessive

Checklist (2016).

Country/Territory of origin: Japan

Specialty type: Oncology

Provenance and peer review:

Unsolicited article; Externally peer reviewed.

Peer-review report's scientific quality classification

Grade A (Excellent): 0

Grade B (Very good): B

Grade C (Good): 0

Grade D (Fair): 0

Grade E (Poor): 0

Open-Access: This article is an open-access article that was selected by an in-house editor and fully peer-reviewed by external reviewers. It is distributed in accordance with the Creative Commons Attribution NonCommercial (CC BY-NC 4.0) license, which permits others to distribute, remix, adapt, build upon this work non-commercially, and license their derivative works on different terms, provided the original work is properly cited and the use is non-commercial. See: <http://creativecommons.org/licenses/by-nc/4.0/>

Received: May 22, 2021

Peer-review started: May 22, 2021

First decision: August 18, 2021

Revised: August 20, 2021

Accepted: September 30, 2021

Article in press: September 30, 2021

Published online: November 24, 2021

P-Reviewer: Liu YC

S-Editor: Gao CC

L-Editor: A

P-Editor: Gao CC



treatments.

Key Words: Foreign body granuloma; Peritoneal dissemination; Peritoneal seeding; Perforation; Operation; Case report

©The Author(s) 2021. Published by Baishideng Publishing Group Inc. All rights reserved.

Core Tip: Multifocal intraabdominal foreign body granulomas (IFBGs) caused by gastrointestinal perforation are clinically rare and mimic peritoneal dissemination. An 86-year-old woman underwent an operation to treat an incarcerated femoral hernia; however, the incarcerated ileum was perforated due to hemorrhage necrosis, resulting in incarcerated ileum resection. After 4 mo, a second laparoscopic operation was conducted for an umbilical incisional hernia; however, small, white nodules were identified throughout the entire abdominal cavity, mimicking peritoneal dissemination. Using intraoperative cytology and frozen sections, the nodules were diagnosed as IFBGs. IFBGs sometimes mimic peritoneal dissemination, and intraoperative pathological examinations are effective for rapid diagnosis.

Citation: Ogino S, Matsumoto T, Kamada Y, Koizumi N, Fujiki H, Nakamura K, Yamano T, Sakakura C. Foreign body granulomas mimic peritoneal dissemination caused by incarcerated femoral hernia perforation: A case report. *World J Clin Oncol* 2021; 12(11): 1083-1088

URL: <https://www.wjgnet.com/2218-4333/full/v12/i11/1083.htm>

DOI: <https://dx.doi.org/10.5306/wjco.v12.i11.1083>

INTRODUCTION

A foreign body granuloma (FBG) is a tissue reaction caused by retained foreign bodies, and intraabdominal FBGs (IFBGs) are typically caused by materials used in a previous operation, such as surgical sutures, gauze, and sponges[1-3]. However, in rare cases, bowel perforation, bile or gallstone spillage, and foreign bodies unrelated to operations, such as fish bones, can result in IFBGs[4-6]. Furthermore, IFBGs sometimes occur multifocally and can closely resemble peritoneal dissemination, leading to misdiagnosis[5,7]. Here, we present a case of IFBGs mimicking peritoneal dissemination 4 mo after an operation to treat an incarcerated and perforated femoral hernia.

CASE PRESENTATION

Chief complaints

An 86-year-old woman presented to our hospital with anorexia and vomiting for 3 d.

History of present illness

Her medical history was unremarkable.

History of past illness

Past appendectomy.

Personal and family history

No special in personal and family history.

Physical examination

Severe pain with redness and a palpable bulge was observed in the right inguinal area.

Laboratory examinations

The laboratory workup showed a white blood cell count of $17.1 \times 10^9/L$ and C-reactive protein levels at 6.13 mg/dL.

Imaging examinations

Abdominal computed tomography (CT) showed a right incarcerated femoral hernia with small bowel obstruction.

FINAL DIAGNOSIS

FBG (see TREATMENT section).

TREATMENT

The laparoscopic repair of an incarcerated femoral hernia was attempted; however, the incarcerated ileum was perforated during the repair because it had become necrotic. The necrotic ileum was resected, and the right femoral hernia was repaired using the McVay procedure (Figure 1). Although postoperative intensive care for septic shock and disseminated intravascular coagulation was necessary, the patient was discharged one month after the operation. The patient revisited our hospital 3 mo later due to an umbilical incisional hernia, and laparoscopic incisional hernia repair was performed. During the operation, the hernia orifice, 11 cm in diameter, was identified at the umbilical wound, and multiple small white nodules expanded throughout the entire abdominal cavity (Figure 2). We suspected the peritoneal dissemination of some tumors. Because no observable tumor could be located in the abdominal cavity, peritoneal wash cytology of Douglas's pouch was performed, and frozen sections of the nodules were examined. The cytology was negative for malignancy (Figure 3), and the frozen sections showed a multinucleated giant cell containing a foreign body, surrounded by inflammatory cells, fibrosis, and granulomatous formations (Figure 4), which was compatible with an FBG reaction. Therefore, laparoscopic intraperitoneal onlay mesh repair with hernia orifice closure (IPOM-plus) was performed.

OUTCOME AND FOLLOW-UP

The postoperative clinical course was uneventful, and no malignant findings were observed on chest-to-abdominal enhanced CT or gastrointestinal and colon endoscopy. No malignancy was detected, and no recurrence of hernia was observed during 7 mo of follow-up.

DISCUSSION

FBG is a chronic immune reaction induced by the presence of a foreign body. IFBG is typically caused by retained surgical residues, bowel perforation, bile spillage, gallstones, or fish bones[1,2,4-6,8]. Suture granulomas are the most common type associated with surgical residuals, although gauze and sponges have also been reported[1-3]. IFBGs occasionally resemble tumorous nodules and sometimes occur multifocally, which can mimic peritoneal dissemination[2,8]. IFBG is also well-known to be caused by glove powder used in operations. IFBGs associated with lycopodium, talcum, and starch powders from surgical gloves have previously been reported, and these IFBGs can be quite difficult to differentiate from cancerous nodules[7,9,10]. Akita *et al*[5] reported that food starch released from gastrointestinal perforations could cause multiple IFBGs, mimicking peritoneal dissemination; they reported a case in which tenderness and guarding over the entire abdomen was observed due to a gastric cancer perforation, which was treated surgically. Two months later, many small, white granulomas mimicking peritoneal dissemination were observed, particularly in the upper abdominal cavity, which were diagnosed as IFBGs based on frozen sections during the second operation. In the pathological findings, saburra was observed at the center of the granuloma.

In the present case, multiple small, white nodules that expanded throughout the entire abdominal cavity were observed during the second operation, which were extremely difficult to differentiate from peritoneal dissemination. A multinucleated giant cell containing a foreign body similar to saburra and surrounded by inflammatory cells and granuloma formation was observed pathologically; thus, these

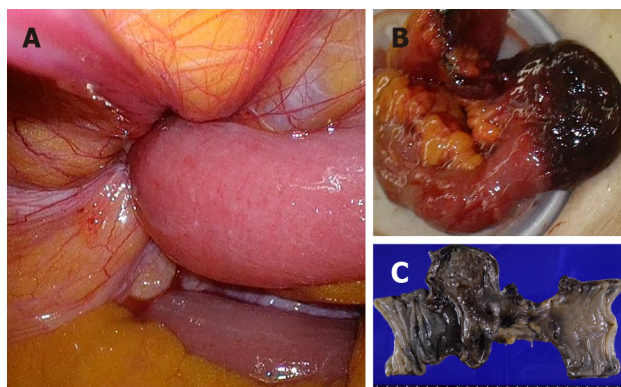


Figure 1 The necrotic ileum was resected, and the right femoral hernia was repaired using the McVay procedure. A: The ileum was incarcerated into the right femoral hernia; B: The incarcerated ileum became necrotic; C: The resected ileum showed hemorrhage necrosis over a 10 cm length.

nodules were diagnosed as IFBGs and were thought to be caused by food starch, similar to the previously reported case[5], particularly as no evidence of malignancy was identified either during or after the operations.

FBG is one type of non-infectious granulomatous reaction, characterized by the presence of a foreign body surrounded by granuloma formations in foreign body giant cells. FBGs have also been associated with granuloma formation due to an excessive immune response to foreign bodies, potentially related to allergic reactions and microbiological factors[11]. Intriguingly, in the present case, the IFBG expanded to the entire abdominal cavity at the time of the second operation, although the amount of enteric fluid that leaked from the perforation was limited to a small range and was localized within the lower abdominal cavity during the first operation. Because the lower abdominal cavity was rinsed after the resection of the incarcerated ileum during the first operation, the remaining food particles released from the small enteric fluid leak should have been minimized and at low concentrations, which suggested that each IFBG was either caused by an extremely minute food starch quantity or represented an allergic response, resulting in the accumulation of microbiological factors. Furthermore, the characteristic histological findings of FBG were very supportive of an IFBG diagnosis, especially during the operation. The misdiagnosis of IFBGs as malignancies can potentially lead to ineffective or unnecessary treatments. A previous case reported IFBGs mimicking peritoneal dissemination 3 mo after laparoscopic cholecystectomy, resulting in the wedge resection of the liver and transverse colon and omentectomy, and IFBGs were later diagnosed pathologically as likely due to bile or gallstone spillage[6]. As reported by Akita *et al*[5], intraoperative cytology and frozen sections are valuable for the rapid diagnosis of IFBGs. In the current case, these quick pathological examinations performed during the operation provided an important and powerful method for differentiating IFBGs from peritoneal dissemination.

The physiologic activation of histiocytes generally occurs within 24-48 h[12]; however, the time required for granulomatous formation resembling nodules remains unclear. In the current case, 4 mo was sufficient for the observed granulomatous formation. The percentage of granulomas observed during operations decreases gradually, from 37% if the previous operation was performed within 6 mo to 18% when the previous operation occurred more than 2 years prior[1]. Granulomas that resemble peritoneal dissemination can form within 2 mo, according to Akita *et al*[5], and this occurred within 4 mo in the current patient. Therefore, the interval between first and second operations also supports the diagnosis of IFBG.

CONCLUSION

In conclusion, multiple IFBGs caused by bowel perforations are associated with a very rare clinicopathological condition and can mimic peritoneal dissemination. A history of past operations and the interval between the current and past operations can be helpful for distinguishing between IFBGs and peritoneal dissemination, and intraoperative cytology and frozen sections are extremely valuable methods for the rapid diagnosis of IFBG, which can prevent misdiagnosis and avoid the use of ineffective or excessive treatments.

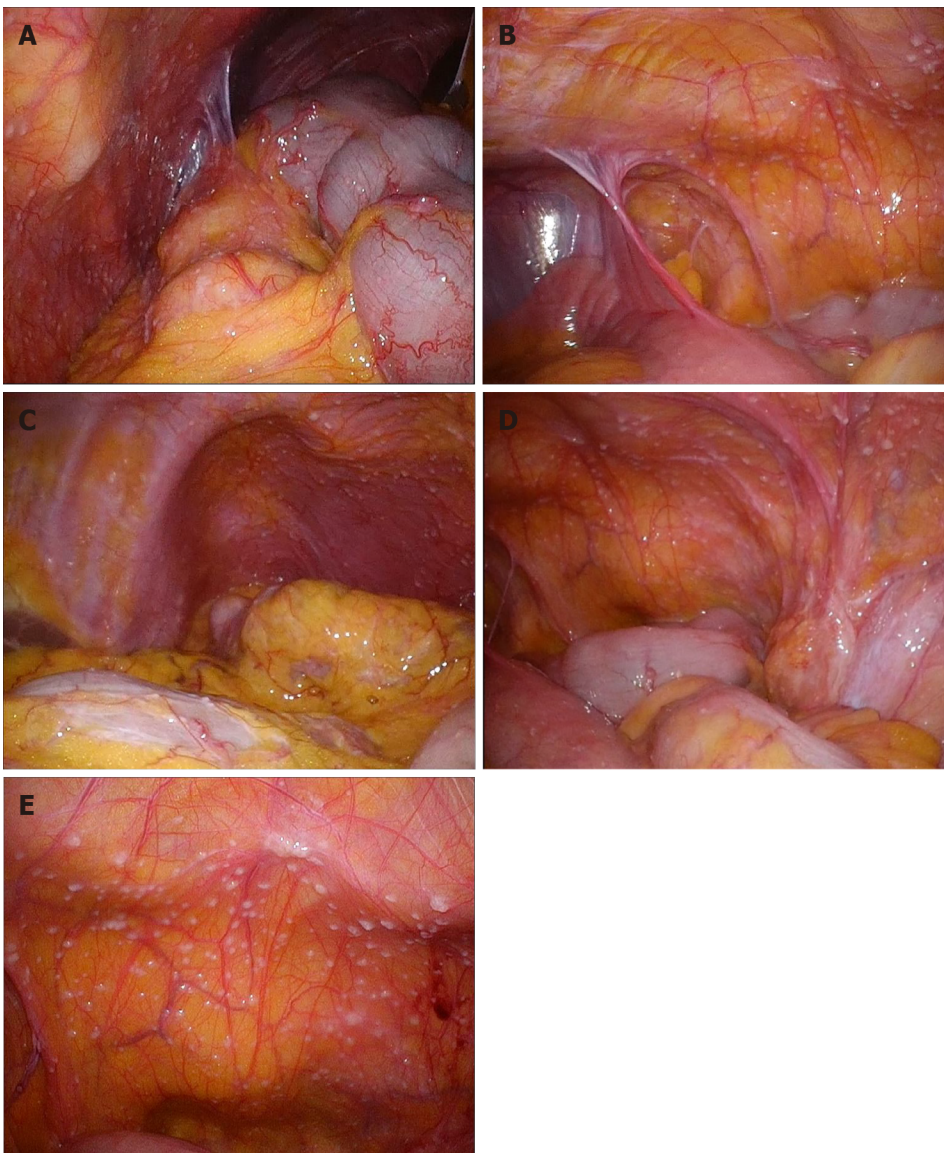


Figure 2 Multiple small white nodules mimicking peritoneal dissemination were observed throughout the entire abdominal cavity during the second operation. A: Right upper abdominal cavity; B: Right lower abdominal cavity; C: Left upper abdominal cavity; D: Left lower abdominal cavity; E: Back side of the bladder.

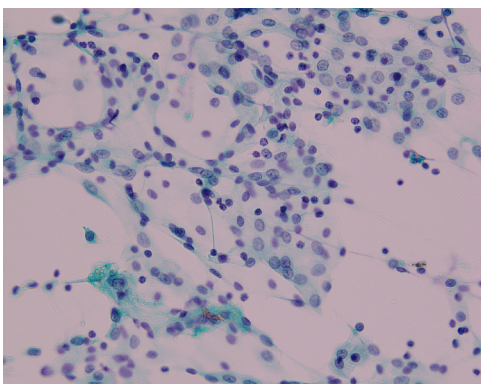


Figure 3 Papanicolaou stain of the peritoneal washing cytology of Douglas' pouch showed only inflammatory cells ($\times 40$).

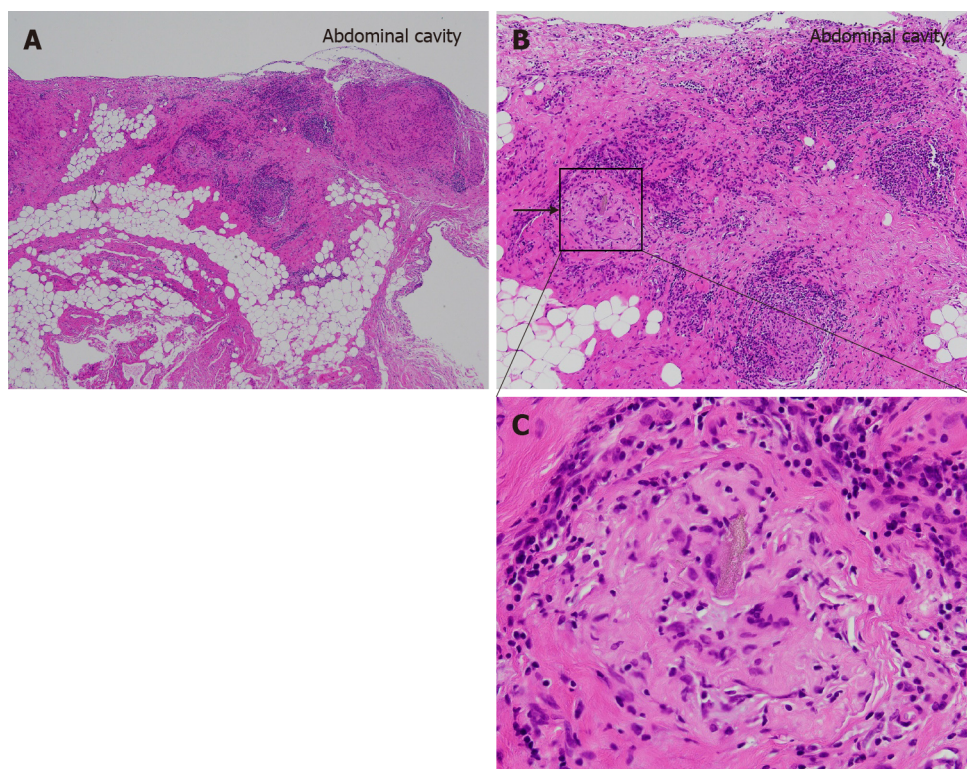


Figure 4 Pathological findings of the small white nodule. Hematoxylin and eosin stain of the nodule. A multinucleated giant cell with a foreign body (arrow) surrounded by monocytes, lymphocytes, and granuloma formations. A: $\times 40$; B: $\times 100$; C: $\times 200$.

REFERENCES

- 1 Luijendijk RW, de Lange DC, Wauters CC, Hop WC, Duron JJ, Pailler JL, Camprodon BR, Holmdahl L, van Geldorp HJ, Jeekel J. Foreign material in postoperative adhesions. *Ann Surg* 1996; **223**: 242-248 [PMID: 8604903 DOI: 10.1097/0000658-199603000-00003]
- 2 Wang H, Chen P. Surgicel® (oxidized regenerated cellulose) granuloma mimicking local recurrent gastrointestinal stromal tumor: A case report. *Oncol Lett* 2013; **5**: 1497-1500 [PMID: 23759739 DOI: 10.3892/ol.2013.1218]
- 3 Ezaki T, Okamura T, Yoshida Y, Kodate M, Shirakusa T, Tanimoto A, Hiratsuka R. Foreign-body granuloma mimicking an extrahepatically growing liver tumor: report of a case. *Surg Today* 1994; **24**: 829-832 [PMID: 7865961 DOI: 10.1007/bf01636316]
- 4 Yamamoto T, Hirohashi K, Iwasaki H, Kubo S, Tanaka Y, Yamasaki K, Koh M, Uenishi T, Ogawa M, Sakabe K, Tanaka S, Shuto T, Tanaka H. Pseudotumor of the omentum with a fishbone nucleus. *J Gastroenterol Hepatol* 2007; **22**: 597-600 [PMID: 17376061 DOI: 10.1111/j.1440-1746.2006.03353.x]
- 5 Akita H, Watanabe Y, Ishida H, Nakaguchi K, Okino T, Kabuto T. A foreign body granuloma after gastric perforation mimicking peritoneal dissemination of gastric cancer: report of a case. *Surg Today* 2009; **39**: 795-799 [PMID: 19779777 DOI: 10.1007/s00595-008-3937-x]
- 6 Jeong H, Lee HW, Jung HR, Hwang I, Kwon SY, Kang YN, Kim SP, Choe M. Bile Granuloma Mimicking Peritoneal Seeding: A Case Report. *J Pathol Transl Med* 2018; **52**: 339-343 [PMID: 30008197 DOI: 10.4132/jptm.2018.06.02]
- 7 Giercksky KE, Qvist H, Giercksky TC, Warloe T, Nesland JM. Multiple glove powder granulomas masquerading as peritoneal carcinomatosis. *J Am Coll Surg* 1994; **179**: 299-304 [PMID: 8069426]
- 8 Shan GD, Chen ZP, Xu YS, Liu XQ, Gao Y, Hu FL, Fang Y, Xu CF, Xu GQ. Gastric foreign body granuloma caused by an embedded fishbone: a case report. *World J Gastroenterol* 2014; **20**: 3388-3390 [PMID: 24696619 DOI: 10.3748/wjg.v20.i12.3388]
- 9 LEE CM Jr, LEHMAN EP. Experiments with nonirritating glove powder. *Surg Gynecol Obstet* 1947; **84**: 689-695 [PMID: 20292162]
- 10 Ellis H. The hazards of surgical glove dusting powders. *Surg Gynecol Obstet* 1990; **171**: 521-527 [PMID: 2244289]
- 11 Schmitt A, Volz A. Non-infectious granulomatous dermatoses. *J Dtsch Dermatol Ges* 2019; **17**: 518-533 [PMID: 31115996 DOI: 10.1111/ddg.13848]
- 12 Shah KK, Pritt BS, Alexander MP. Histopathologic review of granulomatous inflammation. *J Clin Tuberc Other Mycobact Dis* 2017; **7**: 1-12 [PMID: 31723695 DOI: 10.1016/j.jctube.2017.02.001]



Published by **Baishideng Publishing Group Inc**
7041 Koll Center Parkway, Suite 160, Pleasanton, CA 94566, USA

Telephone: +1-925-3991568

E-mail: bpgoffice@wjgnet.com

Help Desk: <https://www.f6publishing.com/helpdesk>

<https://www.wjgnet.com>

