

Pegylated liposomal doxorubicin/carboplatin combination in ovarian cancer, progressing on single-agent pegylated liposomal doxorubicin

Tal Grenader, Ora Rosengarten, Rut Isacson, Yevgeni Plotkin, Alberto Gabizon

Tal Grenader, Ora Rosengarten, Rut Isacson, Yevgeni Plotkin, Alberto Gabizon, Department of Oncology, Sha'are Zedek Medical Center, Jerusalem 91031, Israel

Author contributions: Grenader T and Gabizon A contributed to the conception and design; Grenader T, Gabizon A, Rosengarten O and Isacson R contributed to acquisition of data; Grenader T, Rosengarten O and Gabizon A contributed to analysis and interpretation of data; Grenader T, Rosengarten O, Isacson R, Gabizon A and Plotkin Y contributed to drafting and revising the article; Grenader T, Rosengarten O, Isacson R, Gabizon A and Plotkin Y approved the final version of publication.

Correspondence to: Tal Grenader, MD, Department of Oncology, Sha'are Zedek Medical Center, PO Box 3235, Jerusalem 91031, Israel. talgrenader65@hotmail.com

Telephone: +972-2-6666378 Fax: +972-2-6666731

Received: June 26, 2012 Revised: September 14, 2012

Accepted: September 28, 2012

Published online: October 10, 2012

Abstract

AIM: To assess the efficacy and safety of the combination of pegylated liposomal doxorubicin (PLD) and carboplatin in patients with recurrent epithelial ovarian carcinoma (ROC), following disease progression on single agent PLD.

METHODS: An analysis of the medical records of 10 patients with ROC, treated in our institution with a combination of PLD and carboplatin following progression on single-agent PLD therapy was performed. The median age was 59.1 years (range, 45 to 77 years). All diagnoses were histological-proven. Eight of the 10 patients were platinum-resistant. Following disease progression on single-agent PLD treatment, carboplatin area under the curve (AUC)-5 was added to PLD in all 10 patients. In order to assess disease status, Ca-125 was assessed before each PLD/carboplatin treatment. Relative changes in Ca-125 values were calculated, and response defined as a greater than 50% reduction in Ca-125 from baseline. Radiographic studies were re-evaluated and responses to therapy based on com-

puter tomography (CT) scans carried out on a regular basis every 2-3 mo in each patient. Statistical analysis was performed using SPSS (V19).

RESULTS: A median of 10 cycles (range, 2-26) of the carboplatin-PLD combination was given. Of the 10 treated patients, 6 had > 50% reduction in Ca-125 levels from baseline, 4 of these had a partial response according to Response Evaluation Criteria in Solid Tumors (RECIST) criteria, and the other 2 patients had no measurable disease. In a further 2 patients with a best response of disease stabilization and < 50% reduction of Ca-125 levels, one had progression of disease after 26 cycles, and the second progressed with brain metastases following 12 cycles. Seven of the eight patients who were platinum-resistant showed evidence of clinical benefit on carboplatin-PLD combination therapy; 5 of these had > 50% reduction in Ca-125 level, 4 also showed a partial response on CT scan. The treatment was generally well-tolerated by the patients.

CONCLUSION: Addition of carboplatin to PLD, after disease progression on single-agent PLD therapy, is both effective and safe in patients with ROC, even in those with Platinum-resistant disease.

© 2012 Baishideng. All rights reserved.

Key words: Pegylated liposomal doxorubicin; Carboplatin; Ovarian cancer chemotherapy; Platinum-resistant ovarian cancer; Platinum sensitive ovarian cancer

Peer reviewer: Xian-jun Fang, PhD, Associate Professor, Department of Biochemistry and Molecular Biology, Virginia Commonwealth University School of Medicine, 1101 E Marshall Street, Richmond, VA 23298, United States

Grenader T, Rosengarten O, Isacson R, Plotkin Y, Gabizon A. Pegylated liposomal doxorubicin (PLD)/carboplatin combination in ovarian cancer, progressing on single-agent PLD. *World J Clin Oncol* 2012; 3(10): 137-141 Available from: URL: <http://www.wjgnet.com>

INTRODUCTION

Upon clinical presentation, advanced-stage epithelial ovarian carcinoma is frequently chemotherapy-sensitive either before or after cytoreductive surgery, and response rates to platinum-based therapy are generally in excess of 80% with a pathological complete remission rate of around 25%^[1]. Regrettably, recurrences tend to occur in the majority of patients. Among the factors influencing choice of treatment in recurrent ovarian cancer (ROC), the potential for platinum sensitivity is one of the most important. In general, platinum sensitive ROC patients have response rates in excess of 50% and an overall survival (OS) of > 1 year, and platinum resistant patients tend to have response rates of less than 20% and an OS of < 12 mo^[1-3].

The cost-effectiveness of palliative chemotherapy for platinum-resistant ROC has been studied by Rocconi *et al.*^[4] and they concluded that the only cost-effective approach in these patients was best supportive care.

Combinations of chemotherapeutic agents have received considerable attention in ROC, and while slightly higher objective response rates and two to three months improvements in progression-free survival have been achieved, these regimes are associated with a higher level of toxicity, and no combination has yet been shown definitively to produce a survival benefit over single agent therapy.

Doxorubicin has single-agent activity in relapsed ovarian cancer^[5] and two meta-analyses of trials using platinum-based therapy^[6,7] suggested that the addition of anthracyclines increased overall survival. The 2nd International Collaborative Ovarian Neoplasm Study (ICON2), a randomised trial comparing single-agent carboplatin with a combination of cisplatin-doxorubicin-cyclophosphamide (CAP) did not confirm this suggestion and CAP resulted in a higher level of toxicity with no improvement in outcome^[8].

Pegylated liposomal doxorubicin (PLD), marketed under the names of Doxil or Caelyx, is a form of liposomal doxorubicin in which the liposomes are coated with the hydrophilic polymer, polyethylene glycol. This coating results in reduced uptake of the liposomes by the reticuloendothelial system and, consequently, in a substantially increased half-life in the circulation (50-60 h), and a modified, and generally less problematic toxicity profile^[9,10]. In particular, PLD appears to be associated with a lower incidence of myelosuppression, alopecia and cardiac side-effects than conventional doxorubicin, although a higher incidence of skin toxicity has been found. In addition, long-term therapy with PLD has been shown to be well-tolerated and without cumulative cardiotoxicity^[11]. The efficacy of single-agent PLD in ovarian cancer was demonstrated in a phase III study comparing PLD and topotecan (Hycamtin)^[12,13] as second-line

therapy. OS was superior with PLD (63 wk *vs* 60 wk, $P = 0.05$), particularly in platinum-sensitive patients (112 wk *vs* 77 wk, $P = 0.002$)^[13]. In addition, PLD had a more favorable safety profile and a less cumbersome administration schedule. Differences in OS in the subgroup of platinum-resistant patients did not reach statistical significance attesting to the limitations of single agent PLD in the treatment of this patient population.

Platinum agents are used in combination with doxorubicin in the treatment of a variety of solid tumors. These two agents have different mechanisms of action, show no cross resistance, and their toxicities do not overlap. Lyass *et al.*^[14] evaluated the feasibility of administering a combination of PLD and cisplatin and determined the maximum tolerated dose of the combination. They showed that PLD can be administered at its maximum tolerated dose (50 mg/m² every 4 wk) in combination with cisplatin at 60 mg/m² also every 4 wk, with no evidence of major overlapping toxicities. The incidence and severity of palmar-plantar erythrodysesthesia appeared to be diminished, in comparison with single-agent Doxil, and neutropenia became the dose limiting toxicity. They also demonstrated accelerated clearance of Doxil when administered after cisplatin.

Recently, a number of studies have attested to the value of combinations of PLD and carboplatin in terms of both efficacy and safety in patients with advanced ovarian cancer^[15]. The combination of carboplatin and PLD appears to be the optimal therapeutic approach currently available for platinum-sensitive ROC, and may be also a suitable alternative to carboplatin-paclitaxel for 1st line chemotherapy^[16]. Finding an effective line of chemotherapy for Platinum (Pt)-resistant patients may help improve their survival as suggested by results of Güth *et al.*^[17] who reported that Pt-resistant recurrent ovarian cancer patients, who received two or more therapy lines had comparable survival rate with Pt-sensitive patients. On the basis of these observations, the addition of carboplatin to PLD in patients with ovarian carcinoma may be a valuable approach to therapy deserving further investigation and an expanded use.

We therefore decided to review our own institutional experience with this combination in ROC patients who received prior standard treatment with single agent PLD.

MATERIALS AND METHODS

An analysis of the medical records of 10 patients with recurrent ovarian cancer, treated between January 2002 and December 2011 with a combination of PLD and carboplatin following progression on single-agent PLD therapy was performed. The median age was 59.1 years (range, 45 years to 77 years). All diagnoses were histological-proven. Eight of the 10 patients were Pt-resistant median TFI 3.5 mo. Two Pt-sensitive patients had TFI's of 7 mo and 8 mo respectively. The median TFI for the entire study group was 4.3 mo.

Of the 10 patients, 6 had not previously received any

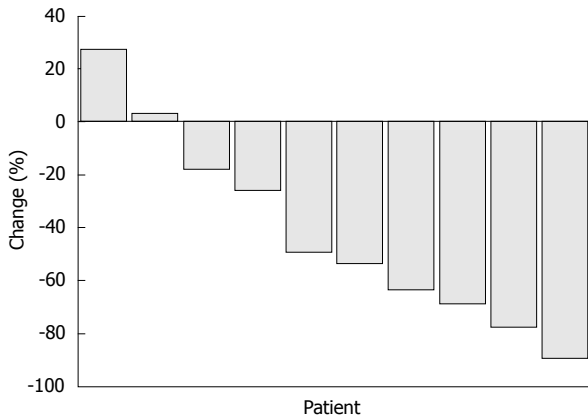


Figure 1 Waterfall plot showing maximum percent decrease in Ca-125 level.

chemotherapy for their recurrent disease, one patient had received topotecan, and 3 patients had received 3 lines of chemotherapy following their initial recurrence.

The initial dose of PLD per course was 40-50 mg/m² every 4 wk, with considered dose reduction to 35-45 mg/m² in the 2nd or 3rd cycle. This reduced dose was then maintained for the duration of treatment with PLD. In every case, the PLD was administered by intravenous infusion over a 1-2 h period. In all ten patients carboplatin area under the curve (AUC-5) every 4 wk was added, after disease progression on single-agent PLD treatment.

In order to assess disease status, Ca-125 was assessed before each PLD/carboplatin treatment. Relative changes in Ca-125 values were calculated, and response defined as a greater than 50% reduction in Ca-125 from baseline. Radiographic studies were re-evaluated and responses to therapy based on CT scans carried out on a regular basis every 2-3 mo in each patient. The responses were then classified according to the Response Evaluation Criteria in Solid Tumors (RECIST)^[18]. Data analysis was performed using SPSS (V19; Chicago, United States).

RESULTS

A median of 10 cycles was given (range, 2-26 cycles). Of the 10 treated patients, 6 had a greater than 50% reduction in Ca-125 from baseline (Figure 1). Four of these had a partial response according to RECIST, and 2 patients had no measurable disease. Two patients achieved stabilization of the disease as judged by CT scan and stable Ca-125 values. One of them had progression of disease after 26 cycles of treatment and the second progressed with brain metastases following 12 cycles of treatment. An additional patient had stable disease by CT scan, but elevation of the Ca-125 after 2 cycles of combination therapy, and another patient had progressive disease according to CT scan but with a stable Ca-125 after 2 cycles of combination therapy.

Seven of the eight patients who were Pt-resistant showed evidence of clinical benefit on the combination therapy (PLD plus carboplatin); five of these had a greater than 50% reduction in Ca-125 (four also showed a partial response on CT scan and one had no evidence of disease

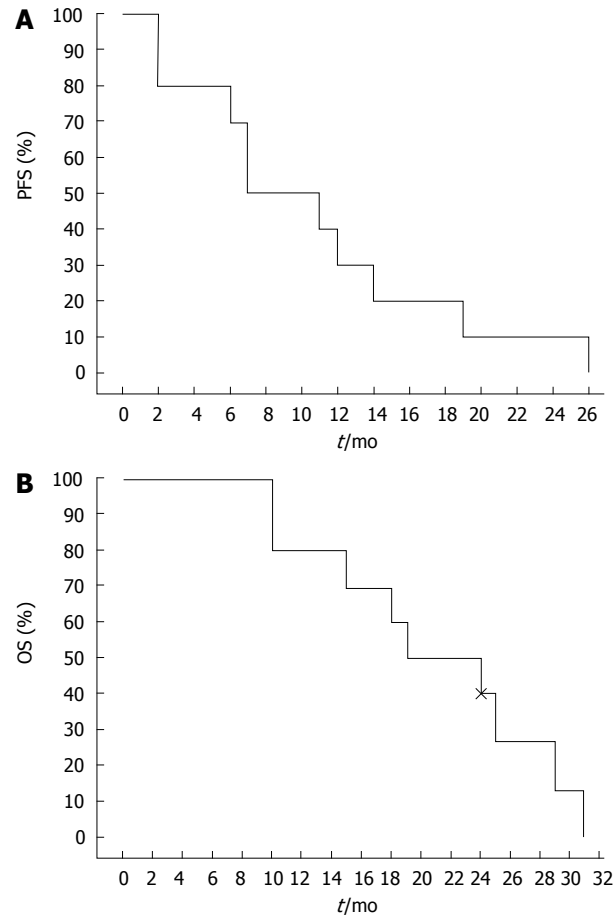


Figure 2 Kaplan-Meier survival curve for all patients over the period of follow-up. A: Kaplan-Meier progression-free survival curve. Median progression free survival (PFS) was 10.6 mo (95% CI: 5.91-15.3); B: Kaplan-Meier overall survival (OS) curve. Median overall survival was 20.93 mo (95% CI: 16.07-25.8).

on CT scan). Two patients had stable disease, and one patient had progressive disease.

Median progression free survival was 10.6 mo (95% CI: 5.91-15.3). Median overall survival was 20.93 mo (95% CI: 16.07-25.8) (Figure 2).

The treatment was generally well-tolerated by the patients. Toxicity data were analyzed retrospectively in a systematic fashion. The following toxic effects previously described with PLD and carboplatin were observed: mild to moderate myelosuppression (but no cases of neutropenic fever); 5 patients developed grade 1-2 thrombocytopenia; 3 patients developed neutropenia including 1 patient with grade 3 neutropenia. There was also mild to moderate skin toxicity and fatigue. There was no evidence of congestive heart failure or other cardiotoxic events. Left ventricular ejection fraction remain within normal limits despite the high cumulative doses in several patients. There were no hospitalizations or death related to treatment.

DISCUSSION

An attempt to demonstrate synergy between PLD and other therapeutic agents has resulted in the appearance

in the literature of a plethora of phase I studies, but relatively few phase II or phase III studies. PLD has been combined with a variety of agents in phase I studies, including ifosfamide, etoposide, platinum, topotecan (oral and intravenous), taxanes, vinorelbine, capecitabine and gemcitabine^[15]. Studies have proceeded to phase II with but a few combinations, however, these including taxanes, vinorelbine, topotecan, gemcitabine and platinum^[19-22].

The combination of PLD and carboplatin was the subject of at least three phase II studies. Two of these involved combination of PLD with carboplatin at a dose of AUC-5, with response rates of 52%-62%^[23,24]. A third study combined PLD with carboplatin at a dose of AUC-6, achieving the slightly higher response rate of 68%^[25]. Time to disease progression was similar in all three studies, and of the order of 9-12 mo. When compared to the low rate of response to single agent PLD (about 20%)^[12,13], the high response rate to the Carboplatin-PLD duplet suggests that this is a synergistic combination. These encouraging results in the area of ovarian cancer prompted evaluation of the combination in phase III studies.

PLD in combination with carboplatin as first-line therapy was studied in the Multicentre Italian Trials in Ovarian Cancer-2 (MITO-2)^[16]. In this study, both treatment groups received carboplatin at a dose of AUC-5. One group received, in addition, PLD at a dose of 30 mg/m² on a 21 d cycle, and the other, paclitaxel at a dose of 175 mg/m², also on a 21 d cycle. The efficacy was similar in the two groups, with similar response rates, progression free and overall survival, but different toxicity (less neurotoxicity and alopecia, but more hematologic adverse effects).

A further phase III study comparing the same two combinations is the Calypso trial, which involves patients with platinum-sensitive recurrent ovarian cancer. This study which is being carried out under the auspices of the Gynecologic Cancer Inter Group (GCIg), and the Gynecologic Oncology Group (GOG) protocol 182^[15], is still in progress in relation to the survival end-point. The Calypso trial was a non-inferiority trial in which the combination of PLD and carboplatin was compared with the standard regimen of paclitaxel and carboplatin in the second- or third-line treatment of Pt-sensitive epithelial ovarian cancer. All patients were previously exposed to a taxane. The combination of PLD and carboplatin was found superior with regard to progression-free survival (11.3 mo *vs* 9.4 mo, respectively)^[26]. Carboplatin-PLD had also a more favorable risk-benefit profile than paclitaxel/carboplatin combination.

These results support the contention that the carboplatin/PLD combination may prove to be a valuable alternative to carboplatin/paclitaxel in various settings, including the frontline treatment of ovarian cancer.

Our retrospective study has demonstrated that the addition of carboplatin to PLD in recurrent ovarian cancer which had progressed on single agent therapy PLD therapy, produced a partial response, with a prolonged

time to disease progression in 5 of the 8 platinum resistant patients, and sustained stable disease in the another two patients. These patients had a very low to nil probability of responding to single agent carboplatin. It is therefore possible that the platinum-PLD combination results in a synergistic therapeutic effect. While some toxic effects were noted, including myelosuppression, some skin toxicity and fatigue, the PLD and carboplatin combination was generally well-tolerated.

On the basis of this small retrospective survey, we conclude that addition of carboplatin to PLD is both effective and safe for long-term administration in patients with recurrent ovarian cancer which has progressed on single-agent PLD therapy. This approach, either as rescue therapy of patients on single agent PLD or as initial therapy in ROC patients, particularly in the Pt-resistant population, would thus appear to be a viable alternative to existing strategies.

COMMENTS

Background

Recurrences tend to occur in the majority of patients with advanced ovarian carcinoma. Among the factors influencing choice of treatment in recurrent ovarian cancer (ROC), the potential for platinum sensitivity is one of the most important. In general, platinum sensitive ROC patients have response rates in excess of 50% and an overall survival (OS) of > 1 year, and platinum resistant patients tend to have response rates of less than 20% and an OS of < 12 mo. A number of studies have attested to the value of combinations of pegylated liposomal doxorubicin (PLD) and carboplatin in terms of both efficacy and safety in patients with advanced ovarian cancer. The combination of carboplatin and PLD appears to be the optimal therapeutic approach currently available for platinum-sensitive ROC.

Innovations and breakthroughs

Common practice in ROC patients treated with single agent PLD is to discontinue PLD if disease progression occurs. This study shows that addition of carboplatin to those patients whether they are platinum-sensitive or platinum-refractory is in many cases an innovative and valid approach to achieve effective disease control.

Applications

The study results suggest that addition of carboplatin to PLD is both effective and safe for long-term administration in patients with ROC whose disease has progressed on single-agent PLD therapy. This approach, either as rescue therapy of patients on single agent PLD or as initial therapy in ROC patients, particularly in the platinum-resistant population, would thus appear to be a viable alternative to existing strategies.

Terminology

Platinum-free interval (PFI) is amount of time that has elapsed between the completion of first line platinum-based treatment and the detection of relapse. Ovarian cancer is considered platinum-sensitive when the PFI is six months or longer, and platinum-resistant when the PFI is less than six months. Pegylated liposomal doxorubicin, marketed under the names of Doxil or Caelyx, is a form of liposomal doxorubicin in which the liposomes are coated with the hydrophilic polymer, polyethylene glycol.

Peer review

The manuscript presented an interesting observation attesting the value of combination of PLD and carboplatin in treatment of relapsed ovarian cancer.

REFERENCES

- 1 Eisenhauer EA, Vermorken JB, van Glabbeke M. Predictors of response to subsequent chemotherapy in platinum pretreated ovarian cancer: a multivariate analysis of 704 patients [see comments]. *Ann Oncol* 1997; 8: 963-968
- 2 Ozols RF. Treatment of recurrent ovarian cancer: increasing

- options--"recurrent" results. *J Clin Oncol* 1997; **15**: 2177-2180
- 3 **Parmar MK**, Ledermann JA, Colombo N, du Bois A, Delaloye JF, Kristensen GB, Wheeler S, Swart AM, Qian W, Torri V, Floriani I, Jayson G, Lamont A, Tropé C. Paclitaxel plus platinum-based chemotherapy versus conventional platinum-based chemotherapy in women with relapsed ovarian cancer: the ICON4/AGO-OVAR-2.2 trial. *Lancet* 2003; **361**: 2099-2106
 - 4 **Rocconi RP**, Case AS, Straughn JM, Estes JM, Partridge EE. Role of chemotherapy for patients with recurrent platinum-resistant advanced epithelial ovarian cancer: A cost-effectiveness analysis. *Cancer* 2006; **107**: 536-543
 - 5 **Hubbard SM**, Bakes P, Young RC. Adriamycin therapy for advanced ovarian carcinoma recurrent after chemotherapy. *Cancer Treat Rep* 1978; **62**: 1375-1377
 - 6 Cyclophosphamide plus cisplatin versus cyclophosphamide, doxorubicin, and cisplatin chemotherapy of ovarian carcinoma: a meta-analysis. The Ovarian Cancer Meta-Analysis Project. *J Clin Oncol* 1991; **9**: 1668-1674
 - 7 **A'Hern RP**, Gore ME. Impact of doxorubicin on survival in advanced ovarian cancer. *J Clin Oncol* 1995; **13**: 726-732
 - 8 **ICON Collaborators**. ICON2: randomised trial of single-agent carboplatin against three-drug combination of CAP (cyclophosphamide, doxorubicin, and cisplatin) in women with ovarian cancer. International Collaborative Ovarian Neoplasm Study. *Lancet* 1998; **352**: 1571-1576
 - 9 **Gabizon AA**, Barenholz Y, Bialer M. Prolongation of the circulation time of doxorubicin encapsulated in liposomes containing a polyethylene glycol-derivatized phospholipid: pharmacokinetic studies in rodents and dogs. *Pharm Res* 1993; **10**: 703-708
 - 10 **Gabizon A**, Catane R, Uziely B, Kaufman B, Safra T, Cohen R, Martin F, Huang A, Barenholz Y. Prolonged circulation time and enhanced accumulation in malignant exudates of doxorubicin encapsulated in polyethylene-glycol coated liposomes. *Cancer Res* 1994; **54**: 987-992
 - 11 **Ewer MS**, Martin FJ, Henderson C, Shapiro CL, Benjamin RS, Gabizon AA. Cardiac safety of liposomal anthracyclines. *Semin Oncol* 2004; **31**: 161-181
 - 12 **Gordon AN**, Fleagle JT, Guthrie D, Parkin DE, Gore ME, Lacave AJ. Recurrent epithelial ovarian carcinoma: a randomized phase III study of pegylated liposomal doxorubicin versus topotecan. *J Clin Oncol* 2001; **19**: 3312-3322
 - 13 **Gordon AN**, Tonda M, Sun S, Rackoff W. Long-term survival advantage for women treated with pegylated liposomal doxorubicin compared with topotecan in a phase 3 randomized study of recurrent and refractory epithelial ovarian cancer. *Gynecol Oncol* 2004; **95**: 1-8
 - 14 **Lyass O**, Hubert A, Gabizon AA. Phase I study of doxil-cisplatin combination chemotherapy in patients with advanced malignancies. *Clin Cancer Res* 2001; **7**: 3040-3046
 - 15 **Strother R**, Matei D. Pegylated liposomal doxorubicin in ovarian cancer. *Ther Clin Risk Manag* 2009; **5**: 639-650
 - 16 **Pignata S**, Scambia G, Ferrandina G, Savarese A, Sorio R, Breda E, Gebbia V, Musso P, Frigerio L, Del Medico P, Lombardi AV, Febbraro A, Scollo P, Ferro A, Tamberi S, Brandes A, Ravaoli A, Valerio MR, Aitini E, Natale D, Scaltriti L, Greggi S, Pisano C, Lorusso D, Salutati V, Legge F, Di Maio M, Morabito A, Gallo C, Perrone F. Carboplatin plus paclitaxel versus carboplatin plus pegylated liposomal doxorubicin as first-line treatment for patients with ovarian cancer: the MITO-2 randomized phase III trial. *J Clin Oncol* 2011; **29**: 3628-3635
 - 17 **Güth U**, Huang DJ, Schötzau A, Wight E. Is the current concept of recurrent ovarian carcinoma as a chronic disease also applicable in platinum resistant patients? *Arch Gynecol Obstet* 2010; **281**: 339-344
 - 18 **Therasse P**, Arbuck SG, Eisenhauer EA, Wanders J, Kaplan RS, Rubinstein L, Verweij J, Van Glabbeke M, van Oosterom AT, Christian MC, Gwyther SG. New guidelines to evaluate the response to treatment in solid tumors. European Organization for Research and Treatment of Cancer, National Cancer Institute of the United States, National Cancer Institute of Canada. *J Natl Cancer Inst* 2000; **92**: 205-216
 - 19 **D'Agostino G**, Ferrandina G, Ludovisi M, Testa A, Lorusso D, Gbaguidi N, Breda E, Mancuso S, Scambia G. Phase II study of liposomal doxorubicin and gemcitabine in the salvage treatment of ovarian cancer. *Br J Cancer* 2003; **89**: 1180-1184
 - 20 **Nicoletto MO**, Falci C, Pianalto D, Artioli G, Azzoni P, De Masi G, Ferrazzi E, Perin A, Donach M, Zoli W. Phase II study of pegylated liposomal doxorubicin and oxaliplatin in relapsed advanced ovarian cancer. *Gynecol Oncol* 2006; **100**: 318-323
 - 21 **Katsaros D**, Oletti MV, Rigault de la Longrais IA, Ferrero A, Celano A, Fracchioli S, Donadio M, Passera R, Cattell L, Bumma C. Clinical and pharmacokinetic phase II study of pegylated liposomal doxorubicin and vinorelbine in heavily pretreated recurrent ovarian carcinoma. *Ann Oncol* 2005; **16**: 300-306
 - 22 **Verhaar-Langereis M**, Karakus A, van Eijkeren M, Voest E, Witteveen E. Phase II study of the combination of pegylated liposomal doxorubicin and topotecan in platinum-resistant ovarian cancer. *Int J Gynecol Cancer* 2006; **16**: 65-70
 - 23 **Ferrero JM**, Weber B, Geay JF, Lepille D, Orfeuvre H, Combe M, Mayer F, Leduc B, Bourgeois H, Paraiso D, Pujade-Lauraine E. Second-line chemotherapy with pegylated liposomal doxorubicin and carboplatin is highly effective in patients with advanced ovarian cancer in late relapse: a GINECO phase II trial. *Ann Oncol* 2007; **18**: 263-268
 - 24 **Alberts DS**, Liu PY, Wilczynski SP, Clouser MC, Lopez AM, Michelin DP, Lanzotti VJ, Markman M. Randomized trial of pegylated liposomal doxorubicin (PLD) plus carboplatin versus carboplatin in platinum-sensitive (PS) patients with recurrent epithelial ovarian or peritoneal carcinoma after failure of initial platinum-based chemotherapy (Southwest Oncology Group Protocol S0200). *Gynecol Oncol* 2008; **108**: 90-94
 - 25 **du Bois A**, Pfisterer J, Burchardi N, Loibl S, Huober J, Wimberger P, Burges A, Stähle A, Jackisch C, Kölbl H. Combination therapy with pegylated liposomal doxorubicin and carboplatin in gynecologic malignancies: a prospective phase II study of the Arbeitsgemeinschaft Gynäkologische Onkologie Studiengruppe Ovarialkarzinom (AGO-OVAR) and Kommission Uterus (AGO-K-Ut). *Gynecol Oncol* 2007; **107**: 518-525
 - 26 **Pujade-Lauraine E**, Wagner U, Aavall-Lundqvist E, Gebiski V, Heywood M, Vasey PA, Volgger B, Vergote I, Pignata S, Ferrero A, Sehouli J, Lortholary A, Kristensen G, Jackisch C, Joly F, Brown C, Le Fur N, du Bois A. Pegylated liposomal Doxorubicin and Carboplatin compared with Paclitaxel and Carboplatin for patients with platinum-sensitive ovarian cancer in late relapse. *J Clin Oncol* 2010; **28**: 3323-3329

S-Editor Jiang L L-Editor A E-Editor Lu YJ