

## WJCO 5<sup>th</sup> Anniversary Special Issues (2): Breast cancer

# Current aspects of therapeutic reduction mammoplasty for immediate early breast cancer management: An update

Alexandre Mendonça Munhoz, Eduardo Montag, Rolf Gemperli

Alexandre Mendonça Munhoz, Division of Plastic Surgery, Hospital Sirio, Libanês, São Paulo 01239-040, Brazil  
Eduardo Montag, Breast Reconstruction Group, University of São Paulo School of Medicine, São Paulo 01239-040, Brazil  
Rolf Gemperli, Department of Plastic Surgery, University of São Paulo School of Medicine, São Paulo 01239-040, Brazil

Author contributions: Munhoz AM contributed to the data collection, analysis and interpretation, and wrote the paper; Montag E contributed to the data collection and analysis; Gemperli R contributed to the data analysis and interpretation.

Correspondence to: Alexandre Mendonça Munhoz, MD, Professor, Division of Plastic Surgery, Hospital Sirio, Libanês, Rua Mato Grosso, 306 cj.1706 Higienópolis, São Paulo 01239-040, Brazil. alexandremunhoz@hotmail.com

Telephone: +55-11-32551760 Fax: +55-11-32551760

Received: September 30, 2013 Revised: November 27, 2013

Accepted: December 17, 2013

Published online: February 10, 2014

it permits wider excision of the tumor, with a superior mean volume of the specimen and potentially reduces the incidence of margin involvement. Regardless of the fact that there is no consensus concerning the best TRM technique, the criteria is determined by the surgeon's experience, the extent/location of glandular tissue resection and the size of the defect in relation to the size of the remaining breast. The main advantages of the technique utilized should include reproducibility, low interference with the oncological treatment and long-term results. The success of the procedure depends on patient selection, coordinated planning and careful intra-operative management.

© 2014 Baishideng Publishing Group Co., Limited. All rights reserved.

**Key words:** Breast reconstruction; Conservative breast surgery; Partial mastectomy; Oncoplastic; Reduction mammoplasty; Outcome; Complications

## Abstract

Breast-conservation surgery (BCS) is established as a safe surgical treatment for most patients with early breast cancer. Recently, advances in oncoplastic techniques are capable of preserving the breast form and quality of life. Although most BCS defects can be managed with primary closure, the aesthetic outcome may be unpredictable. Among technical options, therapeutic reduction mammoplasty (TRM) remains a useful procedure since the BCS defect can be repaired and the preoperative appearance can be improved, resulting in more proportional breasts. As a consequence of rich breast tissue vascularization, the greater part of reduction techniques have based their planning on preserving the pedicle of the nipple-areola complex after tumor removal. Reliable circulation and improvement of a conical shape to the breast are commonly described in TRM reconstructions. With an immediate approach, the surgical process is smooth since both procedures can be carried out in one operative setting. Additionally,

**Core tip:** Recently, advances in oncoplastic techniques are capable of preserving the breast form and quality of life. Among technical options, therapeutic reduction mammoplasty remains a useful procedure since the breast-conservation surgery defect can be repaired and the preoperative appearance can be improved. Additionally, it permits wider excision of the tumor, with a superior mean volume of the specimen and potentially reduces the incidence of margin involvement. The main advantages of the technique utilized should include reproducibility, low interference with the oncological treatment and long-term results. The success of the procedure depends on patient selection, coordinated planning and careful intra-operative management.

Munhoz AM, Montag E, Gemperli R. Current aspects of therapeutic reduction mammoplasty for immediate early breast cancer management: An update. *World J Clin Oncol* 2013; 5(1): 1-18

## INTRODUCTION

Breast-conservation surgery (BCS) is an important component of early breast cancer treatment, with a survival outcome comparable to that of radical procedures<sup>[1]</sup>. In fact, the long-term survival of BCS with radiation is not statistically different when compared with mastectomy in patients with Stage I or II breast cancer<sup>[2]</sup>.

BCS with concomitant reconstruction has been developed over the past decades. In essence defined as oncoplastic surgery, the procedure refers to a number of surgical techniques by which breast tumors are resected while the remaining glandular tissue is transposed to achieve a satisfactory aesthetic outcome<sup>[2-4]</sup>. A variety of such techniques has been described, including volume replacement by local glandular flaps and breast reshaping by therapeutic reduction mammoplasty (TRM) or regional/distant flaps<sup>[5-12]</sup>.

In spite of the acceptance that most BCS defects can be managed with primary closure, some lesions are complex to resect without the risk of aesthetic deformity. In fact, favorable aesthetic outcome can be difficult to achieve and an example of this is in patients with large breast tumors in relation to breast size<sup>[2,6,11]</sup>. In addition, radiation can also have a negative effect on the glandular and skin tissue. In our experience, the main clinical aspects are related to skin pigmentation changes, telangiectasia and skin fibrosis<sup>[11,13-17]</sup>.

Recently, clinical experience with oncoplastic surgery has demonstrated the freedom to perform wider tumor excisions, potentially reducing margin involvement. Additionally, another benefit is the possibility of allowing the excision of larger tumors without compromising cosmetic outcome<sup>[6-18]</sup>. Thus, by means of customized techniques the surgeon ensures that oncological principles are not jeopardized while meeting the needs of the patient from an aesthetic point of view<sup>[3]</sup>.

In general, the oncoplastic procedures are related to volume displacement or replacement techniques and sometimes include contralateral breast surgery. Regardless of the fact that there is no consensus concerning the best approach, the criteria are determined by the surgeon's experience and the size of the defect in relation to the size of the remaining breast<sup>[11]</sup>. The main advantages of the technique utilized should include low interference with the oncological treatment, reproducibility and long-term results. Probably, all these objectives are not achieved by any single procedure and each technique has advantages and limitations<sup>[11]</sup>.

## LITERATURE SEARCH/DATA EXTRACTION

Two independent reviewers evaluated titles and abstracts

without language restrictions to assess eligibility in terms of outcome measures and study design. A literature search was carried out up to August 2013 to identify studies of breast cancer patients treated with oncoplastic surgery procedures and to determine if any use of mammoplasty techniques was recorded. In an attempt to minimize the omission of potentially relevant clinical studies, we also reviewed the reference lists of included studies and relevant reviews for additional eligible articles. Potential studies were identified by searches of Medline and PubMed databases using the terms "oncoplastic breast surgery", "conservative breast surgery reconstruction", "partial mastectomy reconstruction", "therapeutic mammoplasty" and "reduction mammoplasty". Studies identified were screened for those that focused on techniques, surgical and oncological outcomes after therapeutic mammoplasty reconstruction and references of each study were further investigated to include all relevant published data.

A total of 1382 potential articles were identified during the primary evaluation. After appraisal of the inclusion criteria, 311 articles were identified for potential inclusion and reviewed in detail. A total of 226 articles were excluded, leaving 77 articles to form the basis of this review.

## THERAPEUTIC REDUCTION MAMMAPLASTY

Among the main technical options, TRM remains a useful procedure. Usually, the application of TRM involves resection of the tumor and remodeling the breast using an aesthetic breast reduction technique. As a consequence of rich breast tissue vascularization, the greater part of TRM has based their planning on preserving the pedicle of the nipple-areola complex (NAC) after tumor removal. Usually, the procedure is adequate for patients with moderate/larger breasts requiring excision of significant volumes of tissue and contralateral symmetrization. With TRM, the BCS defect can be repaired and the preoperative appearance can be improved, resulting in more proportional breasts<sup>[15-17]</sup>. In addition, the technique reduces the difficulty of providing radiation therapy to the remaining breast tissues with acceptably low complication rates<sup>[19-21]</sup>. In terms of local control and oncological outcome, the added removal of a substantial volume of breast tissue could add a significant amount of safety in terms of surgical margins<sup>[22,23]</sup>.

## INDICATIONS OF TRM: TIMING, TECHNIQUES

### Timing of reconstruction

With immediate reconstruction, the surgical process is smooth since BCS and TRM can be carried out in one operative setting. Additionally, because there is no scar and fibrosis tissue, breast reshaping is easier and the aes-

thetic is improved<sup>[6,8,9,11,12,24-27]</sup>. In fact, Kronowitz *et al.*<sup>[9]</sup> observed that immediate repair is preferable to being delayed because of a decreased incidence of complications. In our previous experience utilizing TRM for BCS reconstruction, we observed that our post-radiation complication rate (delayed BCS reconstruction) was higher than that expected for TRM without radiotherapy (immediate BCS reconstruction)<sup>[24]</sup>. This finding is similar to previous studies that suggest that delayed BCS reconstruction has a significantly higher complication rate compared with immediate procedures<sup>[8,9]</sup>.

In terms of oncological benefits and adjuvant treatment, immediate reconstruction can be advantageous. Some clinical series have observed that patients with large volume breasts present with more radiation related complications than patients with normal volume breasts<sup>[19-21]</sup>. Additionally, some studies observed that there is an increased fat content in large breasts and the fatty tissue results in more fibrosis after radiotherapy than glandular tissue<sup>[21]</sup>. Thus, TRM can increase the eligibility of large-breasted patients for BCS since it can reduce the difficulty of providing radiation therapy<sup>[15-17,19,23]</sup>. Gray *et al.*<sup>[21]</sup>, in a series of 257 patients, found that there was more retraction and asymmetry in the large-breasted *vs* the small-breasted group. Usually, these deformities are complicated to manage and habitually necessitate secondary reconstruction with autologous tissue.

Another aspect is the possibility of accomplishing a negative resection margin. In fact, the immediate reconstruction with TRM allows for wider local tumor excision, potentially reducing the incidence of margin involvement<sup>[15-17,22,23]</sup>. Kaur *et al.*<sup>[22]</sup> compared patients submitted to oncoplastic procedures and to BCS. The immediate reconstruction permitted larger resections, with a superior mean volume of the specimen and negative margins.

In spite of the benefits, the immediate TRM reconstruction presents some negative aspects. The surgical time can be lengthened and require specialist training to learn and properly apply these procedures<sup>[2,3,15]</sup>. Another point is related to the postoperative breast volume and shape<sup>[26]</sup>. In fact, in some cases the final contour of the breast cannot be predicted at the time of the BCS and although the aesthetic result can be adequate, the outcome of the radiated breast is sometimes less favorable than the nonradiated breast<sup>[5-8,23,26]</sup>. Despite there being no consensus, in delayed reconstruction, the plastic surgeon could wait until the postoperative changes in the deformed breast stabilize.

Another important point is related to the postoperative recovery. In theory, some complications of the immediate TRM reconstructions can unfavorably defer the adjuvant therapy. With delayed oncoplastic reconstruction, operative time is shortened and the surgical process is less extensive than an immediate one. Additionally, depending on the technique of reconstruction utilized, surgical techniques can be complicated and lengthy, and

potentially associated with relatively high postoperative complication rates. In fact, some surgeons are concerned that immediate application of TRM may delay adjuvant systemic and locoregional treatment and compromise prognosis. However, our previous experience with TRM<sup>[11,14-17]</sup> and that of others<sup>[8,18,23]</sup> has shown that an immediate approach does not compromise the start of radio and chemotherapy in the overall treatment of breast cancer. Besides the evidence in the literature, it has been our impression that nothing suggests that immediate application of TRM is not safe enough in terms of starting adjuvant therapy. In fact, Kahn *et al.*<sup>[28]</sup> in a series of 169 patients submitted to BCS provide evidence that immediate reconstruction does not lead to a delay in the commencement of adjuvant chemotherapy when compared to three adequate control groups from the same institution and time periods.

### Breast defect definition

BCS reconstructive planning should include the breast volume, tumor location, the extent of glandular tissue resected, and chiefly address individual reconstructive requirements<sup>[11]</sup>. Evaluation of BCS reconstruction must subsequently consider these important points and only then should the proper TRM procedure or a combination of procedures be chosen<sup>[2,11]</sup>. It has been our experience that each BCS defect has its own special reconstructive necessities varying expectations for aesthetic outcome. On the basis of our 15 years of experience, it is possible to identify trends in types of breast defects and to develop an algorithm for immediate BCS reconstruction on the basis of the initial breast volume, the extent/location of glandular tissue resection and the remaining available breast tissue<sup>[11]</sup>. To make possible development of a BCS reconstructive algorithm, immediate partial breast defects are classified into one of three types (Figure 1).

**Type I :** Defects include tissue resection in a smaller breast without ptosis. Type I A defects involve minimal defects that do not cause volume alteration/distortion in the breast shape and the tissue resected is less than 10%-15% of the total breast volume. Type I B defects involve moderate defects that do originate from moderate volume alteration/distortion in the breast shape or symmetry and the tissue resected is between 15% and 40% of the total volume. Usually, the skin above the tumor is resected with the tumor. Type I C defects involve large defects that do cause significant volume alteration/distortion in the breast shape and symmetry and the tissue resected is more than 40% of the total breast volume.

**Type II :** This group includes tissue resection in medium sized breasts with/without ptosis. Type II A involves small defects that do not cause enough volume alteration/distortion in the breast shape. Type II B defects involve moderate defects that cause minor/moderate volume alteration in the breast shape. Type II C defects

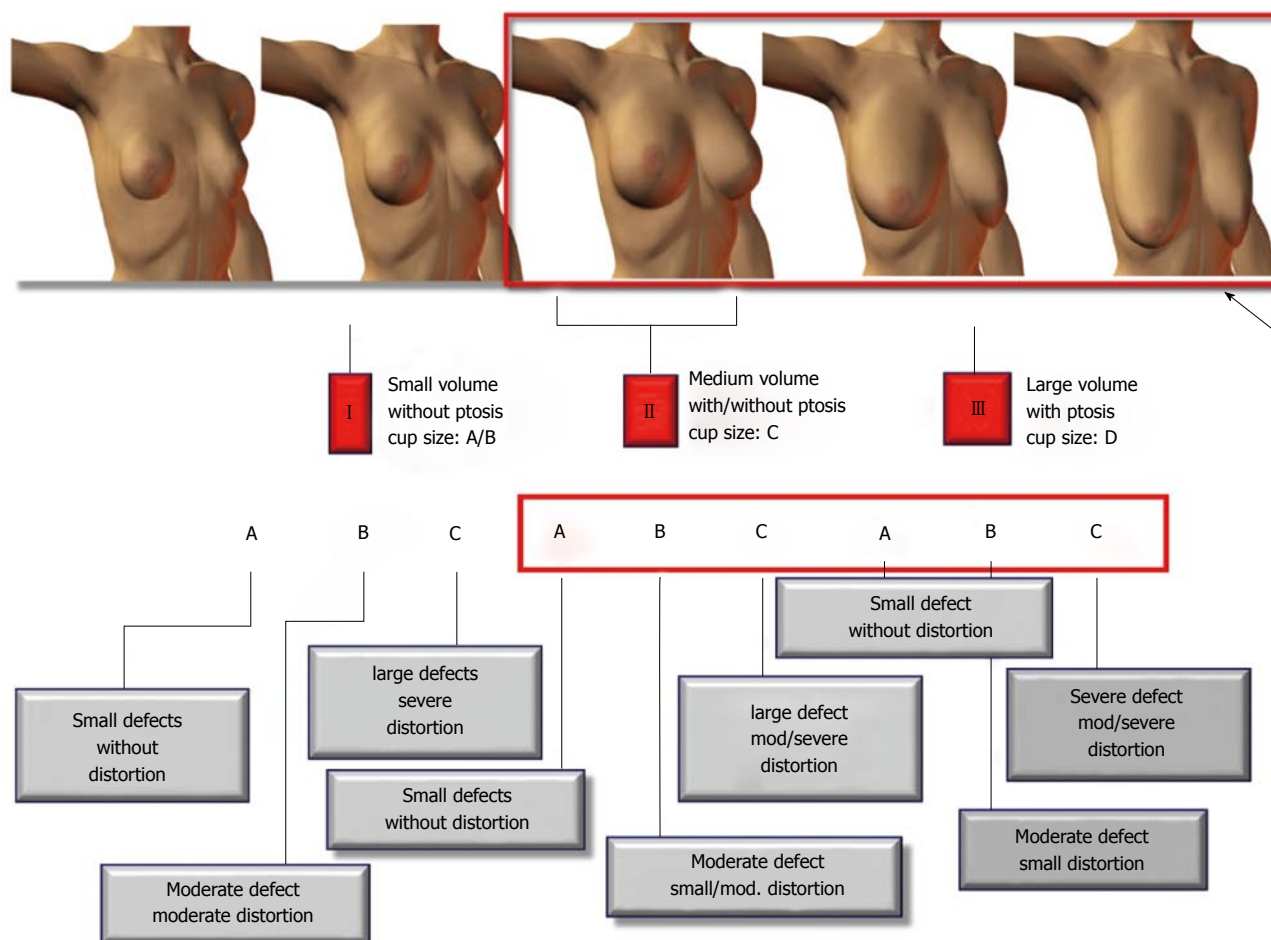


Figure 1 Algorithm for immediate conservative breast surgery reconstruction based on the type of breast and extent of defect.

involve large defects that cause moderate/large volume variations in the breast shape and symmetry.

**Type III:** This group includes tissue resection in large sized breasts with ptosis. Type IIIA involves small defects that do not cause enough aesthetic deformity. Type IIIB defects involve moderate defects that originate from minor/moderate volume alterations in the breast shape or symmetry. Type IIIC defects involve large defects that cause significant volume alteration in the breast.

### Surgical techniques and the role of TRM

BCS defects can be scored and classified according to the proposed classification<sup>[11]</sup>. In our experience, the majority of reconstruction techniques are performed with one of six surgical options: breast tissue advancement flaps (BAF), lateral thoracodorsal flap (LTDF), TRM (bilateral mastopexy and bilateral reduction mammoplasty), latissimus dorsi myocutaneous flap (LDMF) and abdominal flaps.

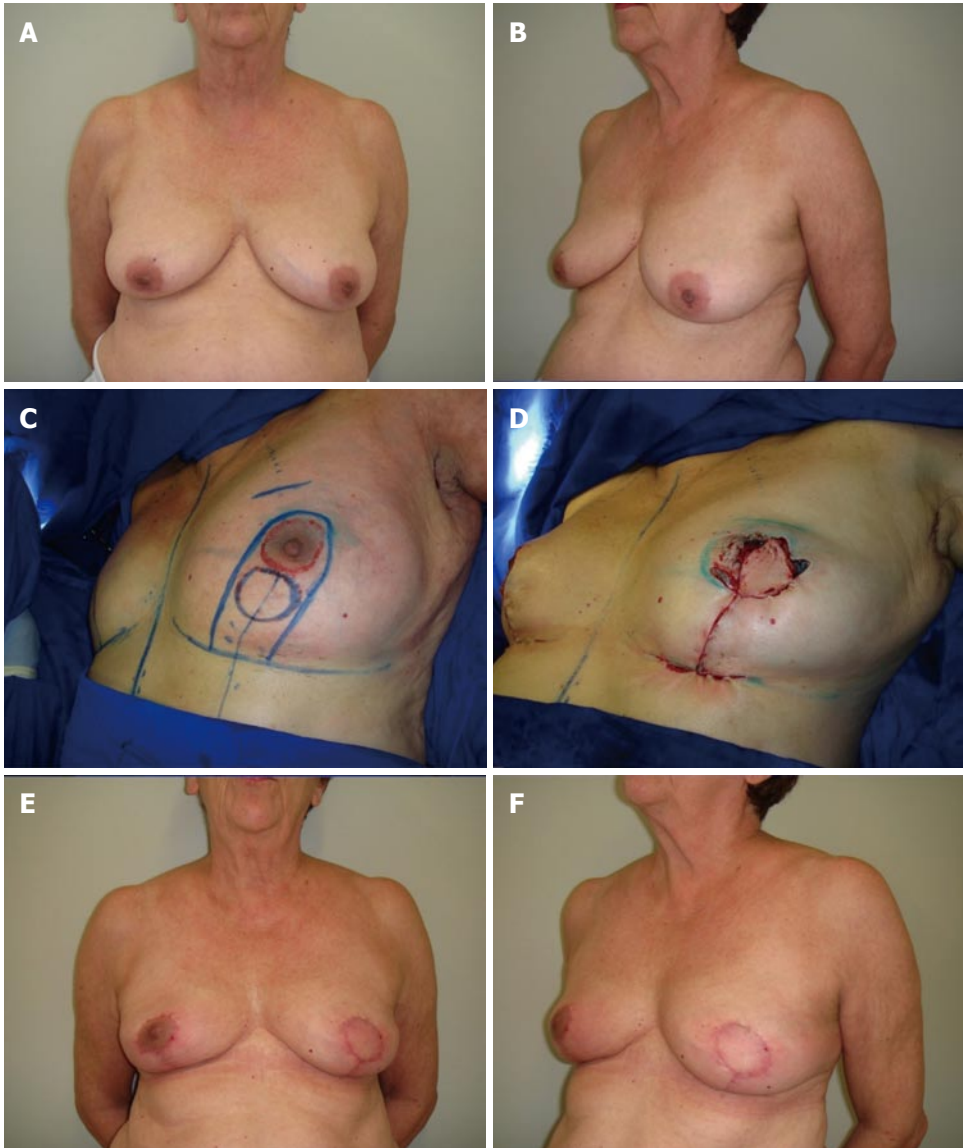
Habitually, TRM may be indicated if the patient has a moderate/large breast volume or if there is breast ptosis. Patient selection should be primarily limited to those who desire breast reduction and those who have at least moderately sized breasts with a defect that is suspected to be at least small and moderate in size (Figure 1). Surgi-

cal planning should include breast characteristics, extent of breast tissue resected, and chiefly address individual reconstructive requirements. Additionally, the decision is usually determined by the surgeon's preferences and the size of the defect in relation to the size of the remaining breast. In fact, it is important to identify trends in types of breast defects on the basis of the initial breast volume, the extent/location of glandular tissue resection and the remaining available breast tissue.

**Type I A, II A and III A:** Defects are usually repaired with BAF in which the defect created is usually spherical or rectangular. The breast tissue is advanced along the chest wall or beneath the breast skin flap to fill the tumor defect. Usually, in these patients no contralateral breast procedure is performed.

**Type I B:** In patients with lateral defects, the LTDF is performed. Previously described elsewhere<sup>[14]</sup>, this local flap is planned as a wedge-shaped triangle located on the lateral aspect of the thorax. Although additional scars are created, they will be placed in the lateral region. The defect margins are sutured to the margins of the flap and the donor site is closed primarily. In patients with central and medial tumors, the LDMF can be utilized<sup>[11,13]</sup>. The flap is designed into a horizontal position and the width





**Figure 2** A 62-year-old patient with invasive ductal carcinoma (1.7 cm) of the left breast. The patient underwent a left central quadrantectomy and sentinel lymph node biopsy, immediately followed by a therapeutic reduction mammoplasty Inferior Pedicle Technique reconstruction (A-B, above left and right); A total of 78 g was removed from the left breast (C-D, center left and right); One year postoperative appearance after the radiotherapy (E-F, below left and right).

of the paddle is measured according to the skin previously resected.

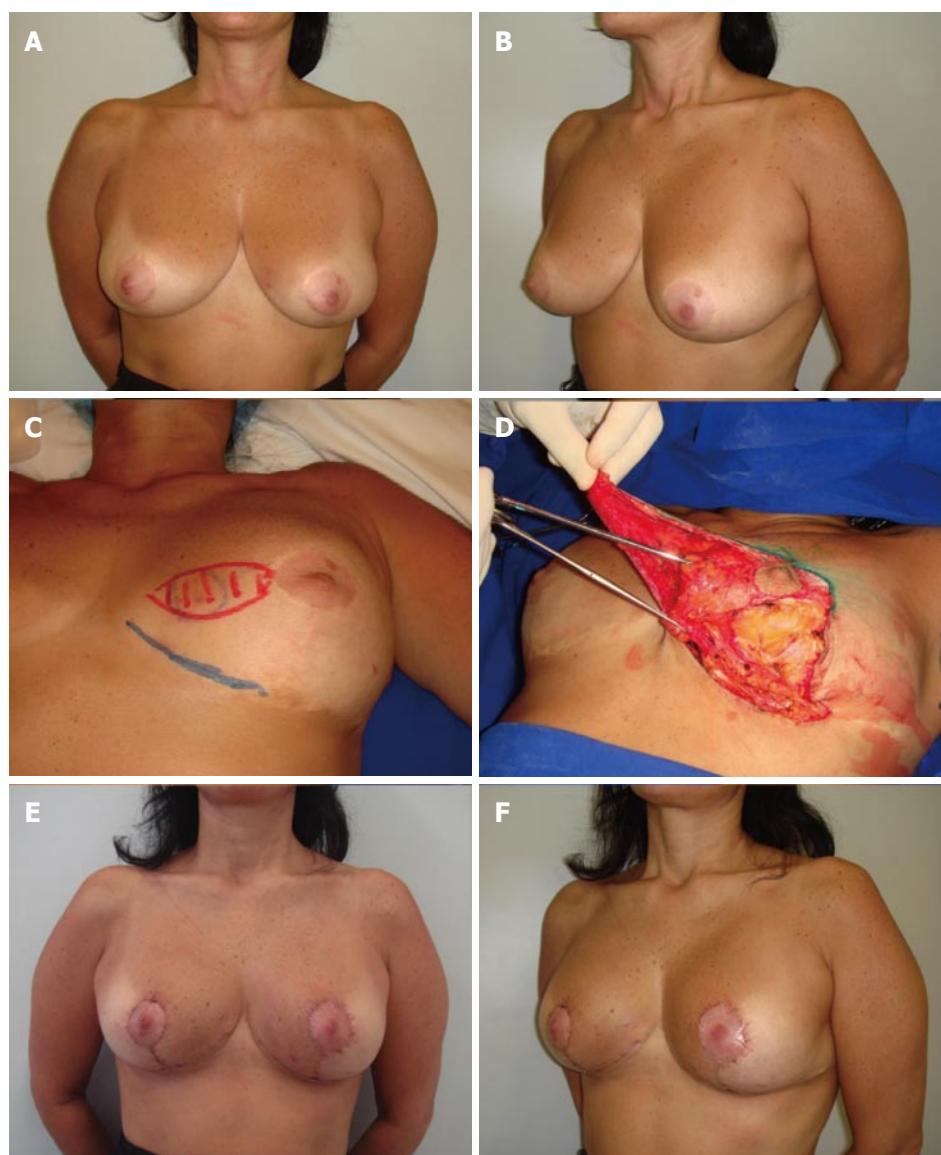
**Type I C:** Defects are converted to a skin-sparing mastectomy (SSM) and reconstructed with an appropriate technique. In patients with enough abdominal tissue, an abdominal flap (pedicled/free TRAM or DIEP) can be an option according to the surgeon's preference. In patients without an adequate abdomen, a LDMF associated with an implant can be performed.

**Type II B:** Defects are frequently reconstructed with TRM techniques when there is sufficient breast tissue to perform the reconstruction (Figure 2).

**Type II C:** Defects are analyzed individually according to the size of the breast defect in relation to the remain-

ing breast tissue available. For this purpose, the patient is positioned upright to assess the amount of the remaining glandular tissue. Thus, type II C can be subclassified into favorable and unfavorable defects. If there is enough tissue to perform an adequate breast mound shaping, the defect is classified as favorable. For the lateral defects, the extended LTDF is most commonly employed. In patients with central and medial defects, the extended LDMF can be utilized<sup>[13]</sup>. Conversely, if not enough breast tissue remains, the breast defect is classified as unfavorable and a SSM and total reconstruction is indicated.

**Type III B:** Defects are frequently reconstructed with TRM techniques when the patient presents with large volume breasts and there is a sufficient amount of breast tissue. The most favorable tumor location is in the lower breast pole where a conventional superior pedicle or



**Figure 3** A 48-year-old patient with invasive ductal carcinoma (3.2 cm) of the inferior-medial quadrant of the left breast. The patient underwent a left inferior-medial quadrantectomy and sentinel lymph node biopsy, immediately followed by a therapeutic reduction mammoplasty Superior-Lateral Pedicle Technique reconstruction (A-B, above left and right); A total of 125 g was removed from the left breast (C-D, center left and right); Six months postoperative appearance after the radiotherapy with a very good outcome (E-F, below left and right).

superior-medial technique can be utilized<sup>[15,16]</sup>. In patients with central tumors, an inferior pedicle is used to carry parenchyma and skin into the central defect<sup>[17]</sup> (Figure 3).

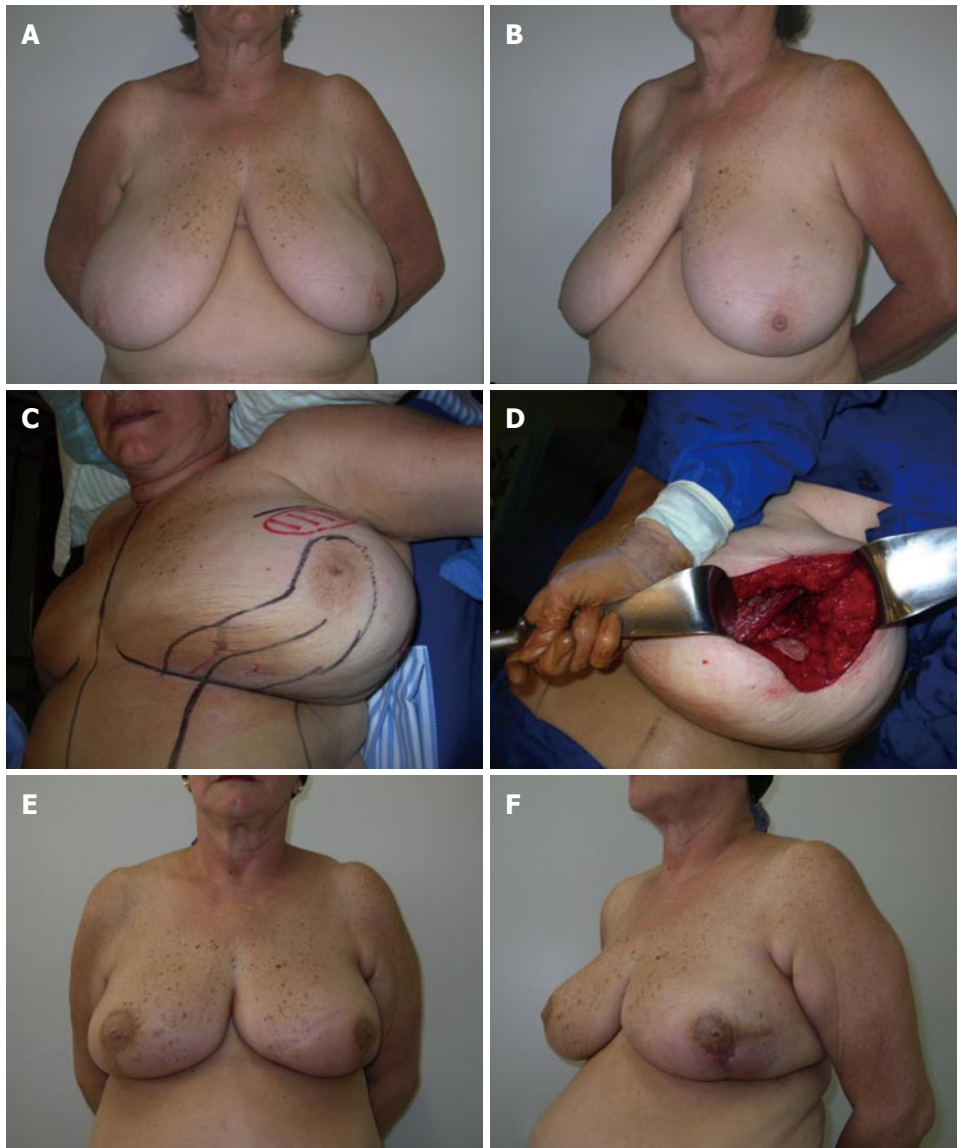
**Type III C:** Breast defects are analyzed individually. When the defect is favorable, the deficiency is most frequently reconstructed with TRM (Figure 4). A marked reshaping of the breast with available tissue and a similar contralateral breast reduction is then performed. In patients in whom the relationship is not favorable, a skin-sparing mastectomy and total breast reconstruction can be indicated.

## TYPES OF TRM TECHNIQUES

In spite of the reduction mammoplasty being a well

documented and commonly performed procedure for aesthetic objectives, less information is available regarding the outcome following immediate reconstruction for oncological objectives. To date, there are few large clinical reports that specifically address the use of the technique for immediate reconstruction and its outcome<sup>[8,15-19]</sup> (Table 1). In addition, there is no consensus regarding the best TRM technique for immediate BCS reconstruction. Possibly, an ideal procedure does not exist and each case should be planned individually. The main advantages of the TRM technique utilized should include reproducibility, safety and long-term results. As any surgical technique, all these goals are probably not met by any single procedure and this is supported by the large number of TRM techniques available<sup>[13]</sup>.

Concerning the techniques, TRM procedures present



**Figure 4** A 58-year-old patient with invasive ductal carcinoma (5.7 cm) of the superior quadrant of the left breast. The patient underwent a superior left quadrantectomy and axillary dissection, immediately followed by a therapeutic reduction mammoplasty Inferior Pedicle Technique reconstruction (A-B, above left and right); a total of 825 g was removed from the left breast (C-D, center left and right); One year postoperative appearance after the radiotherapy with a very good outcome (E-F, below left and right).

**Table 1** Oncological and outcome using reduction mammoplasty techniques

Ref.	Year	Technique	n	Tumor size (cm)	Follow-up (mo)	Local recurrence (%)	Patient satisfaction (%)
Papp <i>et al</i> <sup>[12]</sup>	1998	Superior pedicle	10	NR	52	5	95
Nos <i>et al</i> <sup>[71]</sup>	1998	Superior pedicle	50	3.25	48	7	85
Spear <i>et al</i> <sup>[18]</sup>	2003	Superior pedicle	56	NR	46	6.9	91
Clough <i>et al</i> <sup>[41]</sup>	2003	Superior pedicle	101	3.2	24	0	88
Chang <i>et al</i> <sup>[19]</sup>	2004	Superior pedicle	37	0.6-5.2	NR	0	NR
Goffman <i>et al</i> <sup>[74]</sup>	2005	Superior pedicle	57	NR	18	13	82
Munhoz <i>et al</i> <sup>[15]</sup>	2006	Superior pedicle	74	2-4.0	22	0	93
Munhoz <i>et al</i> <sup>[16]</sup>	2006	Superior-medial pedicle	39	2-4.0	20	0	90
Munhoz <i>et al</i> <sup>[17]</sup>	2007	Inferior pedicle	26	2-4.0	21	0	89
Fitoussi <i>et al</i> <sup>[47]</sup>	2010	Superior pedicle	540	2.9	49	6.8	90

with a variety of glandular pedicle types with an inverted T scar design. Most of the techniques are predictable and permit management over the extent of resection

and the breast-shaping process. Because of rich breast tissue vascularization, the majority of techniques have based their planning on preserving the pedicle of the



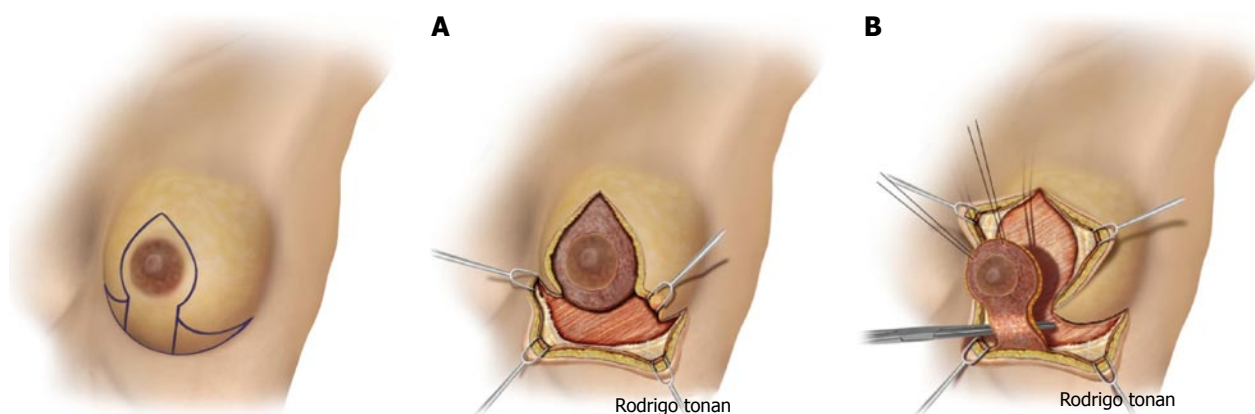


Figure 5 Schematic illustration of the therapeutic reduction mammoplasty surgical markings and Superior (A) and Inferior pedicle (B) techniques.

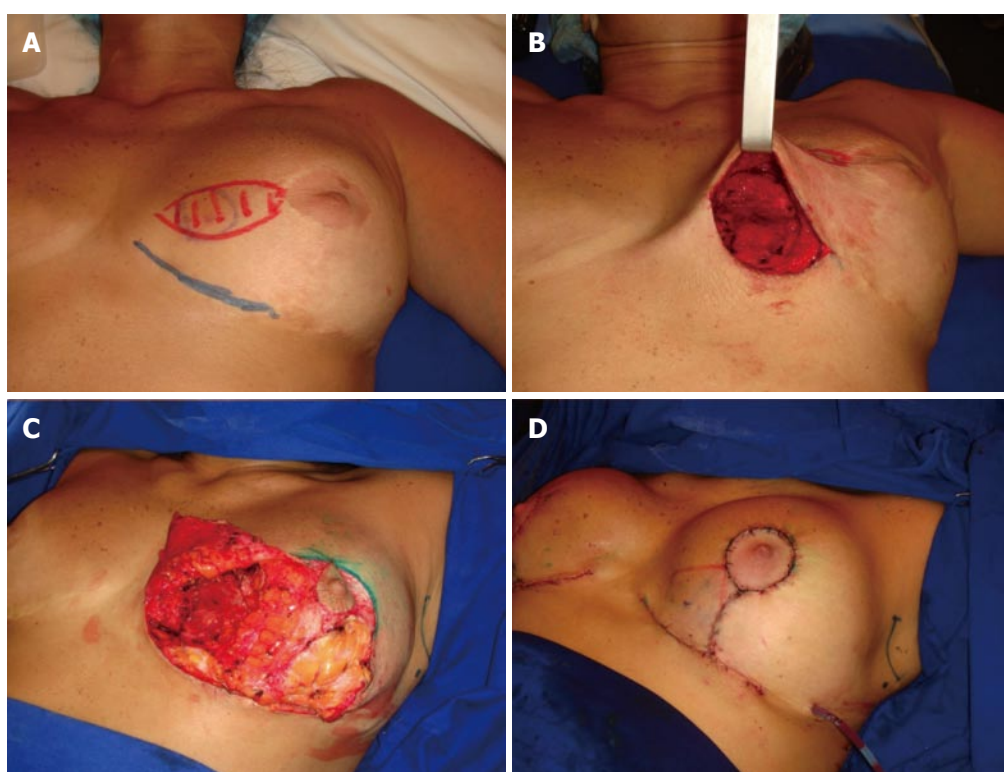


Figure 6 The superior-lateral pedicle technique for inferior-medial quadrantectomy reconstruction. For tumors located in the lower pole of the breast, the tumor resection can be incorporated into the sector of breast tissue removed as part of a superior pedicle mammoplasty (A-B); For inner region tumors, the reduction pattern can be rotated and a superior-lateral (C); The opposite breast surgery is usually performed to match the appropriate symmetry (D).

NAC after tumor removal. Each technique presents particular advantages for their indications, tumor location, additional skin and glandular resections and resultant scar<sup>[15]</sup>. Typically, one of two procedures can be utilized: the superior pedicle and the inferior pedicle technique (Figure 5). A range of other approaches have been described, which are adaptations of the superior and inferior procedures.

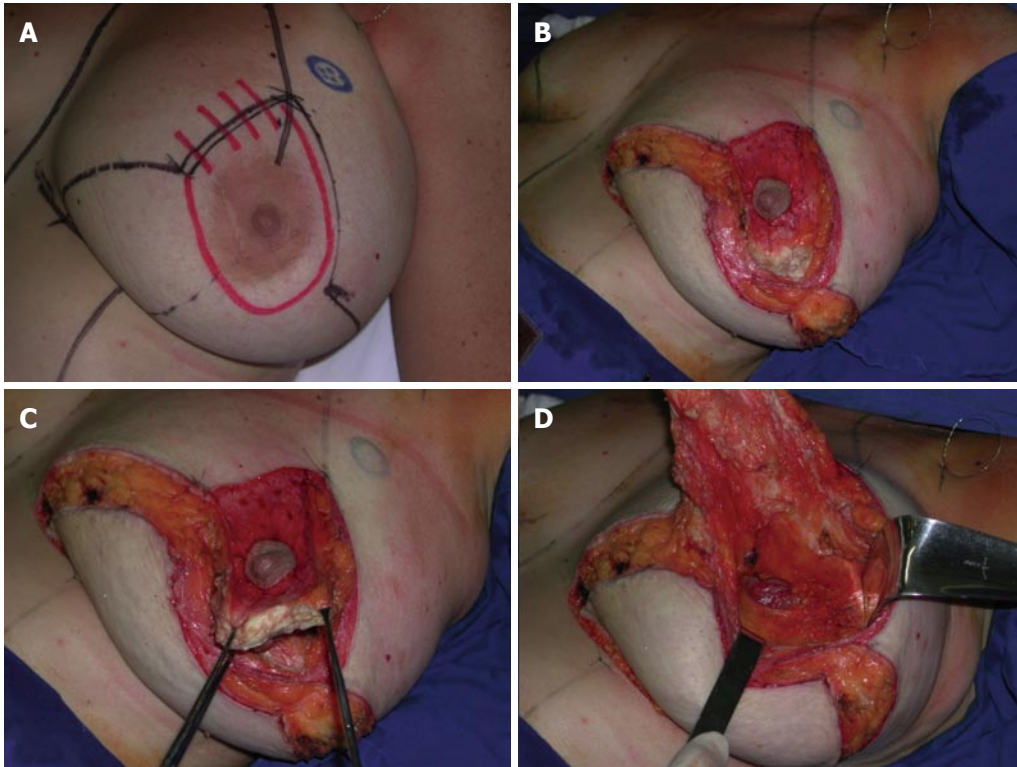
### Superior pedicle techniques

For tumors located in the lower pole of the breast, the tumor resection can be incorporated into the sector of breast tissue removed as part of a superior pedicle mam-

maplasty<sup>[15,16]</sup>. For inner and outer region tumors, the reduction pattern can be rotated and a superior-lateral (Figure 6) or a superior-medial pedicle mammoplasty (SMDP) can be performed<sup>[16]</sup> (Figure 7). The opposite breast surgery is usually performed to match the appropriate symmetry, particularly in breasts with severe ptosis. In our previous study analyzing different TRM for BCS reconstruction, the superior pedicle represented almost 90% of cases<sup>[15]</sup>.

In our clinical practice and with a well-trained surgical team, the procedure can be conducted on both sides at the same time, consequently reducing the operative time. When performing symmetrization, the surgeon can use





**Figure 7** The superior-medial pedicle technique for superior-lateral quadrantectomy reconstruction. For superior and outer region tumors, the reduction pattern can be rotated and a superior-medial (A-D).

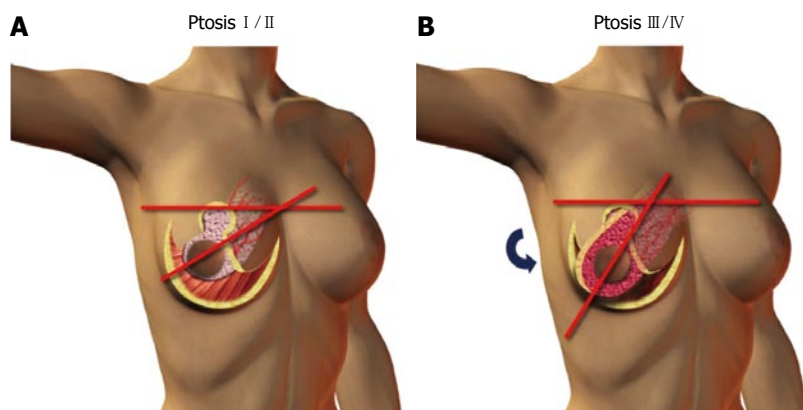
this opportunity to resect any suspicious breast lesion that may have been revealed by preoperative exams<sup>[15,24]</sup>.

Described originally by Orlando and Guthrie in the 1970s, the SMDP technique presents advantages in terms of pedicle safety and aesthetic outcome<sup>[29]</sup>. The technique is designed to preserve the pedicle blood flow as well as to provide a better breast shape<sup>[29-31]</sup>. The superior-medial pedicle receives its blood supply directly from the internal mammary vessels which are the main pedicle in the majority of patients<sup>[31,32]</sup>. This anatomical characteristic permits a better NAC vascularization and can minimize vascular pedicle complications when planned and performed effectively.

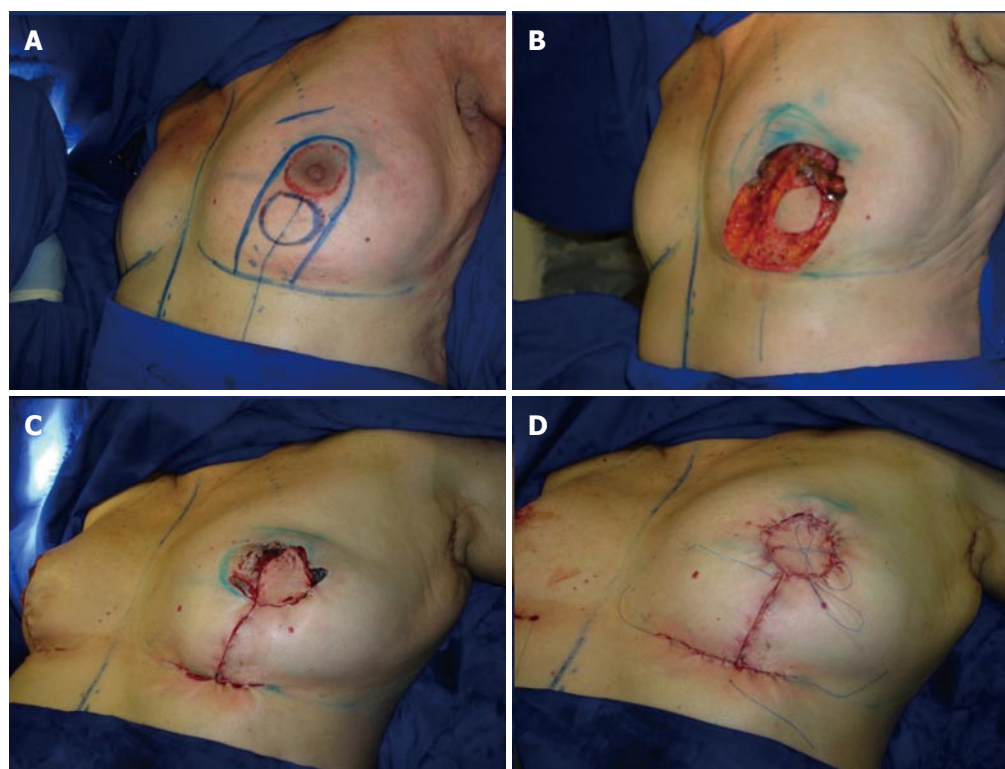
In our previous experience, the SMDP was indicated in patients with medium or large volume breasts with ptosis<sup>[16]</sup>. According to our algorithm, all tumors were located in the lower breast pole and the patients presented with small or moderate defects where there was enough breast tissue to perform the reconstruction<sup>[11]</sup>. Similar to our previous study with superior pedicle techniques<sup>[11,15]</sup>, the planning of the SMDP procedure was based on preserving the pedicle of the NAC before tumor removal. In this situation, the tumor resection was incorporated into the sector of breast tissue removed as part of a conventional SMDP technique and it usually results in an inverted T scar pattern. Normally, the NAC is de-epithelialized and a minimum pedicle base of 4 cm is maintained, depending on the extension of tumor resection. If a large pedicle is maintained, it may be that more vascular supply can be incorporated. It is important to

maintain the distal aspect of the pedicle with a minimum 2 cm margin around the NAC in order to preserve the local vascular plexus. Concerning the final breast shape and projection, some authors in aesthetic reductions advocate the addition of extra glandular tissue in the pedicle to form a platform for the NAC so that it does not become depressed postoperatively. One important point is that the pedicle should rotate without difficulty into its new position<sup>[31]</sup>. At this point, the most crucial aspect is to avoid some degree of kinking or compression<sup>[32]</sup>. If too much glandular tissue is maintained in the pedicle, it will also make it more difficult to rotate and insert it in the new NAC position. Moreover, Hall-Findlay has suggested that there is a risk to the glandular tissue in excess drop down which might result in a pseudoptotic breast<sup>[32]</sup>.

In spite of the main advantages, the SMDP technique has some negative aspects. Since the NAC flap is not an axial flap, tissue vascularization to the most distant parts is difficult to foresee during the NAC pedicle planning and breast molding. This situation can predispose to partial necrosis of the NAC flap and even a total NAC loss. With the objective of improving the NAC vascularization and to avoid pedicle torsion, it is important to define the right position of the NAC pedicle according to the degree of breast ptosis and hypertrophy. Similar to the proposal by Cárdenas-Camarena *et al.*<sup>[33]</sup>, in the superior lateral technique we advocate locating the pedicle lower down when the degree of ptosis and migration of the NAC is greater to avoid marked rotation (Figure 8).



**Figure 8** Schematic illustration of the superior-medial pedicle technique according to the degree of breast ptosis and the rotation of the pedicle. With the objective of improving the nipple-areola complex (NAC) vascularization and to avoid pedicle torsion, it is important to define the right position of the NAC pedicle according to the degree of breast ptosis and hypertrophy. It is important to locate the pedicle lower down when the degree of ptosis and migration of the NAC is greater to avoid marked rotation.



**Figure 9** Inferior pedicle technique for central quadrantectomy reconstruction. For central region tumors (A), the lower breast and skin tissue may be moved into the defect as a skin-glandular flap and an inferior pedicle mammoplasty can be utilized (B-D).

### Inferior pedicle techniques

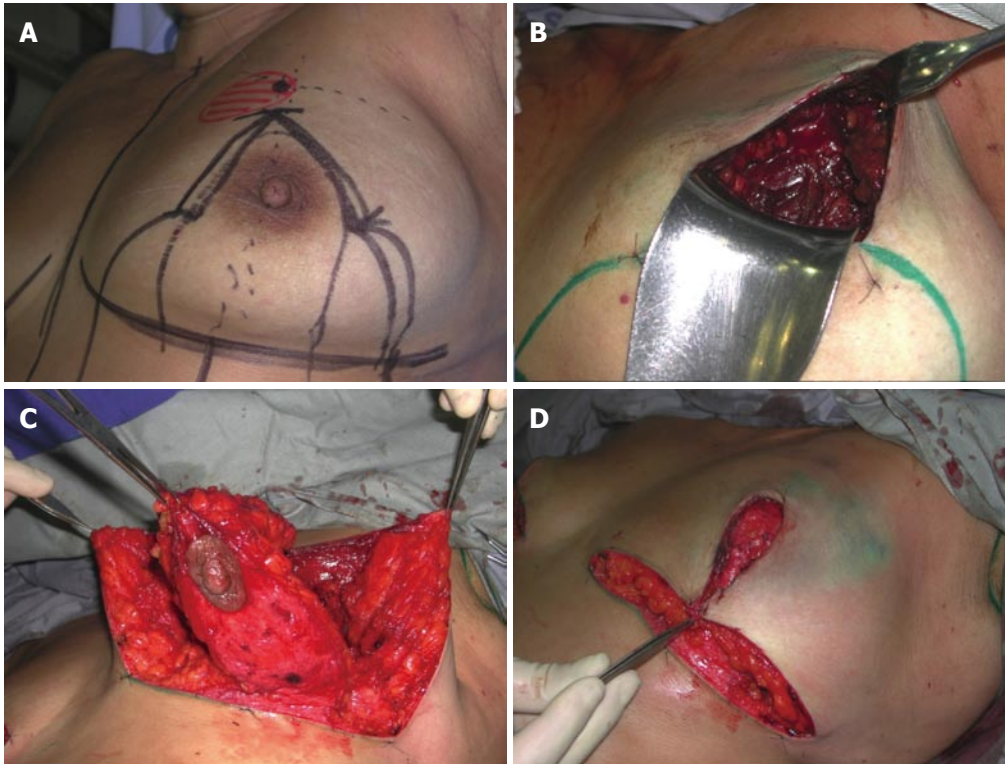
For upper region tumors, the lower breast tissue may be moved into the defect as a glandular flap and an inferior pedicle mammoplasty (IPM) can be utilized<sup>[17]</sup>. Introduced originally by Ribeiro<sup>[34]</sup> in the 1970s and subsequently modified by Courtiss and Goldwyn<sup>[35]</sup>, the technique described the transposition of the NAC on an inferiorly based dermoglandular flap.

Concerning the IPM technique, there are some advantages in terms of pedicle safety and results. The inferior pedicle receives its blood supply directly from the fourth, fifth and sixth intercostal perforating vessels of the internal mammary arteries. In fact, Courtiss and Goldwyn<sup>[35]</sup> demonstrated by cadaver dissections that the principal sources of blood flow are the perforating and intercostal branches of the internal mammary artery and the ex-

ternal mammary branches of the lateral thoracic artery. Thus, the IPM provides a breast that is easily shaped, without neurovascular changes to NAC<sup>[36-39]</sup>.

In our experience, the IPM was performed to repair skin and breast tissue and was indicated in patients with medium or large volume breasts with ptosis<sup>[17]</sup>. All tumors were located in the upper and central breast pole and the patients presented with small or moderate defects where there was enough breast tissue to perform the reconstruction. In the central tumors, the NAC is resected and the lower pole tissue is preserved to perform the reconstruction (Figure 9). Despite no cases of contralateral tumor being observed in our series utilizing the IPM, the contralateral mammoplasty provides an opportunity for histological examination of tissue from the opposite breast. In fact, Petit *et al*<sup>[40]</sup> reported a 4.5% incidence of





**Figure 10 Inferior pedicle technique for upper quadrantectomy reconstruction.** For upper region tumors (A), the lower breast and skin tissue associated with the nipple-areola complex may be moved into the defect as a skin-glandular flap and a conventional inferior pedicle mammoplasty can be utilized (B-D).

occult carcinomas in the contralateral breast in a series of 440 patients. Similarly, in our previous larger study, 4.3% of the patients submitted to contralateral mammoplasty presented with the diagnosis of occult breast cancer<sup>[24]</sup>.

IPM for BCS reconstruction can be a helpful technique for early breast cancer patients; nevertheless, important technical details must be considered. Preoperative evaluation can permit optimal positioning of the skin resection and to preserve the perforator vessels. Normally, the inferior pedicle is de-epithelialized and a minimum pedicle base of 6 cm is maintained. Concerning the breast contour close to the partial mastectomy area, it is practical to bend the inferior pedicle over itself to provide extra glandular tissue so that it does not become depressed postoperatively. For this purpose, the inferior pedicle should lie comfortably within the defect and it is important to avoid additional undermining to preserve the local vascular plexus (Figure 10). Even although we observed a low incidence of vascular complications, care must be taken in treating high risk patients, such as smokers and patients with a longer sternal notch to NAC distance. It has been our impression and that of some authors that the inferior pedicle length and the pedicle placement without tension are the main determinants of complications.

In spite of the advantages, the IPM presents some limitations. Although some authors have observed that the technique does not represent a problem with surveillance, with breast remodeling techniques it may be difficult to establish the location of a positive tumor

margin that is diagnosed postoperatively. In cases of re-exploration, it is rational to execute it in association with the plastic surgery team to identify the original tumor bed and to avoid injury to the inferior pedicle.

In our experience, we observed that the majority of the complications utilizing IPM for BCS reconstruction were immediate, minor and did not interfere with the adjuvant treatment<sup>[17]</sup>. Similarly, as we have observed in superior pedicle techniques, the most frequent complications in the late period were related to skin disorders and fat necrosis which were diagnosed by mammography during the follow-up. According to Losken *et al.*<sup>[23]</sup>, postoperative surveillance is not impaired by immediate mammoplasty. In fact, calcifications and fat necrosis from postoperative scarring can mimic cancer recurrence; nevertheless, these changes can be distinguished on mammography, fine-needle aspiration or core biopsy.

## CLINICAL RESULTS OF TRM IN BCS RECONSTRUCTION

Various oncoplastic procedures have been demonstrated to improve aesthetic outcome following BCS. Techniques range from simple glandular flaps to TRM and distant flaps<sup>[11]</sup>. At the present time, optimal treatment should be correct, adequate and preventive by performing immediate reconstruction before radiotherapy<sup>[9,24,25]</sup>. However, to date there is limited evidence in the plastic and breast surgery literature on the safety and aesthetic clinical results of the TRM techniques<sup>[8,9,10,24,25,27,28]</sup>. In fact, most



of these clinical series are retrospective studies, generally based on a limited number of patients and sometimes only a single surgeon's experience. In addition, there are a small number of data on its impact on local recurrences, distant metastasis and overall survival<sup>[9,41,42]</sup>.

Some retrospective clinical studies with long-term follow-up have shown that TRM is not associated with a higher rate of recurrence or lower survival rate than conventional techniques. Clough *et al.*<sup>[41]</sup> with a median follow-up of 46 mo reported 101 patients who underwent BCS and oncoplastic reconstruction. Local recurrence developed in 11 cases (5 years local recurrence rate was 9.4%). Thirteen patients developed metastases and eight died of their disease (5 years metastasis-free survival of 82.8% and an overall survival rate of 95.7%). Similarly, Kronowitz *et al.*<sup>[9]</sup> in a review of 69 patients observed local recurrence in 2% of immediate oncoplastic reconstructions and in 16% of delayed ( $P = 0.06$ ). The difference observed between the two groups can be explained by the advanced tumor stage for the patients who had a delayed reconstruction. Recently, Rietjens *et al.*<sup>[42]</sup> reported the long-term oncological results of the oncoplastic reconstruction in a series of 148 patients. With a median follow-up of 74 mo, 3% developed an ipsilateral breast cancer recurrence and 13% developed distant metastasis. According to the authors, the rate of local recurrence after 5 years was low in their series when compared with the 14.3% of cumulative incidence in the NSABP trial, the 9.4% after 5 years in the Institut Curie study and the 0.5% after 5 years in the Milan I trial. Consequently, the oncoplastic approach associated with BCS can be considered as safe as mastectomy in tumors less than 2 cm and possibly safer than the BCS.

Another important point is related to tumor size and volume resection. In fact, the use of TRM presents a significantly higher volume of tissue excised compared to standard wide local excision. Kaur *et al.*<sup>[22]</sup> in 2005 compared quadrantectomy with TRM procedures and observed a higher mean volume of tissue excised during TRM. However, they demonstrated no significant difference in margins between the two groups. Similarly, Giacalone *et al.*<sup>[43]</sup> demonstrated mean specimen volumes of 190 cm<sup>3</sup> for oncoplastic techniques and 99 cm<sup>3</sup> for standard quadrantectomy.

There is limited evidence of the oncoplastic procedures concerning the aesthetic outcome. In addition, the methods of aesthetic evaluation vary significantly<sup>[9,10]</sup>. Some authors reported that the volume of tissue resection is directly associated with the aesthetic outcome<sup>[7,44-52]</sup>. Gendy *et al.*<sup>[44]</sup> compared the aesthetic outcomes of 106 patients. Although the panel scored the aesthetic outcome as high, the aesthetic failure rate was 18% on breast retraction assessments. The authors demonstrated an advantage for the BCS reconstruction with regards to the incidence of complications (8% *vs* 14%), additional surgery (12% *vs* 79%) and restricted activities (54% *vs* 73%). Olivotto *et al.*<sup>[45]</sup> and Mills *et al.*<sup>[46]</sup> have docu-

mented that excision of a volume greater than 70 cm<sup>3</sup> in medium-size breasts often leads to unsatisfactory aesthetic results. Clough *et al.*<sup>[41]</sup>, in a panel of three, assessed cosmetic results at 2 and 5 years. At 2 years, 88% and at 5 years, 82% of patients had a fair to excellent outcome. A significantly worse aesthetic outcome was observed in patients that received pre-operative radiotherapy compared to the remainder which were given radiotherapy post-operatively.

Fitoussi *et al.*<sup>[47]</sup> retrospectively used a similar aesthetic evaluation method as proposed by Clough *et al.*<sup>[41]</sup>, with a panel made up of a surgeon, a nurse and a layman, using a five-point scale from excellent to poor. The cosmetic outcome in this retrospective study was satisfactory in 98% of patients at 12 mo and in 90% of patients at 5 years following BCS reconstruction.

Although oncological safety remains the primary objective of BCS, surgical management is increasingly focusing on improved aesthetic outcomes. Immediate application of TRM has evolved to meet this need and the extensive body of literature published in recent years demonstrates the widespread use of these techniques. Recognizing that there is a small risk for local recurrence, we believe that immediate application of TRM could be a safe option for early breast cancer patients who desire BCS.

## LIMITATIONS OF TRM

### Adjuvant treatment

There is evidence that oncoplastic breast conservation surgery and immediate application of TRM does not lead to a delay in the commencement of adjuvant chemotherapy<sup>[15,18,23,25,28,42,50,53-56]</sup>. Although this is an integral part of overall oncological safety, few controlled studies have been published. In fact, most of the studies focus on recurrence rates and long-term survival; however, the evidence described is mostly based on single center retrospective analyses with relatively low patient numbers and no control groups (Table 2).

Time between BCS and commencement of adjuvant chemotherapy is only one aspect of oncological safety after early breast cancer management. In fact, patients who undergo complex surgery may be more susceptible to immunosuppression caused by chemotherapy. This may increase surgery related complication rates, which can lead to an internal delay between chemotherapy cycles, requiring frequent administration of granulocyte colony-stimulating factor or repeat hospital admissions<sup>[28]</sup>.

In a recently published meta-analysis, the average complication rate in the TRM group was 16% and 14% in the flap reconstruction group<sup>[49]</sup>. However, it does not seem that complications in the oncoplastic groups, although potentially higher, have any negative impact on patient care from an oncological point of view. In fact, adequate technique and patient selection is crucial in order to minimize morbidity when this oncoplastic tech-

**Table 2** Oncological and outcome evidence for delivery of adjuvant chemotherapy after immediate breast-conservation surgery reconstruction

Ref.	Year	n	Tumor size (cm)	Adjuvant chemotherapy n (%)	Delay in chemotherapy	Delayed adjuvant chemotherapy n (%)
Nos <i>et al</i> <sup>[71]</sup>	1998	50	Tis-T4	5 (10)	+	3 (6)
Losken <i>et al</i> <sup>[23]</sup>	2002	20	Tis-N/D	N/D	-	0
Clough <i>et al</i> <sup>[41]</sup>	2003	101	T1-T4	0	+	4 (4)
Spear <i>et al</i> <sup>[18]</sup>	2003	22	N/D	22 (100)	-	0
McCulley <i>et al</i> <sup>[53]</sup>	2005	50	Tis-N/D	23 (46)	-	0
Munhoz <i>et al</i> <sup>[15]</sup>	2006	74	T1-T2	22 (29.7)	-	0
Thornton <i>et al</i> <sup>[54]</sup>	2006	6	T1-T2	0	-	0
Kronowitz <i>et al</i> <sup>[50]</sup>	2007	41	Tis-T2	18 (44)	-	0
Losken <i>et al</i> <sup>[25]</sup>	2007	63	Tis-N/D	N/D	-	0
Rietjens <i>et al</i> <sup>[42]</sup>	2007	148	T1-T3	89 (60)	-	0
Meretoja <i>et al</i> <sup>[72]</sup>	2010	90	Tis-T3	60 (67)	+	2 (2)
Fitoussi <i>et al</i> <sup>[47]</sup>	2010	540	T1-T3	N/D	+	10 (1.9)
Song <i>et al</i> <sup>[55]</sup>	2010	28	Tis	N/A	-	0
Romics <i>et al</i> <sup>[56]</sup>	2012	31	T1-T3	31 (100)	-	0
Kahn <i>et al</i> <sup>[28]</sup>	2013	169	T1-T3	N/D	-	0

N/D: Not disclosed; N/A: Not applicable; (+): Positive; (-): Negative.

nique is selected. Despite the poor scientific evidence, nothing suggests that TRM is unsafe in terms of starting adjuvant therapy on time. In fact, Kahn *et al*<sup>[28]</sup> provide evidence that immediate BCS reconstruction does not lead to a delay in the commencement of adjuvant chemotherapy when compared to three adequate control groups from the same institution and time periods.

Concerning adjuvant radiotherapy, one might surmise that techniques that involve rearrangement of breast tissue may jeopardize the boost radiation dose delivery since the target area is defined as the site of the original tumor<sup>[15,57-59]</sup>. For this reason, coordinated planning with the radiotherapy center is important since TRM modifies the normal architecture of the breast<sup>[15,16]</sup>. To locate the original tumor area, we advocate orienting the original tumor area by skin markings and also placing surgical clips at the tumor margins. It has been our impression, similarly observed by other authors<sup>[57,58]</sup>, that identification of the original tumor bed based only on physical exam, without precise imaging information, can result in missing the primary tumor bed. In our previous studies<sup>[15-17]</sup>, clips have not interfered with mammography and have actually helped recognize areas at risk for recurrence. Additionally, clips have not been mentioned as interfering with physical examination or aesthetic outcome<sup>[57]</sup>. On the other hand, Poortmans *et al*<sup>[60]</sup> mentioned that the location of clips can be misleading in cases where volume displacement techniques are utilized, especially where the boost area is not the entire surgical cavity. According to other authors, this usually results in larger boost volumes than actually necessary, potentially leading to local fibrosis and poorer aesthetic outcome<sup>[60,61]</sup>.

Another important issue is related to delayed reconstruction following BCS and radiotherapy. Frequently, the appearance of the radiated breast is less pleasing than the nonradiated one and the total dose, boost therapy and number of radiation fields may be involved<sup>[19,21,23,24]</sup>.

Spear *et al*<sup>[18]</sup> mentioned that, besides the differences observed in the normal healing process, the radiated breast has a longer induration and swelling than the opposite breast<sup>[18]</sup>. In our previous experiences utilizing TRM, the majority of patients presented with good or very good results in terms of breast shape and symmetry<sup>[15-17]</sup>. In spite of this, almost 10% of patients presented with complications of breast skin necrosis and wound dehiscence, 92.3% of patients were either very satisfied or satisfied with their result and none regretted the surgery. Losken *et al*<sup>[23]</sup> advocated that when radiation is expected, the possibility of fibrosis and glandular atrophy should be taken into account in an attempt to preserve breast symmetry. The authors suggested less aggressive reductions on the ipsilateral breast to accommodate for any additional size distortion. Additionally, some authors advocated that oncoplastic reconstruction with radiation is best achieved using autologous, nonirradiated flaps<sup>[6,9,11,24]</sup>.

### Postoperative surveillance

According to Losken *et al*<sup>[49,62]</sup> postoperative surveillance is not significantly affected by the rearrangement of breast tissue. These results corroborate with the findings of Roberts *et al*<sup>[63]</sup> concerning the incidence of abnormal mammograms after reduction mammoplasty. In fact, these authors observed that, despite the substantial mobilization of tissue, postoperative mammography did not lead to more diagnostic interventions than nonoperative controls<sup>[63,64]</sup>.

Concerning late complications, the most common event is related to fat necrosis and this aspect is well defined in conventional mammograms. In our previous experience comparing immediate and delayed BCS reconstruction with reduction mammoplasty techniques, this complication was significantly higher in the delayed group<sup>[24]</sup>. It has been our impression that radiation therapy played a significant role and contributed to de-

**Table 3** Immediate breast-conservation surgery reconstruction and therapeutic reduction mammoplasty techniques: surgical margins and outcome

Ref.	n	Follow-up (mo)	Tumor size (cm)	Positive margins (%)	Local recurrence (%)
Clough <i>et al</i> <sup>[41]</sup> 2003	101	46	3.2 (0.1-7)	10.9	6.9
Clough <i>et al</i> <sup>[7]</sup> 1999	20	54	NS	0	5
Nos <i>et al</i> <sup>[71]</sup> 1998	50	48	3.5 (1.5-6)	10	7
Papp <i>et al</i> <sup>[12]</sup> 1998	10	52	NS	0	5
Masetti <i>et al</i> <sup>[75]</sup> 2000	56	23	NS	NS	0
Spear <i>et al</i> <sup>[18]</sup> 2003	11	24	NS	0	0
Chang <i>et al</i> <sup>[19]</sup> 2004	37	NS	0.6-5.2	2.7	0
Losken <i>et al</i> <sup>[23]</sup> 2002	14	23	1.5 (0.6-3)	28.6	0
Munhoz <i>et al</i> <sup>[15]</sup> 2006	74	22	1.9 (0.6-3.9)	9.5	0
Fitoussi <i>et al</i> <sup>[47]</sup> 2010	540	49	2.9	5	6.8

NS: Not specified.

velopment of fat necrosis. One might surmise that in delayed reconstructions, a slower reestablishment of a local blood supply to rearranged breast tissues from the underlying irradiated chest wall can be observed. In addition, previous breast tissue scarring and local effects of radiotherapy can also disrupt the local blood supply and the ability to create a safe parenchymal pedicle<sup>[9,24]</sup>. Thus, in these patients, careful surveillance is prudent since the risk of local recurrence is always possible. According to Losken *et al*<sup>[25,49,62]</sup>, postoperative surveillance is not impaired by simultaneous TRM. In some cases, calcifications and fat necrosis can simulate tumor recurrence; however, these aspects can be distinguished on mammogram or core biopsy<sup>[15-17,25]</sup>.

### Final surgical margins assessment and immediate reconstruction

When margins are found to be positive following BCS reconstruction, there is no consensus as to whether or not additional re-excision is possible as there may be difficulty in identifying the area of the original quadrantectomy. Some breast surgeons therefore indicate skin-sparing mastectomy if margins are compromised following definitive pathology evaluation.

In fact, TRM involves rearrangement of glandular tissue and could make re-excision difficult in cases where close or positive margins are observed<sup>[64,65]</sup>. This fact could make it difficult to locate the residual tumor and to perform margin re-excision. In our previous studies<sup>[14-17,65]</sup>, intraoperative margin evaluation was assessed by pathological monitoring, which is based on macroscopic, radiological and histological examination of frozen sections. In our experience, positive margins discovered on permanent pathology in a previously negative margin patient were observed in 5.5%<sup>[65]</sup>. Overall, the oncological outcome of our data corroborate the study of Fitoussi *et al*<sup>[47]</sup>, which is the largest study describing the oncological outcomes of 540 patients over a period of two decades. This study described clear margins in 438 patients (81%), focal involvement in 77 patients (14%)

and tumor-involved margins in 25 patients (5%). According to the authors, eleven patients underwent re-excision (2%), 40 patients received an additional radiotherapy boost (7%) and 51 patients required a mastectomy (9% overall) (Table 3).

Previous studies have investigated risk factors to identify patients with a high probability of having positive margins<sup>[25,64-75]</sup>. Age (younger)<sup>[25,65,67,68]</sup>, tumor type (in situ carcinoma)<sup>[25,64-75]</sup> and larger tumor size<sup>[65,69]</sup> have all been associated with positive margins. Our results were comparable to those of the previous studies, with young patients and larger tumor size as more likely to have positive margins<sup>[64]</sup>. Concerning the reoperative rates, Weinberg *et al*<sup>[69]</sup> observed that 6.2% had later re-excisions and Cendán *et al*<sup>[70]</sup> reported that 19.6% of subjects required additional operations to clear surgical margins. Despite these aspects, the positive margins can be effectively managed with either re-excision with/without reconstruction or with skin-sparing mastectomy and total reconstruction, depending on the extension of tissue resection, preference and pathology. The decision to re-operate depends on the extent of tumor involvement, whether the dissection had already been extended to the chest wall or skin, or whether the patient had opted to proceed with a total reconstruction. It has been our impression that re-operation was not a negative aspect and the disadvantage of a more extensive surgery is negligible. In cases of re-exploration, it is rational to carry it out in association with the plastic surgery team to identify the original tumor bed and to avoid injury to the NAC pedicle<sup>[15-17,64]</sup>.

Thus, intraoperative assessment of surgical margins requires multidisciplinary cooperation among oncological and plastic surgeons and pathologists. According to Losken *et al*<sup>[25]</sup>, all patients should be informed preoperatively of the potential need for a delayed-immediate approach. Additionally, these high-risk patients can be better managed by staged procedures and confirmation of negative margins prior to CBS reconstruction.

### Opposite breast surgery

Another important issue is related to the OB surgery. Previous studies have differed with regard to the timing of opposite breast symmetrization. In fact, Gray *et al*<sup>[21]</sup> described an association between breast irradiation in large volume breasts or obese patients and greater retraction at 5 years and an inferior overall cosmetic result. Another concept advocated was to perform symmetrization 6 mo after BCS following neoadjuvant treatment, as they suspected an unpredictable effect of radiotherapy on the breast and an alteration of body weight during chemotherapy.

In our previous experiences, almost all patients submitted to TRM had bilateral procedures<sup>[15-17]</sup>. In fact, Kronowitz *et al*<sup>[50]</sup> observed a significant relationship between the reconstructive technique and the need for an OB reduction. This aspect can be viewed as a negative point; however, it also has the advantages of allowing for sampling of glandular tissue<sup>[15-17,19,24,27,50]</sup>. In our previ-



ous study<sup>[24]</sup>, we reported our experience with surgical management and outcome in BCS reconstruction with TRM techniques with regards as to whether immediate or delayed reconstruction is better in terms of complication rates. In this series, in 2.8% of patients, an unexpected cancer in the OB was observed in immediate TRM reconstruction. Although the diagnosis of occult cancer is not a reason to perform an OB reduction, this procedure can be advantageous for high-risk patients and especially for patients with previous breast cancer<sup>[24]</sup>.

### Delayed BCS reconstruction and outcome

Another important issue is related to the complication rates and the timing of reconstruction. In our previous series, delayed reconstruction complication rates have been shown to be higher than immediate reconstruction (31% *vs* 22% respectively)<sup>[24]</sup>. However, this aspect was not significant ( $P = 0.275$ ). Thus, our results indicate that timing of reconstruction is not a significant predictor of complications following BCS reconstruction with TRM. This finding is contradictory to published reports that suggest that delayed BCS reconstruction has a significantly higher complication rate compared with immediate procedures. In fact, Kronowitz *et al*<sup>[9]</sup> observed that delayed reconstruction was associated with a complication rate almost twice that of immediate. In our study, the relatively small number of patients and especially the small number of obese patients in the delayed group (21.7% *vs* 10.5%) may have influenced this comparison. Thus, a large number of patients and a prospective and controlled sample are necessary for definitive conclusions.

### CONCLUSION

BCS defects represent an anatomic variety that ranges from small defects that may repair with primary closure to large defects that involve skin, NAC and a significant amount of glandular tissue. Each defect has its own special reconstructive necessities and varying expectations for aesthetic outcome. Recently, increasing attention has been focused on the oncoplastic approach and although surgical techniques have advanced, BCS reconstruction remains a challenging impasse. It has been our impression that a number of procedures have been described involving primary closure, breast reshaping, local and distant flaps. In addition, some different classifications have been proposed to describe the extent of resection, which has consequently created a wide-range of surgical options with different indications.

TRM in combination with BCS is not a new concept but is becoming increasingly accepted by oncological breast surgeons. In selected patients, this approach has allowed us to perform wide resections and obtain good oncological control with favorable aesthetic outcome. The majority of the complications were immediate, minor and comparable to other aesthetic reduction techniques. The main indication is in patients with enough breast tissue to perform the reconstruction. Although the combined

approach requires more preoperative planning and intra-operative care, the concept can reduce deformities, favor the oncological treatment and optimize the aesthetic outcome in most early stage cancer patients.

### REFERENCES

- 1 Veronesi U, Cascinelli N, Mariani L, Greco M, Saccozzi R, Luini A, Aguilar M, Marubini E. Twenty-year follow-up of a randomized study comparing breast-conserving surgery with radical mastectomy for early breast cancer. *N Engl J Med* 2002; **347**: 1227-1232 [PMID: 12393819 DOI: 10.1056/NEJMoa020989]
- 2 Hamdi M, Wolfli J, Van Landuyt K. Partial mastectomy reconstruction. *Clin Plast Surg* 2007; **34**: 51-62; abstract vi [PMID: 17307071 DOI: 10.1016/j.cps.2006.11.007]
- 3 Munhoz AM, Aldrighi CM, Ferreira MC. Paradigms in oncoplastic breast surgery: a careful assessment of the oncological need and esthetic objective. *Breast J* 2007; **13**: 326-327 [PMID: 17461918 DOI: 10.1111/j.1524-4741.2007.00437.x]
- 4 Audretsch W, Rezai M, Kolotas C. Tumor-specific immediate reconstruction in breast cancer patients. *Perspec Plast Surg* 1998; **11**: 71-79
- 5 Huemer GM, Schrenk P, Moser F, Wagner E, Wayand W. Oncoplastic techniques allow breast-conserving treatment in centrally located breast cancers. *Plast Reconstr Surg* 2007; **120**: 390-398 [PMID: 17632339 DOI: 10.1097/01.prs.0000267328.09246.02]
- 6 Slavin SA, Halperin T. Reconstruction of the breast conservation deformity. *Semin Plast Surg* 2004; **18**: 89-96 [PMID: 20574487 DOI: 10.1055/s-2004-829043]
- 7 Clough KB, Kroll SS, Audretsch W. An approach to the repair of partial mastectomy defects. *Plast Reconstr Surg* 1999; **104**: 409-420 [PMID: 10654684 DOI: 10.1097/00006534-199908000-00014]
- 8 Clough KB, Thomas SS, Fitoussi AD, Couturaud B, Reyat F, Falcou MC. Reconstruction after conservative treatment for breast cancer: cosmetic sequelae classification revisited. *Plast Reconstr Surg* 2004; **114**: 1743-1753 [PMID: 15577344 DOI: 10.1097/01.PRS.0000142442.62956.78]
- 9 Kronowitz SJ, Feledy JA, Hunt KK, Kuerer HM, Youssef A, Koutz CA, Robb GL. Determining the optimal approach to breast reconstruction after partial mastectomy. *Plast Reconstr Surg* 2006; **117**: 1-11; discussion 12-14 [PMID: 16404237 DOI: 10.1097/01.prs.0000194899.01875.d6]
- 10 Asgeirsson KS, Rasheed T, McCulley SJ, Macmillan RD. Oncological and cosmetic outcomes of oncoplastic breast conserving surgery. *Eur J Surg Oncol* 2005; **31**: 817-823 [PMID: 16043322 DOI: 10.1016/j.ejso.2005.05.010]
- 11 Munhoz AM, Montag E, Arruda E, Pellarin L, Filassi JR, Piatto JR, de Barros AC, Prado LC, Fonseca A, Baracat E, Ferreira MC. Assessment of immediate conservative breast surgery reconstruction: a classification system of defects revisited and an algorithm for selecting the appropriate technique. *Plast Reconstr Surg* 2008; **121**: 716-727 [PMID: 18317121 DOI: 10.1097/01.prs.0000299295.74100.fal]
- 12 Papp C, Wechselberger G, Schoeller T. Autologous breast reconstruction after breast-conserving cancer surgery. *Plast Reconstr Surg* 1998; **102**: 1932-1936; discussion 1937-1938 [PMID: 9810988 DOI: 10.1097/00006534-199811000-00018]
- 13 Munhoz AM, Montag E, Fels KW, Arruda EG, Sturtz GP, Aldrighi C, Gemperli R, Ferreira MC. Outcome analysis of breast-conservation surgery and immediate latissimus dorsi flap reconstruction in patients with T1 to T2 breast cancer. *Plast Reconstr Surg* 2005; **116**: 741-752 [PMID: 16141810 DOI: 10.1097/01.prs.0000176251.15140.36]
- 14 Munhoz AM, Montag E, Arruda EG, Aldrighi C, Gemperli R, Aldrighi JM, Ferreira MC. The role of the lateral thoracodorsal fasciocutaneous flap in immediate conser-

- vative breast surgery reconstruction. *Plast Reconstr Surg* 2006; **117**: 1699-1710 [PMID: 16651939 DOI: 10.1097/01.prs.0000209943.13682.42]
- 15 **Munhoz AM**, Montag E, Arruda EG, Aldrighi C, Gemperli R, Aldrighi JM, Ferreira MC. Critical analysis of reduction mammoplasty techniques in combination with conservative breast surgery for early breast cancer treatment. *Plast Reconstr Surg* 2006; **117**: 1091-1093; discussion 1104-1107 [PMID: 16582770 DOI: 10.1097/01.prs.0000202121.84583.0d]
- 16 **Munhoz AM**, Montag E, Arruda EG, Aldrighi C, Gemperli R, Aldrighi JM, Ferreira MC. Superior-medial dermoglandular pedicle reduction mammoplasty for immediate conservative breast surgery reconstruction: technical aspects and outcome. *Ann Plast Surg* 2006; **57**: 502-508 [PMID: 17060729 DOI: 10.1097/01.sap.0000233969.25031.cb]
- 17 **Munhoz AM**, Montag E, Arruda E, Aldrighi C, Filassi JR, de Barros AC, Piato JR, Prado L, Petti D, Baracat E, Ferreira MC. Reliability of inferior dermoglandular pedicle reduction mammoplasty in reconstruction of partial mastectomy defects: surgical planning and outcome. *Breast* 2007; **16**: 577-589 [PMID: 17566738 DOI: 10.1016/j.breast.2007.04.008]
- 18 **Spear SL**, Pelletiere CV, Wolfe AJ, Tsangaris TN, Pennanen MF. Experience with reduction mammoplasty combined with breast conservation therapy in the treatment of breast cancer. *Plast Reconstr Surg* 2003; **111**: 1102-1109 [PMID: 12621180 DOI: 10.1097/01.PRS.0000046491.87997.40]
- 19 **Chang E**, Johnson N, Webber B, Booth J, Rahhal D, Gannett D, Johnson W, Franzini D, Zegzula H. Bilateral reduction mammoplasty in combination with lumpectomy for treatment of breast cancer in patients with macromastia. *Am J Surg* 2004; **187**: 647-650; discussion 650-651 [PMID: 15135684 DOI: 10.1016/j.amjsurg.2004.01.002]
- 20 **Brierley JD**, Paterson IC, Lallemand RC, Rostom AY. The influence of breast size on late radiation reaction following excision and radiotherapy for early breast cancer. *Clin Oncol (R Coll Radiol)* 1991; **3**: 6-9 [PMID: 2001345 DOI: 10.1016/S0936-6555(05)81031-3]
- 21 **Gray JR**, McCormick B, Cox L, Yahalom J. Primary breast irradiation in large-breasted or heavy women: analysis of cosmetic outcome. *Int J Radiat Oncol Biol Phys* 1991; **21**: 347-354 [PMID: 2061111 DOI: 10.1016/0360-3016(91)90781-X]
- 22 **Kaur N**, Petit JY, Rietjens M, Maffini F, Luini A, Gatti G, Rey PC, Urban C, De Lorenzi F. Comparative study of surgical margins in oncoplastic surgery and quadrantectomy in breast cancer. *Ann Surg Oncol* 2005; **12**: 539-545 [PMID: 15889210 DOI: 10.1245/ASO.2005.12.046]
- 23 **Losken A**, Elwood ET, Styblo TM, Bostwick J. The role of reduction mammoplasty in reconstructing partial mastectomy defects. *Plast Reconstr Surg* 2002; **109**: 968-975; discussion 976-977 [PMID: 11884818 DOI: 10.1097/00006534-200203000-00025]
- 24 **Munhoz AM**, Aldrighi CM, Montag E, Arruda E, Brasil JA, Filassi JR, Aldrighi JM, Gemperli R, Ferreira MC. Outcome analysis of immediate and delayed conservative breast surgery reconstruction with mastopexy and reduction mammoplasty techniques. *Ann Plast Surg* 2011; **67**: 220-225 [PMID: 21301307 DOI: 10.1097/SAP.0b013e3181f77bba]
- 25 **Losken A**, Styblo TM, Carlson GW, Jones GE, Amerson BJ. Management algorithm and outcome evaluation of partial mastectomy defects treated using reduction or mastopexy techniques. *Ann Plast Surg* 2007; **59**: 235-242 [PMID: 17721207 DOI: 10.1097/SAP.0b013e31802ec6d1]
- 26 **Blondeel PN**, Hijawi J, Depypere H, Roche N, Van Landuyt K. Shaping the breast in aesthetic and reconstructive breast surgery: an easy three-step principle. Part III-reconstruction following breast conservative treatment. *Plast Reconstr Surg* 2009; **124**: 28-38 [PMID: 19568041 DOI: 10.1097/PRS.0b013e318ac7608]
- 27 **Ricci MD**, Munhoz AM, Pinotti M, Geribela AH, Teixeira LC, Aldrighi C, Ferreira MC, Filassi JR, Pinotti JA. The influence of reduction mammoplasty techniques in synchronous breast cancer diagnosis and metachronous breast cancer prevention. *Ann Plast Surg* 2006; **57**: 125-132; discussion 133 [PMID: 16861988 DOI: 10.1097/01.sap.0000216245.16475.b9]
- 28 **Kahn J**, Barrett S, Forte C, Stallard S, Weiler-Mithoff E, Doughty JC, Romics L. Oncoplastic breast conservation does not lead to a delay in the commencement of adjuvant chemotherapy in breast cancer patients. *Eur J Surg Oncol* 2013; **39**: 887-891 [PMID: 23746877]
- 29 **Orlando JC**, Guthrie RH. The superomedial dermal pedicle for nipple transposition. *Br J Plast Surg* 1975; **28**: 42-45 [PMID: 1125478]
- 30 **Wray RC**, Luce EA. Treatment of impending nipple necrosis following reduction mammoplasty. *Plast Reconstr Surg* 1981; **68**: 242-244 [PMID: 7255586 DOI: 10.1097/00006534-198108000-00025]
- 31 **Nahabedian MY**, McGibbon BM, Manson PN. Medial pedicle reduction mammoplasty for severe mammary hypertrophy. *Plast Reconstr Surg* 2000; **105**: 896-904 [PMID: 10724248 DOI: 10.1097/00006534-200003000-00011]
- 32 **Hall-Findlay EJ**. A simplified vertical reduction mammoplasty: shortening the learning curve. *Plast Reconstr Surg* 1999; **104**: 748-759; discussion 760-763 [PMID: 10456528]
- 33 **Cárdenas-Camarena L**, Vergara R. Reduction mammoplasty with superior-lateral dermoglandular pedicle: another alternative. *Plast Reconstr Surg* 2001; **107**: 693-699 [PMID: 11304593 DOI: 10.1097/00006534-200103000-00007]
- 34 **Ribeiro L**. A new technique for reduction mammoplasty. *Plast Reconstr Surg* 1975; **55**: 330-334 [PMID: 1118493]
- 35 **Courtiss EH**, Goldwyn RM. Reduction mammoplasty by the inferior pedicle technique. An alternative to free nipple and areola grafting for severe macromastia or extreme ptosis. *Plast Reconstr Surg* 1977; **59**: 500-507 [PMID: 847026]
- 36 **Robbins TH**. A reduction mammoplasty with the areola-nipple based on an inferior dermal pedicle. *Plast Reconstr Surg* 1977; **59**: 64-67 [PMID: 831241 DOI: 10.1097/00006534-197701000-00011]
- 37 **Georgiade NG**, Serafin D, Morris R, Georgiade G. Reduction mammoplasty utilizing an inferior pedicle nipple-areolar flap. *Ann Plast Surg* 1979; **3**: 211-218 [PMID: 543656 DOI: 10.1097/00000637-197909000-00003]
- 38 **Bolger WE**, Seyfer AE, Jackson SM. Reduction mammoplasty using the inferior glandular "pyramid" pedicle: experiences with 300 patients. *Plast Reconstr Surg* 1987; **80**: 75-84 [PMID: 3602162 DOI: 10.1097/00006534-198707000-00011]
- 39 **Mandrekas AD**, Zambacos GJ, Anastasopoulos A, Hapsas DA. Reduction mammoplasty with the inferior pedicle technique: early and late complications in 371 patients. *Br J Plast Surg* 1996; **49**: 442-446 [PMID: 8983544 DOI: 10.1016/S0007-1226(96)90027-2]
- 40 **Petit JY**, Rietjens M, Contesso G, Bertin F, Gilles R. Contralateral mastopexy for breast reconstruction: a good opportunity for glandular exploration and occult carcinomas diagnosis. *Ann Surg Oncol* 1997; **4**: 511-515 [PMID: 9309343 DOI: 10.1007/BF02303678]
- 41 **Clough KB**, Lewis JS, Couturaud B, Fitoussi A, Nos C, Falcou MC. Oncoplastic techniques allow extensive resections for breast-conserving therapy of breast carcinomas. *Ann Surg* 2003; **237**: 26-34 [PMID: 12496527 DOI: 10.1097/00000658-200301000-00005]
- 42 **Rietjens M**, Urban CA, Rey PC, Mazzarol G, Maisonneuve P, Garusi C, Intra M, Yamaguchi S, Kaur N, De Lorenzi F, Matthes AG, Zurrida S, Petit JY. Long-term oncological results of breast conservative treatment with oncoplastic surgery. *Breast* 2007; **16**: 387-395 [PMID: 17376687 DOI: 10.1016/j.breast.2007.01.008]
- 43 **Giacalone PL**, Roger P, Dubon O, El Gareh N, Rihaoui S, Taourel P, Daurés JP. Comparative study of the accuracy of

- breast resection in oncoplastic surgery and quadrantectomy in breast cancer. *Ann Surg Oncol* 2007; **14**: 605-614 [PMID: 17151794 DOI: 10.1245/s10434-006-9098-5]
- 44 **Gendy RK**, Able JA, Rainsbury RM. Impact of skin-sparing mastectomy with immediate reconstruction and breast-sparing reconstruction with miniflaps on the outcomes of oncoplastic breast surgery. *Br J Surg* 2003; **90**: 433-439 [PMID: 12673744 DOI: 10.1002/bjs.4060]
  - 45 **Olivetto IA**, Rose MA, Osteen RT, Love S, Cady B, Silver B, Recht A, Harris JR. Late cosmetic outcome after conservative surgery and radiotherapy: analysis of causes of cosmetic failure. *Int J Radiat Oncol Biol Phys* 1989; **17**: 747-753 [PMID: 2777664 DOI: 10.1016/0360-3016(89)90061-8]
  - 46 **Mills JM**, Schultz DJ, Solin LJ. Preservation of cosmesis with low complication risk after conservative surgery and radiotherapy for ductal carcinoma in situ of the breast. *Int J Radiat Oncol Biol Phys* 1997; **39**: 637-641 [PMID: 9336143 DOI: 10.1016/S0360-3016(97)00381-7]
  - 47 **Fitoussi AD**, Berry MG, Famà F, Falcou MC, Curnier A, Couturaud B, Reyat F, Salmon RJ. Oncoplastic breast surgery for cancer: analysis of 540 consecutive cases [outcomes article]. *Plast Reconstr Surg* 2010; **125**: 454-462 [PMID: 20124831 DOI: 10.1097/PRS.0b013e3181c82d3e]
  - 48 **Cochrane RA**, Valasiadou P, Wilson AR, Al-Ghazal SK, Macmillan RD. Cosmesis and satisfaction after breast-conserving surgery correlates with the percentage of breast volume excised. *Br J Surg* 2003; **90**: 1505-1509 [PMID: 14648728 DOI: 10.1002/bjs.4344]
  - 49 **Losken A**, Dugal CS, Styblo TM, Carlson GW. A Meta-Analysis Comparing Breast Conservation Therapy Alone to the Oncoplastic Technique. *Ann Plast Surg* 2013; Epub ahead of print [DOI: 10.1097/SAP.0b013e3182605598]
  - 50 **Kronowitz SJ**, Hunt KK, Kuerer HM, Strom EA, Buchholz TA, Ensor JE, Koutz CA, Robb GL. Practical guidelines for repair of partial mastectomy defects using the breast reduction technique in patients undergoing breast conservation therapy. *Plast Reconstr Surg* 2007; **120**: 1755-1768 [PMID: 18090737 DOI: 10.1097/01.prs.0000287130.77835.f6]
  - 51 **Berrino P**, Campora E, Santi P. Postquadrantectomy breast deformities: classification and techniques of surgical correction. *Plast Reconstr Surg* 1987; **79**: 567-572 [PMID: 3823249 DOI: 10.1097/00006534-198704000-00010]
  - 52 **Kroll SS**, Singletary SE. Repair of partial mastectomy defects. *Clin Plast Surg* 1998; **25**: 303-310 [PMID: 9627788]
  - 53 **McCulley SJ**, Macmillan RD. Therapeutic mammoplasty-analysis of 50 consecutive cases. *Br J Plast Surg* 2005; **58**: 902-907 [PMID: 16043153 DOI: 10.1016/j.bjps.2005.03.007]
  - 54 **Thornton BP**, Stewart DH, McGrath PC, Pu LL. Breast reduction as an alternative treatment option for early breast cancer in women with macromastia. *Ann Plast Surg* 2006; **56**: 26-30 [PMID: 16374091 DOI: 10.1097/01.sap.0000183791.51843.40]
  - 55 **Song HM**, Styblo TM, Carlson GW, Losken A. The use of oncoplastic reduction techniques to reconstruct partial mastectomy defects in women with ductal carcinoma in situ. *Breast J* 2010; **16**: 141-146 [PMID: 20102367 DOI: 10.1111/j.1524-4741.2009.00891.x]
  - 56 **Romics L**, Chew BK, Weiler-Mithoff E, Doughty JC, Brown IM, Stallard S, Wilson CR, Mallon EA, George WD. Ten-year follow-up of skin-sparing mastectomy followed by immediate breast reconstruction. *Br J Surg* 2012; **99**: 799-806 [PMID: 22367773 DOI: 10.1002/bjs.8704]
  - 57 **Solin LJ**, Danoff BF, Schwartz GF, Galvin JM, Goodman RL. A practical technique for the localization of the tumor volume in definitive irradiation of the breast. *Int J Radiat Oncol Biol Phys* 1985; **11**: 1215-1220 [PMID: 3997603 DOI: 10.1016/0360-3016(85)90072-0]
  - 58 **Solin LJ**, Chu JC, Larsen R, Fowle B, Galvin JM, Goodman RL. Determination of depth for electron breast boosts. *Int J Radiat Oncol Biol Phys* 1987; **13**: 1915-1919 [DOI: 10.1016/0360-3016(87)90360-9]
  - 59 **Regine WF**, Ayyangar KM, Komarnicky LT, Bhandare N, Mansfield CM. Computer-CT planning of the electron boost in definitive breast irradiation. *Int J Radiat Oncol Biol Phys* 1991; **20**: 121-125 [PMID: 1899658 DOI: 10.1016/0360-3016(91)90147-V]
  - 60 **Poortmans P**, Aznar M, Bartelink H. Quality indicators for breast cancer: revisiting historical evidence in the context of technology changes. *Semin Radiat Oncol* 2012; **22**: 29-39 [PMID: 22177876 DOI: 10.1016/j.semradonc.2011.09.007]
  - 61 **Collette S**, Collette L, Budiharto T, Horiot JC, Poortmans PM, Struikmans H, Van den Bogaert W, Fourquet A, Jager JJ, Hoogenraad W, Mueller RP, Kurtz J, Morgan DA, Dubois JB, Salamon E, Mirimanoff R, Bolla M, Van der Hulst M, Wárlám-Rodenhuis CC, Bartelink H. Predictors of the risk of fibrosis at 10 years after breast conserving therapy for early breast cancer: a study based on the EORTC Trial 22881-10882 'boost versus no boost'. *Eur J Cancer* 2008; **44**: 2587-2599 [PMID: 18757193 DOI: 10.1016/j.ejca.2008.07.032]
  - 62 **Losken A**, Schaefer TG, Newell M, Styblo TM. The impact of partial breast reconstruction using reduction techniques on postoperative cancer surveillance. *Plast Reconstr Surg* 2009; **124**: 9-17 [PMID: 19568039 DOI: 10.1097/PRS.0b013e3181ab10e5]
  - 63 **Roberts JM**, Clark CJ, Campbell MJ, Paige KT. Incidence of abnormal mammograms after reduction mammoplasty: implications for oncoplastic closure. *Am J Surg* 2011; **201**: 611-614 [PMID: 21545908 DOI: 10.1016/j.amjsurg.2011.01.019]
  - 64 **Munhoz AM**, Montag E, Arruda E, Aldrighi CM, Filassi JR, Piatto JR, Prado LC, Aldrighi JM, Gemperli R, Ferreira MC. Immediate reconstruction following breast-conserving surgery: management of the positive surgical margins and influence on secondary reconstruction. *Breast* 2009; **18**: 47-54 [PMID: 19110425 DOI: 10.1016/j.breast.2008.10.005]
  - 65 **Laucirica R**. Intraoperative assessment of the breast: guidelines and potential pitfalls. *Arch Pathol Lab Med* 2005; **129**: 1565-1574 [PMID: 16329729]
  - 66 **Cabioglu N**, Hunt KK, Sahin AA, Kuerer HM, Babiera GV, Singletary SE, Whitman GJ, Ross MI, Ames FC, Feig BW, Buchholz TA, Meric-Bernstam F. Role for intraoperative margin assessment in patients undergoing breast-conserving surgery. *Ann Surg Oncol* 2007; **14**: 1458-1471 [PMID: 17260108 DOI: 10.1245/s10434-006-9236-0]
  - 67 **Obedian E**, Haffty BG. Negative margin status improves local control in conservatively managed breast cancer patients. *Cancer J Sci Am* 2000; **6**: 28-33 [PMID: 10696736]
  - 68 **Tartter PI**, Kaplan J, Bleiweiss I, Gajdos C, Kong A, Ahmed S, Zapetti D. Lumpectomy margins, reexcision, and local recurrence of breast cancer. *Am J Surg* 2000; **179**: 81-85 [PMID: 10773138 DOI: 10.1016/S0002-9610(00)00272-5]
  - 69 **Weinberg E**, Cox C, Dupont E, White L, Ebert M, Greenberg H, Diaz N, Vercel V, Centeno B, Cantor A, Nicosia S. Local recurrence in lumpectomy patients after imprint cytology margin evaluation. *Am J Surg* 2004; **188**: 349-354 [PMID: 15474425 DOI: 10.1016/j.amjsurg.2004.06.024]
  - 70 **Cendán JC**, Coco D, Copeland EM. Accuracy of intraoperative frozen-section analysis of breast cancer lumpectomy-bed margins. *J Am Coll Surg* 2005; **201**: 194-198 [PMID: 16038815 DOI: 10.1016/j.jamcollsurg.2005.03.014]
  - 71 **Nos C**, Fitoussi A, Bourgeois D, Fourquet A, Salmon RJ, Clough KB. Conservative treatment of lower pole breast cancers by bilateral mammoplasty and radiotherapy. *Eur J Surg Oncol* 1998; **24**: 508-514 [PMID: 9870725 DOI: 10.1016/S0748-7983(98)93356-X]
  - 72 **Meretoja TJ**, Svarvar C, Jähkola TA. Outcome of oncoplastic breast surgery in 90 prospective patients. *Am J Surg* 2010; **200**: 224-228 [PMID: 20573334 DOI: 10.1016/



- j.amjsurg.2009.09.026]
- 73 **Haloua MH**, Krekel NM, Winters HA, Rietveld DH, Meijer S, Bloemers FW, van den Tol MP. A systematic review of oncoplastic breast-conserving surgery: current weaknesses and future prospects. *Ann Surg* 2013; **257**: 609-620 [PMID: 23470508 DOI: 10.1097/SLA.0b013e3182888782]
- 74 **Goffman TE**, Schneider H, Hay K, Elkins DE, Schnarrs RA, Carman C. Cosmesis with bilateral mammoreduc-
- tion for conservative breast cancer treatment. *Breast J* 2005; **11**: 195-198 [PMID: 15871705 DOI: 10.1111/j.1075-122X.2005.21610.x]
- 75 **Masetti R**, Di Leone A, Franceschini G, Magno S, Terribile D, Fabbri MC, Chiesa F. Oncoplastic techniques in the conservative surgical treatment of breast cancer: an overview. *Breast J* 2006; **12**: S174-S180 [PMID: 16958998 DOI: 10.1111/j.1075-122X.2006.00331.x]

**P- Reviewers:** Kabir A, Sperti C **S- Editor:** Qi Y  
**L- Editor:** Roemmele A **E- Editor:** Wang CH





百世登  
**Baishideng**®

Published by **Baishideng Publishing Group Co., Limited**

Flat C, 23/F., Lucky Plaza, 315-321 Lockhart Road,

Wan Chai, Hong Kong, China

Fax: +852-31158812

Telephone: +852-58042046

E-mail: [bpgoffice@wjgnet.com](mailto:bpgoffice@wjgnet.com)

<http://www.wjgnet.com>

