

Pleomorphic lobular carcinoma *in situ* of the breast: Can the evidence guide practice?

Andrew Pieri, James Harvey, Nigel Bundred

Andrew Pieri, Wansbeck General Hospital, Northumbria, NE63 9JJ, United Kingdom

James Harvey, Nigel Bundred, Nightingale Centre, University Hospital of South Manchester, Wythenshawe Hospital, Manchester, M23 9LT, United Kingdom

Author contributions: Pieri A, Harvey J and Bundred N designed the review; Pieri A performed the systematic search; Pieri A and Harvey J assessed the quality of the studies; Pieri A analysed the data from the included studies; Pieri A, Harvey J and Bundred N wrote the paper.

Correspondence to: Nigel Bundred, MD, FRCS, Professor of Surgical Oncology, Nightingale Centre, University Hospital of South Manchester, Wythenshawe Hospital, Southmoor Road, Manchester, M23 9LT,

United Kingdom. nigel.j.bundred@manchester.ac.uk

Telephone: +44-161-2915859 Fax: +44-161-2915860

Received: February 22, 2014 Revised: April 20, 2014

Accepted: June 10, 2014

Published online: August 10, 2014

Abstract

The clinical significance of pleomorphic lobular carcinoma *in situ* (PLCIS) is a subject of controversy. As a consequence, there is a risk of providing inconsistent management to patients presenting with PLCIS. This review aims to establish whether the current guidelines for the management of PLCIS are consistent with current evidence. A systematic electronic search was performed to identify all English language articles regarding PLCIS management. The data was analysed, specifically looking at: incidence of concurrent disease, recurrence rates, long-term prognosis and PLCIS management. A search was also performed for PLCIS management guidelines for the United Kingdom, United States, Canada, Australia, Germany and pan-European. The results of the evidence analyses were compared to the guidelines in order to establish whether the recommended management is consistent with the published evidence. Nine studies (level 3-4 evidence), involving a total of 176 patients and five management guidelines

(from United Kingdom, United States, Australia and pan-European) were included in the review. From the evidence, 46 of 93 (49%) patients were found to have PLCIS with concurrent invasive disease on excision specimen analysis. Regarding recurrence rates, 11 of 117 (9.4%) patients developed a recurrence of PLCIS. There were no instances of invasive disease or ductal carcinoma *in situ* (DCIS) on recurrence histology. There were no studies assessing long-term outcomes in PLCIS cases. With regards to the management guidelines, the Association of Breast Surgery (United Kingdom) and the National Breast and Ovarian Cancer Care (Australia) do not mention PLCIS. The National Comprehensive Cancer Network (United States) suggest considering excision of PLCIS with negative margins. The NHS Breast Screening Programme (United Kingdom) and the European Society of Medical Oncology (pan-European) recommend PLCIS should be treated as with DCIS. We conclude that high quality evidence to inform guidance is lacking, thus recommendations are relatively vague. However, based on the available evidence, it would seem prudent to treat PLCIS in a similar manner to DCIS.

© 2014 Baishideng Publishing Group Inc. All rights reserved.

Key words: Pleomorphic lobular carcinoma *in situ*; Breast cancer; Breast carcinoma; Carcinoma *in situ*; Guideline; Excision margin; Recurrence rate

Core tip: Pleomorphic lobular carcinoma *in situ* (PLCIS) is a breast lesion, the clinical significance of which is a subject of controversy. To date, this systematic review is the largest pooled series of clinical data regarding PLCIS. We aimed to establish whether current guidelines for management are consistent with the evidence. The results demonstrate a lack of high quality data and guidelines for management are variable. Analysis revealed a high incidence of concurrent invasive disease with PLCIS (49%) and following excision, a recurrence rate of 9.4%. We conclude that it would seem prudent

to manage PLCIS as with ductal carcinoma *in situ*, although there is a dire need for long-term outcome studies.

Pieri A, Harvey J, Bundred N. Pleomorphic lobular carcinoma *in situ* of the breast: Can the evidence guide practice? *World J Clin Oncol* 2014; 5(3): 546-553 Available from: URL: <http://www.wjgnet.com/2218-4333/full/v5/i3/546.htm> DOI: <http://dx.doi.org/10.5306/wjco.v5.i3.546>

INTRODUCTION

The pleomorphic subtype of lobular carcinoma *in situ* (PLCIS) was first described by Frost *et al*^[1] in 1996. Frost described the lesion as being composed of one or multiple distended lobules with enlarged and dyscohesive cells, irregularly shaped nuclei and abundant eosinophilic cytoplasm^[1]. PLCIS is also regularly associated with comedo necrosis and calcification and hence is often mammographically detectable, in contrast to classical LCIS (CLCIS)^[1-5]. The clinical significance of PLCIS is a subject of controversy. It is generally accepted to be a risk factor for invasive disease, as with CLCIS. However, there is a suspicion that PLCIS may carry a higher risk of progression to invasive disease due to its more aggressive molecular and histopathological features, which are more consistent with those of ductal carcinoma *in situ* (DCIS) than CLCIS^[1,2]. There is an acceptance that PLCIS should be considered a non-obligate precursor to invasive disease and managed in a similar way to DCIS, though this is largely based on the histopathological similarities rather than studies providing evidence on clinical outcomes^[1,6].

It has historically been difficult to differentiate PLCIS from DCIS due to the similarities in their histomorphology. Due to recent advances in immunohistochemical staining differentiating PLCIS from DCIS has become much more achievable. Use of E-cadherin immunohistochemistry can differentiate between DCIS and LCIS^[7,8]; E-cadherin is a cell adhesion molecule, expression of which is lost in lobular neoplasia but retained in ductal. As a consequence, there has been an increase in the number of PLCIS cases reported^[9].

There are multiple reviews relating to PLCIS in the literature, but they are predominantly narrative in nature^[6,9-14]. Hussain *et al.* published the only systematic review to date that includes clinical data regarding PLCIS^[12]. However, this review included only 22 PLCIS cases. Compared to CLCIS and atypical lobular hyperplasia (ALH), they demonstrated that PLCIS is the most likely to have concurrent malignancy on excision specimen (41% of PLCIS being associated with malignancy compared with 19% in ALH ($P = 0.003$). Since the Hussain *et al*^[12] systematic review there has been a large increase in the published literature for PLCIS. Guidance on the management of PLCIS may be historical, based on a small number of reported cases. The aim of this systematic re-

view is to compare the current evidence base for PLCIS with international guidance on its management.

SEARCH STRATEGY: EVIDENCE

This systematic review was conducted in line with the Preferred Reporting Items for Systematic Reviews and Meta-analyses (PRISMA) Guidelines. Electronic literature search of Medline, Embase, the Cochrane database, and the WHO International Clinical Trials Registry Platform were performed by a single author (AP). Search terms were “pleomorphic lobular carcinoma *in situ*”, “pleomorphic lobular carcinoma *in-situ*” and “PLCIS”. Articles were then selected based on title and abstract and then on the full text manuscript. A manual search of the references from key articles was also performed to identify any articles potentially missed by the systematic search.

The search was limited to human studies published in English, from 1996 onwards. The search was conducted in October 2013. We excluded editorials, case reports, reviews and letters or comments, and case series with less than five patients. Small studies (less than five patients) were excluded to focus the review on studies that would more likely influence practice.

SEARCH STRATEGY: GUIDELINES

In order to obtain a global representation of management guidelines for PLCIS, searches were performed for the United States, Canada, United Kingdom, Germany, pan-European and Australia. Electronic literature search of Medline and Embase were performed by a single author (AP). Search terms were “guideline” AND “breast cancer” AND the respective country (“United States”, “Great Britain”, “Canada”, “Australia” and “Europe”). National oncology, pathology and surgical societies, colleges, associations and governing bodies were also manually searched for each country. Independent organisations’ websites were searched for guidelines for breast cancer management. For the United Kingdom, the National Institute for Health and Care Excellence^[15], the Association of Breast Surgery^[16] and the National Health Service Breast Screening Program^[17] sites were searched. For the United States, the American Society of Clinical Oncology^[18], the College of American Pathologists^[19], the National Comprehensive Cancer Network^[20], the American College of Surgeons^[21] and the Society of Surgical Oncology^[22] websites were searched. For Canada, the Royal College of Physicians and Surgeons of Canada^[23], the Breast Cancer Society of Canada^[24], the Canadian Cancer Society^[25] and the Cancer Care Ontario (CCO)^[26] websites were searched. For Australia, the Cancer Australia and National Breast and Ovarian Cancer Care^[27] site was searched. For Germany, the German Cancer Society^[28] website was searched. Pan-European guidelines were searched for on the European Society of Medical Oncology^[29] website. Google search engine was used and Google Translate was used for non-English websites.

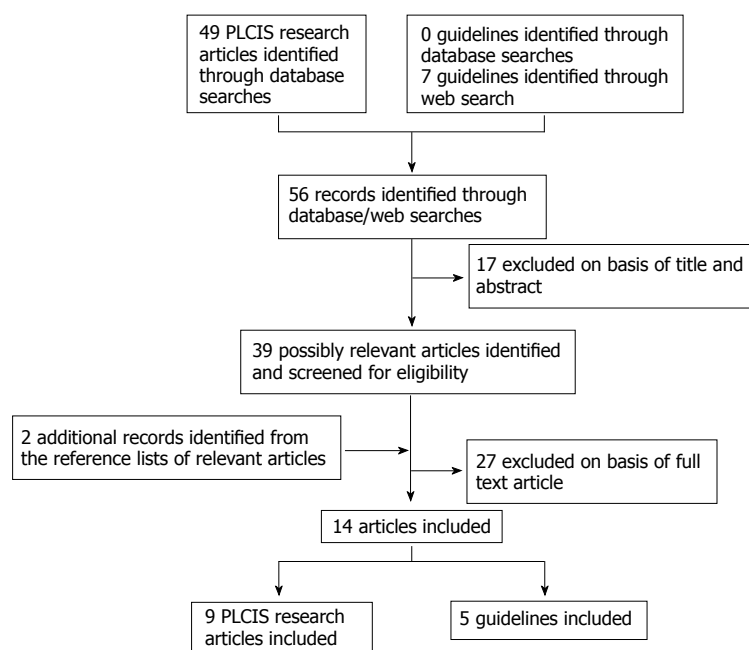


Figure 1 Study selection. PLCIS: Pleomorphic lobular carcinoma *in situ*.

Guidelines that did not have a version available in English were excluded. Guidelines that were specific to invasive disease (*i.e.*, did not give recommendations regarding *in situ* disease) were excluded.

DATA ANALYSIS

AP extracted data and JH and AP assessed its quality. Disagreements were resolved by discussion and study review. The following topics were specifically considered: incidence of concurrent invasive disease, recurrence rate of disease, long-term prognosis and the management of PLCIS alone.

DESCRIPTION OF STUDIES AND GUIDELINES

There were nine research articles and five guidelines that met the inclusion criteria (Figure 1). The nine studies involve a total of 176 patients. There were no meta-analyses, randomised control trials or cohort studies. All studies were case series, with data collected retrospectively. The dates of publication ranged from 2000 to 2013. Seven of the studies (93 patients) aimed to determine the risk of concurrent invasive carcinoma or DCIS on excision specimen, following a core needle biopsy diagnosis of PLCIS. Three studies (117 patients) documented recurrence rates in PLCIS. There are no studies published to date that investigate comparative treatment options, or oncological outcomes such as local and systemic recurrence disease in PLCIS patients.

Guidelines for “*in-situ*” breast disease management were found for the United Kingdom (Association of Breast Surgery and NHS Breast Screening Programme), United States (National Comprehensive Cancer Network), Canada (Cancer Care Ontario), Australia (National

Breast and Ovarian Cancer Care), Germany (German Cancer Society) and pan-European (European Society of Medical Oncology). An English version of the German guidelines could not be found and thus was excluded. The Canadian guidelines were pertaining to invasive disease only and thus were excluded.

INCIDENCE OF CONCURRENT INVASIVE DISEASE

The risk of concurrent invasive disease was based on the pooled data from seven studies, involving 93 patients^[3,4,30-34]. All patients were women, with a mean age of 58.4 years at PLCIS diagnosis (age range 35-84 years). Of those with a documented mode of presentation, 40 (91%) patients presented after a screen-detected abnormality and 4 (9%) had a symptomatic lump. Initial core biopsy results showed PLCIS as the most significant lesion in 58 (62%) cases and PLCIS with DCIS or invasive carcinoma in 35 (38%) cases. The breakdown of number of patients diagnosed with concurrent PLCIS with DCIS, and PLCIS and invasive carcinoma on core biopsy are not specified. After core biopsy, all patients went on to have surgery: 2 had a diagnostic biopsy, 67 had a wide local excision, 8 had a segmental mastectomy, 15 had a mastectomy and 1 patient had a bilateral mastectomy (reason not stated). On surgical specimen histology, 34 (37%) patients had PLCIS alone and 59 (63%) patients were found to have concurrent DCIS or invasive carcinoma (Table 1). Of these patients with DCIS or invasive disease; 13 (22%) were DCIS, 7 (12%) were invasive ductal carcinoma, 26 (44%) were invasive lobular carcinoma and 13 (22%) were invasive carcinoma with type not specified. The risk of concurrent invasive disease was 49% (46 of 93 patients). Looking specifically at the risk of upstaging from a core biopsy result of PLCIS only,

Table 1 Risk that ductal carcinoma *in situ* or invasive carcinoma is found on subsequent surgical excision pathology following a core biopsy diagnosis of pleomorphic lobular carcinoma *in situ*

Ref.	No. of PLCIS cases	Diagnosis on core biopsy	Surgical procedure	PLCIS alone on surgical specimen	Concurrent DCIS or invasive carcinoma on surgical specimen	Concurrent DCIS (%)	Concurrent invasive cancer (%)
Carder <i>et al</i> ^[4]	10	10 PLCIS	2 DB, 8 WLE	7	3 ILC	0	30
Chivukula <i>et al</i> ^[3]	12	12 PLCIS	1 DB, 1 WLE, 8 SMx, 1Mx, 1BMx	9	3 ILC	0	25
Fasola <i>et al</i> ^[30]	34	13 PLCIS 21 PLCIS + DCIS or IC	PLCIS: 11 WLE, 2 Mx PLCIS with DCIS or IC: 9 WLE, 12 Mx	4	9 DCIS 15 ILC 6 IDC	26	62
Morris <i>et al</i> ^[31]	17	3 PLCIS 7 PLCIS + DCIS 7 PLCIS + IC	17 WLE	3	3 DCIS 11 IC	18	65
Niell <i>et al</i> ^[32]	5	5 PLCIS	5 WLE	1	1 DCIS 2 ILC 1 IDC	20	60
Georgian-Smith <i>et al</i> ^[33]	5	5 PLCIS	5 WLE	3	2 IC	0	40
Lavoue <i>et al</i> ^[34]	10	10 PLCIS	10 WLE	7	3 ILC	0	30
Total	93	58 PLCIS 7 PLCIS + DCIS 7 PLCIS + IC 21 PLCIS + DCIS or IC		34	13 DCIS 26 ILC 7 IDC 13 IC	14	49

At initial assessment PLCIS is diagnosed on a core biopsy specimen, this table details the subsequent histology from a surgical resection of the area, demonstrating how many of the core biopsies are upgraded to invasive carcinoma or DCIS. PLCIS: Pleomorphic lobular carcinoma *in situ*; DCIS: Ductal carcinoma *in situ*; ILC: Invasive lobular carcinoma; IDC: Invasive ductal carcinoma; IC: Invasive carcinoma (with type not specified); DB: Diagnostic biopsy; WLE: Wide local excision; Mx: Mastectomy; SMx: Segmental mastectomy; BMx: Bilateral mastectomy.

to invasive disease on surgical specimen, data from five of the studies were used (in two studies, the correlation between core biopsy specimen and respective surgical specimen is unclear^[30,31]). Of 42 patients with PLCIS only on core biopsy, 14 were upstaged to invasive carcinoma on surgical specimen histology (33%).

RECURRENCE RATE OF DISEASE

There are three articles reporting recurrence rates following excision of PLCIS^[5,30,35]. Downs-Kelly *et al*^[5] report a retrospective series of 26 patients with PLCIS on surgical excision. They included both patients with PLCIS alone (20 cases) and patients with PLCIS and concurrent invasive disease where excision margin for the invasive component was more than 10 mm (6 cases). Patients were offered adjuvant chemoprevention and/or radiotherapy. The article does not state which chemoprevention agents were used. Of the six PLCIS cases with concurrent invasive disease, one had adjuvant radiotherapy and five had both chemoprevention and radiotherapy. Of the 20 cases of PLCIS alone, three patients received radiotherapy, six had chemoprevention and one received both chemoprevention and radiotherapy. The authors state that three of the cases of PLCIS alone had been misdiagnosed as DCIS at the time of treatment and thus received adjuvant therapy. The rationale for the remaining seven cases of PLCIS alone whom received adjuvant treatment is unclear. Downs-Kelly *et al*^[5] report one episode of recurrent PLCIS at 19 mo (3.8% recurrence rate). The recurrence was biopsy-diagnosed following a mammogram with new suspicious calcification at the surgical site (patient had

previous normal mammograms at 7 and 12 mo). Of note at initial excision, PLCIS was present at the margin. The patient had received adjuvant chemotherapy after the initial excision but no radiotherapy (Table 2).

Khoury *et al*^[35] report a series of 57 PLCIS cases and compare their recurrence rate to that of 615 cases of DCIS, who had presented over the same 12-year period. Their data shows 7 episodes of recurrent PLCIS with no invasive disease (12.3% recurrence rate). This series reports that the recurrence rate was higher in younger women and in cases where the margin remained positive for CLCIS ($P = 0.02$ and 0.01 respectively). PLCIS had a higher rate of recurrence than low and intermediate grade DCIS cases observed in the study ($P = 0.06$ and 0.04 respectively). It is not stated as to whether margin clearance was the same for DCIS and PLCIS cases. The margin status for PLCIS recurrences and the time to recurrences are not reported. Fasola *et al*^[30] consider the role of radiotherapy in PLCIS, comparing 13 patients with a diagnosis of PLCIS alone and 21 patients with PLCIS in the setting of invasive carcinoma. Patients with PLCIS alone were more frequently treated with lumpectomy as opposed to mastectomy (85% *vs* 43%, $P = 0.03$) and none of the PLCIS only patients received adjuvant radiotherapy or chemotherapy compared to 16 (76%) of the patients with PLCIS and invasive disease receiving radiotherapy and/or chemotherapy. They report that local recurrence rate in the PLCIS only group is 15% compared with 5% in the PLCIS and carcinoma group ($P = 0.8$). The comparative adequacy of margin clearance is not stated for the two groups. However, they conclude that this increased rate of recurrence may be a result of the

Table 2 Rate of recurrent disease after surgical excision of pleomorphic lobular carcinoma *in situ*

Ref.	No. of PLCIS cases	PLCIS at margin	Histology of recurrence	Time to recurrence	Local recurrence rate
Downs-Kelly <i>et al</i> ^[5]	26	13 cases ≤ 1 mm 4 cases 1.1-2 mm 9 cases > 2 mm	1 PLCIS	19 mo	3.8%
Khoury <i>et al</i> ^[35]	57	Not stated	7 PLCIS	Not stated	12.3%
Fasola <i>et al</i> ^[30]	34	Not stated	3 PLCIS	≤ 5 yr	8.85

This details the number of cases of histologically diagnosed recurrence following a previous excision of PLCIS. PLCIS: Pleomorphic lobular carcinoma *in situ*.

less aggressive adjuvant therapy and there may be a role for radiotherapy in PLCIS. They report an overall 5-year recurrence rate of 8.8% (3 of 34 patients) for PLCIS.

Combining the data from the three studies gives a PLCIS recurrence rate of 9.4% (11 of 117 cases) regardless of margin (not reported in all cases). There were no cases reported where invasive disease was found on recurrence specimens in any of the three studies.

REVIEW OF NATIONAL GUIDELINES FOR MANAGEMENT

A total of 5 national guidelines (United Kingdom, United States, Australian and pan-European) were found that met the inclusion criteria and are summarised in Table 3. Associated guidelines for management of CLCIS and DCIS by the same organisations are included in the Table for comparison.

There is no mention of PLCIS in the Association of Breast Surgery and National Breast and Ovarian Cancer Care guidance. The National Comprehensive Cancer Network suggest considering resection of PLCIS with negative margins. The European Society of Medical Oncology recommend that PLCIS should be managed as with DCIS and similarly, the NHS Breast Screening Programme recommend grading PLCIS on core biopsy as B5a, *i.e.*, non-invasive carcinoma (in contrast to CLCIS which is graded as B3 indeterminate) and excising with negative margins.

EVIDENCE QUALITY

There are significant limitations to this review, currently there is a lack of quality evidence supporting the management of PLCIS, the majority being level 3-4 evidence^[36]. There are no management comparison studies measuring long-term survival and very limited data on recurrence rates. Nonetheless, there are significant findings within the data available. This is the only systematic review to focus specifically on PLCIS management and with 173 cases, this is the largest pooled series of clinical data regarding PLCIS.

ASSOCIATION OF PLCIS WITH INVASIVE DISEASE

PLCIS is associated with invasive lobular carcinoma on

excision in at least 28% of cases (26 of the 93 cases, but in 13 more cases of associated invasive carcinoma, the type is not reported). When DCIS is diagnosed on core biopsy there is a 10%-20% risk of associated invasive carcinoma on subsequent excision^[37-40]. By comparison with DCIS, this study demonstrates PLCIS to have a higher association with its invasive counterpart. Reis-Filho *et al*^[41] identified that invasive pleomorphic carcinoma and its *in situ* counterpart share the same genetic changes, supporting the argument that PLCIS is a precursor lesion (rather than simply a risk factor) of invasive disease. The high rate of upstaging of PLCIS to invasive disease seen in this review further supports the “non-obligate precursor” hypothesis. These findings suggest that it would not only be advisable to perform a surgical biopsy for PLCIS to look for associated malignancy, but to ensure excision with margins negative for PLCIS. Thus, a grading of pre-invasive (B5a) similar to DCIS would seem appropriate.

SENTINEL NODE BIOPSY AND PLCIS

For pure DCIS on core biopsy, the Association of Breast Surgery recommend that sentinel lymph node biopsy should be considered in cases where there is a high risk of finding invasive disease on the subsequent excision specimen^[42]. They state that this would include patients undergoing surgery for: an extensive area of microcalcification; a palpable mass; or high grade disease. In this review, the overall rate of concurrent invasive disease associated with PLCIS was found to be 49%. In 67% of these cases, the invasive component was missed on core biopsy and thus wasn't diagnosed until analysis of the surgical specimen. Given the high risk of upgrading PLCIS to invasive disease after definitive surgery, combined with the fact that histologically, PLCIS is considered to have a similar appearance and characteristics to high grade DCIS, sentinel node biopsy should be considered in PLCIS.

ADJUVANT THERAPY FOR PLCIS

There are no studies that consider the role of adjuvant chemoprevention in PLCIS. Fasola *et al*^[30] assessed whether there is a potential role for radiation therapy in PLCIS by looking at the comparative recurrence rates^[30]. However, they demonstrated no significant difference between the radiation therapy and non-radiation therapy groups.

Table 3 Summary of guidelines for the management of *in situ* breast disease

Guideline source	Recommendation-PLCIS	Recommendation-CLCIS	Recommendation-DCIS
ABS, 2009 ^[16] (United Kingdom)	PLCIS not mentioned	Should consider diagnostic biopsy Clear margins not required Post-op surveillance is appropriate (No adjuvant treatment mentioned) (No lymph node surgery required)	Resection with clear margins (> 1 mm) required (WLE or Mx) Intra-op radiography should be used for all DCIS as majority impalpable Lymph node surgery not usually required but may be considered in high risk cases
NCCN, 2013 ^[20] (United States)	"Consider excision with negative margins"	Diagnostic biopsy Risk reducing treatment discussion with patient (options: risk reducing surgery, hormone therapy, no further treatment) Surveillance indicated	Consider MRI WLE or Mx Margin controversial but certainly > 1 mm SLNB usually not required but may be considered in high risk cases Consider RTx
ESMO, 2013 ^[29] (pan-European)	"May behave similarly to DCIS and should be treated accordingly"	Risk factor for future development of invasive cancer and does not require active treatment	Resection with clear margin (≥ 2 mm) required (WLE or Mx) SLNB usually not required but may be considered in high risk cases
NBOCC, 2003 ^[27] (Australia)	PLCIS not mentioned	Consider surgical biopsy Surveillance ≥ 15 yr No role for clear margin excision established	Clear margin excision Usually adjuvant RTx Consider hormone therapy
NHSBSP "In situ lobular neoplasia: overview and recommendations" [pending publication] ^[17] (United Kingdom)	Should be classified B5a (as with DCIS) and excised with negative margins	Merits MDT discussion and usually diagnostic biopsy	

ABS: Association of Breast Surgery; NCCN: National Comprehensive Cancer Network; ESMO: European Society of Medical Oncology; NBOCC: National Breast and Ovarian Cancer Care; NHSBSP: National Health Service Breast Screening Programme. PLCIS: Pleomorphic lobular carcinoma *in situ*; DCIS: Ductal carcinoma *in situ*.

ARGUMENT FOR MRI IN PLCIS CASES

Invasive lobular carcinoma is associated with over a quarter of the PLCIS cases, it is more frequently multifocal and bilateral compared with ductal carcinoma^[43,44]. Consequently, MRI is often performed pre-operatively in known lobular carcinomas in order to better assess the extent of disease and thus reduce re-excision rates. MRI may have a future role in imaging of patients with PLCIS due to the high rate of upstaging from PLCIS to invasive lobular carcinoma.

RECURRENCE RATES AFTER PLCIS EXCISION

Safety of PLCIS management ultimately can be determined by recurrence rates. No conclusions could be drawn from a small sample size of 173 cases, especially given the heterogeneous mix of margin management and adjuvant therapies. Information on recurrence is also not stated in all series. Using DCIS again as a comparator, Boyages *et al* reported that after excision, 43% of local recurrences were invasive, not *in situ*^[45]. In this review, there were no episodes of invasive disease on recurrence - only PLCIS.

PLCIS MANAGEMENT GUIDELINES

Looking at the guidelines for management, PLCIS is not mentioned in the Association of Breast Surgery or the

National Breast and Ovarian Cancer Care publications. These guidelines were last updated in 2009 and 2003 respectively and thus pre-date the majority of the evidence regarding PLCIS. Thus, it is no surprise that PLCIS does not feature. The National Comprehensive Cancer Network publication (2013) states that PLCIS may have a similar behaviour to DCIS, and proposes that negative margin excision should be considered. Qualification of this statement is made by explaining that the outcome data regarding the efficacy of surgical excision to negative margins is lacking. This guidance is certainly consistent with the data reviewed. The NHS Breast Screening Programme (pending publication) and the European Society of Medical Oncology (2013) make similar statements that PLCIS may behave similarly to DCIS and should be excised with negative margins. The European Society of Medical Oncology also states, with regards to *in situ* lobular neoplasia, "radiotherapy is not warranted, perhaps with the exception of the pleomorphic subtype". This statement is presumably made, based on the histomorphological similarities between DCIS and PLCIS, thus using DCIS-based data as surrogate evidence, but there is no data regarding the clinical efficacy of radiotherapy for PLCIS directly. The lack of guidance from many National and International organisations on the management of PLCIS reflects the lack of data on which to support treatment guidance. The few guidelines that do pertain to PLCIS generally recommend excision with no clear definition of margin width.

CURRENT VARIATIONS IN PRACTICE

Blair *et al.*^[46] recently published a survey completed by surgeons in the United States, regarding the management of positive margins in PLCIS cases. They report considerable heterogeneity in the management. Only 24% felt they would always wish to re-excite PLCIS at the margin. The survey did not address the reasons for the varied responses, but they postulate that it may be due to a lack of familiarity with this unusual variant of LCIS or an active decision to await better evidence to inform further intervention. Either way, such diversity in responses suggests a requirement for clearer evidence and guidance.

PLCIS has historically been a rarely diagnosed phenomenon. In the past, some cases will undoubtedly have been diagnosed as DCIS due to its histological similarities. However, due to the relatively recent universal use of E-cadherin immunostaining, combined with the ever-growing numbers in breast screening programs, PLCIS is likely to become a more frequent diagnosis. Its clinical characteristics remain largely unknown, but are not entirely consistent with either DCIS or CLCIS. Thus independent, clear guidelines for the management of PLCIS are required, although there remains a need for quality evidence on a national and international scale, to inform practice.

CONCLUSION

There is a lack of quality evidence to inform guidance on the management of PLCIS. The limited data demonstrates a high rate of concurrent invasive disease associated with PLCIS. Based on the available evidence, it would seem safe to surgically excise PLCIS in a similar manner to DCIS. There is no evidence on the efficacy of adjuvant treatments. As with high grade DCIS, a sentinel lymph node biopsy may be considered at the time of excision.

REFERENCES

- 1 **Frost AR**, Tsangaris TN, Silverberg SG. Pleomorphic lobular carcinoma in situ. *Pathol Case Rev* 1996; **1**: 27-30 [DOI: 10.1097/00132583-199605000-00009]
- 2 **Chen YY**, Hwang ES, Roy R, DeVries S, Anderson J, Wa C, Fitzgibbons PL, Jacobs TW, MacGrogan G, Peterse H, Vincent-Salomon A, Tokuyasu T, Schnitt SJ, Waldman FM. Genetic and phenotypic characteristics of pleomorphic lobular carcinoma in situ of the breast. *Am J Surg Pathol* 2009; **33**: 1683-1694 [PMID: 19701073 DOI: 10.1097/PAS.0b013e3181b18a89]
- 3 **Chivukula M**, Haynik DM, Brufsky A, Carter G, Dabbs DJ. Pleomorphic lobular carcinoma in situ (PLCIS) on breast core needle biopsies: clinical significance and immunoprofile. *Am J Surg Pathol* 2008; **32**: 1721-1726 [PMID: 18769331 DOI: 10.1097/PAS.0b013e31817dc3a6]
- 4 **Carder PJ**, Shaaban A, Alizadeh Y, Kumaraswamy V, Liston JC, Sharma N. Screen-detected pleomorphic lobular carcinoma in situ (PLCIS): risk of concurrent invasive malignancy following a core biopsy diagnosis. *Histopathology* 2010; **57**: 472-478 [PMID: 20727019 DOI: 10.1111/j.1365-2559.2010.03634.x]
- 5 **Downs-Kelly E**, Bell D, Perkins GH, Sneige N, Middleton LP. Clinical implications of margin involvement by pleomorphic lobular carcinoma in situ. *Arch Pathol Lab Med* 2011; **135**: 737-743 [PMID: 21631266 DOI: 10.1043/2010-0204-OA.1]
- 6 **Contreras A**, Sattar H. Lobular neoplasia of the breast: an update. *Arch Pathol Lab Med* 2009; **133**: 1116-1120 [PMID: 19642738 DOI: 10.1043/1543-2165-133.7.1116]
- 7 **Bratthauer GL**, Moinfar F, Stamatakis MD, Mezzetti TP, Shekitka KM, Man YG, Tavassoli FA. Combined E-cadherin and high molecular weight cytokeratin immunoprofile differentiates lobular, ductal, and hybrid mammary intraepithelial neoplasias. *Hum Pathol* 2002; **33**: 620-627 [PMID: 12152161 DOI: 10.1053/hupa.2002.124789]
- 8 **Vos CB**, Cleton-Jansen AM, Bex G, de Leeuw WJ, ter Haar NT, van Roy F, Cornelisse CJ, Peterse JL, van de Vijver MJ. E-cadherin inactivation in lobular carcinoma in situ of the breast: an early event in tumorigenesis. *Br J Cancer* 1997; **76**: 1131-1133 [PMID: 9365159 DOI: 10.1038/bjc.1997.523]
- 9 **Carder PJ**, Shaaban AM. Pleomorphic lobular carcinoma in situ. *Diagn Histopathol* 2012; **18**: 119-123 [DOI: 10.1016/j.mpdhp.2011.12.005]
- 10 **Chivukula M**. Pleomorphic lobular carcinoma in situ: A divergent entity with emerging significance. *Oncology (Williston Park)* 2011; **25**: 358, 360, 362 [PMID: 21618958]
- 11 **Fulford LG**, Reis-Filho JS, Lakhani SR. Lobular in situ neoplasia. *Cur Diagn Pathol* 2004; **10**: 183-92 [DOI: 10.1016/j.cdip.2003.11.003]
- 12 **Hussain M**, Cunnick GH. Management of lobular carcinoma in-situ and atypical lobular hyperplasia of the breast--a review. *Eur J Surg Oncol* 2011; **37**: 279-289 [PMID: 21306860 DOI: 10.1016/j.ejso.2011.01.009]
- 13 **Middleton LP**. The diagnosis of pleomorphic lobular carcinoma in situ warrants complete excision with negative margins. *Cur Breast Cancer Rep* 2012; **4**: 96-101 [DOI: 10.1007/s12609-012-0072-x]
- 14 **Murray M**, Brogi E. Lobular Carcinoma in Situ, Classical Type and Unusual Variants. *Surgical Pathology Clinics* 2009; **2**: 273-99 [DOI: 10.1016/j.path.2009.02.001]
- 15 National Institute for Health and Care Excellence. Available from: URL: <http://www.nice.org.uk/>. Accessed Nov 28, 2013
- 16 Association of Breast Surgery. Available from: URL: <http://www.associationofbreastsurgery.org.uk>. Accessed Nov 28, 2013
- 17 NHS Breast Screening Programme (NHSBSP). Available from: URL: <http://www.cancerscreening.nhs.uk/breast-screen/>. Accessed Nov 28, 2013
- 18 American Society of Clinical Oncology. Available from: URL: <http://www.asco.org>. Accessed Nov 28, 2013
- 19 College of American Pathologists. Available from: URL: <http://www.cap.org>. Accessed Nov 28, 2013
- 20 National Comprehensive Cancer Network. Available from: URL: <http://www.nccn.org>. Accessed Nov 28, 2013
- 21 American College of Surgeons. Available from: URL: <http://www.facs.org>. Accessed Nov 28, 2013
- 22 Society of Surgical Oncology. Available from: URL: <http://www.surgonc.org>. Accessed Nov 28, 2013
- 23 Royal College of Physicians and Surgeons of Canada. Available from: URL: <http://www.royalcollege.ca>. Accessed Nov 28, 2013
- 24 The Breast Cancer Society of Canada. Available from: URL: <http://www.bccsc.ca>. Accessed Nov 28, 2013
- 25 Canadian Cancer Society. Available from: URL: <http://www.cancer.ca>. Accessed Nov 28, 2013
- 26 Cancer Care Ontario. Available from: URL: <http://www.cancercare.on.ca>. Accessed Nov 28, 2013
- 27 Cancer Australia. Available from: URL: <http://canceraustralia.gov.au>. Accessed Nov 28, 2013
- 28 German Cancer Society. Available from: URL: <http://www.krebsgesellschaft.de/>. Accessed Nov 28, 2013

- 29 European Society of Medical Oncology. Available from: URL: <http://www.esmo.org>. Accessed Nov 28, 2013
- 30 **Fasola CE**, Jensen KC, Horst KC. Local regional recurrence among patients with pleomorphic lobular carcinoma in situ: Is there a role for radiation therapy? *Int J Radiat Oncol Biol Phys* 2012; **1**: S238 [DOI: 10.1016/j.ijrobp.2012.07.618]
- 31 **Morris K**, Howe M, Kirwan C, Harvey J. Clinical and phenotypic characteristics of core biopsy diagnosed pleomorphic lobular carcinoma-in-situ in a UK population (PLCIS). *Eur J Surg Oncol* 2013; **39**: 484 [DOI: 10.1016/j.ejso.2013.01.118]
- 32 **Niell B**, Specht M, Gerade B, Rafferty E. Is excisional biopsy required after a breast core biopsy yields lobular neoplasia? *AJR Am J Roentgenol* 2012; **199**: 929-935 [PMID: 22997389 DOI: 10.2214/AJR.11.8447]
- 33 **Georgian-Smith D**, Lawton TJ. Calcifications of lobular carcinoma in situ of the breast: radiologic-pathologic correlation. *AJR Am J Roentgenol* 2001; **176**: 1255-1259 [PMID: 11312190 DOI: 10.2214/ajr.176.5.1761255]
- 34 **Lavoué V**, Graesslin O, Classe JM, Fondrinier E, Angibeau H, Levêque J. Management of lobular neoplasia diagnosed by core needle biopsy: study of 52 biopsies with follow-up surgical excision. *Breast* 2007; **16**: 533-539 [PMID: 17629481 DOI: 10.1016/j.breast.2007.04.005]
- 35 **Khoury T**, Karabakhtsian R, Yan L, Syriac S, Liu S, Desouki MM. Pleomorphic lobular carcinoma in situ of the breast: Clinicopathological review of 57 cases and a proposed new histopathologic classification. *Lab Invest* 2013; **93**: 49A [DOI: 10.1038/labinvest.2013.14]
- 36 **Harbour R**, Miller J. A new system for grading recommendations in evidence based guidelines. *BMJ* 2001; **323**: 334-336 [DOI: 10.1136/bmj.323.7308.334]
- 37 **Chan MYP**, Lim S. Predictors of invasive breast cancer in ductal carcinoma in situ initially diagnosed by core biopsy. *Asian J Surg* 2010; **33**: 76-82 [DOI: 10.1016/S1015-9584(10)60013-9]
- 38 **Yen TW**, Hunt KK, Ross MI, Mirza NQ, Babiera GV, Meric-Bernstam F, Singletary SE, Symmans WF, Giordano SH, Feig BW, Ames FC, Kuerer HM. Predictors of invasive breast cancer in patients with an initial diagnosis of ductal carcinoma in situ: a guide to selective use of sentinel lymph node biopsy in management of ductal carcinoma in situ. *J Am Coll Surg* 2005; **200**: 516-526 [PMID: 15804465 DOI: 10.1016/j.jamcollsurg.2004.11.012]
- 39 **Cox CE**, Nguyen K, Gray RJ, Salud C, Ku NN, Dupont E, Hutson L, Peltz E, Whitehead G, Reintgen D, Cantor A. Importance of lymphatic mapping in ductal carcinoma in situ (DCIS): why map DCIS? *Am J Surg* 2001; **67**: 513-519
- 40 **Brinkmann E**, Rademaker A, Morrow M. Is sentinel lymph node biopsy (SLNB) for ductal carcinoma in situ (DCIS) justified? *Ann Surg Oncol* 2002; **9**
- 41 **Reis-Filho JS**, Simpson PT, Jones C, Steele D, Mackay A, Irvani M, Fenwick K, Valgeirsson H, Lambros M, Ashworth A, Palacios J, Schmitt F, Lakhani SR. Pleomorphic lobular carcinoma of the breast: role of comprehensive molecular pathology in characterization of an entity. *J Pathol* 2005; **207**: 1-13 [PMID: 15957152 DOI: 10.1002/path.1806]
- 42 **Association of Breast Surgery at Baso 2009**. Surgical guidelines for the management of breast cancer. *Eur J Surg Oncol* 2009; **35** Suppl 1: 1-22 [PMID: 19299100 DOI: 10.1016/j.ejso.2009.01.008]
- 43 **Goyal A**, Newcombe RG, Mansel RE, Chetty U, Ell P, Fal-lowfield L, Kissin M, Sibbering M. Sentinel lymph node biopsy in patients with multifocal breast cancer. *Eur J Surg Oncol* 2004; **30**: 475-479 [PMID: 15135472 DOI: 10.1016/j.ejso.2004.02.009]
- 44 **Toikkanen S**, Pylkkänen L, Joensuu H. Invasive lobular carcinoma of the breast has better short- and long-term survival than invasive ductal carcinoma. *Br J Cancer* 1997; **76**: 1234-1240 [PMID: 9365176 DOI: 10.1038/bjc.1997.540]
- 45 **Boyages J**, Delaney G, R. T. Predictors of local recurrence after treatment of ductal carcinoma in situ: a meta-analysis. *Cancer* 1999; **85**: 616-28 [DOI: 10.1002/(SICI)1097-0142(19990201)85:3<616::AID-CNCR12>3.0.CO;2-7]
- 46 **Blair SL**, Emerson DK, Kulkarni S, Hwang ES, Malcarne V, Ollila DW. Breast surgeon's survey: no consensus for surgical treatment of pleomorphic lobular carcinoma in situ. *Breast J* 2013; **19**: 116-118 [PMID: 23231019 DOI: 10.1111/tbj.12062]

P- Reviewer: Daneshbod Y, Higgins PJ **S- Editor:** Song XX
L- Editor: A **E- Editor:** Lu YJ





Published by **Baishideng Publishing Group Inc**

8226 Regency Drive, Pleasanton, CA 94588, USA

Telephone: +1-925-223-8242

Fax: +1-925-223-8243

E-mail: bpgoffice@wjgnet.com

Help Desk: <http://www.wjgnet.com/esps/helpdesk.aspx>

<http://www.wjgnet.com>

