

World Journal of *Clinical Oncology*

World J Clin Oncol 2017 August 10; 8(4): 305-377



**REVIEW**

- 305 Magnetic resonance imaging for prostate cancer before radical and salvage radiotherapy: What radiation oncologists need to know
Couñago F, Sancho G, Catalá V, Hernández D, Recio M, Montemuiño S, Hernández JA, Maldonado A, del Cerro E

MINIREVIEWS

- 320 Use of programmed cell death protein ligand 1 assay to predict the outcomes of non-small cell lung cancer patients treated with immune checkpoint inhibitors
Tibaldi C, Lunghi A, Baldini E
- 329 Platinum-induced neurotoxicity: A review of possible mechanisms
Kanat O, Ertas H, Caner B

ORIGINAL ARTICLE**Retrospective Study**

- 336 Physician approaches to drug shortages: Results of a national survey of pediatric hematologist/oncologists
Beck JC, Chen B, Gordon BG
- 343 Trans-arterial chemoperfusion for the treatment of liver metastases of breast cancer and colorectal cancer: Clinical results in palliative care patients
Gruber-Rouh T, Langenbach M, Naguib NNN, Nour-Eldin NEM, Vogl TJ, Zangos S, Beeres M

Observational Study

- 351 Rescue associating liver partition and portal vein ligation for staged hepatectomy after portal embolization: Our experience and literature review
Maulat C, Philis A, Charriere B, Mokrane FZ, Guimbaud R, Otaï P, Suc B, Muscari F

CASE REPORT

- 360 *BRAF* V600Q-mutated lung adenocarcinoma with duodenal metastasis and extreme leukocytosis
Qasrawi A, Tolentino A, Abu Ghanimeh M, Abughanimeh O, Albadarin S
- 366 Intimal sarcoma of the pulmonary artery with multiple lung metastases: Long-term survival case
García-Cabezas S, Centeno-Haro M, Espejo-Pérez S, Carmona-Asenjo E, Moreno-Vega AL, Ortega-Salas R, Palacios-Eito A
- 371 Long-term stabilization of metastatic melanoma with sodium dichloroacetate
Khan A, Andrews D, Shainhouse J, Blackburn AC

Contents

World Journal of Clinical Oncology
Volume 8 Number 4 August 10, 2017

ABOUT COVER

Editorial Board Member of *World Journal of Clinical Oncology*, Che-Chun Su, MD, PhD, Associate Professor, Attending Doctor, Department of Internal Medicine, Changhua Christian Hospital, Changhua 500, Taiwan

AIM AND SCOPE

World Journal of Clinical Oncology (*World J Clin Oncol*, *WJCO*, online ISSN 2218-4333, DOI: 10.5306) is a peer-reviewed open access academic journal that aims to guide clinical practice and improve diagnostic and therapeutic skills of clinicians.

WJCO covers a variety of clinical medical topics, including etiology, epidemiology, evidence-based medicine, informatics, diagnostic imaging, endoscopy, tumor recurrence and metastasis, tumor stem cells, radiotherapy, chemotherapy, interventional radiology, palliative therapy, clinical chemotherapy, biological therapy, minimally invasive therapy, physiotherapy, psycho-oncology, comprehensive therapy, and oncology-related nursing. Priority publication will be given to articles concerning diagnosis and treatment of oncology diseases. The following aspects are covered: Clinical diagnosis, laboratory diagnosis, differential diagnosis, imaging tests, pathological diagnosis, molecular biological diagnosis, immunological diagnosis, genetic diagnosis, functional diagnostics, and physical diagnosis; and comprehensive therapy, drug therapy, surgical therapy, interventional treatment, minimally invasive therapy, and robot-assisted therapy.

We encourage authors to submit their manuscripts to *WJCO*. We will give priority to manuscripts that are supported by major national and international foundations and those that are of great clinical significance.

INDEXING/ABSTRACTING

World Journal of Clinical Oncology is now indexed in PubMed, PubMed Central and Scopus.

FLYLEAF

I-III Editorial Board

EDITORS FOR THIS ISSUE

Responsible Assistant Editor: *Xiang Li*
Responsible Electronic Editor: *Ya-Jing Lu*
Proofing Editor-in-Chief: *Lian-Sheng Ma*

Responsible Science Editor: *Fang-Fang Ji*
Proofing Editorial Office Director: *Ze-Mao Gong*

NAME OF JOURNAL
World Journal of Clinical Oncology

ISSN
ISSN 2218-4333 (online)

LAUNCH DATE
November 10, 2010

FREQUENCY
Bimonthly

EDITOR-IN-CHIEF
Godefridus J Peters, PhD, Professor, Department of Medical Oncology, Cancer Center Amsterdam, VU University Medical Center, Amsterdam 1081 HV, Netherlands

EDITORIAL BOARD MEMBERS
All editorial board members resources online at <http://www.wjgnet.com/2218-4333/editorialboard.htm>

EDITORIAL OFFICE
Xiu-Xia Song, Director

World Journal of Clinical Oncology
Baishideng Publishing Group Inc
7901 Stoneridge Drive, Suite 501, Pleasanton, CA 94588, USA
Telephone: +1-925-2238242
Fax: +1-925-2238243
E-mail: editorialoffice@wjgnet.com
Help Desk: <http://www.f6publishing.com/helpdesk>
<http://www.wjgnet.com>

PUBLISHER
Baishideng Publishing Group Inc
7901 Stoneridge Drive,
Suite 501, Pleasanton, CA 94588, USA
Telephone: +1-925-2238242
Fax: +1-925-2238243
E-mail: bpgoffice@wjgnet.com
Help Desk: <http://www.f6publishing.com/helpdesk>
<http://www.wjgnet.com>

PUBLICATION DATE
August 10, 2017

COPYRIGHT

© 2017 Baishideng Publishing Group Inc. Articles published by this Open-Access journal are distributed under the terms of the Creative Commons Attribution Non-commercial License, which permits use, distribution, and reproduction in any medium, provided the original work is properly cited, the use is non commercial and is otherwise in compliance with the license.

SPECIAL STATEMENT

All articles published in journals owned by the Baishideng Publishing Group (BPG) represent the views and opinions of their authors, and not the views, opinions or policies of the BPG, except where otherwise explicitly indicated.

INSTRUCTIONS TO AUTHORS

<http://www.wjgnet.com/bpg/gerinfo/204>

ONLINE SUBMISSION

<http://www.f6publishing.com>

Intimal sarcoma of the pulmonary artery with multiple lung metastases: Long-term survival case

Sonia García-Cabezas, Macarena Centeno-Haro, Simona Espejo-Pérez, Elvira Carmona-Asenjo, Alberto L Moreno-Vega, Rosa Ortega-Salas, Amalia Palacios-Eito

Sonia García-Cabezas, Amalia Palacios-Eito, Department of Radiation Oncology, Reina Sofia University Hospital, 14004 Cordoba, Spain

Spain. amalia.palacios.sspa@juntadeandalucia.es
Telephone: +34-957-011415
Fax: +34-957-011414

Macarena Centeno-Haro, Rosa Ortega-Salas, Department of Pathological Anatomy, Reina Sofia University Hospital, 14004 Cordoba, Spain

Received: November 30, 2016
Peer-review started: December 1, 2016
First decision: February 17, 2017
Revised: June 12, 2017
Accepted: July 21, 2017
Article in press: July 24, 2017
Published online: August 10, 2017

Simona Espejo-Pérez, Department of Radiology, Reina Sofia University Hospital, 14004 Cordoba, Spain

Elvira Carmona-Asenjo, Department of Nuclear Medicine, Reina Sofia University Hospital, 14004 Cordoba, Spain

Alberto L Moreno-Vega, Department of Medical Oncology, Reina Sofia University Hospital, 14004 Cordoba, Spain

Author contributions: All authors contributed to the acquisition of patient's clinical data, writing and revision of this manuscript.

Institutional review board statement: This publication has been approved by the Institutional Review Board.

Informed consent statement: The patient provided informed written consent prior to publication.

Conflict-of-interest statement: All authors declare that there are no conflicts of interest.

Open-Access: This article is an open-access article which was selected by an in-house editor and fully peer-reviewed by external reviewers. It is distributed in accordance with the Creative Commons Attribution Non Commercial (CC BY-NC 4.0) license, which permits others to distribute, remix, adapt, build upon this work non-commercially, and license their derivative works on different terms, provided the original work is properly cited and the use is non-commercial. See: <http://creativecommons.org/licenses/by-nc/4.0/>

Manuscript source: Invited manuscript

Correspondence to: Amalia Palacios-Eito, PhD, Department of Radiation Oncology, Reina Sofia University Hospital, Avda. Menéndez Pidal, s/n, 14004 Cordoba,

Abstract

Pulmonary artery intimal sarcoma (PAIS) is a rare tumor with a very poor prognosis. Clinical and radiological findings usually mimic thromboembolic disease, leading to diagnostic delays. The treatment of choice is surgery, and adjuvant chemotherapy and radiotherapy have limited results. We report the case of a 48-year-old male patient, initially suspected with pulmonary thromboembolism. The angio-CT revealed a filling defect in the pulmonary artery trunk. The patient underwent surgery, resulting in with complete resection of the mass with a diagnosis of PAIS. The tumor progressed rapidly in the lung, requiring surgery of multiple lung metastases. The patient was treated with stereotactic body radiation therapy (SBRT) on two occasions for new pulmonary lesions. In the last follow-up (4 years after initial diagnosis), the patient was disease-free. In conclusion, SBRT proved to be an alternative treatment to metastasectomy, allowing palliative chemotherapy to be delayed or omitted, which may result in improved quality of life.

Key words: Intimal sarcoma of the pulmonary artery; Lung metastases; Metastasectomy; Stereotactic body radiation therapy; Treatment

© **The Author(s) 2017.** Published by Baishideng Publishing Group Inc. All rights reserved.

Core tip: Intimal sarcoma of the pulmonary artery is a rare tumor with a very poor prognosis. It has been described in a limited number of reports. This case is a uncommon patient with long-term survival despite having rapid metastatic progression, who maintains a complete remission after initial surgical treatment, completed after occurrence of progression with stereotactic body radiotherapy.

García-Cabezas S, Centeno-Haro M, Espejo-Pérez S, Carmona-Asenjo E, Moreno-Vega AL, Ortega-Salas R, Palacios-Eito A. Intimal sarcoma of the pulmonary artery with multiple lung metastases: Long-term survival case. *World J Clin Oncol* 2017; 8(4): 366-370 Available from: URL: <http://www.wjgnet.com/2218-4333/full/v8/i4/366.htm> DOI: <http://dx.doi.org/10.5306/wjco.v8.i4.366>

INTRODUCTION

Pulmonary artery intimal sarcoma (PAIS) is a rare tumor first described by Mandelstamm^[1] in 1923. Since then, about 300 cases have been reported in the literature^[2,3]. The prognosis is generally poor, with a median overall survival of approximately 17 mo^[2-4]. Clinical and radiological findings usually mimic thromboembolic disease, leading to diagnostic delays^[5]. Surgical resection of the primary tumor is the best therapeutic option to prolong survival and adjuvant chemotherapy and radiotherapy have limited results^[2,3]. The treatment of choice is surgery, as adjuvant chemotherapy and radiotherapy have limited results. When metastases occur, they may be resected in specific patients^[6,7]. Otherwise, treatment is generally systemic and palliative in nature. In recent years, stereotactic body radiation therapy (SBRT) for lung metastases, a high-precision external radiotherapy technique, alternative to metastasectomy, has undergone significant development. Prospective phase I / II studies have shown that SBRT is safe and effective as treatment of lung metastases in oligometastatic patients who are not candidates for surgery^[8,9]. SBRT of inoperable lung metastases is today considered routine in many centers. We report the case of a rapidly metastatic PAIS, with sustained complete remission following surgical resection and SBRT.

CASE REPORT

A 48-year-old male patient presenting with sudden-onset symptoms of sweating, dizziness and falling to the ground, with loss of consciousness, and spontaneous recovery. After observing electrocardiographic changes, he was hospitalized with suspected acute coronary syndrome. An angio-computed tomography (CT) was performed, resulting in a diagnosis of pulmonary thromboembolism, with no improvement after anti-coagulant therapy. The patient was transferred to our

hospital, where a repeat angio-CT was performed, revealing a filling defect in the pulmonary artery trunk, extending from the subvalvular area to the origin of the right pulmonary artery, with no change in size with respect to the previous angio-CT (Figure 1). The patient was operated on for a suspected primary tumor of the pulmonary artery, resulting in with complete resection of the mass, whose pathological result was an intermediate-grade malignant tumor suggestive of PAIS (Figure 2). Following an extension study, CT showed only a nonspecific pulmonary nodule of 4 mm in diameter in the right upper lobe. No adjuvant treatment was given. Three months later, a positron emission tomography-computed tomography (PET-CT) found that the previously mentioned nodule measured 6 mm, suggestive of metastasis. Another 4 mm *de novo* nodule was found and two more of 2-3 mm in size, possibly granulomas, all without an increase in metabolic activity. The patient underwent surgery where 4 bilateral pulmonary lesions, compatible with metastasis, were resected. Fifteen months later, a new PET-CT reveals a subpleural nodule in the left upper lobe, again suspicious of metastasis (Figure 3A), as well as several millimeter-size nodules reported in the previous CT, not metabolically characterizable. After discussion in a multidisciplinary committee, the patient was given treatment with SBRT (12 Gy × 5 fractions), with excellent control. Six months later, growth of the two new pulmonary lesions noted in the previous CT was observed (Figure 3B and C). Chemotherapy was prescribed, which was rejected by the patient, and a second course of SBRT was given on both pulmonary lesions. Nine months after SBRT, the patient is disease-free by PET-CT.

DISCUSSION

PAIS is characterized by insidious growth, causing extensive local invasion and hematogeneous metastases. Because it is a rare tumor, only case reports and small case series have been published, most of them focused on the histopathological findings and surgical aspects of its management^[3,4,10-12]. Few patients achieve long-term survival and they are those without disease dissemination. The largest analysis of outcomes of this tumor reported better median survival of patients who received multimodality treatment with respect those who had single treatment (median survival of 24.7 and 8.0 mo, respectively). However, single treatment was defined as either surgery, chemotherapy or radiotherapy alone, instead of surgery without postoperative treatment^[2]. Mussot *et al*^[3] described a surgical series of 31 patients. They concluded that there appeared to be no statistical survival benefit in those who received adjuvant treatment compared to those who did not. A recent study^[4] analyzed 20 patients diagnosed with PAIS obtaining a median overall survival of 17 mo: Patients who received postoperative chemo and radiotherapy showed a trend towards better survival compared to those who had surgery alone (24 mo vs 8 mo, $P = 0.3417$). Successful

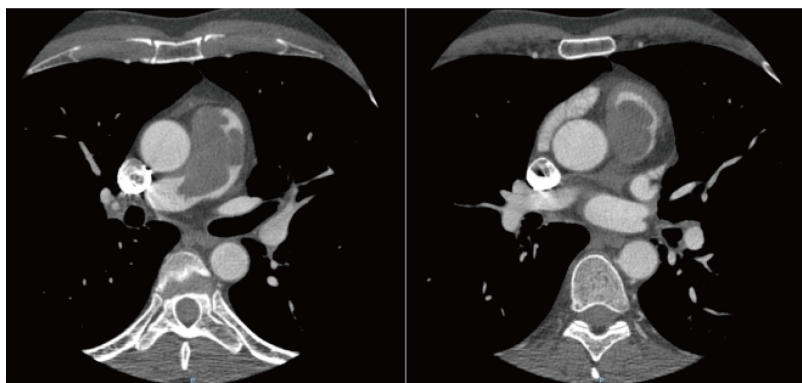


Figure 1 Angio-computed tomography: Filling defect in pulmonary artery trunk measuring 58 mm × 32 mm × 44 mm, extending from the subvalvular area to the origin of the right pulmonary artery.

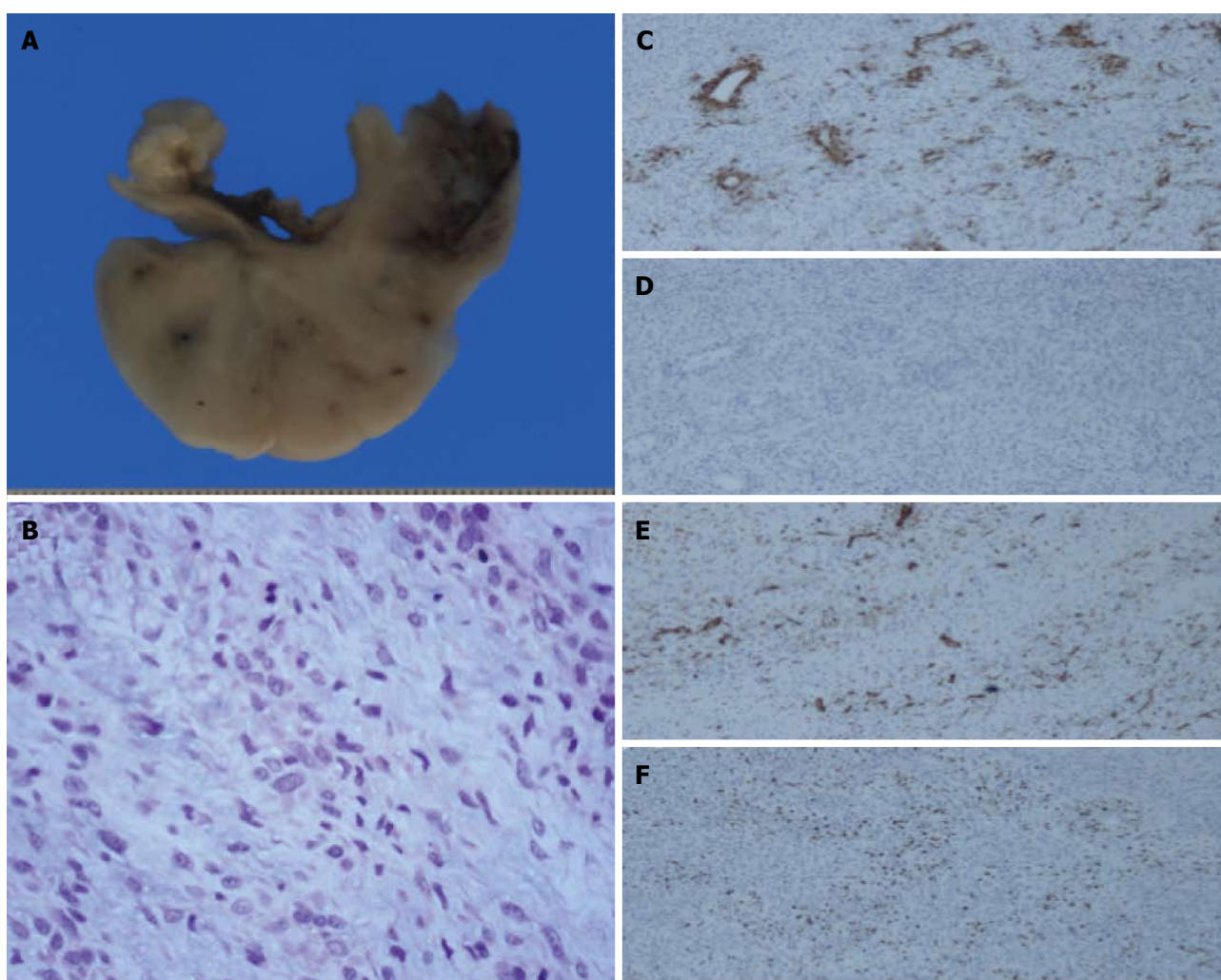


Figure 2 The patient was operated on for a suspected primary tumor of the pulmonary artery, resulting in with complete resection of the mass, whose pathological result was an intermediate-grade malignant tumor suggestive of Pulmonary artery intimal sarcoma. A: Macro: View of the pulmonary artery transversal section with infiltrating sarcoma on the lumen; B: High power of the tumor. Note the variable atypia 200 ×. Immunohistochemical stainings 100 ×; C: Smooth muscle actin: Focal tumor cell reaction 100 ×; D: Desmine: Negative 100 ×; E: CD31: Reaction of the endothelium surrounded by negative tumor cells 100 ×; F: Ki-67: Variable proliferation index in tumor cells 100 ×.

cases reported in metastatic patients are anecdotal. Thus, Said *et al*^[13] reported a case of pulmonary artery angiosarcoma, with a follow-up of 5 years and multiple repeat lung metastasectomies, which has a disease-free

interval of 1 year. Choi *et al*^[14] published a case of PAIS with metastases in the thyroid and adrenal glands, 4.7 and 6.3 years, respectively, after initial surgery. Both metastases were surgically resected, with an unusual

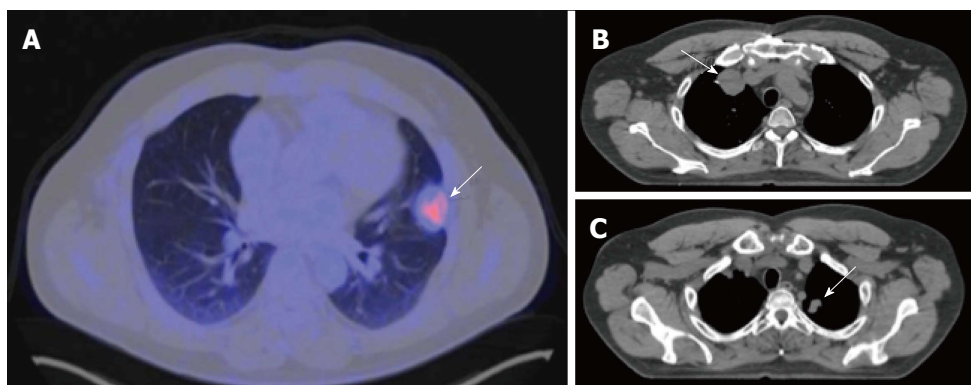


Figure 3 Positron emission tomography-computed tomography, three months later. A: Subpleural hypermetabolic nodular lesion in left upper lobe (SUV max 3.8) measuring 27 mm × 30 mm, suggestive of tumor activity; B and C: Computed tomography, a 38-mm nodule in right upper lobe and another 20-mm nodule in left upper lobe, compatible with metastasis.

survival of 12.5 years up to the last follow-up. In our case, dissemination occurred much earlier, as the patient was operated on for lung metastases 5 mo after the initial surgery, though it is likely that patient was already metastatic at diagnosis. He is currently disease-free, 4 years after diagnosis. To our knowledge, this is the first published case of metastatic PAIS with long-term survival treated with surgery and SBRT.

In conclusion, SBRT proved to be an alternative treatment to metastasectomy, allowing palliative chemotherapy to be delayed or omitted, which may result in improved quality of life.

COMMENTS

Case characteristics

A 48-year-old male presenting sudden-onset symptoms of sweating, dizziness and fall, with momentary loss of consciousness.

Clinical diagnosis

Acute coronary syndrome.

Differential diagnosis

Thromboembolic disease.

Imaging diagnosis

Angio-computed tomography: Filling defect in the pulmonary artery trunk, extending from the subvalvular area to the origin of the right pulmonary artery.

Pathological diagnosis

Intermediate-grade malignant tumor suggestive of pulmonary artery intimal sarcoma.

Treatment

The patient underwent surgery. The tumor progressed rapidly in the lung, requiring surgery of multiple lung metastases. Finally, he was treated with stereotactic body radiation therapy on two occasions for new pulmonary lesions.

Experiences and lessons

This case report describes an uncommon patient with exceptional long-term survival despite having rapid metastatic progression. This case teaches us that SBRT is an alternative treatment to metastasectomy, allowing palliative chemotherapy to be delayed or omitted.

Peer-review

The article presents an unusual case of intimal sarcoma of the pulmonary artery. There are a small number of cases reported. This is a rare sarcoma with very good response to treatment with radiotherapy.

REFERENCES

- 1 **Mandelstamm M.** Über primäre Neubildungen des Herzens. *Virchows Arch Pathol Anat* 1923; **245**: 43-54
- 2 **Blackmon SH,** Rice DC, Correa AM, Mehran R, Putnam JB, Smythe WR, Walkes JC, Walsh GL, Moran C, Singh H, Vaporciyan AA, Reardon M. Management of primary pulmonary artery sarcomas. *Ann Thorac Surg* 2009; **87**: 977-984 [PMID: 19231448 DOI: 10.1016/j.athoracsur.2008.08.018]
- 3 **Musnot S,** Ghigna MR, Mercier O, Fabre D, Fadel E, Le Cesne A, Simonneau G, Dartevelle P. Retrospective institutional study of 31 patients treated for pulmonary artery sarcoma. *Eur J Cardiothorac Surg* 2013; **43**: 787-793 [PMID: 22843511 DOI: 10.1093/ejcts/ezs387]
- 4 **Wong HH,** Gounaris I, McCormack A, Berman M, Davidson D, Horan G, Pepke-Zaba J, Jenkins D, Earl HM, Hatcher HM. Presentation and management of pulmonary artery sarcoma. *Clin Sarcoma Res* 2015; **5**: 3 [PMID: 25628857 DOI: 10.1186/s13569-014-0019-2]
- 5 **Jiang S,** Li J, Zeng Q, Liang J. Pulmonary artery intimal sarcoma misdiagnosed as pulmonary embolism: A case report. *Oncol Lett* 2017; **13**: 2713-2716 [PMID: 28454456 DOI: 10.3892/ol.2017.5775]
- 6 **Digesu CS,** Wiesel O, Vaporciyan AA, Colson YL. Management of Sarcoma Metastases to the Lung. *Surg Oncol Clin N Am* 2016; **25**: 721-733 [PMID: 27591495 DOI: 10.1016/j.soc.2016.05.005]
- 7 **Chudgar NP,** Brennan MF, Munhoz RR, Bucciarelli PR, Tan KS, D'Angelo SP, Bains MS, Bott M, Huang J, Park BJ, Rusch VW, Adusumilli PS, Tap WD, Singer S, Jones DR. Pulmonary metastasectomy with therapeutic intent for soft-tissue sarcoma. *J Thorac Cardiovasc Surg* 2017; **154**: 319-330.e1 [PMID: 28395901 DOI: 10.1016/j.jtcvs.2017.02.061]
- 8 **Okunieff P,** Petersen AL, Philip A, Milano MT, Katz AW, Boros L, Schell MC. Stereotactic Body Radiation Therapy (SBRT) for lung metastases. *Acta Oncol* 2006; **45**: 808-817 [PMID: 16982544 DOI: 10.1080/02841860600908954]
- 9 **Rusthoven KE,** Kavanagh BD, Burri SH, Chen C, Cardenes H, Chidel MA, Pugh TJ, Kane M, Gaspar LE, Scheffter TE. Multi-institutional phase I/II trial of stereotactic body radiation therapy for lung metastases. *J Clin Oncol* 2009; **27**: 1579-1584 [PMID: 19255320 DOI: 10.1200/JCO.2008.19.6386]
- 10 **Grazioli V,** Vistarini N, Morsolini M, Klersy C, Orlandoni G, Dore R, D'Armini AM. Surgical treatment of primary pulmonary artery sarcoma. *J Thorac Cardiovasc Surg* 2014; **148**: 113-118 [PMID: 24075471 DOI: 10.1016/j.jtcvs.2013.07.054]
- 11 **Huo L,** Moran CA, Fuller GN, Gladish G, Suster S. Pulmonary artery sarcoma: a clinicopathologic and immunohistochemical study of 12

- cases. *Am J Clin Pathol* 2006; **125**: 419-424 [PMID: 16613346]
- 12 **Tavora F**, Miettinen M, Fanburg-Smith J, Franks TJ, Burke A. Pulmonary artery sarcoma: a histologic and follow-up study with emphasis on a subset of low-grade myofibroblastic sarcomas with a good long-term follow-up. *Am J Surg Pathol* 2008; **32**: 1751-1761 [PMID: 18779732 DOI: 10.1097/PAS.0b013e31817d7fd0]
 - 13 **Said SM**, Sundt TM 3rd, Garces YI, Wigle DA. 5-year survival after multiple repeat metastasectomy for pulmonary artery angiosarcoma. *Ann Thorac Surg* 2011; **91**: e49-e51 [PMID: 21440106 DOI: 10.1016/j.athoracsur.2010.11.020]
 - 14 **Choi YM**, Jang EK, Ahn SH, Jeon MJ, Han JM, Kim SC, Han DJ, Gong G, Kim TY, Shong YK, Kim WB. Long-term survival of a patient with pulmonary artery intimal sarcoma after sequential metastasectomies of the thyroid and adrenal glands. *Endocrinol Metab (Seoul)* 2013; **28**: 46-49 [PMID: 24396650 DOI: 10.3803/EnM.2013.28.1.46]

P- Reviewer: Bramhall S, Cerwenka HR **S- Editor:** Kong JX
L- Editor: A **E- Editor:** Lu YJ





Published by **Baishideng Publishing Group Inc**
7901 Stoneridge Drive, Suite 501, Pleasanton, CA 94588, USA
Telephone: +1-925-223-8242
Fax: +1-925-223-8243
E-mail: bpgoffice@wjgnet.com
Help Desk: <http://www.f6publishing.com/helpdesk>
<http://www.wjgnet.com>

