

World Journal of *Orthopedics*

World J Orthop 2019 April 18; 10(4): 176-218



**SYSTEMATIC REVIEW**

- 176** Investigational growth factors utilized in animal models of spinal fusion: Systematic review
Cottrill E, Ahmed AK, Lessing N, Pennington Z, Ishida W, Perdomo-Pantoja A, Lo SF, Howell E, Holmes C, Goodwin CR, Theodore N, Sciubba DM, Witham TF
- 192** Growing pains: What do we know about etiology? A systematic review
Pavone V, Vescio A, Valenti F, Sapienza M, Sessa G, Testa G

CASE REPORT

- 206** Fracture of allograft interbody spacer resulting in post-operative radiculopathy: A case report
Kyle A, Rowland A, Stirton J, Elgafy H
- 212** Recalcitrant distal humeral non-union following previous Leiomyosarcoma excision treated with retainment of a radiated non-angiogenic segment augmented with 20 cm free fibula composite graft: A case report
Gathen M, Norris G, Kay S, Giannoudis PV

ABOUT COVER

Editorial Board Member of *World Journal of Orthopedics*, Kern Singh, MD, Associate Professor, Orthopaedic Surgery, Rush University Medical Center, Chicago, IL 60611, United States

AIMS AND SCOPE

World Journal of Orthopedics (*World J Orthop*, *WJO*, online ISSN 2218-5836, DOI: 10.5312) is a peer-reviewed open access academic journal that aims to guide clinical practice and improve diagnostic and therapeutic skills of clinicians.

The *WJO* covers topics concerning arthroscopy, evidence-based medicine, epidemiology, nursing, sports medicine, therapy of bone and spinal diseases, bone trauma, osteoarthropathy, bone tumors and osteoporosis, etc. Priority publication will be given to articles concerning diagnosis and treatment of orthopedic diseases. The following aspects are covered: Clinical diagnosis, laboratory diagnosis, differential diagnosis, imaging tests, pathological diagnosis, molecular biological diagnosis, immunological diagnosis, genetic diagnosis, etc.

We encourage authors to submit their manuscripts to *WJO*.

INDEXING/ABSTRACTING

The *WJO* is now abstracted and indexed in PubMed, PubMed Central, Emerging Sources Citation Index (Web of Science), Scopus, China National Knowledge Infrastructure (CNKI), China Science and Technology Journal Database (CSTJ), and Superstar Journals Database.

**RESPONSIBLE EDITORS
FOR THIS ISSUE**

Responsible Electronic Editor: Yun-Xiao Jian Wu Proofing Editorial Office Director: Jin-Lei Wang

NAME OF JOURNAL

World Journal of Orthopedics

ISSN

ISSN 2218-5836 (online)

LAUNCH DATE

November 18, 2010

FREQUENCY

Monthly

EDITORS-IN-CHIEF

Bao-Gan Peng

EDITORIAL BOARD MEMBERS

<http://www.wjgnet.com/2218-5836/editorialboard.htm>

EDITORIAL OFFICE

Jin-Lei Wang, Director

PUBLICATION DATE

April 18, 2019

COPYRIGHT

© 2019 Baishideng Publishing Group Inc

INSTRUCTIONS TO AUTHORS

<https://www.wjgnet.com/bpg/gerinfo/204>

GUIDELINES FOR ETHICS DOCUMENTS

<https://www.wjgnet.com/bpg/GerInfo/287>

GUIDELINES FOR NON-NATIVE SPEAKERS OF ENGLISH

<https://www.wjgnet.com/bpg/gerinfo/240>

PUBLICATION MISCONDUCT

<https://www.wjgnet.com/bpg/gerinfo/208>

ARTICLE PROCESSING CHARGE

<https://www.wjgnet.com/bpg/gerinfo/242>

STEPS FOR SUBMITTING MANUSCRIPTS

<https://www.wjgnet.com/bpg/GerInfo/239>

ONLINE SUBMISSION

<https://www.f6publishing.com>



Fracture of allograft interbody spacer resulting in post-operative radiculopathy: A case report

Andrews Kyle, Andrea Rowland, Jacob Stirton, Hossein Elgafy

ORCID number: Andrews Kyle (0000-0001-5358-9515); Andrea Rowland (0000-0002-9027-6195); Jacob Stirton (0000-0003-4669-4696); Hossein Elgafy (0000-0001-7518-9600).

Author contributions: Kyle A, Rowland A, Stirton J and Elgafy H contributed in outlining the manuscript, gathering the data, and writing the manuscript.

Informed consent statement: The patient wrote informed written consent.

Conflict-of-interest statement: None of the authors have any financial or other conflicts of interest that may bias the current study.

Open-Access: This article is an open-access article which was selected by an in-house editor and fully peer-reviewed by external reviewers. It is distributed in accordance with the Creative Commons Attribution Non Commercial (CC BY-NC 4.0) license, which permits others to distribute, remix, adapt, build upon this work non-commercially, and license their derivative works on different terms, provided the original work is properly cited and the use is non-commercial. See: <http://creativecommons.org/licenses/by-nc/4.0/>

Manuscript source: Unsolicited manuscript

Received: January 2, 2019

Peer-review started: January 4, 2019

First decision: January 26, 2019

Andrews Kyle, Andrea Rowland, Jacob Stirton, Hossein Elgafy, Department of Orthopaedic Surgery, University of Toledo College of Medicine and Life Sciences, 3000 Arlington Avenue, Toledo, OH 43614-5807, United States

Corresponding author: Hossein Elgafy, FRCS (Ed), FRCSC, MD, Professor, Department of Orthopaedics, University of Toledo Medical Centre, 3065 Arlington Avenue, Toledo, OH 43614-5807, United States. hossein.elgafy@utoledo.edu

Telephone: +1-419-3833515

Fax: +1-419-3833526

Abstract

BACKGROUND

Allograft interbody spacers are utilized during transforaminal lumbar interbody fusion (TLIF) to reestablish anterior column support and disc height. While the TLIF technique offers many improvements over previous surgical methods, instrumentation and bone graft-related complications such as spacer misplacement or migration, screw fracture or misplacement, or rod breakage continue to be reported. The objective of this manuscript is to report on a fractured allograft interbody spacer that displaced into the neural foramen and resulted in impingement on the exiting nerve root that required revision.

CASE SUMMARY

A 50-year-old male had two-level TLIF with immediate post-operative right L5 radiculopathy. Computed tomography scan demonstrated a fractured allograft interbody spacer that displaced into the right neural foramen and impinged on the exiting L5 nerve root. Revision surgery was performed to remove the broken allograft fragments from the right L5 foramen and the intact portion of the spacer was left in place. The right leg L5 radicular pain resolved. At the last follow up 12 mo after the index procedure, computed tomography scan confirmed sound interbody and posterolateral fusion.

CONCLUSION

Displacement of broken allograft interbody spacer following TLIF procedures can result in neurological sequelae that require revision. To avoid such an occurrence, the authors recommend allowing sufficient time for the reconstitution of the graft in saline prior to use to decrease brittleness, to use an impactor size that is as close as possible to the spacer size and meticulous inspection of the cortical allograft spacer for any visible imperfection prior to insertion.

Key words: Transforaminal lumbar interbody fusion; Interbody fusion; Allograft

Revised: February 18, 2019
Accepted: March 16, 2019
Article in press: March 16, 2019
Published online: April 18, 2019

P-Reviewer: Emara KM, Malik H
S-Editor: Wang JL
L-Editor: Filipodia
E-Editor: Wu YXJ



interbody spacer; Postoperative radiculopathy; Graft breakage; Case report

©The Author(s) 2019. Published by Baishideng Publishing Group Inc. All rights reserved.

Core tip: Allograft interbody spacers are commonly used in lumbar transforaminal lumbar interbody fusion procedures. A complication previously undocumented in the literature, we report on a fractured allograft interbody spacer that displaced into the neural foramen and resulted in impingement on the exiting nerve root that required revision. At 12 mo post-op, the patient was doing well with computed tomography scan confirming fusion and subsequent removal of the impinging fractured graft fragment. While presumably a rare occurrence, the authors review several technical points to avoid this complication.

Citation: Kyle A, Rowland A, Stirton J, Elgafy H. Fracture of allograft interbody spacer resulting in post-operative radiculopathy: A case report. *World J Orthop* 2019; 10(4): 206-211
URL: <https://www.wjgnet.com/2218-5836/full/v10/i4/206.htm>
DOI: <https://dx.doi.org/10.5312/wjo.v10.i4.206>

INTRODUCTION

Transforaminal lumbar interbody fusion (TLIF) is a surgical technique that is utilized for lumbar pathologies for which segmental fusion is indicated^[1-5]. This method was developed to improve upon previous surgical methods such as anterior or posterior lumbar interbody fusion. Its unilateral approach can reduce the risk of durotomy, nerve damage, or epidural fibrosis relative to posterior lumbar interbody fusion while decreasing incidence of vascular injury and procedure time relative to anterior lumbar interbody fusion^[2,5,7].

Prosthetic allograft interbody spacers are utilized during TLIF procedures to restore anterior column support and disc height in patients with degenerative disc disease and spondylolisthesis^[4,8-11]. The demineralized surface of the implant's allogenic bone provides osteoconductivity to aid in osteogenesis and scaffolding for new bone formation along its surface and successful interbody arthrodesis^[12,13].

Instrumentation or bone graft-related complications of the TLIF procedure typically involve graft misplacement or migration, screw fracture or misplacement, or rod breakage^[14-21]. The authors report on a complication involving a fractured allograft spacer that displaced into the neural foramen impinging on the exiting nerve root during a two-level TLIF. Revision surgery was carried out to remove the broken allograft fragment from the right L5 foramen. To the best of the authors' knowledge, a complication such as this has not been described in the literature.

CASE PRESENTATION

Chief complaints

A 50-year-old male who had previously undergone L5/S1 laminectomy, instrumentation and attempted posterolateral fusion presented to the clinic 2 years after this procedure with chronic low back pain and numbness/pain radiating down his right lower extremity, and to a lesser degree the left lower extremity.

Imaging examination

Computed tomography scan and magnetic resonance imaging confirmed L5/S1 nonunion with hardware loosening and adjacent segment disc degeneration and spinal stenosis. Risks, benefits, and alternative management were discussed and the patient elected to proceed with hardware removal, L4/5 decompression using a right-sided approach, and L4-S1 TLIF and posterior spinal fusion with iliac crest autograft. The procedure was carried out as planned with an allograft interbody spacer impacted into the anterior half of the disk space at both the L4/5 and L5/S1 levels without any obvious intraoperative complication. Soon after awakening from anesthesia, the patient began complaining of right leg radiculopathy along the L5 dermatome. Plain films (**Figure 1A** and **B**) showed no obvious complication. Computed tomography scan was then obtained which revealed allograft spacer

fracture with fragment displacement into the right L5 neural foramen (Figure 2A-C).

TREATMENT

The patient was subsequently taken back to the operating room for revision. The broken allograft pieces were identified and extracted (Figure 3). The intact portion of the allograft interbody spacer was left in place. Immediately following the procedure the patient's pain improved, and he was discharged home on post-operative day 2.

OUTCOME AND FOLLOW-UP

Over subsequent clinic visits, right leg L5 radicular pain resolved, and in the last follow-up 12 mo after the index procedure computed tomography scan confirmed sound interbody and posterolateral fusion with no foraminal bone fragment or stenosis (Figure 4A and B, and Figure 5A-C).

DISCUSSION

Complications resulting from the interbody fusion procedures have been well reported since the technique was first described by Harms *et al*^[22] in 1982. These complications, however, have typically involved infection, durotomy, bleeding, malpositioned hardware, or pseudoarthrosis^[5,11,17,19,21]. Hardware failure reports have been limited to interbody device migration/subsidence, screw fracture, or rod breakage^[18,20,23-25]. Saville *et al*^[26] showed that when a posterior lumbar interbody fusion spacer is compressed, failure is observed by subsidence of the graft into the upper or lower vertebral bodies and never internally within the graft itself. There have been case studies reporting vertebral fracture following TLIF procedures that may have resulted from the implantation process itself^[26].

The interbody fusion technique involves using vertebral endplate shavers to prepare the disc for the fusion. The graft size is determined using trial spacers. Starting with a smaller size trial spacer and under lateral view fluoroscopic guidance, the trial spacer is gradually increased until the most secure fit is achieved, and then selected for the corresponding graft size. The current case reported is unique as part of the graft was sheared off, which resulted in fractured pieces migrating to the right L5-S1 neural foramen, compressing the exiting nerve root, and resulting in right L5 radiculopathy. The remaining bulk of the interbody spacer remained intact and well positioned. No damage to the vertebral bodies was noted.

According to Janssen *et al*^[27], allograft spacers have been tested to withstand 25000 N of force compared to the compressive strength of a vertebral body itself as 8000 N. This assumes that the compressive strength of the spacer was equally distributed across the surface of the spacer, as opposed to a localized force applied to a portion of the spacer. As the patient experienced a limited axial load on his vertebrae following surgery, it is unlikely the fracture of the spacer occurred post-operatively. No reports were found of the surgeons experiencing significant difficulty or resistance during the insertion of allograft interbody spacers. Typically, a trial spacer is used to determine appropriate spacer size to achieve good vertebral body distraction and press-fit placement prior to inserting the interbody device. This makes it less likely that a poor interbody spacer size choice can explain the resulting fractured spacer. A system-specific insertion tool was used to implant the spacer decreasing the chance of damage occurring during graft insertion.

There are reports of bone allograft fracture in orthopedic surgery, such as after bone tumor resection. Aponte-Tinao *et al*^[28] reported fractured allografts in 19 out of 135 (14%) patients with segmental intercalary bone allograft reconstruction of the lower extremity. The kidney shaped allograft spacer used in the current report is freeze-dried. It is recommended by the manufacturer to reconstitute the graft in saline prior to use to decrease brittleness. After preparation of the disc space, the allograft spacer is inserted into the space with an implant holder, and then an impactor is used to fully seat the spacer into the intervertebral disc space. Possible causes for graft breakage could be one or a combination of the following: insufficient reconstitution of the graft prior to insertion, the impactor used to seat the graft is smaller than the spacer that may lead to shearing of part of the spacer, or the spacer was microscopically cracked prior to its insertion resulting in the graft weakening and breaking.

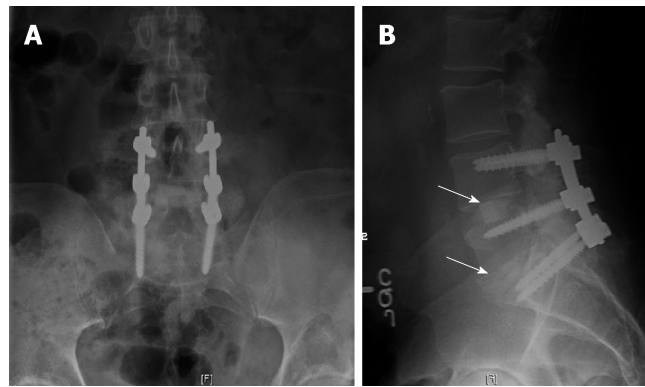


Figure 1 Post-operative radiographs showed good spinal alignment with hardware in good position and interbody spacer at each level is under the midsection of the disc space (arrows). A: Anteroposterior; B: Lateral.

CONCLUSION

Displacement of broken allograft interbody spacer following TLIF procedures can result in neurological sequelae that require revision. Though this complication was found during a TLIF procedure, any lumbar interbody fusion technique is subject to this complication in the event a prosthetic allograft spacer is used. To avoid such an occurrence, the authors recommend allowing sufficient time for the reconstitution of the graft in saline prior to use to decrease brittleness, to use an impactor size that is as close as possible to the spacer size and meticulous inspection of the cortical allograft spacer for any visible imperfection prior to insertion.

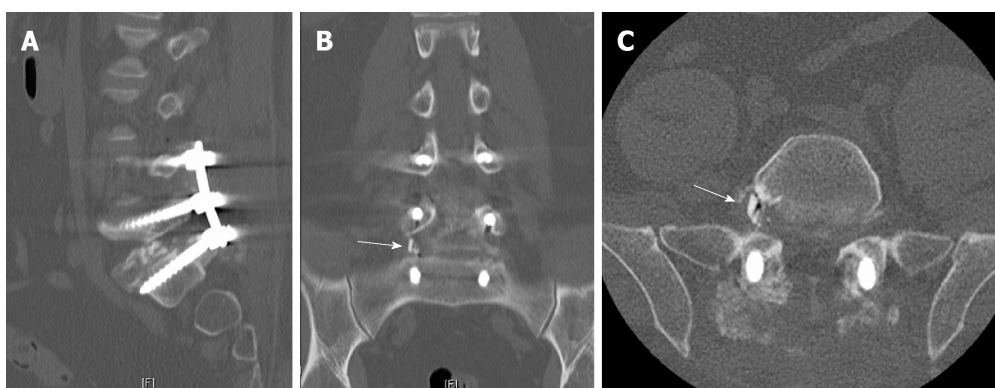


Figure 2 Postoperative computed tomography scan. A: Sagittal view showed the main part of the allograft spacer in the disc space without clear view of broken fragment; B: Coronal view shows obvious fragment (arrow) in the right L5-S1 foramina; C: Axial view also shows obvious fragment (arrow) in the right L5-S1 foramina.

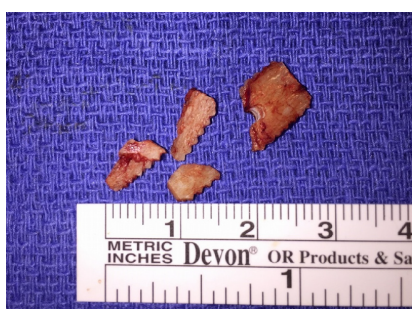

Figure 3 Fragments of prosthetic allograft interbody spacer extracted from right L5 neural foramen.

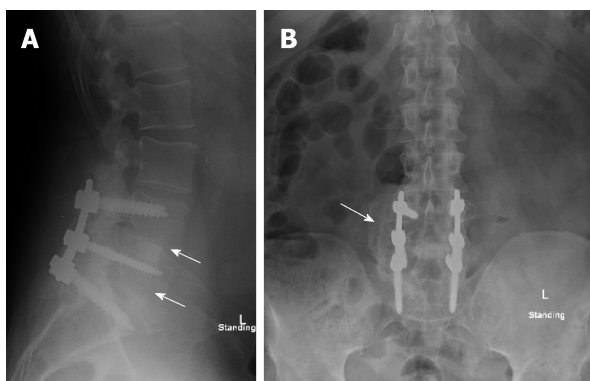


Figure 4 One-year post-operative radiographs showed interbody fusion and posterolateral fusion mass (arrows). A: Anteroposterior; B: Lateral.

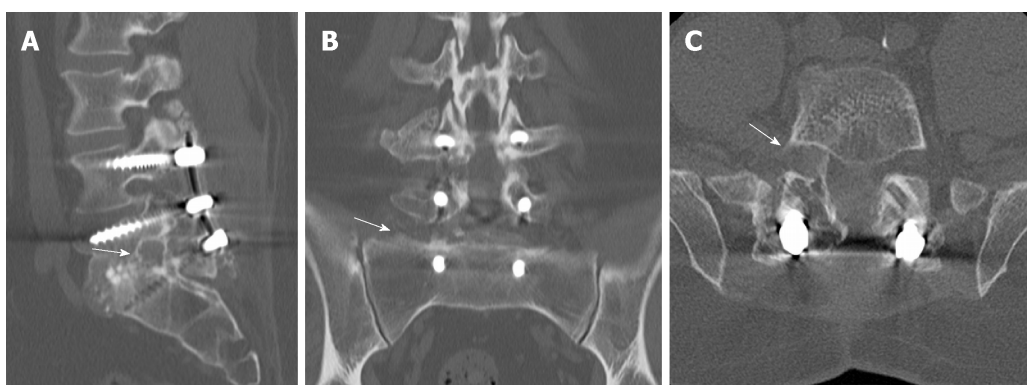


Figure 5 One-year post-operative computed tomography-scan. A: Sagittal, B: Coronal; C: Axial. No foraminal bone fragment or stenosis (arrows).

REFERENCES

- 1 **Mobbs RJ**, Phan K, Malham G, Seex K, Rao PJ. Lumbar interbody fusion: techniques, indications and comparison of interbody fusion options including PLIF, TLIF, MI-TLIF, OLIF/ATP, LLIF and ALIF. *J Spine Surg* 2015; **1**: 2-18 [PMID: 27683674 DOI: 10.3978/j.issn.2414-469X.2015.10.05]
- 2 **Derman PB**, Albert TJ. Interbody Fusion Techniques in the Surgical Management of Degenerative Lumbar Spondylolisthesis. *Curr Rev Musculoskelet Med* 2017; **10**: 530-538 [PMID: 29076042 DOI: 10.1007/s12178-017-9443-2]
- 3 **Hee HT**, Castro FP, Majd ME, Holt RT, Myers L. Anterior/posterior lumbar fusion versus transforaminal lumbar interbody fusion: analysis of complications and predictive factors. *J Spinal Disord* 2001; **14**: 533-540 [PMID: 11723406 DOI: 10.1097/00002517-200112000-00013]
- 4 **Moskowitz A**. Transforaminal lumbar interbody fusion. *Orthop Clin North Am* 2002; **33**: 359-366 [PMID: 12389281 DOI: 10.1016/S0030-5898(01)00008-6]
- 5 **Phan K**, Thayaparan GK, Mobbs RJ. Anterior lumbar interbody fusion versus transforaminal lumbar interbody fusion--systematic review and meta-analysis. *Br J Neurosurg* 2015; **29**: 705-711 [PMID: 25968330 DOI: 10.3109/02688697.2015.1036838]
- 6 **Potter BK**, Freedman BA, Verwiebe EG, Hall JM, Polly DW, Kuklo TR. Transforaminal lumbar interbody fusion: clinical and radiographic results and complications in 100 consecutive patients. *J Spinal Disord Tech* 2005; **18**: 337-346 [PMID: 16021015 DOI: 10.1097/01.bsd.0000166642.69189.45]
- 7 **Cutler AR**, Siddiqui S, Mohan AL, Hillard VH, Cerabona F, Das K. Comparison of polyetheretherketone cages with femoral cortical bone allograft as a single-piece interbody spacer in transforaminal lumbar interbody fusion. *J Neurosurg Spine* 2006; **5**: 534-539 [PMID: 17176018 DOI: 10.3171/spi.2006.5.6.534]
- 8 **Syed H**, Voyadzis JM. True Percutaneous Transforaminal Lumbar Interbody Fusion: Case Illustrations, Surgical Technique, and Limitations. *J Neurol Surg A Cent Eur Neurosurg* 2016; **77**: 344-353 [PMID: 26291889 DOI: 10.1055/s-0035-1558821]
- 9 **Xiao YX**, Chen QX, Li FC. Unilateral transforaminal lumbar interbody fusion: a review of the technique, indications and graft materials. *J Int Med Res* 2009; **37**: 908-917 [PMID: 19589277 DOI: 10.1177/147323000903700337]
- 10 **Tallarico RA**, Lavelle WF, J Bianco A, Taormina JL, Ordway NR. Positional effects of transforaminal interbody spacer placement at the L5-S1 intervertebral disc space: a biomechanical study. *Spine J* 2014; **14**: 3018-3024 [PMID: 25007755 DOI: 10.1016/j.spinee.2014.06.023]
- 11 **Heim SE**, Abitbol JJ. Complications and strategies for salvage of intervertebral fixation devices. *Orthop Clin North Am* 2002; **33**: 393-402, vii [PMID: 12389285 DOI: 10.1016/S0030-5898(01)00007-4]
- 12 **Gupta A**, Kukkar N, Sharif K, Main BJ, Albers CE, El-Amin Iii SF. Bone graft substitutes for spine fusion: A brief review. *World J Orthop* 2015; **6**: 449-456 [PMID: 26191491 DOI: 10.5312/wjo.v6.i6.449]
- 13 **Beaman FD**, Bancroft LW, Peterson JJ, Kransdorf MJ, Menke DM, DeOrto JK. Imaging characteristics of bone graft materials. *Radiographics* 2006; **26**: 373-388 [PMID: 16549604 DOI: 10.1148/rg.262055039]
- 14 **Liang Y**, Shi W, Jiang C, Chen Z, Liu F, Feng Z, Jiang X. Clinical outcomes and sagittal alignment of single-level unilateral instrumented transforaminal lumbar interbody fusion with a 4 to 5-year follow-up. *Eur Spine J* 2015; **24**: 2560-2566 [PMID: 25870077 DOI: 10.1007/s00586-015-3933-y]
- 15 **Leute PJ**, Hammad A, Hoffmann I, Hoppe S, Klinger HM, Lakemeier S. Set screw fracture with cage dislocation after two-level transforaminal lumbar interbody fusion (TLIF): a case report. *J Med Case Rep* 2015; **9**: 22 [PMID: 25609204 DOI: 10.1186/1752-1947-9-22]
- 16 **Pan FM**, Wang SJ, Yong ZY, Liu XM, Huang YF, Wu DS. Risk factors for cage retropulsion after lumbar interbody fusion surgery: Series of cases and literature review. *Int J Surg* 2016; **30**: 56-62 [PMID: 27107661 DOI: 10.1016/j.ijsu.2016.04.025]
- 17 **Hu W**, Tang J, Wu X, Zhang L, Ke B. Minimally invasive versus open transforaminal lumbar fusion: a systematic review of complications. *Int Orthop* 2016; **40**: 1883-1890 [PMID: 26987979 DOI: 10.1007/s00264-016-3153-z]
- 18 **Tormenti MJ**, Maserati MB, Bonfield CM, Gerszten PC, Moossy JJ, Kanter AS, Spiro RM, Okonkwo DO. Perioperative surgical complications of transforaminal lumbar interbody fusion: a single-center experience. *J Neurosurg Spine* 2012; **16**: 44-50 [PMID: 21993389 DOI: 10.3171/2011.9.SPINE11373]
- 19 **Joseph JR**, Smith BW, La Marca F, Park P. Comparison of complication rates of minimally invasive transforaminal lumbar interbody fusion and lateral lumbar interbody fusion: a systematic review of the literature. *Neurosurg Focus* 2015; **39**: E4 [PMID: 26424344 DOI: 10.3171/2015.7.FOCUS15278]
- 20 **Smith AJ**, Argenteanu M, Moore F, Steinberger A, Camins M. Increased incidence of cage migration and nonunion in instrumented transforaminal lumbar interbody fusion with bioabsorbable cages. *J Neurosurg Spine* 2010; **13**: 388-393 [PMID: 20809735 DOI: 10.3171/2010.3.SPINE09587]
- 21 **Wong AP**, Smith ZA, Stadler JA, Hu XY, Yan JZ, Li XF, Lee JH, Khoo LT. Minimally invasive transforaminal lumbar interbody fusion (MI-TLIF): surgical technique, long-term 4-year prospective outcomes, and complications compared with an open TLIF cohort. *Neurosurg Clin N Am* 2014; **25**: 279-304 [PMID: 24703447 DOI: 10.1016/j.nec.2013.12.007]
- 22 **Harms J**, Rolinger H. A one-stager procedure in operative treatment of spondylolistheses: dorsal traction-reposition and anterior fusion (author's transl). *Z Orthop Ihre Grenzgeb* 1982; **120**: 343-347 [PMID: 7113376 DOI: 10.1055/s-2008-1051624]
- 23 **Villavicencio AT**, Nelson EL, Rajpal S, Otolara F, Burneikiene S. Case Series of Anterior Intervertebral Graft Extrusions in Transforaminal Lumbar Interbody Fusion Surgeries. *World Neurosurg* 2016; **85**: 130-135 [PMID: 26341432 DOI: 10.1016/j.wneu.2015.08.047]
- 24 **Stein IC**, Than KD, Chen KS, Wang AC, Park P. Failure of a polyether-ether-ketone expandable interbody cage following transforaminal lumbar interbody fusion. *Eur Spine J* 2015; **24** Suppl 4: S555-S559 [PMID: 25465905 DOI: 10.1007/s00586-014-3704-1]
- 25 **Kim PD**, Baron EM, Levesque M. Extrusion of expandable stacked interbody device for lumbar fusion: case report of a complication. *Spine (Phila Pa 1976)* 2012; **37**: E1155-E1158 [PMID: 22498990 DOI: 10.1097/BRS.0b013e318257f14d]
- 26 **Saville PA**, Anari JB, Smith HE, Arlet V. Vertebral body fracture after TLIF: a new complication. *Eur Spine J* 2016; **25** Suppl 1: 230-238 [PMID: 26984878 DOI: 10.1007/s00586-016-4517-1]
- 27 **Janssen ME**, Lam C, Beckham R. Outcomes of allogenic cages in anterior and posterior lumbar interbody fusion. *Eur Spine J* 2001; **10** Suppl 2: S158-S168 [PMID: 11716014 DOI: 10.1007/s005860100292]
- 28 **Aponte-Tinao LA**, Ayerza MA, Muscolo DL, Farfalli GL. Should fractures in massive intercalary bone allografts of the lower limb be treated with ORIF or with a new allograft? *Clin Orthop Relat Res* 2015; **473**: 805-811 [PMID: 24793105 DOI: 10.1007/s11999-014-3659-x]



Published By Baishideng Publishing Group Inc
7041 Koll Center Parkway, Suite 160, Pleasanton, CA 94566, USA
Telephone: +1-925-2238242
Fax: +1-925-2238243
E-mail: bpgoffice@wjgnet.com
Help Desk: <https://www.f6publishing.com/helpdesk>
<https://www.wjgnet.com>

