


World Journal of *Orthopedics*

World J Orthop 2020 January 18; 11(1): 1-75



**MINIREVIEWS**

- 1 Patents and intellectual property in orthopaedics and arthroplasty
Uzoigwe CE, Shoaib A

ORIGINAL ARTICLE**Basic Study**

- 10 Double-row repair of rotator cuff tears: Comparing tendon contact area between techniques
Ng SHA, Tan CHJ

Case Control Study

- 18 National trends in total hip arthroplasty for traumatic hip fractures: An analysis of a nationwide all-payer database
Boniello AJ, Lieber AM, Denehy K, Cavanaugh P, Kerbel YE, Star A

Retrospective Cohort Study

- 27 Corrections in alpha angle following two different operative approaches for CAM-type femoral acetabular impingement - Ganz surgical hip dislocation *vs* anterior mini-open
Haug EC, Novicoff WM, Cui Q
- 36 Good accuracy of the alpha-defensin lateral flow test for hip periprosthetic joint infection: A pilot study in a retrospective cohort of 52 patients
Kuiper JW, Pander P, Vos SJ

Randomized Controlled Trial

- 47 Effect of deep transverse friction massage *vs* stretching on football players' performance
Fakhro MA, Chahine H, Srouf H, Hijazi K

META-ANALYSIS

- 57 Use of three-dimensional printing in preoperative planning in orthopaedic trauma surgery: A systematic review and meta-analysis
Morgan C, Khatri C, Hanna SA, Ashrafian H, Sarraf KM

CASE REPORT

- 68 Rapid spontaneous resolution of lumbar ganglion cysts: A case report
Chiarella V, Ramieri A, Giugliano M, Domenicucci M

ABOUT COVER

Editorial Board Member of *World Journal of Orthopedics*, Charles L Nelson, MD, Associate Professor, Chief Doctor, Surgeon, Department of Orthopaedic Surgery, University of Pennsylvania Perelman School of Medicine, Philadelphia, PA 19104, United States

AIMS AND SCOPE

The primary aim of *World Journal of Orthopedics* (*WJO*, *World J Orthop*) is to provide scholars and readers from various fields of orthopedics with a platform to publish high-quality basic and clinical research articles and communicate their research findings online.

WJO mainly publishes articles reporting research results and findings obtained in the field of orthopedics and covering a wide range of topics including arthroscopy, bone trauma, bone tumors, hand and foot surgery, joint surgery, orthopedic trauma, osteoarthritis, osteoporosis, pediatric orthopedics, spinal diseases, spine surgery, and sports medicine.

INDEXING/ABSTRACTING

The *WJO* is now abstracted and indexed in PubMed, PubMed Central, Emerging Sources Citation Index (Web of Science), Scopus, China National Knowledge Infrastructure (CNKI), China Science and Technology Journal Database (CSTJ), and Superstar Journals Database.

RESPONSIBLE EDITORS FOR THIS ISSUE

Responsible Electronic Editor: *Mei-Yi Liu*

Proofing Production Department Director: *Xiang Li*

NAME OF JOURNAL

World Journal of Orthopedics

ISSN

ISSN 2218-5836 (online)

LAUNCH DATE

November 18, 2010

FREQUENCY

Monthly

EDITORS-IN-CHIEF

Bao-Gan Peng

EDITORIAL BOARD MEMBERS

<http://www.wjgnet.com/2218-5836/editorialboard.htm>

EDITORIAL OFFICE

Ruo-Yu Ma, Director

PUBLICATION DATE

January 18, 2020

COPYRIGHT

© 2020 Baishideng Publishing Group Inc

INSTRUCTIONS TO AUTHORS

<https://www.wjgnet.com/bpg/gerinfo/204>

GUIDELINES FOR ETHICS DOCUMENTS

<https://www.wjgnet.com/bpg/GerInfo/287>

GUIDELINES FOR NON-NATIVE SPEAKERS OF ENGLISH

<https://www.wjgnet.com/bpg/gerinfo/240>

PUBLICATION MISCONDUCT

<https://www.wjgnet.com/bpg/gerinfo/208>

ARTICLE PROCESSING CHARGE

<https://www.wjgnet.com/bpg/gerinfo/242>

STEPS FOR SUBMITTING MANUSCRIPTS

<https://www.wjgnet.com/bpg/GerInfo/239>

ONLINE SUBMISSION

<https://www.f6publishing.com>



Retrospective Cohort Study

Corrections in alpha angle following two different operative approaches for CAM-type femoral acetabular impingement - Ganz surgical hip dislocation vs anterior mini-open

Emanuel C Haug, Wendy M Novicoff, Quanjun Cui

ORCID number: Emanuel Haug (0000-0002-7655-6326); Wendy Novicoff (0000-0002-5146-7706); Quanjun Cui (0000-0003-4285-4488).

Author contributions: Haug EC, Cui Q and Novicoff WM all contributed equally to this project; Haug EC and Cui Q contributed to design and literature Research; Novicoff WM contributed to statistical analysis; Cui Q performed surgical procedures; Haug EC and Cui Q wrote the manuscript.

Institutional review board statement: This study was reviewed and approved by the University of Virginia Institution Review Board, ID# 18513.

Informed consent statement: Patients were not required to give informed consent to this study because the analysis used anonymous data that were obtained after each patient agreed to treatment by written consent.

Conflict-of-interest statement: Haug EC and Novicoff WM have no disclosures. Cui Q has received research grants by Exactech and NIH. He is a board member of VOS and ARCO, and editorial board member at the Journal of Arthroplasty and Journal of Orthopaedic Research.

STROBE statement: The authors have read the STROBE Statement-checklist of items, and the manuscript was prepared and revised according to the STROBE

Emanuel C Haug, Wendy M Novicoff, Quanjun Cui, Department of Orthopedic Surgery, University of Virginia School of Medicine, Charlottesville, VA 22908, United States

Corresponding author: Quanjun Cui, MD, Professor, Vice Chair for Research, Department of Orthopaedic Surgery, University of Virginia School of Medicine, Charlottesville, VA 22903, United States. qc4q@hscmail.mcc.virginia.edu

Abstract

BACKGROUND

Femoroacetabular impingement (FAI) is a predisposing factor for secondary osteoarthritis of the hip joint. The two extensively described impingement mechanisms of FAI are CAM and Pincer-type. Initially managed conservatively, operative intervention should be offered to the persistently symptomatic patient. The measurement of the alpha angle is considered a standard method of assessing the severity of pathology in Cam-type FAI on pre-operative plain radiographs. The radiological correction of the alpha angle has not been previously compared between different surgical approaches. We hypothesize that there is no difference in alpha angle correction between Ganz surgical hip dislocation and the anterior mini-open approach.

AIM

To compare the magnitude of alpha angle correction achieved by using the Ganz surgical hip dislocation and the anterior mini-open approach.

METHODS

This is a retrospective study assessing seventy-nine patients identified in a 5-year period. These patients had preoperative radiographic evidence of FAI and underwent surgery by a single surgeon at our institution, a tertiary care center. Patients with missing radiographic documentation, radiographs with insufficient quality which then precluded accurate measurement of the angle α , a diagnosed congenital condition, isolated type II pathology (Pincer), and history of prior surgery were excluded from the study. Either the Ganz surgical hip dislocation or the anterior mini open approach was used. Postoperative radiographic evaluation of the alpha angle between the two surgical methods was done and corrected for age and gender using two-sample *t*-tests and Chi-square analyses.

RESULTS

A total of 79 patients met the inclusion and exclusion criteria. Forty-seven males

Statement-checklist of items.

Open-Access: This article is an open-access article which was selected by an in-house editor and fully peer-reviewed by external reviewers. It is distributed in accordance with the Creative Commons Attribution Non Commercial (CC BY-NC 4.0) license, which permits others to distribute, remix, adapt, build upon this work non-commercially, and license their derivative works on different terms, provided the original work is properly cited and the use is non-commercial. See: <http://creativecommons.org/licenses/by-nc/4.0/>

Manuscript source: Unsolicited manuscript

Received: March 7, 2019

Peer-review started: March 8, 2019

First decision: April 16, 2019

Revised: May 16, 2019

Accepted: November 6, 2019

Article in press: November 6, 2019

Published online: January 18, 2020

P-Reviewer: Schmolders J, Widmer KH

S-Editor: Gong ZM

L-Editor: A

E-Editor: Liu MY



(mean age of 35.3, range 16-53) and 32 females (mean age 36.7, range 16-60) were enrolled. Forty-seven patients underwent the anterior mini-open approach, and 32 underwent the Ganz surgical hip dislocation. There were no significant differences in age between the two surgical groups or in pre- and post-operative alpha angles based on patient gender. The mean pre-operative alpha angle for the Ganz surgical hip dislocation group was 88.0 degrees (SD 12.3) and 99.4 degrees (SD 7.2) for the anterior mini-open group. Mean post-operative angles were 49.9 degrees (SD 4.3) for the Ganz surgical hip dislocation and 43.8 (SD 4.3) degrees for the anterior mini-open group. There was a statistically significant difference in patient's pre-operative and post-operative angles ($P = 0.000$) with both surgical approaches.

CONCLUSION

Statistically significant decreases in alpha angle were noted for both surgical techniques, with larger decreases seen in the anterior mini-open group.

Key words: Alpha angle; Femoroacetabular impingement; Ganz surgical hip dislocation; Anterior mini-open

©The Author(s) 2020. Published by Baishideng Publishing Group Inc. All rights reserved.

Core tip: It is well understood that femoroacetabular impingement (FAI) is a predisposing factor for secondary osteoarthritis of the hip joint. The two extensively described impingement mechanisms of FAI are CAM and Pincer-type. If conservative management fails, a surgical approach can be chosen. The measurement of the alpha angle is considered a standard method of assessing the severity of pathology in Cam-type FAI on pre-operative plain radiographs. The radiological correction of the alpha angle, as measured on a lateral view radiograph, has not been previously compared between different surgical approaches. This article compares the magnitude of alpha angle correction achieved by using two different operative techniques: the Ganz surgical hip dislocation and the anterior mini-open approach. Seventy-nine patients were identified in a 5-year period who underwent surgery at our institution. Statistically significant decreases in alpha angle were noted for both surgical techniques, with larger decreases seen in the anterior mini-open group.

Citation: Haug EC, Novicoff WM, Cui Q. Corrections in alpha angle following two different operative approaches for CAM-type femoral acetabular impingement - Ganz surgical hip dislocation vs anterior mini-open. *World J Orthop* 2020; 11(1): 27-35

URL: <https://www.wjgnet.com/2218-5836/full/v11/i1/27.htm>

DOI: <https://dx.doi.org/10.5312/wjo.v11.i1.27>

INTRODUCTION

The pathology for femoroacetabular impingement (FAI) may be noted in the acetabulum, the head-neck junction of the proximal femur, or a combination of the two. It can be seen in all age groups and there is new evidence suggesting occurrence in younger patients than previously seen, as well as, specific sex-dependent characteristics between males and females^[1-3].

The mechanism by which FAI occurs is generally classified into three categories. Type I describes a CAM-type impingement where the femoral head and neck region creates asphericity, the head-neck offset is reduced, with increased alpha angle. This region may be covered by hyaline cartilage and could be developmental in origin due to incomplete separation of the growth plates of the femoral head and the trochanter. This physeal growth abnormality has been shown to cause the non-spherical contour with lateral epiphyseal extension^[4]. An adolescent growth spurt and a known history of a slipped capital femoral epiphysis can also predispose a person to this type of asymmetry. As with many orthopaedic conditions, musculoskeletal injury may also contribute to the alteration of the shape of head and neck region and cause this CAM-type impingement effect. Ultimately, and largely regardless of predisposing etiology, this abnormal impingement type mechanism leads to secondary osteoarthritis of the

hip joint. The reason for this is that the structural abnormality leads to chronic abutment of the femoral neck and the rim of acetabulum in flexion and internal rotation of the hip joint. This causes atypical and increased compression and shear forces which results in chondral lesions, labral tears and osteoarthritis^[1]. Therefore, early detection and removal of the asphericity alleviates this mechanical mismatch and oftentimes significantly improves the patient's symptomatology. To this end, various techniques (*i.e.*, arthroscopic procedures ranging to more extensive open methods) have been well described in today's literature and are broadly accepted and employed in everyday practice^[5-8].

Type II impingement is consistent with a pincer mechanism. This is generally defined by over-coverage of the femoral head and neck by the acetabulum. The acetabular socket is abnormally deep or retroverted while the femoral neck is generally normal. An anteroposterior (AP) pelvis radiograph can demonstrate such signs to a good extent. This increased coverage inherently limits motion of the hip joint and, at extremes of motion, causes the neck to impinge on the acetabular labrum and socket. Over time, this is known to lead to degenerative cleavage in the labrum and circumferential cartilage damage^[1]. In this case, treatment is aimed at resecting the prominent acetabular rim to allow for impingement free range of motion. As with type I, there are various surgical techniques described for type II pathology depending on surgeon's individual comfort level.

The third and last general type of FAI is more common than the isolated type I or II lesions, and it is a combination of both the cam and pincer pathology. Thus, the surgical treatment for the type III mechanistic mismatch is aimed to address the femoral neck region along with the acetabular rim. Traditionally, whenever both intra- and extra-articular pathology and deformity need to be addressed, the open hip dislocation offers satisfactory exposure and access^[9].

To determine and qualify the presence of Cam type morphology, a radiographic calculation of the alpha angle is most often employed. It provides reliable information for operative planning and helps to monitor the progress in the immediate post-operative period and on subsequent follow up. While generally calculated on standard radiographs, the researchers described this angle on magnetic resonance imaging as well^[10,11]. The angle is subtended by a line drawn in the middle of the femoral neck to the center of the head and a line drawn from the center of the femoral head to a point where head extrudes the perfect circle drawn around it^[12]. The cross-table lateral radiograph with the femur in 15 degree of internal rotation and a Dunn view in flexion evaluate the aspheric morphology appropriately. The frog lateral views also provide comparable information^[13,14]. It is worthy to mention that this pathology may be missed on a cross-table view with femur in external rotation, as well as, on direct AP radiographs^[10].

An appropriately measured angle affords a reliable metric to assess the postoperative correction, irrespective of the technique utilized, and helps to correlate impingement free motion^[11]. To our knowledge, the correlation of alpha angle improvement has not been compared between various operative techniques, especially the extensile traditional and modern anterior mini-open approach.

Therefore, the aims of this study were to determine (1) Change from baseline in the alpha angle on cross-table lateral radiograph (with leg in 15 degree internal rotation) after surgery; and (2) Compare radiographic corrections between the Ganz surgical hip dislocation and anterior mini-open.

MATERIALS AND METHODS

Institutional review board approval was obtained prior to commencement of the study. The institutional data of the patients who underwent surgery for FAI under a single surgeon were abstracted from a large medical center's records ranging from 2007 to 2012. All patients with pre- and post-operative radiographs were screened. Patients with missing radiographic documentation, radiographs with insufficient quality which then precluded accurate measurement of the angle α , a diagnosed congenital condition, isolated type II pathology (Pincer), and history of prior surgery were excluded from the study.

The Ganz surgical hip dislocation^[15] was performed in a lateral decubitus position. A trochanteric flip osteotomy was used to achieve an anterior approach to the hip joint. The thickness of the trochanter was kept at approximately 1.5 cm and the gluteus medius and vastus lateralis were kept intact. A Z-shaped capsulotomy was then performed in the order of anterolateral limb in line with the neck, a distal anteroinferior extension in front of the lesser trochanter and finally a curved posterolateral limb between gluteus minimus and piriformis in line with the

acetabular rim. The main aim of this approach was to preserve the profundus branch of medial femoral circumflex artery (MFCA) at the time of osteotomy. This also served to protect the medial branch at the level of lesser trochanter and contact anastomosis of inferior gluteal and MFCA posteriorly during the capsulotomy. Next, the femoral head was dislocated from the acetabulum and the pathology was assessed. Depending on extent of damage and viability, the labrum was either debrided or repaired. Then, the cam lesion was shaved carefully with a 5-mm diameter high-speed burr in order to more accurately restore the normal femoral neck morphology. The bone was removed to a safe level of a 4-5 mm depth until an impingement free range of motion was achieved in 90 degrees of flexion and 10-15 degrees of internal rotation^[11]. This was assessed intraoperatively prior to closure. The deep capsule was first closed in interrupted fashion. The trochanter was then reattached and held down with two small fragment screws and, finally, the skin was closed with subcutaneous absorbable sutures.

The second group in this study underwent an anterior mini-open approach. A partial anterior approach to the hip, the "Heuter Approach," also called the "Short Smith-Pete" because it follows the interval of the formal Smith-Petersen distal to the anterior superior iliac spine, was used for access to the capsule and femoral neck^[16-18]. All patients were positioned supine with a small well-padded bump under the pelvis. The incision was commenced slightly lateral and inferior to anterior superior iliac spine and then continued distally for 3-5.5 cm. The dissection was carried down to the capsule via the intramuscular (sartorius and tensor fascia lata) and internervous planes (femoral and superior gluteal nerves). Care was taken to avoid injury the branches of lateral cutaneous nerve to thigh, and the ascending branch of lateral femoral circumflex was ligated wherever necessary. Capsulotomy was carried out in line with the femoral neck with hip in flexion and then extended proximally around the acetabular rim while taking care to avoid damage to the cartilage and labrum. Blunt retractors are placed around the neck to expose the hip joint. To address the abnormal bony morphology, we employed similar steps as described above for the formal surgical hip dislocation. Then, a standard layered closure from deep to superficial was performed with the skin re-approximated in a sub-cuticular fashion.

To compare the differences in the alpha angles between the two surgical approaches, and to determine if age or gender were associated with the choice of surgical approach, two-sample *t*-tests and Chi-square analyses were employed, depending on the nature of the variables. All statistical analysis was done using SPSS Version 21.

TraumaCad® software (Voyant Health, Petach-Tikva, Israel) was utilized to measure the alpha angle^[11,12].

RESULTS

A total of 79 patients met the inclusion and exclusion criteria and had available records from the 5-year study period. Forty-seven males (mean age of 35.3, range 16-53) and 32 females (mean age 36.7, range 16-60) were enrolled. Forty-seven patients underwent the anterior mini-open approach, and 32 underwent the Ganz surgical hip dislocation. Pre-operatively, all patients were symptomatic and showed clinical and radiological features of impingement without significant degenerative changes. There were no significant differences in age between the two surgical groups or in pre- and post-operative alpha angles based on patient gender.

The overall angle correction achieved by both methods is shown in **Figure 1**. The mean pre-operative alpha angle for the Ganz surgical hip dislocation group was 88.0 degrees (SD 12.3) and 99.4 degrees (SD 7.2) for the anterior mini-open group. Mean post-operative angles were 49.9 degrees (SD 4.3) for the Ganz surgical hip dislocation and 43.8 (SD 4.3) degrees for the anterior mini-open group (**Table 1**). There was a statistically significant difference in patient's pre-operative and post-operative angles ($P = 0.000$) with both surgical approaches.

DISCUSSION

With a progressively better understanding of the abnormal femoroacetabular morphologies which can ultimately lead to secondary cartilage and labrum damage, mechanistic impingement has been recognized as one of the leading causes for early degeneration of the hip joint^[1]. The impingement mainly occurs when a patient flexes their hip joint past 90 degrees in an internal rotated and adducted position. This then leads to abutment of the femoral neck to the antero-superior and lateral parts of the

Table 1 Comparison of age and alpha angles for gender and surgery approach

	n	Mean age (SD)	Mean pre-op angle (SD)	Mean post-op angle (SD)
Overall	79	35.9 (10.7)	94.0 (11.0)	46.0 (5.0)
Male gender ²	47	35.3 (9.5)	92.1 (11.6)	45.9 (4.9)
Female gender	32	36.7 (12.3)	96.7 (9.5)	46.6 (5.6)
P value		0.61	0.14	0.28
Mini open	47	37.3 (11.1)	99.4 (7.2)	43.8 (4.3) ¹
Ganz surgical dislocation	32	33.8 (9.8)	88.0 (12.3)	49.9 (4.3) ¹
P value		0.16	0.00	0.00

¹P = 0.00 for the comparison between pre-operative and post-operative angles for each surgical approach.

²P = 0.55 for relationship between gender and surgical approach.

acetabulum. Clinical signs for the rare postero-superior pathology could be elicited by using a reverse maneuver. The basic radiological investigations for anterior pathology include AP pelvis, cross-table lateral, frog lateral, and Dunn views.

The mean alpha angles range from 42 to 74 degrees between asymptomatic and symptomatic patients^[12]. It is worth noting that even in the asymptomatic young population there is a 14 % prevalence of CAM-type morphology when abnormal angle is considered > 50.5 degrees^[19]. The significance of this is still largely unknown. Neumann *et al* identified impingement free range of motion at an angle with a mean value of 43 degrees (range, 34-60)^[11]. They concluded that the value of measurement determined in their study could be considered as a normal limit, which consequently is lower than the currently accepted angle of 50-55 degrees. When surgery is contemplated, the aim is to alleviate patient symptoms and achieve pain free range of motion.

Currently, it is not fully understood if surgical intervention will ultimately prevent progression of osteoarthritis of the hip joint, however, it is believed that early detection and treatment should mitigate the presumed destructive forces^[20]. This notion is supported by many short to mid term reports of good to excellent results regarding the effectiveness of the surgical procedure and possible slowing down of the pathological cartilage destruction process^[6,7,11,21-26].

There are many approaches and techniques described for surgical management and more are rapidly evolving. Current review of evidence suggests that all widely used techniques have, at least, comparable mid term results^[8,18,22,26-28].

The Ganz surgical hip dislocation for correction of FAI remains the gold standard and has been reported with good results^[15,20,22,24]. However, in recent times, there has been an inclination towards more minimally invasive and potentially less morbid procedures such as the anterior mini-open approach which provides ease of access to the joint with lower risks of incidental destruction of the crucial blood supply^[7,23]. Additionally, it bears mention that as hip arthroscopy continues to evolve, arthroscopic CAM lesion debridement has begun to gain acceptance and popularity^[8,20,27,29]. Previous studies with only relatively short-term arthroscopic outcomes data were largely confounded with heterogeneous outcome measures^[27]. However, more recent studies have shown that patients with FAI undergoing hip arthroscopy experience improvement in pain, quality of life and improvement in function^[28,30]. Furthermore, several studies have shown that arthroscopic CAM lesion debridement have a similar functional outcome compared to open surgical approaches^[31,32]. Interestingly, to this date no study has shown the correction of the alpha angle in hip arthroscopy, however, a recently published study by Briggs *et al*^[33] concluded that while the alpha angle is of importance in preoperative evaluation and diagnosis of FAI, the post operative angle does not correlate with functional outcome or development of osteoarthritis based on patient symptoms.

As for the anterior mini-open approach, there are additional early rehabilitation benefits in comparison to formal hip dislocation as no osteotomies are performed and no hardware is used to re-attach the greater trochanter. At our institution, we used the Ganz surgical hip dislocation approach until early part of the year 2010 and then gradually transitioned to the mini open approach based on good results reported by various studies^[7,23]. This transition period, has given us an opportunity to compare our results between the two approaches. By measuring the alpha angle on a plain radiograph, the morphology was closely monitored in the patient's post-operative follow up period.

We noted that for pre-op measurements, mini open cases had significantly larger

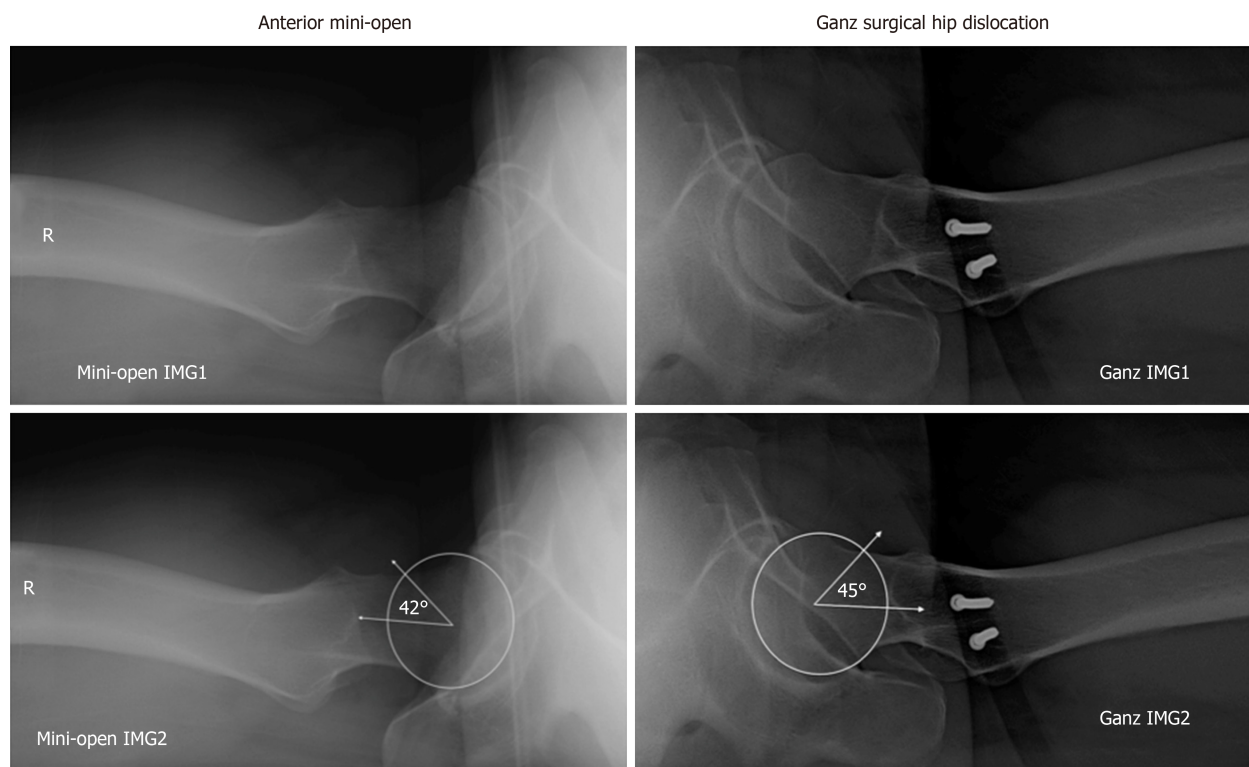


Figure 1 A 31-year-old male with bilateral hip femoroacetabular impingement with left hip treated using Ganz surgical hip dislocation while right hip treated through anterior mini-open approach. Both hips showed adequate correction of alpha angle (Top panels: Post-operative cross-table lateral X-ray images. Bottom panels: Showing measurement of alpha angle with left hip being 45 degrees and right being 42 degrees).

alpha angles. Additionally, for post-op measurements, mini-open cases also had significantly smaller angles. So the Ganz surgical hip dislocation did not lead to as large of a change in the alpha angle as compared to the mini-open approach. However, with both approaches we were able to achieve impingement free motion of the hip joint. There were no significant differences in age between the two surgical groups or pre- and post-operative alpha angles based on gender. The overall angle correction achieved by both methods is shown in [Table 1](#). In each case, we achieved alpha angles with impingement-free range of motion.

Using the anterior mini-open approach, when the deformity is in the antero-superior and antero-lateral part of the head and neck region, the hip is rotated under direct visualization and the bony prominence is shaved with high-speed burr. The labral damage can also be addressed by either debridement or repair. This leads to the assumption that the mini open method should be a more desirable approach. However, it is not without limitations. In the instance of circumferential pathology, it is quite challenging to dislocate the hip and access becomes a limiting factor. On the other hand, the more extensile approach can deal with circumferential pathology in a significantly more desirable manner. Prior studies have reported significant improvement in patient function with no significant risk of avascular necrosis of the femoral head with Ganz surgical hip dislocation^[11,15]. However, this approach also carries potential complications. These have been noted to include a bony non-union of the greater trochanter osteotomy site, heterotrophic ossification, and a slow abductor muscle recovery leading to delayed rehabilitation and return to activity.

There are a few limitations to our study. It is a retrospective review of patient records and radiographs. The data would have been more informative if the study was done in a prospective, randomized fashion. Pre-operative magnetic resonance arthrograms were obtained in many of our cases where the pathology was suspicious but the patients had a mixed clinical picture. A combination of radiographs and CT or MRI scans, pre- and post-operatively, could have led to more precise alpha angle measurements and subsequently strengthened the findings. However, this comes at a significantly added cost, radiation exposure, and time factor. Ultimately, it is unlikely that this diagnostic approach would significantly change the findings acquired on plain radiographs which remain a cost-effective and an easily accessible tool for diagnosis of FAI. Lastly, including arthroscopic debridement in our case series would have allowed us to comparatively assess its power of alpha angle correction, however, this approach was not performed at our institution during the data collection phase of

this study.

In conclusion, the alpha angle was adequately corrected to the level of impingement free motion with both the anterior mini-open approach and the Ganz surgical hip dislocation. Additionally, the mini-open approach led to an overall greater radiographic improvement.

ARTICLE HIGHLIGHTS

Research background

Femoroacetabular impingement (FAI) is a predisposing factor for secondary osteoarthritis of the hip joint. The two extensively described impingement mechanisms of FAI are CAM and Pincer-type deformities. Regardless of predisposing etiology, this abnormal impingement type mechanism leads functional decrease of the patient and to secondary osteoarthritis of the hip joint. Early detection and removal of the asphericity alleviates this mechanical mismatch and oftentimes significantly improves the patient's symptomatology. Various techniques (*i.e.*, arthroscopic procedures ranging to more extensive open methods) have been well described in today's literature and are broadly accepted. This study is significant since it shows statistically significant decreases in alpha angle were noted for both surgical techniques, the Ganz surgical hip dislocation vs anterior mini-open with larger decreases seen in the anterior mini-open group

Research motivation

Ultimately abnormal impingement type mechanisms can lead to symptomatic patients and to secondary osteoarthritis of the hip joint. Early detection and removal of the asphericity alleviates this mechanical mismatch. FAI and successful treatment has become a main focus of today's research focus. There are many surgical approaches to treat FAI. Finding effective surgical management to correct this deformity radiographically and improving functional outcome of the patient remains a challenge and requires further investigation.

Research objectives

The main objectives remains to find a successful way to address deformities of the acetabulum and proximal femur that lead to FAI. For this study the objectives were to evaluate the change from the baseline in the alpha angle on cross-table lateral radiograph after surgery and to compare radiographic corrections between the Ganz surgical hip dislocation and the anterior mini-open approach.

Research methods

This is a retrospective study assessing seventy-nine patients identified in a 5-year period. These patients had preoperative radiographic evidence of FAI and underwent surgery by a single surgeon at our institution, a tertiary care center. Patients with missing radiographic documentation, radiographs with insufficient quality which then precluded accurate measurement of the angle α , a diagnosed congenital condition, isolated Pincer deformity, and history of prior surgery were excluded from the study. Either the Ganz surgical hip dislocation or the anterior mini open approach was used. Postoperative radiographic evaluation of the alpha angle between the two surgical methods was done and corrected for age and gender using two-sample t-tests and chi-square analyses.

Research results

Statistically significant decreases in alpha angle were noted for both surgical techniques, with larger decreases seen in the anterior mini-open group. It is not fully understood if surgical intervention will ultimately prevent progression of osteoarthritis of the hip joint, however, it is believed that early detection and treatment should mitigate the presumed destructive forces. This study therefore shows that both surgical approaches provide a valid option for correcting the alpha angle which is implicated in FAI.

Research conclusions

Statistically significant decreases in alpha angle were noted for both surgical techniques, with larger decreases seen in the anterior mini-open group. While we do not know whether there is a difference in functional outcome of the patient, both surgical approaches provide a valid treatment option successfully decrease the alpha angle in patients with FAI.

Research perspectives

It remains difficult to design studies around surgical treatment options and radiographic findings do not necessarily correlate with clinical and functional outcome emphasizing the importance of investigating functional outcome of the patient. Future research should focus on arthroscopic vs open alpha angle reduction for FAI as well as functional outcome and future development of secondary osteoarthritis. Ideally, randomized controlled trials comparing functional outcome and radiographic changes pre vs post surgery between arthroscopic vs open treatment vs no treatment would be ideal. However, this study design may not be feasible in the US.

ACKNOWLEDGEMENTS

The authors would like to thank Wojciech L Czoch, MD and Khang Lee, MD for their help in collecting data and editing manuscript.

REFERENCES

- 1 **Beck M**, Kalhor M, Leunig M, Ganz R. Hip morphology influences the pattern of damage to the acetabular cartilage: femoroacetabular impingement as a cause of early osteoarthritis of the hip. *J Bone Joint Surg Br* 2005; **87**: 1012-1018 [PMID: 15972923 DOI: 10.1302/0301-620X.87B7.15203]
- 2 **Ito K**, Minka MA 2nd, Leunig M, Werlen S, Ganz R. Femoroacetabular impingement and the cam-effect. A MRI-based quantitative anatomical study of the femoral head-neck offset. *J Bone Joint Surg Br* 2001; **83**: 171-176 [PMID: 11284559 DOI: 10.1302/0301-620X.83B2.0830171]
- 3 **Nepple JJ**, Riggs CN, Ross JR, Clohisy JC. Clinical presentation and disease characteristics of femoroacetabular impingement are sex-dependent. *J Bone Joint Surg Am* 2014; **96**: 1683-1689 [PMID: 25320194 DOI: 10.2106/JBJS.M.01320]
- 4 **Siebenrock KA**, Wahab KH, Werlen S, Kalhor M, Leunig M, Ganz R. Abnormal extension of the femoral head epiphysis as a cause of cam impingement. *Clin Orthop Relat Res* 2004; 54-60 [PMID: 15043093 DOI: 10.1097/00003086-200401000-00010]
- 5 **Ganz R**, Parvizi J, Beck M, Leunig M, Nötzli H, Siebenrock KA. Femoroacetabular impingement: a cause for osteoarthritis of the hip. *Clin Orthop Relat Res* 2003; 112-120 [PMID: 14646708 DOI: 10.1097/01.blo.0000096804.78689.c2]
- 6 **Jackson TJ**, Stake CE, Trenga AP, Morgan J, Domb BG. Arthroscopic technique for treatment of femoroacetabular impingement. *Arthrosc Tech* 2013; **2**: e55-e59 [PMID: 23767009 DOI: 10.1016/j.eats.2012.10.005]
- 7 **Parvizi J**, Huang R, Diaz-Ledezma C, Og B. Mini-open femoroacetabular osteoplasty: how do these patients do? *J Arthroplasty* 2012; **27**: 122-125.e1 [PMID: 22682041 DOI: 10.1016/j.arth.2012.03.047]
- 8 **Nwachukwu BU**, Rebolledo BJ, McCormick F, Rosas S, Harris JD, Kelly BT. Arthroscopic Versus Open Treatment of Femoroacetabular Impingement: A Systematic Review of Medium- to Long-Term Outcomes. *Am J Sports Med* 2016; **44**: 1062-1068 [PMID: 26059179 DOI: 10.1177/0363546515587719]
- 9 **Tibor LM**, Sink EL. Pros and cons of surgical hip dislocation for the treatment of femoroacetabular impingement. *J Pediatr Orthop* 2013; **33** Suppl 1: S131-S136 [PMID: 23764786 DOI: 10.1097/BPO.0b013e318286006e]
- 10 **Meyer DC**, Beck M, Ellis T, Ganz R, Leunig M. Comparison of six radiographic projections to assess femoral head/neck asphericity. *Clin Orthop Relat Res* 2006; **445**: 181-185 [PMID: 16456309 DOI: 10.1097/01.blo.0000201168.72388.24]
- 11 **Neumann M**, Cui Q, Siebenrock KA, Beck M. Impingement-free hip motion: the 'normal' angle alpha after osteochondroplasty. *Clin Orthop Relat Res* 2009; **467**: 699-703 [PMID: 19018605 DOI: 10.1007/s11999-008-0616-6]
- 12 **Nötzli HP**, Wyss TF, Stoecklin CH, Schmid MR, Treiber K, Hodler J. The contour of the femoral head-neck junction as a predictor for the risk of anterior impingement. *J Bone Joint Surg Br* 2002; **84**: 556-560 [PMID: 12043778 DOI: 10.1302/0301-620X.84B4.0840556]
- 13 **Kumar R**, Aggarwal A, Krishnan V, Gopinathan N, Chakraborty S. Femoroacetabular impingement and comparison of radiological indexes: a study on 50 cases. *Musculoskelet Surg* 2013; **97**: 153-158 [PMID: 23381374 DOI: 10.1007/s12306-013-0244-5]
- 14 **Kapron AL**, Anderson AE, Aoki SK, Phillips LG, Petron DJ, Toth R, Peters CL. Radiographic prevalence of femoroacetabular impingement in collegiate football players: AAOS Exhibit Selection. *J Bone Joint Surg Am* 2011; **93**: e111(1-e1110) [PMID: 22005872 DOI: 10.2106/JBJS.K.00544]
- 15 **Ganz R**, Gill TJ, Gautier E, Ganz K, Krügel N, Berlemann U. Surgical dislocation of the adult hip a technique with full access to the femoral head and acetabulum without the risk of avascular necrosis. *J Bone Joint Surg Br* 2001; **83**: 1119-1124 [PMID: 11764423 DOI: 10.1302/0301-620X.83B8.0831119]
- 16 **Laude F**, Soriali E, Nogier A. Femoroacetabular impingement treatment using arthroscopy and anterior approach. *Clin Orthop Relat Res* 2009; **467**: 747-752 [PMID: 19089524 DOI: 10.1007/s11999-008-0656-y]
- 17 **Ribas M**, Ledesma R, Cardenas C, Marin-Peña O, Toro J, Caceres E. Clinical results after anterior mini-open approach for femoroacetabular impingement in early degenerative stage. *Hip Int* 2010; **20** Suppl 7: S36-S42 [PMID: 20512770 DOI: 10.5301/HIP.2010.858]
- 18 **Wilson AS**, Cui Q. Current concepts in management of femoroacetabular impingement. *World J Orthop* 2012; **3**: 204-211 [PMID: 23362464 DOI: 10.5312/wjo.v3.i12.204]
- 19 **Hack K**, Di Primio G, Rakhra K, Beaulé PE. Prevalence of cam-type femoroacetabular impingement morphology in asymptomatic volunteers. *J Bone Joint Surg Am* 2010; **92**: 2436-2444 [PMID: 20962194 DOI: 10.2106/JBJS.J.01280]
- 20 **Amanatullah DF**, Antkowiak T, Pillay K, Patel J, Refaat M, Toupadakis CA, Jamali AA. Femoroacetabular impingement: current concepts in diagnosis and treatment. *Orthopedics* 2015; **38**: 185-199 [PMID: 25760499 DOI: 10.3928/01477447-20150305-07]
- 21 **Bedi A**, Kelly BT. Femoroacetabular impingement. *J Bone Joint Surg Am* 2013; **95**: 82-92 [PMID: 23283377 DOI: 10.2106/JBJS.K.01219]
- 22 **Beaulé PE**, Le Duff MJ, Zaragoza E. Quality of life following femoral head-neck osteochondroplasty for femoroacetabular impingement. *J Bone Joint Surg Am* 2007; **89**: 773-779 [PMID: 17403799 DOI: 10.2106/00004623-200704000-00011]
- 23 **Cohen SB**, Huang R, Ciccotti MG, Dodson CC, Parvizi J. Treatment of femoroacetabular impingement in athletes using a mini-direct anterior approach. *Am J Sports Med* 2012; **40**: 1620-1627 [PMID: 22562788 DOI: 10.1177/0363546512445883]
- 24 **Espinosa N**, Beck M, Rothenfluh DA, Ganz R, Leunig M. Treatment of femoro-acetabular impingement: preliminary results of labral refixation. Surgical technique. *J Bone Joint Surg Am* 2007; **89** Suppl 2 Pt.1: 36-53 [PMID: 17332124 DOI: 10.2106/00004623-200605000-00001]
- 25 **Tibor LM**, Leunig M. The pathoanatomy and arthroscopic management of femoroacetabular impingement. *Bone Joint Res* 2012; **1**: 245-257 [PMID: 23610655 DOI: 10.1302/2046-3758.110.2000105]

- 26 **Steppacher SD**, Anwander H, Zurmühle CA, Tannast M, Siebenrock KA. Eighty percent of patients with surgical hip dislocation for femoroacetabular impingement have a good clinical result without osteoarthritis progression at 10 years. *Clin Orthop Relat Res* 2015; **473**: 1333-1341 [PMID: [25367110](#) DOI: [10.1007/s11999-014-4025-8](#)]
- 27 **MacFarlane RJ**, Konan S, El-Huseinny M, Haddad FS. A review of outcomes of the surgical management of femoroacetabular impingement. *Ann R Coll Surg Engl* 2014; **96**: 331-338 [PMID: [24992414](#) DOI: [10.1308/003588414X13946184900723](#)]
- 28 **Roos BD**, Roos MV, Camisa Júnior A, Lima EMU, Betto MD. Open versus arthroscopic approach in the treatment of femoroacetabular impingement: a case-control study with two-years follow up. *Rev Bras Ortop* 2017; **52**: 21-28 [PMID: [28971082](#) DOI: [10.1016/j.rboe.2017.07.007](#)]
- 29 **Gillespie JA**, Patil SR, Meek RD. Clinical outcome scores for arthroscopic femoral osteochondroplasty in femoroacetabular impingement: a quantitative systematic review. *Scott Med J* 2015; **60**: 13-22 [PMID: [25428942](#) DOI: [10.1177/0036933014560300](#)]
- 30 **Lund B**, Mygind-Klavsen B, Grønbech Nielsen T, Maagaard N, Kraemer O, Hölmich P, Winge S, Lind M. Danish Hip Arthroscopy Registry (DHAR): the outcome of patients with femoroacetabular impingement (FAI). *J Hip Preserv Surg* 2017; **4**: 170-177 [PMID: [28630739](#) DOI: [10.1093/jhps/hnx009](#)]
- 31 **Matsuda DK**, Khatod M, Antounian F, Burchette R, Bini S, Anthony FF, Harris J, Calipusan C. Multicenter outcomes of arthroscopic surgery for femoroacetabular impingement in the community hospital setting. *J Hip Preserv Surg* 2016; **3**: 318-324 [PMID: [29632692](#) DOI: [10.1093/jhps/hnw024](#)]
- 32 **Sariali E**, Vandenbulcke F. Clinical outcomes following arthroscopic treatment of femoro-acetabular impingement using a minimal traction approach and an initial capsulotomy. Minimum two year follow-up. *Int Orthop* 2018; **42**: 2549-2554 [PMID: [29572638](#) DOI: [10.1007/s00264-018-3904-0](#)]
- 33 **Briggs KK**, Soares E, Bhatia S, Philippon MJ. Postoperative alpha angle not associated with patient-centered midterm outcomes following hip arthroscopy for FAI. *Knee Surg Sports Traumatol Arthrosc* 2019; **27**: 3105-3109 [PMID: [29644385](#) DOI: [10.1007/s00167-018-4933-3](#)]



Published By Baishideng Publishing Group Inc
7041 Koll Center Parkway, Suite 160, Pleasanton, CA 94566, USA
Telephone: +1-925-2238242
E-mail: bpgoffice@wjgnet.com
Help Desk: <https://www.f6publishing.com/helpdesk>
<https://www.wjgnet.com>

