


World Journal of *Orthopedics*

World J Orthop 2020 January 18; 11(1): 1-75





MINIREVIEWS

- 1 Patents and intellectual property in orthopaedics and arthroplasty
Uzoigwe CE, Shoaib A

ORIGINAL ARTICLE

Basic Study

- 10 Double-row repair of rotator cuff tears: Comparing tendon contact area between techniques
Ng SHA, Tan CHJ

Case Control Study

- 18 National trends in total hip arthroplasty for traumatic hip fractures: An analysis of a nationwide all-payer database
Boniello AJ, Lieber AM, Denehy K, Cavanaugh P, Kerbel YE, Star A

Retrospective Cohort Study

- 27 Corrections in alpha angle following two different operative approaches for CAM-type femoral acetabular impingement - Ganz surgical hip dislocation *vs* anterior mini-open
Haug EC, Novicoff WM, Cui Q
- 36 Good accuracy of the alpha-defensin lateral flow test for hip periprosthetic joint infection: A pilot study in a retrospective cohort of 52 patients
Kuiper JW, Pander P, Vos SJ

Randomized Controlled Trial

- 47 Effect of deep transverse friction massage *vs* stretching on football players' performance
Fakhro MA, Chahine H, Srouf H, Hijazi K

META-ANALYSIS

- 57 Use of three-dimensional printing in preoperative planning in orthopaedic trauma surgery: A systematic review and meta-analysis
Morgan C, Khatri C, Hanna SA, Ashraffian H, Sarraf KM

CASE REPORT

- 68 Rapid spontaneous resolution of lumbar ganglion cysts: A case report
Chiarella V, Ramieri A, Giugliano M, Domenicucci M

ABOUT COVER

Editorial Board Member of *World Journal of Orthopedics*, Charles L Nelson, MD, Associate Professor, Chief Doctor, Surgeon, Department of Orthopaedic Surgery, University of Pennsylvania Perelman School of Medicine, Philadelphia, PA 19104, United States

AIMS AND SCOPE

The primary aim of *World Journal of Orthopedics* (*WJO*, *World J Orthop*) is to provide scholars and readers from various fields of orthopedics with a platform to publish high-quality basic and clinical research articles and communicate their research findings online.

WJO mainly publishes articles reporting research results and findings obtained in the field of orthopedics and covering a wide range of topics including arthroscopy, bone trauma, bone tumors, hand and foot surgery, joint surgery, orthopedic trauma, osteoarthritis, osteoporosis, pediatric orthopedics, spinal diseases, spine surgery, and sports medicine.

INDEXING/ABSTRACTING

The *WJO* is now abstracted and indexed in PubMed, PubMed Central, Emerging Sources Citation Index (Web of Science), Scopus, China National Knowledge Infrastructure (CNKI), China Science and Technology Journal Database (CSTJ), and Superstar Journals Database.

RESPONSIBLE EDITORS FOR THIS ISSUE

Responsible Electronic Editor: *Mei-Yi Liu*

Proofing Production Department Director: *Xiang Li*

NAME OF JOURNAL

World Journal of Orthopedics

ISSN

ISSN 2218-5836 (online)

LAUNCH DATE

November 18, 2010

FREQUENCY

Monthly

EDITORS-IN-CHIEF

Bao-Gan Peng

EDITORIAL BOARD MEMBERS

<http://www.wjgnet.com/2218-5836/editorialboard.htm>

EDITORIAL OFFICE

Ruo-Yu Ma, Director

PUBLICATION DATE

January 18, 2020

COPYRIGHT

© 2020 Baishideng Publishing Group Inc

INSTRUCTIONS TO AUTHORS

<https://www.wjgnet.com/bpg/gerinfo/204>

GUIDELINES FOR ETHICS DOCUMENTS

<https://www.wjgnet.com/bpg/GerInfo/287>

GUIDELINES FOR NON-NATIVE SPEAKERS OF ENGLISH

<https://www.wjgnet.com/bpg/gerinfo/240>

PUBLICATION MISCONDUCT

<https://www.wjgnet.com/bpg/gerinfo/208>

ARTICLE PROCESSING CHARGE

<https://www.wjgnet.com/bpg/gerinfo/242>

STEPS FOR SUBMITTING MANUSCRIPTS

<https://www.wjgnet.com/bpg/GerInfo/239>

ONLINE SUBMISSION

<https://www.f6publishing.com>



Rapid spontaneous resolution of lumbar ganglion cysts: A case report

Vito Chiarella, Alessandro Ramieri, Marco Giugliano, Maurizio Domenicucci

ORCID number: Alessandro Ramieri (0000-0002-3504-7381); Vito Chiarella (0000-0003-0286-2256); Marco Giugliano (0000-0002-6551-4163); Maurizio Domenicucci (0000-0002-9745-6439).

Author contributions: Domenicucci M and Ramieri A designed research; Ramieri A and Chiarella V performed research; Chiarella V and Giugliano M contributed analytic tools; Chiarella V and Ramieri A analyzed data; Ramieri A and Chiarella V wrote the paper.

Informed consent statement: Informed written consent was obtained from the patient.

Conflict-of-interest statement: The authors declare that they have no conflict of interest.

CARE Checklist (2016) statement: The manuscript was prepared and revised according to the CARE Checklist (2016).

Open-Access: This article is an open-access article which was selected by an in-house editor and fully peer-reviewed by external reviewers. It is distributed in accordance with the Creative Commons Attribution Non Commercial (CC BY-NC 4.0) license, which permits others to distribute, remix, adapt, build upon this work non-commercially, and license their derivative works on different terms, provided the original work is properly cited and the use is non-commercial. See: <http://creativecommons.org/licenses/by-nc/4.0/>

Manuscript source: Invited

Vito Chiarella, Marco Giugliano, Maurizio Domenicucci, Department of Neurological and Psychiatric, Sapienza University of Rome, Rome 00185, Italy

Alessandro Ramieri, Orthopaedic Division, Don Gnocchi Foundation, Milan 20148, Italy

Corresponding author: Alessandro Ramieri, MD, PhD, Research Fellow, Surgeon, Orthopaedic Division, Don Gnocchi Foundation Onlus Milan Italy, Maresciallo Caviglia 30, Rome 00100, Italy. alexramieri@libero.it

Abstract

BACKGROUND

To discuss the rare event of spontaneous resolution of a lumbar ganglion cyst, a personal case report and 25 cases culled from the literature were described in detail. We focused on demographic, classification, clinical and radiological findings, treatment, outcome and radiological resolution.

CASE SUMMARY

A 51-year-old man presented to our observation with complaints of low back and right leg pain. Lumbar magnetic resonance imaging (MRI) showed a L4-L5 ganglion cyst. The patient was referred to medical therapy and bracing. After 4 wk, he showed a complete resolution of pain. The complete spontaneous resolution of the cyst was demonstrated by the followed-up MRI.

CONCLUSION

Spontaneous resolution of lumbar ganglion is very rare and only 26 cases, including ours, were reported in literature. Different degrees of biomechanical impairment seem to play a fundamental role in the pathogenesis. Related symptoms are essentially represented by low back and/or radicular pain, without significant neurological disorders. Anti-inflammatory drugs, light unloading exercises and brace could be recommended to administrated pain and decrease facet loads. Mean time for clinical improvement was 7 mo, while MRI disappearance occurred in an average time of 11 mo. Therefore, surgery should be applied when conservative treatment, prolonged at least 6 mo, fails.

Key words: Lumbar ganglion cyst; Spontaneous resolution; Conservative treatment; Radiological disappearance; Case report

©The Author(s) 2020. Published by Baishideng Publishing Group Inc. All rights reserved.

Core tip: Our paper is an original study that analyzes in detail and for the first time, on

manuscript

Received: May 20, 2019**Peer-review started:** May 26, 2019**First decision:** August 31, 2019**Revised:** September 23, 2019**Accepted:** October 27, 2019**Article in press:** October 27, 2019**Published online:** January 18, 2020**P-Reviewer:** Kahveci R, Li S, Peng BG**S-Editor:** Zhang L**L-Editor:** A**E-Editor:** Liu MY

the basis of a personal observation, the clinical and radiological scenario related to the rare spontaneous resolution of a lumbar ganglion cyst. The term “ganglion cyst” was used according to the recent our morphological classification. Discussing natural history and biomechanical features of this pathology, we propose some recommendations that could be adopted in cases with a propensity to spontaneous resolution.

Citation: Chiarella V, Ramieri A, Giugliano M, Domenicucci M. Rapid spontaneous resolution of lumbar ganglion cysts: A case report. *World J Orthop* 2020; 11(1): 68-75
URL: <https://www.wjnet.com/2218-5836/full/v11/i1/68.htm>
DOI: <https://dx.doi.org/10.5312/wjo.v11.i1.68>

INTRODUCTION

Spinal articular cysts are more frequently found in the lumbar spine and often they are treated by surgical cystectomy, with or without spinal instrumentation. Recently, the term “ganglion” was proposed to identify the pathological entity, together with an original morphological classification to define possible localizations^[1]. Remission of this type of cyst after conservative treatment was not so frequently reported in literature^[2]. We report a case of clinical and radiological resolution of a symptomatic lumbar ganglion cyst (LGC) after conservative treatment, discussing mechanisms that could have led to its disappearance.

CASE PRESENTATION

Chief complaints

A 51-year-old man presented to our observation with complaints of low back and right leg pain with a L5 dermatomeric distribution.

History of past illness

His disorders persisted from 10 d.

Personal and family history

Personal and family history were negative for medical or surgical diseases.

Laboratory examinations

Lasègue test was highly positive, without neurological deficits. Tendon reflexes were normal. Laboratory tests were normal.

Imaging examinations

Lumbar MRI showed a cystic lesion in the L4-L5 spinal canal, medial and adjacent to the right internal facet joint, iso-hypointense in T1 and hyperintense in T2-weighted images, compatible with a ganglion cyst.

FINAL DIAGNOSIS

Final diagnosis was: A symptomatic right L4-L5 LGC.

TREATMENT

After discussion on treatment options, the patient was referred to medical therapy, based on NSAID, SAID for 10 d and lumbar bracing. Clinical follow-up was instituted after 4 wk, advising the patient to call us in case of neurological worsening. Surprisingly, 4 wk later, the patient showed complete resolution of the symptoms. We scheduled a new lumbar MRI after 2 d, in order to evaluate the evolution of the lesion. T1 and T2 sequences demonstrated the complete resolution of the LGC as well as compression of the right L5 nerve root (Figure 1).

We conducted a PubMed research on literature published until October 2018. The search was undertaken using the keywords “lumbar cyst”, “ganglion cyst”, “synovial

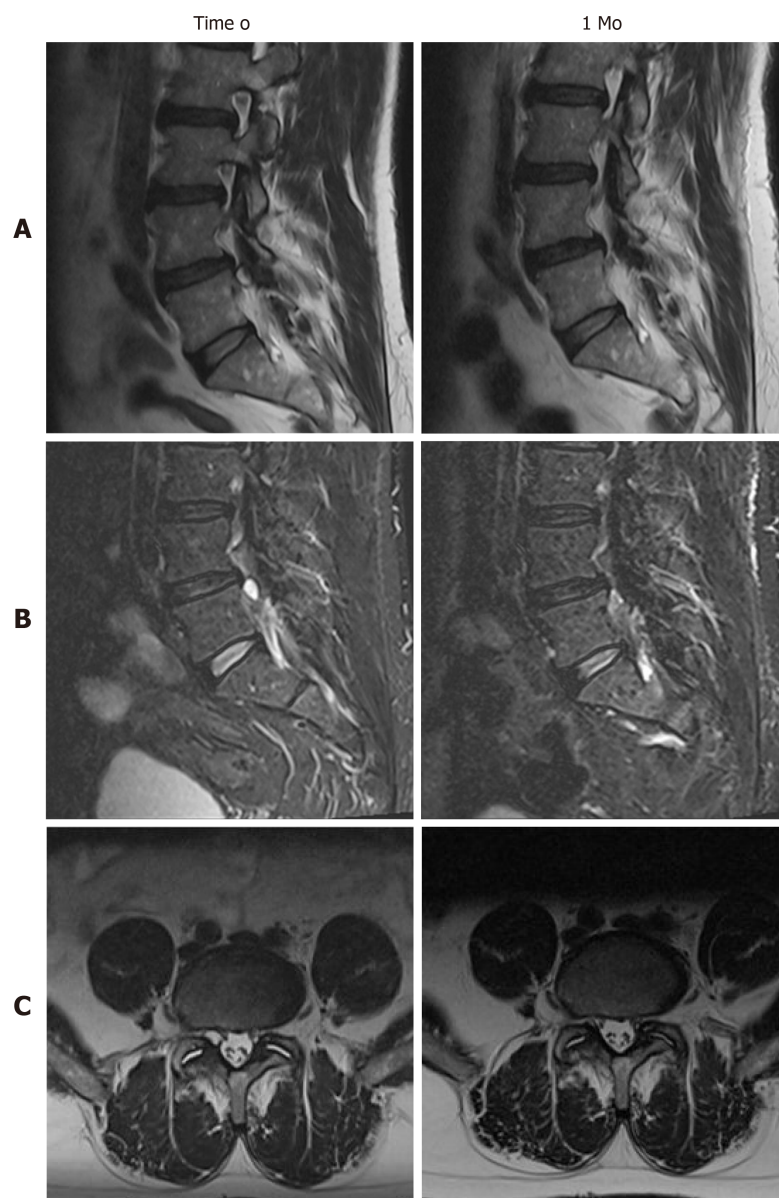


Figure 1 Radiological detection of the spontaneous disappearance of our right L4-L5 ganglion cyst, comparison of magnetic resonance imaging findings at observation (time 0) and follow-up (1 mo). A: Sagittal T2 images; B: Sagittal STIR T2 images; C: Axial T2 images: note the decrease of interfacet fluid amount at 1 mo follow-up.

cyst”, “juxtafacet cyst”, “facet joint cyst”, and “resolution”. References from the retrieved reports were checked to identify other possible results. We enrolled cases with radiological documented remission of LGC and/or clinical improvement after conservative treatment based on rest, lumbar bracing, drugs and/or kinesiotherapy, excluding all those treated by surgery or deep percutaneous procedures (*e.g.* radiofrequency, epidural injection *etc.*). For every case collected, we analyzed age, sex, symptoms, neurological deficits and treatment received. When radiological data were available, we classified the localization of the LGC following our previous original classification^[1] and we searched for the presence of instability signs, even in the follow-up images. Outcome clinical data were classified in 4 categories: (1) Excellent; (2) Good; (3) Fair; or (4) Poor, according to Macnab^[3] (Table 1).

OUTCOME AND FOLLOW-UP

Demographic, clinical and radiological data were summarized in Table 2. The total number of cases, including ours, was 26. Male: Female ratio was 1.6 (16 males and 10 females) and the mean age was 56 (range 15-75). Most of localizations were in L4-L5 (17; 65%), followed by L5-S1 (6; 23%) and L3-L4 (3; 12%). In 1 case LGCs were

Table 1 Macnab^[3] criteria used for measuring outcome

| Grade | Criteria |
|-----------|-------------------------------------------------------------------------------------------------------------------------------------------|
| Excellent | No pain; no restriction of activity |
| Good | Occasional back or leg pain of sufficient severity to interfere with the patient's ability to do his normal work |
| Fair | Improved functional capacity, but handicapped by intermittent pain of sufficient severity to curtail or modify work or leisure activities |
| Poor | No improvement or insufficient improvement to enable increase in activities; further operative intervention required |

bilateral. All classified LGCs (21; 81%) were in the spinal canal and medium: Medium-external in 9 cases (33%), medium-internal in 4 (15%), purely medium in 7 (26%); 1 case (4 %) was purely external (intra-foraminal); in 6 cases (22%) there were no data available to classify the LGC. In all papers the radiological diagnosis was made by MRI, except for 2 cases published before year 2000 in which diagnosis was made by CT scans. Associated spondylolisthesis was detected in 5 (19%) cases, while increased interfacet fluid in 9 (33%). Clinical presentation was constantly characterized by single or double radiculopathy due to irritation of exiting and/or traversing nerve roots. Low back pain accompanied radicular pain 11 times (42%), while pure low back pain was the only symptom in 2 cases (8%). Sensory radicular deficits were identified in 4 cases (15%). There were no cases of motor deficits. Before observation, the mean duration of symptoms was 6.8 mo (range 5 d - 36 mo). When reported (18 cases; 70%), among conservative treatments, a lumbar brace was used in 5 cases (28%), nonsteroidal anti-inflammatory drugs in 13 (72%), corticosteroids in 2 (11%) as well as gabapentin. Rest was recommended in 10 cases (55%), while kinesiotherapy (especially unloading exercises) in 8 (44%). Chiropractic manipulation was performed on 4 patients (22%). Radiological reduction or resolution of the lesion were evaluated by CT or MRI in 21 cases (81%), but in 4 cases images were not available in papers. The mean time for radiological resolution was 11 mo (range 2 d - 48 mo). Signs of instability remained unchanged, except in 2 cases (13%) for reduction of interfacet fluid amount. The mean time for clinical improvement was 7 mo (range 2 d - 24 mo). Final clinical condition was good or excellent in all cases.

DISCUSSION

The number of reported synovial cysts of the lumbar spine have been increasing probably due to the availability of magnetic resonance imaging technique. Recently, the term “ganglion” and a new morphological classification were introduced to identify the pathological entity and its localization^[1].

LGCs are usually associated with osteoarthritis of the adjacent facet joint, degenerative spondylosis and/or spondylolisthesis, particularly in middle aged or elderly patients. The majority of such cysts require surgical resection due to persistent radicular symptoms and/or occasional paresis^[4], that could be associated to fusion if pre-operative instability is detected^[1]. While ganglion cysts elsewhere (*e.g.* the wrist) spontaneously resolve in 40% of patients, the spontaneous resolution of root compression with radiological disappearance of LGC were rarely reported in literature.

We collected 24 cases from the literature^[2,4,5] that affected the adult lumbar spine in adults and one more in the adolescent spine (Table 2)^[6-22]. All ganglia, detected by CT or MRI and classified according to Domenicucci *et al*^[1], were in the spinal canal and in medium position (95% of cases), except one reported by Tepe *et al*^[15] that was purely external. Most were associated to indirect signs of segmental hypermobility (*e.g.* increase of synovial fluid) or proper instability. They were able to give, exiting and/or transiting nerve roots, irritation and compression, with prevalently single radiculopathy but without significant neurological deficits. Their resolution, demonstrated by radiological follow-up in 17 cases (68%), was always associated to substantial clinical improvement or full recovery. Indirect radiological signs of segmental instability remained unchanged after resolution, except in one case^[10] in which occurred the reduction of interfacet synovial fluid amount, similar to our MRI follow-up findings.

Explaining the spontaneous resolution of LGC is complicated, in part because of the high prevalence of surgical removal. Some authors have supported the thesis that progressive degenerative changes of the facet joint lead to fixation of the previously hypermobile facets, so that intra-articular pressure decreases and the cyst shrinks^[6]. The cyst may also undergo degenerative changes, losing connection with the facet

Table 2 Regression of lumbar ganglion cyst: Our case and 25 from literature

| | Author/ Yr | Age | Sex | Level/ Side | Classi- fication ¹ | Imag- ing | Instabi- lity | Symp- toms | Dura- tion | Deficit | Treat- ment | Imag- ing control /Time | Instabi- lity control | Control | Out- come ² |
|----|------------------------------------------------|-----|-----|-----------------|----------------------------------|--------------|------------------|---------------|---------------|---------|-------------------------|------------------------------------------|-----------------------------|---------|---------------------------|
| 1 | Mercader <i>et al</i> ^[2] , 1985 | 65 | F | L4-L5/ right | Med-Int | CT | SPL | Rad | 8 mo | \ | Rest-NSAID-KT-brace | CT reduction/3 mo | SPL | 3 mo | Good |
| 2 | Coulier <i>et al</i> ^[4] , 1998 | 47 | F | L4-L5/bilat | Med/Med | CT | NR | LBP | NR | \ | Brace | CT/20 mo: left resolution, right reduced | NR | 20 mo | Excellent |
| 3 | Maezawa <i>et al</i> ^[5] , 2000 | 15 | M | L4-L5/left | Med | MRI | NR | LBP + Rad | 2 mo | \ | Brace | MRI resolution/3 mo | NR | 3 mo | Excellent |
| 4 | Houten <i>et al</i> ^[6] , 2003 | 64 | M | L4-L5/ right | NA | MRI | NR | LBP + Rad | 7 mo | \ | Conservative (na) | MRI resolution/1 mo (na images) | NR | 1 mo | Good |
| 5 | | 57 | F | L4-L5/left | NA | MRI | NR | Rad | 5 mo | \ | NSAID-gabapentin | MRI resolution/8 mo (na images) | NR | 8 mo | Good |
| 6 | | 58 | F | L4-L5/left | Med-Ext | MRI | NR | LBP + Rad | 18 mo | \ | Conservative (na) | MRI resolution/4 mo | NR | 4 mo | Good |
| 7 | Swartz <i>et al</i> ^[7] , 2003 | 58 | F | L5-S1/ right | Med-Ext | MRI | SPL | Rad | 1 mo | \ | Rest-NSAID-KT-brace | MRI resolution/18 mo | SPL | 12 mo | Good |
| 8 | Cox ^[8] , 2005 | 71 | M | L3-L4/ right | NA | MRI | NR | Rad | 6 mo | \ | Rest-NSAID-chiropractic | MRI reduction/9 mo | NR | 9 mo | Good |
| 9 | | 59 | F | L4-L5/left | Med-Ext | MRI | IFF ^a | Rad | NR | \ | Rest-NSAID-chiropractic | Not performed | NR | 2 mo | Excellent |
| 10 | Ewald <i>et al</i> ^[9] , 2005 | 65 | F | L4-L5/ right | Med-Ext | MRI | SPL | Rad | 5 mo | \ | Rest-NSAID-KT | MRI reduction/3 mo | SPL | 3 mo | Good |
| 11 | Illerhaus <i>et al</i> ^[10] , 2005 | 50 | M | L4-L5/ right | Med-Int | MRI | IFF ^a | LBP + Rad | 12 mo | \ | NSAID-KT | MRI resolution/7 mo | IFF ^a | 7 mo | Good |
| 12 | Beukeelaar <i>et al</i> ^[11] , 2010 | 59 | M | L4-L5/ right | Med | MRI | IFF ^a | LBP + Rad | 2 mo | L5 S | Conservative (na) | MRI reduction/3 mo | IFF ^b | 3 mo | Excellent |
| 13 | Bashir <i>et al</i> ^[12] , 2012 | 47 | M | L4-L5/ right | NA | MRI | NR | Rad | 6 mo | \ | Rest-NSAID-KT | Not performed | NR | 24 mo | Excellent |
| 14 | | 58 | M | L4-L5/left | Med | MRI | IFF ^a | Rad | 3 mo | \ | Rest-NSAID-KT | MRI resolution/2 mo (na images) | NR | 2 mo | Excellent |
| 15 | | 41 | M | L5-S1/ right | NA | MRI | NR | Rad | 12 mo | \ | Rest-NSAID-KT | Not performed | NR | 24 mo | Excellent |

| | | | | | | | | | | | | | | | |
|----|---------------------------------------------|----|---|-----------------|-------------|-----|------------------|--------------|-------|------|-----------------------------------|-----------------------------------------------------------|------------------|-------|----------------|
| 16 | Barazi <i>et al</i> ^[13] , 2012 | 48 | F | L4-L5/ right | NA | MRI | NR | Rad | NR | \ | Conser- vative (na) | MRI resolu- tion/8 mo (na images) | NR | 8 mo | Good |
| 17 | Cox <i>et al</i> ^[14] , 2012 | 75 | M | L3- L4/left | Med-Int | MRI | NR | Rad | 36 mo | \ | Chiro- pactic | Not perfor- med | NR | 2 mo | Good |
| 18 | Tepe <i>et al</i> ^[15] , 2012 | 64 | M | L5- S1/left | Ext | MRI | SPL | Rad | 2 mo | L5 S | Conser- vative (na) | MRI reduc- tion/1 yr, resolu- tion/4 yr | SPL | 12 mo | Good |
| 19 | Mattei <i>et al</i> ^[16] , 2012 | 56 | M | L5-S1/ right | Med | MRI | IFF ^a | Rad | NR | S1 S | NSAID- KT | MRI resolu- tion/13 mo | IFF ^a | 1 mo | Excel- lent |
| 20 | Pulhorn <i>et al</i> ^[17] , 2012 | 72 | M | L4-L5/ right | Med- Ext | MRI | IFF ^a | LBP | NR | \ | Conser- vative (na) | MRI resolu- tion/18 mo | IFF ^a | 18 mo | Excel- lent |
| 21 | Ngo <i>et al</i> ^[18] , 2013 | 58 | F | L4-L5/ right | Med- Ext | MRI | NR | LBP + Rad | 5 d | \ | SAID- chiro- pactic | Not perfor- med | NR | 3 mo | Excel- lent |
| 22 | Kim <i>et al</i> ^[19] , 2015 | 58 | M | L3- L4/left | Med- Ext | MRI | SPL | LBP + Rad | 4 mo | \ | Conser- vative (na) | MRI resolu- tion/4 yr | SPL | 1 mo | Excel- lent |
| 23 | Delen <i>et al</i> ^[20] , 2015 | 63 | M | L5- S1/left | Med | MRI | IFF ^a | LBP + Rad | 1 mo | S1 S | NSAID- gaba- pentin | MRI resolu- tion/1 mo | ↑IFF | 1 mo | Excel- lent |
| 24 | Sinha <i>et al</i> ^[21] , 2016 | 66 | M | L5- S1/left | Med-Int | MRI | NR | LBP + Rad | 12 mo | \ | Conser- vative (na) | MRI resolu- tion/12 mo | NR | 12 mo | Good |
| 25 | Ucler <i>et al</i> ^[22] , 2017 | 36 | F | L4-L5/ right | Med- Ext | MRI | IFF ^a | LBP + Rad | 10 d | \ | Rest | MRI resolu- tion/2 d | IFF ^a | 2 d | Excel- lent |
| 26 | Our case | 51 | M | L4-L5/ right | Med- Ext | MRI | IFF ^a | LBP + Rad | 10 d | \ | Rest- NSAID- SAID- brace | MRI resolu- tion/1 mo | IFF ^b | 1 mo | Excel- lent |

¹Domenicucci *et al*^[11];²Macnab^[3]; SPL: Spondylolisthesis; IFF: Interfacet fluid; LBP: Low back pain; Rad: Radiculopathy; S: Sensory deficits; NSAID: Nonsteroidal anti-inflammatory drug; SAID: Steroidal anti-inflammatory drug; KT: Kinesiotherapy; NR: Not reported; NA: Not available data; med: Medial; int: Internal; ext: External; MRI: Magnetic resonance; CT: Computed tomography;^aIncrease;^bDecrease.

joint and resolving because of a lack of supply^[9]. Other possible causes for resolution include rupture, as seen in other different articular districts of the human body, with the extrusion of its contents, followed by reabsorption of the cystic wall^[7]; or reduction of the local intra-articular forces that contributed to synovial herniation through the facet joint capsule. The last hypothesis could be supplied by the antigravitary lumbar bracing or unloading exercises usage in most cases described, including ours (11/19; 58%). Also chiropractic manipulations seemed clinically effective^[14,18], though only one paper^[8] showed the radiological resolution of the cyst. So, in our patient, who underwent treatment with NSAIDs, corticosteroids and lumbo-sacral bracing, LGC probably resolved because of the association between decreased inflammatory fluid production and microtraumatic loads.

An early clinical and radiological remission as ours is referred in only 2 cases^[20,22]. Two fast clinical resolutions were previously reported, but without radiological confirmation of the cyst reabsorption^[6,18]. Other two early clinical improvement were described, but radiological resolution was achieved after over one year^[16,19]. Generally, clinical improvement and radiological remission occurred on average respectively in 7 and 11 mo.

CONCLUSION

The natural history of spinal ganglion cysts is unknown and there is scant literature involving their non-surgical therapy. In the lumbar spine, different degrees of biomechanical impairment seem to play a fundamental role in their pathogenesis, but LGCs should be considered as dynamic entities. In other words, formation and resolution appear strictly influenced by event and regression of inflammatory and mechanical phenomena.

Although rarely, the symptoms related to LGC, essentially represented by low back and/or radicular pain, could regress spontaneously, if cystic evolution (enlargement, hemorrhage, worsening of spondylolisthesis) with associated worsening of neurological status does not occur.

Our case is the twenty-sixth in literature. Based on our experience and reviewing data, we can suggest that in case of absence of neurological deficits and in selected compliant patients, percutaneous procedures or surgery should be considered when conservative treatment, consisting of rest, pharmacological therapy, kinesiotherapy and/or lumbar bracing, prolonged at least for 6 mo, fails to produce symptoms control. We recommend, anti-inflammatory drugs and light unloading exercises to control pain and reduce intra-cystic fluid, but also rest and lumbar bracing to achieve the decrease of loads on arthritic facets. We also recommend MRI confirmation of cyst resolution, which can be helpful to understand mechanisms responsible of resolution.

REFERENCES

- 1 **Domenicucci M**, Ramieri A, Marruzzo D, Missori P, Miscusi M, Tarantino R, Delfini R. Lumbar ganglion cyst: Nosology, surgical management and proposal of a new classification based on 34 personal cases and literature review. *World J Orthop* 2017; **8**: 697-704 [PMID: [28979853](#) DOI: [10.5312/wjo.v8.i9.697](#)]
- 2 **Mercader J**, Muñoz Gomez J, Cardenal C. Intraspinial synovial cyst: diagnosis by CT. Follow-up and spontaneous remission. *Neuroradiology* 1985; **27**: 346-348 [PMID: [4047392](#) DOI: [10.1007/BF00339570](#)]
- 3 **Macnab I**. Negative disc exploration. An analysis of the causes of nerve-root involvement in sixty-eight patients. *J Bone Joint Surg Am* 1971; **53**: 891-903 [PMID: [4326746](#) DOI: [10.2106/00004623-197153050-00004](#)]
- 4 **Coulter B**, Ghosez JP, Mailleux P. Computed tomography diagnosis of clinically well-tolerated bilateral lumbar vertebral synovial cysts. *JBR-BTR* 1998; **81**: 141-143
- 5 **Maezawa Y**, Baba H, Uchida K, Furusawa N, Kubota C, Yoshizawa K. Spontaneous remission of a solitary intraspinal synovial cyst of the lumbar spine. *Eur Spine J* 2000; **9**: 85-87 [PMID: [10766084](#) DOI: [10.1007/s005860050016](#)]
- 6 **Houten JK**, Sanderson SP, Cooper PR. Spontaneous regression of symptomatic lumbar synovial cysts. Report of three cases. *J Neurosurg* 2003; **99**: 235-238 [PMID: [12956468](#) DOI: [10.3171/spi.2003.99.2.0235](#)]
- 7 **Swartz PG**, Murtagh FR. Spontaneous resolution of an intraspinal synovial cyst. *AJNR Am J Neuroradiol* 2003; **24**: 1261-1263 [PMID: [12812968](#)]
- 8 **Cox JM**, Cox JM 2nd. Chiropractic treatment of lumbar spine synovial cysts: a report of two cases. *J Manipulative Physiol Ther* 2005; **28**: 143-147 [PMID: [15800515](#) DOI: [10.1016/j.jmpt.2005.01.011](#)]
- 9 **Ewald C**, Kalff R. Resolution of a synovial cyst of the lumbar spine without surgical therapy -- a case report. *Zentralbl Neurochir* 2005; **66**: 147-151 [PMID: [16116558](#) DOI: [10.1055/s-2005-836475](#)]
- 10 **Illerhaus B**, Scholz M, Pechlivanis I, Gries N, König M, Harders A. [MRT follow-up study of spontaneous regression of lumbar articular facet cyst]. *Rofo* 2005; **177**: 1717-1719 [PMID: [16333798](#) DOI: [10.1055/s-2005-858823](#)]
- 11 **de Beukelaar JW**, Dallenga A, de Jong GJ, de Winter KJ, Bakker SL. [Juxta facet cyst of the lumbar spine: an uncommon cause of lumbar radiculopathy]. *Ned Tijdschr Geneesk* 2010; **154**: A1673 [PMID: [20619028](#)]
- 12 **Bashir el F**, Ajani O. Management of lumbar spine juxtafacet cysts. *World Neurosurg* 2012; **77**: 141-146 [PMID: [22405394](#) DOI: [10.1016/j.wneu.2011.06.034](#)]
- 13 **Barazi S**, D'Urso P, Thomas N. Concomitant Spontaneous Resolution and Appearance of a New Contralateral Lumbar Synovial Cyst: Case Report. *J Neurol Surg Part A Cent Eur Neurosurg* 2012 [DOI: [10.1055/s-0032-1316217](#)]
- 14 **Cox JM**. Chiropractic management of a patient with lumbar spine pain due to synovial cyst: a case report. *J Chiropr Med* 2012; **11**: 7-15 [PMID: [22942836](#) DOI: [10.1016/j.jcm.2011.08.007](#)]
- 15 **Tepe S**, Kara M, Iplikcioglu AC. Spontaneous Disappearance of Lumbar Synovial Cyst. *J Neurological Sciences* 2012; **29**: 154-158
- 16 **Mattei TA**, Goulart CR, McCall TD. Pathophysiology of regression of synovial cysts of the lumbar spine: the 'anti-inflammatory hypothesis'. *Med Hypotheses* 2012; **79**: 813-818 [PMID: [23021571](#) DOI: [10.1016/j.mehy.2012.08.034](#)]
- 17 **Pulhorn H**, Murphy M. Spontaneous resolution of a symptomatic synovial cyst of the lumbar spine. *Br J Neurosurg* 2012; **26**: 123-124 [PMID: [22122711](#) DOI: [10.3109/02688697.2011.595847](#)]
- 18 **Ngo T**, Decina P, Hsu W. Spontaneous resolution of symptoms associated with a facet synovial cyst in an adult female - a case report. *J Can Chiropr Assoc* 2013; **57**: 87-92 [PMID: [23483069](#)]
- 19 **Kim HS**, Ju CI, Kim SW, Kim SH. Contralateral Juxtafacet Cyst Development after the Spontaneous Resolution of a Previous Facet Cyst. *J Korean Neurosurg Soc* 2015; **58**: 563-565 [PMID: [26819695](#) DOI: [10.3340/jkns.2015.58.6.563](#)]
- 20 **Delen E**, Tütüncüler B, Akıncı AT, Kunduracılar M. Spontaneous Regression of a Symptomatic Lumbar Facet Synovial Cyst in One Month. *Sch J Appl Med Sci* 2015; **3**: 1587-1589
- 21 **Sinha P**, Panbehchi S, Lee MT, Parekh T, Pal D. Spontaneous resolution of symptomatic lumbar synovial cyst. *J Surg Case Rep* 2016; **2016**: rjw166 [PMID: [29034070](#) DOI: [10.1093/jscr/rjw166](#)]

- 22 **Ucler N**, Ozturk S, Gulkesen A, Kaplan M. Rapid spontaneous regression of a lumbar juxta-facet cyst. *Neurol India* 2017; **65**: 417-418 [PMID: [28290421](#) DOI: [10.4103/neuroindia.NI_596_16](#)]



Published By Baishideng Publishing Group Inc
7041 Koll Center Parkway, Suite 160, Pleasanton, CA 94566, USA
Telephone: +1-925-2238242
E-mail: bpgoffice@wjgnet.com
Help Desk: <https://www.f6publishing.com/helpdesk>
<https://www.wjgnet.com>

