

# World Journal of *Orthopedics*

*World J Orthop* 2020 October 18; 11(10): 418-474



**ORIGINAL ARTICLE****Basic Study**

- 418 Association of vitamin D and knee osteoarthritis in younger individuals

*Tripathy SK, Gantaguru A, Nanda SN, Velagada S, Srinivasan A, Mangaraj M*

**Retrospective Study**

- 426 Mortality following combined fractures of the hip and proximal humerus

*Haque A, Singh HP*

- 431 Early clinical outcome and learning curve following unilateral primary total knee arthroplasty after introduction of a novel total knee arthroplasty system

*Omari A, Troelsen A, Husted H, Nielsen CS, Gromov K*

**Randomized Controlled Trial**

- 442 Highly cross-linked versus conventional polyethylene inserts in total hip arthroplasty, a five-year Roentgen stereophotogrammetric analysis randomised controlled trial

*van Loon J, Hoornenborg D, Sierevelt I, Opdam KT, Kerkhoffs GM, Haverkamp D*

**CASE REPORT**

- 453 Long-term effect of intrathecal baclofen treatment on bone health and body composition after spinal cord injury: A case matched report

*Ifon DE, Ghatas MP, Davis JC, Khalil RE, Adler RA, Gorgey AS*

- 465 Conversion to reverse shoulder arthroplasty fifty-one years after shoulder arthrodesis: A case report

*Dogger MN, Bommel AFV, Alta TDW, van Noort A*

**LETTER TO THE EDITOR**

- 473 Trochanteric bursitis information on the internet; can we trust the information presented?

*Tyrrell R, Kelly M, Kennedy C*

**ABOUT COVER**

Peer reviewer of *World Journal of Orthopedics*, Dr. Milan Kravarski is an Orthopedic and Trauma Surgeon and Practicing Consultant in the Canton of Nidwalden-Hospital (Stans, Switzerland). Having received his medical diploma from Medical Faculty of University of Belgrade (Serbia) in 2003, he passed the recognition exams of medical diploma for EU at the University of Ljubljana (Slovenia) in 2011. He received his medical diploma from the University of Bern (Switzerland) in 2013. Dr. Kravarski undertook his postgraduate training at the University Hospital of Bern as well as in several other canton, regional and city hospitals throughout Switzerland. His professional interests involve pathology and traumatology of the foot and ankle, and hip joint. Treatment of the diabetic foot as well as ultrasonography and traumatology of the musculoskeletal system complete his professional portrait. (L-Editor: Filipodia)

**AIMS AND SCOPE**

The primary aim of *World Journal of Orthopedics* (*WJO*, *World J Orthop*) is to provide scholars and readers from various fields of orthopedics with a platform to publish high-quality basic and clinical research articles and communicate their research findings online.

*WJO* mainly publishes articles reporting research results and findings obtained in the field of orthopedics and covering a wide range of topics including arthroscopy, bone trauma, bone tumors, hand and foot surgery, joint surgery, orthopedic trauma, osteoarthritis, osteoporosis, pediatric orthopedics, spinal diseases, spine surgery, and sports medicine.

**INDEXING/ABSTRACTING**

The *WJO* is now abstracted and indexed in PubMed, PubMed Central, Emerging Sources Citation Index (Web of Science), Scopus, China National Knowledge Infrastructure (CNKI), China Science and Technology Journal Database (CSTJ), and Superstar Journals Database.

**RESPONSIBLE EDITORS FOR THIS ISSUE**

Production Editor: Yan-Xia Xing; Production Department Director: Xiang Li; Editorial Office Director: Jia-Ping Yan.

**NAME OF JOURNAL**

*World Journal of Orthopedics*

**ISSN**

ISSN 2218-5836 (online)

**LAUNCH DATE**

November 18, 2010

**FREQUENCY**

Monthly

**EDITORS-IN-CHIEF**

Massimiliano Leigheb

**EDITORIAL BOARD MEMBERS**

<http://www.wjgnet.com/2218-5836/editorialboard.htm>

**PUBLICATION DATE**

October 18, 2020

**COPYRIGHT**

© 2020 Baishideng Publishing Group Inc

**INSTRUCTIONS TO AUTHORS**

<https://www.wjgnet.com/bpg/gerinfo/204>

**GUIDELINES FOR ETHICS DOCUMENTS**

<https://www.wjgnet.com/bpg/GerInfo/287>

**GUIDELINES FOR NON-NATIVE SPEAKERS OF ENGLISH**

<https://www.wjgnet.com/bpg/gerinfo/240>

**PUBLICATION ETHICS**

<https://www.wjgnet.com/bpg/GerInfo/288>

**PUBLICATION MISCONDUCT**

<https://www.wjgnet.com/bpg/gerinfo/208>

**ARTICLE PROCESSING CHARGE**

<https://www.wjgnet.com/bpg/gerinfo/242>

**STEPS FOR SUBMITTING MANUSCRIPTS**

<https://www.wjgnet.com/bpg/GerInfo/239>

**ONLINE SUBMISSION**

<https://www.f6publishing.com>



## Conversion to reverse shoulder arthroplasty fifty-one years after shoulder arthrodesis: A case report

Melissa N Dogger, Annelies F van Bommel, Tjarco D W Alta, Arthur van Noort

**ORCID number:** Melissa N Dogger 0000-0002-0613-4945; Annelies F van Bommel 0000-0001-9618-7428; Tjarco D W Alta 0000-0002-3512-7840; Arthur van Noort 0000-0003-1389-9708.

**Author contributions:** Alta TDW, van Noort A, and van Bommel AF were involved in the diagnosis and treatment of the case; Dogger MN, van Noort A, and van Bommel AF helped to draft the manuscript; all authors reviewed and edited the manuscript and approved the final version of the manuscript.

**Informed consent statement:** Written informed consent was obtained from the patient for the publication of his anonymized information to be published in this article.

**Conflict-of-interest statement:** No potential conflicts of interest.

**CARE Checklist (2016) statement:** The authors have read the CARE Checklist (2016), and the manuscript was prepared according to the CARE Checklist (2016).

**Open-Access:** This article is an open-access article that was selected by an in-house editor and fully peer-reviewed by external reviewers. It is distributed in accordance with the Creative

Melissa N Dogger, Annelies F van Bommel, Tjarco D W Alta, Arthur van Noort, Department of Orthopedic Surgery, Spaarne Gasthuis, Hoofddorp 2134 TM, Netherlands

**Corresponding author:** Melissa N Dogger, MD, Doctor, Department of Orthopedic Surgery, Spaarne Gasthuis, Spaarnepoort 1, Hoofddorp 2134 TM, Netherlands. [m.n.dogger@gmail.com](mailto:m.n.dogger@gmail.com)

### Abstract

#### BACKGROUND

Patients with a shoulder arthrodesis generally experience restriction in range of motion and limitations in activities of daily living. In addition, up to one-third of the patients deals with serious peri scapular pain. The conversion of a shoulder arthrodesis in a reverse shoulder arthroplasty (RSA) has been described as an effective treatment to achieve better function and decreased pain, although literature is sparse. We present the case of a conversion from a painful shoulder arthrodesis to RSA, after a 51 years interval.

#### CASE SUMMARY

A 71-year-old male presented with severe peri scapular pain and limited function 51 years after shoulder arthrodesis. Preoperative workup showed a normal bone stock of the glenoid and an intact axillary nerve, but atrophic posterior part of the deltoid muscle. The shoulder arthrodesis was successfully converted to RSA. Twelve months postoperative the patient was very satisfied. He has no pain at rest, nor with exercise and experienced definite improvements in activities of daily living, despite his limited range of motion.

#### CONCLUSION

Conversion from shoulder arthrodesis to a RSA can be performed safely, with a high chance of peri scapular pain relief; even after a longstanding arthrodesis.

**Key Words:** Shoulder arthrodesis; Conversion; Reverse shoulder arthroplasty; Electromyography; Case report

©The Author(s) 2020. Published by Baishideng Publishing Group Inc. All rights reserved.

**Core Tip:** To the best of our knowledge, this unique presentation of a conversion from shoulder arthrodesis to reverse shoulder arthroplasty is the sixth reported case. This

Commons Attribution NonCommercial (CC BY-NC 4.0) license, which permits others to distribute, remix, adapt, build upon this work non-commercially, and license their derivative works on different terms, provided the original work is properly cited and the use is non-commercial. See: <http://creativecommons.org/licenses/by-nc/4.0/>

**Manuscript source:** Unsolicited manuscript

**Received:** May 19, 2020

**Peer-review started:** May 19, 2020

**First decision:** July 21, 2020

**Revised:** July 23, 2020

**Accepted:** September 4, 2020

**Article in press:** September 4, 2020

**Published online:** October 18, 2020

**P-Reviewer:** Koumantakis GA

**S-Editor:** Gao CC

**L-Editor:** A

**P-Editor:** Li JH



treatment should be considered in patients with a painful shoulder arthrodesis. Requirements for a successful procedure are adequate bone stock and a functional deltoid muscle. The treatment can be performed safely, with a high chance of peri scapular pain relief; even after a longstanding arthrodesis. Improvements of activities of daily living are noticed, with varying results of shoulder function.

**Citation:** Dogger MN, Bommel AFV, Alta TDW, van Noort A. Conversion to reverse shoulder arthroplasty fifty-one years after shoulder arthrodesis: A case report. *World J Orthop* 2020; 11(10): 465-472

**URL:** <https://www.wjgnet.com/2218-5836/full/v11/i10/465.htm>

**DOI:** <https://dx.doi.org/10.5312/wjo.v11.i10.465>

## INTRODUCTION

Shoulder arthrodesis is a salvage procedure for patients with shoulder dysfunction when other surgical options are limited. Indications include post-traumatic brachial plexus injuries, paralysis of the deltoid muscle and the rotator cuff, chronic infections, failed arthroplasties, and recurrent instability<sup>[1,2]</sup>. A shoulder arthrodesis may involve an acromioclavicular fusion, a glenohumeral fusion, or a combination of both<sup>[1-3]</sup>. The shoulder function of a well-positioned arthrodesis is limited and allows the patient to reach his back pocket, groin, and mouth. Generally, only scapulothoracic movements, like elevation and minimal rotations, after an arthrodesis are possible<sup>[1,2]</sup>. Most patients experience a reduction in pain but few are pain free, with up to one-third experiencing substantial peri scapular pain<sup>[1,2,4]</sup>.

A treatment for a painful arthrodesis is conversion to reverse shoulder arthroplasty (RSA), which has been described as effective for pain relief and promising functional improvements<sup>[5,6]</sup>. Based on the literature review conducted by the authors of this report, only two reports were found that describe a total of five cases in which the patients received a conversion to RSA<sup>[5,6]</sup>.

Here we present the case and surgical technique of a conversion from a painful shoulder arthrodesis to RSA in a 71-year-old male patient after a 51 years interval. The patient was informed that data concerning the case would be submitted for publication, and written patient consent was obtained. **Table 1** outlines a timeline of the patient presentation.

## CASE PRESENTATION

### Chief complaints

A 71-year-old male patient presented to the orthopedics outpatient department of our hospital with complaints of severe peri scapular pain and limited shoulder function, 51 years post arthrodesis of the right shoulder.

### History of present illness

Since the shoulder arthrodesis, the patient has been experiencing peri scapular pain. There was no history of new preceding trauma or injury. Pain progressed throughout the years, present at rest and with activity. Due to the limited range of shoulder motion, the patient experienced problems in activities of daily living. He was unable to reach above shoulder level and particularly the loss of internal rotation bothered him in self-care. Conservative treatment including analgesics and physical therapy was ineffective.

### History of past illness

Indication for arthrodesis in the past was persistent posttraumatic posterior instability of both shoulders after failed open stabilizing procedures. In 2017, the patient was treated with a RSA on the left side because of development of a rotator cuff arthropathy. Due to a very good functional outcome of the left shoulder, he had the expressed wish for conversion of the fused right shoulder into RSA as well.



**Table 1 Patient timeline**

Timeline	Patient situation
1967	Posttraumatic posterior instability both shoulders; underwent arthrodesis right shoulder
2017	Underwent reverse shoulder arthroplasty left shoulder
Mai 2018	Conversion of arthrodesis to reverse shoulder arthroplasty right shoulder
Mai 2019	At twelve months follow-up; complete disappearance of his peri scapular pain and improvements in activities of daily living

### **Physical examination**

At physical examination the actively achieved elevation was 100°, external rotation and internal rotation to lateral side of his leg. Notable was the peri scapular pain which he experienced during physical examination. He had an Oxford Shoulder Score of 38 (the best score: 12; the lowest score: 60). Sensibility of the axillary nerve was intact and despite general atrophy of the deltoid muscle (in particular the posterior part), contraction of the deltoid muscle was still possible.

### **Imaging examinations**

Conventional radiographs (Figure 1) and computed tomography (Figure 2) showed a shoulder arthrodesis with glenohumeral and acromiohumeral consolidation and normal bone stock of the glenoid. As part of the preoperative workup, electromyography (EMG) was performed and showed normal motor unit activity and recruitment in all three parts of the deltoid muscle.

## **FINAL DIAGNOSIS**

Complete cessation of peri scapular pain and structural improvements in daily activity after conversion of shoulder arthrodesis to RSA, after a 51 years interval.

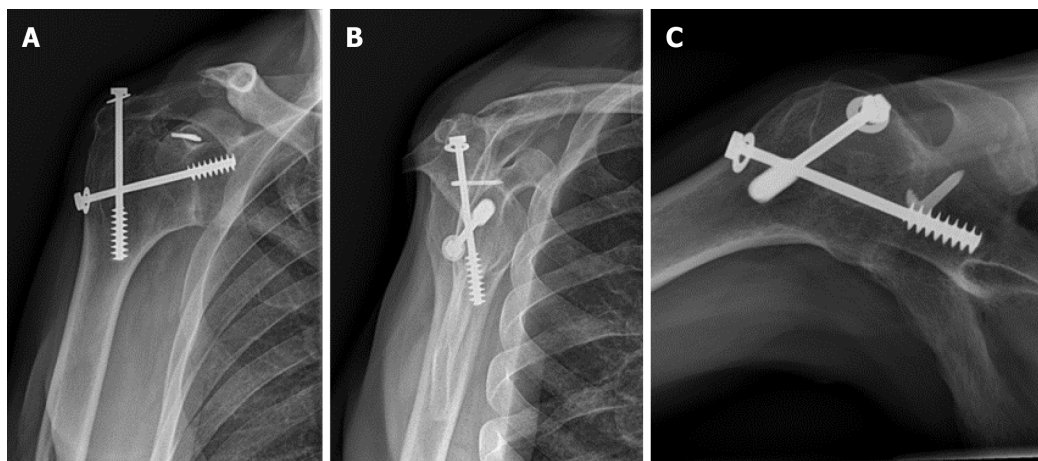
## **TREATMENT**

### **Surgical technique**

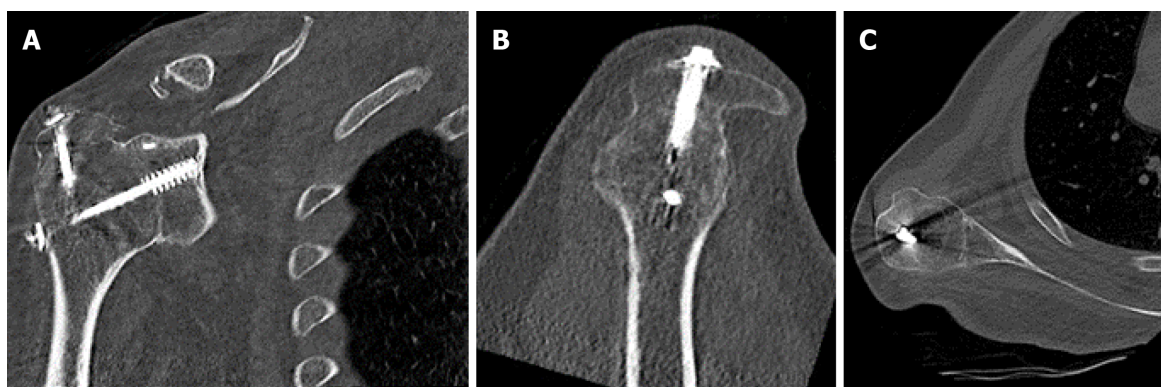
At the time of surgery, the patient had an interscalene block with general anesthesia, and was positioned semi-inclined in the beach chair position. After a stab incision the superior screw, through the acromion into the humeral head, was removed. The original anterior incision was used and a deltopectoral approach performed. The layers could nicely be mobilized without obstruction of an excessive amount of fibrosis. In contrast with a sufficient deltoid muscle (Figure 3), the quality of the rotator cuff was very poor with an absent superior cuff and a fibrotic, very thin subscapularis muscle. After removal of the screw which penetrated the formal glenohumeral joint, an osteotome was used to split the acromion from the humeral head. The “glenohumeral” osteotomy was performed under 10° of caudal inclination, a neutral version and one centimeter lateral from the original joint line, creating a long-necked scapula (Figure 4) in order to minimize scapular notching and improve rotations. An uncemented RSA (DELTA XTEND, DePuy Synthes, Raynham, Massachusetts, United States) was now implanted in a standard fashion (Figure 5).

## **OUTCOME AND FOLLOW-UP**

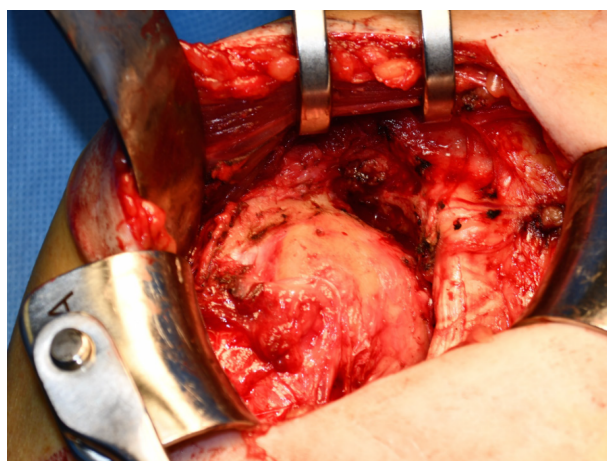
Postoperatively the patient was placed in a shoulder immobilizer for 6 wk. The patient was allowed to move passively and actively guided for 6 wk direct postoperatively. The postoperative course was otherwise uneventful. At 12 mo follow-up, the patient was very happy with respect to the outcome, with complete disappearance of his peri scapular pain (visual analogue scale score 0 in rest and exercise) and structural improvements in activities of daily living like eating with knife and fork, wiping his buttocks with his right hand, carrying more heavy objects with his right hand. Nevertheless, his shoulder function was rather poor with an active forward elevation of 50°, internal rotation to Th12 and absence of external rotation (neutral position)



**Figure 1** Conventional radiographs demonstrating the glenohumeral and acromiohumeral consolidation. A: Preoperative anteroposterior; B: Lateral/scapular Y; C: Axial radiographs.

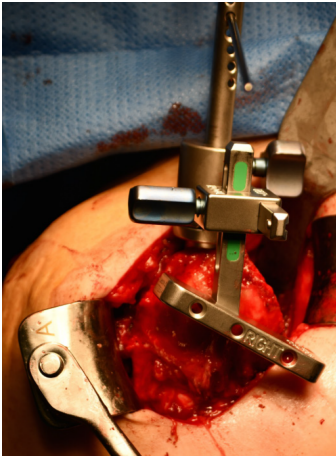


**Figure 2** Preoperative Computed Tomography scan demonstrating the glenohumeral and acromiohumeral consolidation. A: Coronal view; B: Sagittal view; C: Axial view.

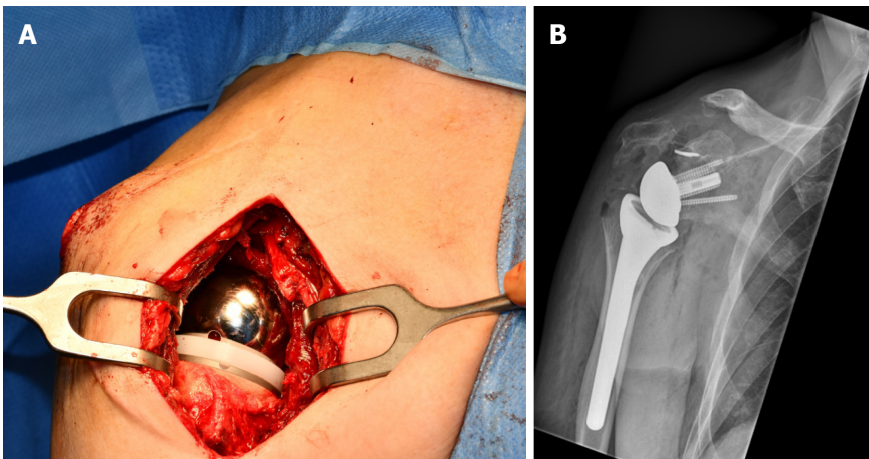


**Figure 3** Deltopectoral approach. The anterior and cranial rotator cuff muscles are absent.

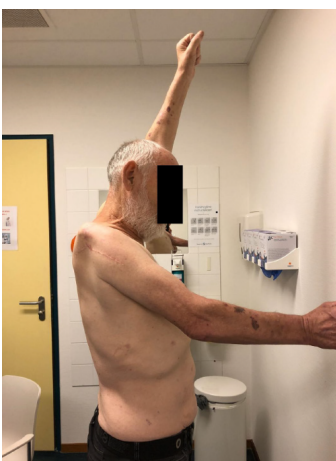(Figures 6-8). The deltoid muscle had an intact function in the anterior and lateral part, the posterior part was atrophic (Figure 6). He had an Oxford Shoulder Score of 23, and a Subjective Shoulder Value of 60%. Conventional radiographs showed a correct position of the RSA (Figure 5B). The patient was very satisfied with the outcome and assured the necessity of the surgery.



**Figure 4** The glenohumeral osteotomy. The glenohumeral osteotomy was performed under 10° of inclination, a neutral version and 1 cm lateral from the original joint line.



**Figure 5** The implanted reverse shoulder arthroplasty. A: During surgery; B: Postoperative anteroposterior radiograph.



**Figure 6** The active forward elevation of 50° after 12 mo postoperatively.



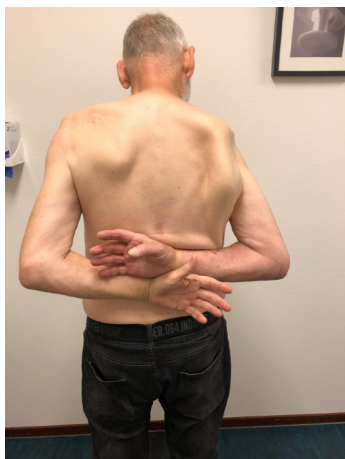

Figure 7 The internal rotation to Th12 12 mo postoperatively.

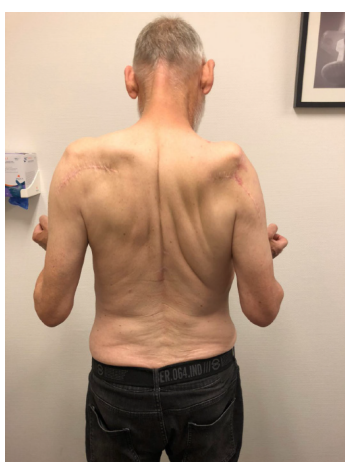

Figure 8 No external rotation 12 mo postoperatively.

## DISCUSSION

Shoulder arthrodesis for recurrent instability is a salvage procedure to regaining stability and some degree of function<sup>[1,2]</sup>. However, after the arthrodesis not all patients are pain free. Our patient still experienced peri scapular pain and severe limitation of active range of motion. The conversion of a shoulder arthrodesis into a RSA, has been described as an alternative and promising treatment for managing pain and achieve better functional results<sup>[5,6]</sup>.

In patients with a RSA, the deltoid muscle becomes the primary mover of the shoulder. Due to fibrosis and atrophy after arthrodesis, the function of the rotator cuff muscles is absent<sup>[4,6]</sup>. Therefore, the deltoid muscle function is critical to shoulder function after RSA<sup>[7,8]</sup>. Li *et al*<sup>[8]</sup> have suggested that preoperative EMG measurements of the deltoid muscle will help to predict the postoperative outcome of RSA. They found that postoperative shoulder strength after RSA was increased in patients with greater EMG activity of the middle deltoid. In an EMG study of Walker *et al*<sup>[4]</sup>, an important role for the anterior part of the deltoid is suggested. Lädermann *et al*<sup>[9]</sup> concluded that if partial deltoid function remains, RSA can produce reliable improvements in functional outcomes without an increased risk of dislocation. To obtain preoperative information of the activity and the quality of the deltoid muscle, we performed an EMG, which showed normal motor unit activity and recruitment in all three parts of the deltoid muscle.

A few previous case reports described conversion of a shoulder arthrodesis into hemiarthroplasty and total shoulder arthroplasty<sup>[10-13]</sup>. Patients achieved minimal functional improvement and mild to moderate pain remained. To the best of our knowledge, only two case reports of conversion of a shoulder arthrodesis into RSA are published<sup>[5,6]</sup>. No cases reported such a long interval (51 years) between arthrodesis

and conversion to RSA.

Table 2 shows the patient characteristics and functional outcomes at different follow-up of patients from both studies<sup>[5,6]</sup>. Alta *et al*<sup>[6]</sup> found that activity in two-thirds of the deltoid was sufficient to create a stable arthroplasty, with impairment of the anterior part in three of the four patients. Only one patient preoperatively had a completely intact deltoid muscle. Nevertheless, after conversion to RSA the elevation of that patient improved with 40 degrees but postoperative elevation did not reach above shoulder height<sup>[6]</sup>. The young patient in Toney *et al*<sup>[5]</sup> achieved excellent elevation of 160 degrees after conversion to RSA, with an intact deltoid muscle. However, this patient was not free of pain. In Alta *et al*<sup>[6]</sup>, all patients experienced decreased pain, but only one patient noted a pain score of zero. Most important for our patient was his complete ceasing of peri scapular pain, and he was very pleased with the improvement in internal rotation. Despite an intact axillary nerve and anterior part of the deltoid, he lost postoperatively active forward elevation, which could be related with the timeframe between arthrodesis and reverse arthroplasty. However, the patient is a highly motivated patient who continued in a determined way with active exercises.

The importance of a complete intact deltoid muscle and the role of the anterior part seems debatable. In our opinion, the activity of the deltoid muscle can be assessed by judging the tension of the muscle during physical examination. Additional information on the deltoid muscle by performing an EMG can be considered. More cases with conversion of arthroplasty to RSA are needed to predict the outcome of shoulder function from the activity of the three parts of the deltoid muscle.

---

## CONCLUSION

---

Conversion from shoulder arthrodesis to a RSA can be performed safely, with a possibility for peri scapular pain relief; even after a longstanding arthrodesis. Improvements in activities of daily living were noticed by our patient despite loss of active forward elevation.

**Table 2 Outcomes of previous studies with patients who underwent conversion of arthrodesis to reversed shoulder arthrodesis**

	<b>Toney <i>et al</i><sup>[5]</sup></b>	<b>Alta <i>et al</i><sup>[6]</sup></b>			
Patient characteristics	Female, 41 yr	Female, 63 yr	Male, 46 yr	Female 66, yr	Male, 58 yr
Arthrodesis indication	Brachial plexus injury with recurrent instability	Post-traumatic arthritis	Glenohumeral arthritis	Failed surgeries for proximal humeral fracture	Failed surgeries for proximal humeral fracture
Years after arthrodesis	5	11	5	6	11
Preoperative EMG	Deltoid intact	2/3 deltoid intact	2/3 deltoid intact	Deltoid intact	2/3 deltoid intact
Follow-up (mo)	12	36	6	48	22
Preoperative/postoperative					
Forward elevation	60/160	60/70	70/110	50/90	40/40
External rotation	0/60	0/15	0/20	0/15	0/10
Internal rotation	Trochanter/Th12	Trochanter/L5	Trochanter/L5	Trochanter/L5	Trochanter/sacrum
VAS pain scores	6	2	0	4	1

EMG: Electromyography; VAS: Visual analogue scale.

## ACKNOWLEDGEMENTS

We would like to thank the patient for being so willing to participate in the case report. Thanks are also due to Schager M, our native speaker, for her help with the language and grammar.

## REFERENCES

- 1 **Safran O**, Iannotti JP. Arthrodesis of the shoulder. *J Am Acad Orthop Surg* 2006; **14**: 145-153 [PMID: 16520365 DOI: 10.5435/00124635-200603000-00005]
- 2 **Clare DJ**, Wirth MA, Groh GI, Rockwood CA Jr. Shoulder arthrodesis. *J Bone Joint Surg Am* 2001; **83**: 593-600 [PMID: 11315792 DOI: 10.2106/00004623-200104000-00018]
- 3 **Lädermann A**, Denard PJ. Arthroscopic glenohumeral arthrodesis with o-arm navigation. *Arthrosc Tech* 2014; **3**: e205-e209 [PMID: 24904761 DOI: 10.1016/j.eats.2013.09.020]
- 4 **Walker D**, Wright TW, Banks SA, Struk AM. Electromyographic analysis of reverse total shoulder arthroplasties. *J Shoulder Elbow Surg* 2014; **23**: 166-172 [PMID: 23953059 DOI: 10.1016/j.jse.2013.05.005]
- 5 **Toney CB**, Thompson MJ, Barnes BJ, Boardman ND 3rd. Conversion of Glenohumeral Fusion to Reverse Total Shoulder Arthroplasty: A Case Report. *JBJS Case Connect* 2017; **7**: e20 [PMID: 29244700 DOI: 10.2106/JBJS.CC.16.00029]
- 6 **Alta TD**, Willems WJ. Once an arthrodesis, always an arthrodesis? *J Shoulder Elbow Surg* 2016; **25**: 232-237 [PMID: 26344871 DOI: 10.1016/j.jse.2015.07.010]
- 7 **Smith RA**, Woolley K, Mazzocca A, Feinn R, Cote M, Gomlinski G, Garbalosa J, Myrick KM. Kinematics and EMG activity in Reverse Total Shoulder Arthroplasty. *J Orthop* 2020; **22**: 165-169 [PMID: 32419758 DOI: 10.1016/j.jor.2020.04.017]
- 8 **Li H**, Yoon SH, Lee D, Chung H. Relation between preoperative electromyographic activity of the deltoid and upper trapezius muscle and clinical results in patients treated with reverse shoulder arthroplasty. *J Shoulder Elbow Surg* 2020; **29**: 195-201 [PMID: 31420222 DOI: 10.1016/j.jse.2019.05.032]
- 9 **Lädermann A**, Walch G, Denard PJ, Collin P, Sirveaux F, Favard L, Edwards TB, Kherad O, Boileau P. Reverse shoulder arthroplasty in patients with pre-operative impairment of the deltoid muscle. *Bone Joint J* 2013; **95-B**: 1106-1113 [PMID: 23908428 DOI: 10.1302/0301-620X.95B8.31173]
- 10 **Nho SJ**, Garbis N, Reiff S, Terry A, Shindelar S, Romeo AA. Conversion of glenohumeral fusion to total shoulder arthroplasty for scapulothoracic pain: case report and surgical technique. *HSS J* 2010; **6**: 14-18 [PMID: 19771479 DOI: 10.1007/s11420-009-9131-x]
- 11 **Cofield RH**, Briggs BT. Glenohumeral arthrodesis. Operative and long-term functional results. *J Bone Joint Surg Am* 1979; **61**: 668-677 [PMID: 457712 DOI: 10.2106/00004623-197961050-00005]
- 12 **Sperling JW**, Cofield RH. Total shoulder arthroplasty after attempted shoulder arthrodesis: report of three cases. *J Shoulder Elbow Surg* 2003; **12**: 302-305 [PMID: 12851587 DOI: 10.1016/S1058-2746(02)86826-4]
- 13 **Hertel R**, Ballmer FT. Shoulder arthroplasty after glenohumeral fusion. *J Shoulder Elbow Surg* 1994; **3**: 407-410 [PMID: 22958849 DOI: 10.1016/S1058-2746(09)80030-X]



Published by **Baishideng Publishing Group Inc**  
7041 Koll Center Parkway, Suite 160, Pleasanton, CA 94566, USA

**Telephone:** +1-925-3991568

**E-mail:** [bpgoffice@wjgnet.com](mailto:bpgoffice@wjgnet.com)

**Help Desk:** <https://www.f6publishing.com/helpdesk>

<https://www.wjgnet.com>

