

World Journal of *Orthopedics*

World J Orthop 2021 November 18; 12(11): 811-960



OPINION REVIEW

- 811 Revisiting Pauwels' classification of femoral neck fractures
Nandi S

ORIGINAL ARTICLE**Case Control Study**

- 816 Paraspinal strength and electromyographic fatigue in patients with sub-acute back pain and controls: Reliability, clinical applicability and between-group differences
Koumantakis GA, Oldham JA

Retrospective Cohort Study

- 833 Preseason elimination impact on anterior cruciate ligament injury in the national football league
Patetta M, Mayo B, Martini OZ, Sullivan B, Onsen L, Hutchinson M

Retrospective Study

- 842 Risk of methicillin-resistant staphylococcus aureus prosthetic joint infection in elective total hip and knee arthroplasty following eradication therapy
Kapur BP, Tonge X, Kumar G

- 850 Reliability of a simple fluoroscopic image to assess leg length discrepancy during direct anterior approach total hip arthroplasty
Caus S, Reist H, Bernard C, Blankstein M, Nelms NJ

- 859 Anthropometric method for estimating component sizes in total hip arthroplasty
Sahemey R, Moores TS, Meacher H, Youssef B, Khan S, Evans CR

- 867 Treatment of knee osteochondritis dissecans with autologous tendon transplantation: Clinical and radiological results
Turhan AU, Açıl S, Gül O, Öner K, Okutan AE, Ayas MS

Clinical Trials Study

- 877 Direct anterior approach *vs* Hardinge in obese and nonobese osteoarthritic patients: A randomized controlled trial
Macheras G, Stasi S, Sarantis M, Triantafyllou A, Tzefronis D, Papadakis SA

Observational Study

- 891 Work-related musculoskeletal injuries among upper extremity surgeons: A web-based survey
Alzahrani MM, Alqahtani SM, Pichora D, Bicknell R

EVIDENCE-BASED MEDICINE

- 899 Implementation science for the adductor canal block: A new and adaptable methodology process
Crain N, Qiu CY, Moy S, Thomas S, Nguyen VT, Lee-Brown M, Laplace D, Naughton J, Morkos J, Desai V

SYSTEMATIC REVIEWS

- 909 Femoral lengthening in young patients: An evidence-based comparison between motorized lengthening nails and external fixation
Hafez M, Nicolaou N, Offiah AC, Giles S, Madan S, Fernandes JA

META-ANALYSIS

- 920 Role of coatings and materials of external fixation pins on the rates of pin tract infection: A systematic review and meta-analysis
Stoffel C, Eltz B, Salles MJ

CASE REPORT

- 931 Allergic dermatitis after knee arthroscopy with repeated exposure to Dermabond Prineo™ in pediatric patients: Two case reports
Robinson J, Smidt KP, Houk G, McKie J, Barton RS, Massey P
- 938 Pathological humerus fracture due to anti-interferon-gamma autoantibodies: A case report
Yang CH, Kuo FC, Lee CH
- 945 Spontaneous pneumothorax in a 17-year-old male patient with multiple exostoses: A case report and review of the literature
Nakamura K, Asanuma K, Shimamoto A, Kaneda S, Yoshida K, Matsuyama Y, Hagi T, Nakamura T, Takao M, Sudo A
- 954 Management of acute length-unstable Monteggia fractures in children: A case report
Evola FR, Di Fede GF, Bonanno S, Evola G, Cucuzza ME

ABOUT COVER

Editorial Board Member of *World Journal of Orthopedics*, Christiaan JA van Bergen, MD, PhD, Senior Researcher, Surgeon, Department of Orthopaedic Surgery, Amphia, Breda 3000, Netherlands. cvanbergen@amphia.nl

AIMS AND SCOPE

The primary aim of *World Journal of Orthopedics* (WJO, *World J Orthop*) is to provide scholars and readers from various fields of orthopedics with a platform to publish high-quality basic and clinical research articles and communicate their research findings online.

WJO mainly publishes articles reporting research results and findings obtained in the field of orthopedics and covering a wide range of topics including arthroscopy, bone trauma, bone tumors, hand and foot surgery, joint surgery, orthopedic trauma, osteoarthropathy, osteoporosis, pediatric orthopedics, spinal diseases, spine surgery, and sports medicine.

INDEXING/ABSTRACTING

The WJO is now abstracted and indexed in PubMed, PubMed Central, Emerging Sources Citation Index (Web of Science), Scopus, China National Knowledge Infrastructure (CNKI), China Science and Technology Journal Database (CSTJ), and Superstar Journals Database. The 2021 edition of Journal Citation Reports® cites the 2020 Journal Citation Indicator (JCI) for WJO as 0.66. The WJO's CiteScore for 2020 is 3.2 and Scopus CiteScore rank 2020: Orthopedics and Sports Medicine is 87/262.

RESPONSIBLE EDITORS FOR THIS ISSUE

Production Editor: *Lin-YuTong Wang*; Production Department Director: *Xiang Li*; Editorial Office Director: *Jim-Lai Wang*.

NAME OF JOURNAL

World Journal of Orthopedics

ISSN

ISSN 2218-5836 (online)

LAUNCH DATE

November 18, 2010

FREQUENCY

Monthly

EDITORS-IN-CHIEF

Massimiliano Leigheb

EDITORIAL BOARD MEMBERS

<http://www.wjgnet.com/2218-5836/editorialboard.htm>

PUBLICATION DATE

November 18, 2021

COPYRIGHT

© 2021 Baishideng Publishing Group Inc

INSTRUCTIONS TO AUTHORS

<https://www.wjgnet.com/bpg/gerinfo/204>

GUIDELINES FOR ETHICS DOCUMENTS

<https://www.wjgnet.com/bpg/gerinfo/287>

GUIDELINES FOR NON-NATIVE SPEAKERS OF ENGLISH

<https://www.wjgnet.com/bpg/gerinfo/240>

PUBLICATION ETHICS

<https://www.wjgnet.com/bpg/gerinfo/288>

PUBLICATION MISCONDUCT

<https://www.wjgnet.com/bpg/gerinfo/208>

ARTICLE PROCESSING CHARGE

<https://www.wjgnet.com/bpg/gerinfo/242>

STEPS FOR SUBMITTING MANUSCRIPTS

<https://www.wjgnet.com/bpg/gerinfo/239>

ONLINE SUBMISSION

<https://www.f6publishing.com>



Management of acute length-unstable Monteggia fractures in children: A case report

Francesco Roberto Evola, Giovanni Francesco Di Fede, Santo Bonanno, Giuseppe Evola, Maria Elena Cucuzza

ORCID number: Francesco Roberto Evola 0000-0002-0470-8343; Giovanni Francesco Di Fede 0000-0001-6387-7377; Santo Bonanno 0000-0002-7606-5404; Giuseppe Evola 0000-0002-3648-7063; Maria Elena Cucuzza 0000-0002-2609-7141.

Author contributions: Evola FR and Di Fede GF reviewed the literature and contributed to conception and design of the study; Evola FR, Bonanno S and Evola G contributed to the drafting the article and to making critical revisions related to important intellectual content of the manuscript; Evola FR and Cucuzza ME revised the manuscript and approved the final version of the article.

Informed consent statement: The informed consent statement has been sent previously.

Conflict-of-interest statement: The authors declare that they have no conflict of interest and financial relationships for the realization of this work.

CARE Checklist (2016) statement: The authors have read the CARE Checklist (2016), and the manuscript was prepared and revised according to the CARE Checklist (2016).

Open-Access: This article is an

Francesco Roberto Evola, Department of Surgery, Division of Orthopedics and Trauma Surgery, “Cannizzaro” Hospital, Catania 95100, Italy

Giovanni Francesco Di Fede, Radiodiagnostics Department, Division of Radiology, “S. Marta and S. Venera” Hospital, Acireale 95024, Italy

Santo Bonanno, Emergency Department, Division of First Aid, “Garibaldi” Hospital, catania 95124, Catania, Italy

Giuseppe Evola, General and Emergency Surgery Department, Division of Surgery, “Garibaldi” Hospital, Catania, Italy, Catania 95124, Italy

Maria Elena Cucuzza, Maternity-Childhood Department, Division of Paediatrics, “Cannizzaro” Hospital, Catania 95124, Italy

Corresponding author: Francesco Roberto Evola, MD, PhD, Doctor, Department of Surgery, Division of Orthopedics and Trauma Surgery, “Cannizzaro” Hospital, Via Messina 829, Catania 95100, Italy. robertoevola@virgilio.it

Abstract

BACKGROUND

Monteggia fractures are uncommon injuries in paediatric age. Treatment algorithms assert that length-unstable fractures are treated with plate fixation. In this case report, intramedullary fixation of an acute length-unstable Monteggia fracture allowed a stable reduction to be achieved, along with an appropriate ulnar length and alignment as well as radio capitellar reduction despite the fact that the orthopaedic surgeon did not use a plate for the ulnar fracture. The scope of treatment is to avoid the use of a plate that causes periosteal stripping and blood circulation disruption around the fracture.

CASE SUMMARY

A four-year-old girl presented at the Emergency Department following an accidental fall off a chair onto the right forearm. The X-ray highlighted a length-unstable acute Bado type 1 Monteggia fracture of the right forearm. On the same day, the patient underwent surgical treatment of the Monteggia fracture. The surgeon preferred not to use a plate to avoid a delay in fracture healing and to allow the micromotion necessary for callus formation. The operation comprised percutaneous fixation with an elastic intramedullary K-wire of the ulnar fracture and, subsequently, humeroradial joint reduction through manual manipulation.

open-access article that was selected by an in-house editor and fully peer-reviewed by external reviewers. It is distributed in accordance with the Creative Commons Attribution NonCommercial (CC BY-NC 4.0) license, which permits others to distribute, remix, adapt, build upon this work non-commercially, and license their derivative works on different terms, provided the original work is properly cited and the use is non-commercial. See: <http://creativecommons.org/licenses/by-nc/4.0/>

Provenance and peer review:

Unsolicited article; Externally peer reviewed

Specialty type: Orthopedics

Country/Territory of origin: Italy

Peer-review report's scientific quality classification

Grade A (Excellent): 0
Grade B (Very good): B
Grade C (Good): 0
Grade D (Fair): 0
Grade E (Poor): 0

Received: July 5, 2021

Peer-review started: July 5, 2021

First decision: July 28, 2021

Revised: August 30, 2021

Accepted: September 27, 2021

Article in press: September 27, 2021

Published online: November 18, 2021

P-Reviewer: Zyoud SH

S-Editor: Liu M

L-Editor: A

P-Editor: Liu M



The orthopaedic surgeon assessed the stability of the radial head reduction under fluoroscopic control through flexion, extension, pronation and supination of the forearm. Healing of the fracture occurred within six weeks after surgery, as indicated by the presence of calluses on at least three cortices on standard radiographs. Dislocation/subluxation or loss of ulnar reduction was not apparent at the final X-ray examination.

CONCLUSION

Intramedullary fixation of unstable Monteggia fractures results in excellent outcomes, provides reliable reduction and causes fewer complications.

Key Words: Monteggia fractures; Children; Management; Outcome; Case report

©The Author(s) 2021. Published by Baishideng Publishing Group Inc. All rights reserved.

Core Tip: Treatment algorithms assert that acute length-stable Monteggia fractures are treated with an intramedullary device, while acute length-unstable fractures are treated with plates. Intramedullary devices have the advantage of smaller skin incisions, less soft tissue disruption, shorter operative times and easier device removal. Plates allow more anatomical restoration of the ulnar fracture and the radial bow, although they can cause delayed union due to blood circulation disruption around the fracture. Intramedullary wires can be used for the treatment of acute length-unstable Monteggia fractures instead of plates as these are associated with excellent results and fewer complications.

Citation: Evola FR, Di Fede GF, Bonanno S, Evola G, Cucuzza ME. Management of acute length-unstable Monteggia fractures in children: A case report. *World J Orthop* 2021; 12(11): 954-960

URL: <https://www.wjgnet.com/2218-5836/full/v12/i11/954.htm>

DOI: <https://dx.doi.org/10.5312/wjo.v12.i11.954>

INTRODUCTION

Monteggia fractures are uncommon injuries in paediatric age. In the nineteenth century, an Italian surgeon named Giovanni Monteggia described a traumatic injury involving a fracture of the proximal ulna with an associated dislocation of the radial head and disruption of the radioulnar joint[1]. Subsequently, these fractures were classified by Bado[2] into four types according to the direction of dislocation of the radial head.

The mechanism of injury is caused by direct trauma and hyperpronation as well as hyperextension[3]. The occurrence of paediatric Monteggia fractures covers between 1. Of 5% and 3% of all childhood elbow injuries[3,4]. Monteggia fractures remain a challenge for paediatric orthopaedic surgeons because of the difficulty involved in diagnosis and in the treatment of missed radial head dislocation and late instability. The aim of treatment is to achieve stable reduction of the ulnar fracture and radial head dislocation. Nowadays, the surgical treatment modalities available for these acute fractures include plates, intramedullary Kirschnerwires or elastic stable intramedullary nailing and, more recently, external fixation devices[5]. Although plates and intramedullary devices have comparable outcomes and complications, nailing or K-wires have the advantage of smaller skin incisions, less soft tissue disruption, shorter operative times and easier device removal. Furthermore, intramedullary wire fixations, due to their lack of rigidity, allow micromotion and callus formation[5]. Mechanical properties of intramedullary wires are based on a three-point fixation of the inner cortex and on a spread of the interosseous membrane [5]. Nowadays, there is no consensus regarding the preferred nail diameter, although, in the literature, authors suggest that the diameter of the wire should be approximately two-thirds of the medullary canal, measured at the isthmus level[6]. Intramedullary devices may cause skin irritation, refractures, malunion, secondary displacement and nerve injury. The use of plates is associated with a more anatomical

restoration of the ulnar fracture and the radial bow, and a more rigid fixation, which requires reduced post-operative immobilization[6]. Despite this, open reduction and plate fixation cause periosteal stripping and blood circulation disruption around the fracture, resulting in a greater likelihood of delayed union or more rarely non-union [6].

The aim of this case report was to assess the efficacy of intramedullary wires for the treatment of acute length-unstable Monteggia fractures instead of plate fixation and to review the literature.

CASE PRESENTATION

Chief complaints

A four-year-old right-hand-dominant girl presented at the Emergency Department of our hospital following an accidental fall off a chair onto the right forearm. The mother reported a direct trauma to the floor of the right forearm with hyperextension and hyperpronation.

History of present illness

Post-trauma, the child reported pain in the right forearm along with inability to bend the elbow.

History of past illness

The patient had a free previous surgical history.

Physical examination

The child had forearm deformities with swelling and local tenderness around the elbow. Furthermore, active and passive motion of the elbow was impossible and accompanied by pain.

Imaging examinations

The X-rays appeared to show a fracture of the proximal ulna with an associated anterior dislocation of the radial head of the right elbow (Figure 1). The ulnar injury consisted of a long oblique fracture with a line measuring more than twice the cortical diameter. Radial head dislocation may be diagnosed when the radiocapitellar line, drawn through the axis of the radial neck on a lateral radiograph, regardless of the degree of flexion or extension of the elbow, crosses the humeral capitulum anterior to this normal position.

FINAL DIAGNOSIS

The X-ray highlighted a length-unstable acute Bado type1 Monteggia fracture of the right forearm.

TREATMENT

On the same day, the patient underwent surgical treatment of the Monteggia fracture. The surgeon preferred not to use a plate to avoid a delay in fracture healing and to allow the micromotion necessary for callus formation. The operation comprised percutaneous fixation with an elastic intramedullary K-wire of the ulnar fracture and, subsequently, humeroradial joint reduction through a combination of longitudinal traction and manual manipulation. The wire was inserted through the tip of the olecranon and advanced across the fracture site after a reduction is obtained. The reduction of the radial head may be considered stable under fluoroscopic control if the intramedullary fixation of the ulnar fracture maintains its reduced position through flexion, extension, pronation and supination. Alignment of the ulnar injury by K-wire had simultaneously reduced and stabilized the radial head dislocation. No other K-wire was used to maintain the reduction of the radial head. The K-wire can be bent and cut outside the skin to facilitate easy removal. A long arm cast was applied at the end of the operation with the elbow at 90° of flexion and the forearm in supination. Adequate analgesia was provided after surgery, the affected limb was elevated,

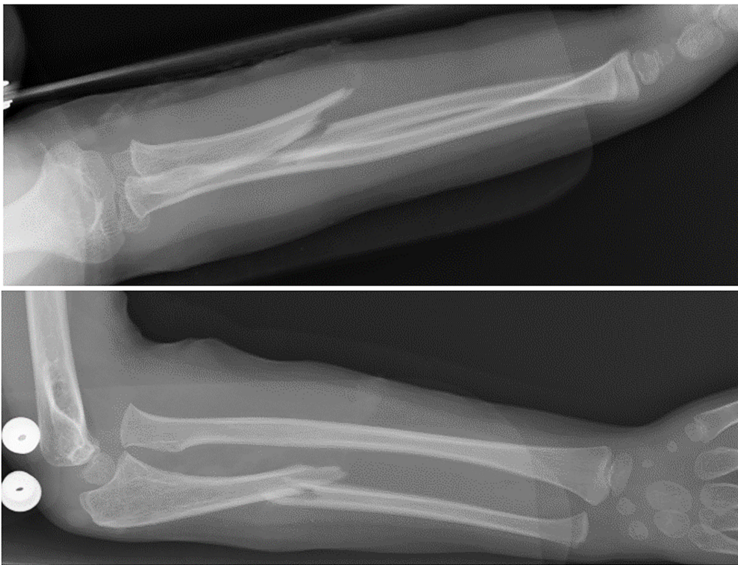


Figure 1 Plain X-ray taken at the time of injury revealing a fracture of the proximal third of the ulna and anterior dislocation of the radial head.

cryotherapy applied and circulation of the fingers monitored. The girl's parents were taught how to manage post-operative swelling and pain over the following days. Cast immobilization was used after the surgical treatment until there was radiographic evidence of fracture union.

OUTCOME AND FOLLOW-UP

At the first (5 d) and second (10 d) follow-up, control two-plane radiographs were obtained to assess any possible loss of articular contact between the proximal radius and humeral capitellum and loss of ulnar reduction (> 10 degree increase in the ulnar angle). Healing of the fracture occurred within six weeks after surgery. In children, although the fracture may still be visible at six weeks, adequate healing is represented by a callus on at least three cortices on standard radiographs (Figure 2). At the last follow-up (6 wk), the cast and the intramedullary wire were removed. Dislocation/subluxation, defined as a loss of articular contact between the proximal radius and capitellum, or loss of ulnar reduction, was not apparent in the final X-ray examination. Active range of motion exercises were started on the first day after removal of the cast and K-wire with the aid of a physiotherapist until full elbow range of motion was achieved. No pain, limitations in range of motion or function, or any complications (recurrent dislocation, elbow dysfunction or stiffness, refracture, transient neuropraxias) were observed at the end of the rehabilitative treatment. The patient had excellent results and complete return of elbow motion at short-term clinical follow-up (6 wk after physiotherapy). Complete fracture healing, defined as full return to activities of daily living and sports, occurred four months after the trauma.

DISCUSSION

If the radial head dislocation or subluxation in Monteggia fractures is not diagnosed and adequately treated, it may lead to chronic elbow disability, pain, progressive valgus deformity, neurologic problems (posterior interosseous nerve palsy), radial head dysplasia and degenerative arthritis, elbow stiffness and loss of motion, particularly supination and pronation [4,7,8]. Foran *et al* [4], in a retrospective study performed on 94 patients, asserts that 83% of patients are successfully managed with a cast and do not require surgical stabilization. Reduction of the deformity of the ulnar fracture is achieved through a combination of longitudinal traction, elbow rotation and manual manipulation; when the ulnar length has been re-established, the radiocapitellar joint will often reduce spontaneously or as a result of pressure on the radial head. The author asserts that paediatric Monteggia fractures, including in patients

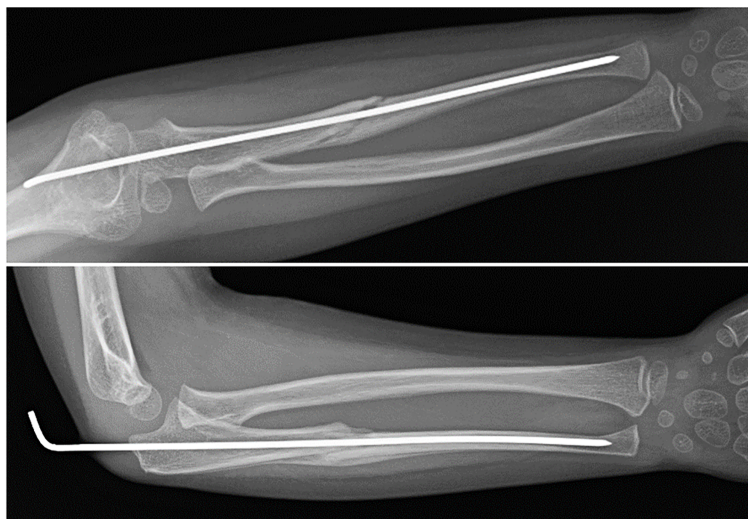

Figure 2 Radiographs at six weeks of follow-up showing reduction of the radial head dislocation and adequate healing of the proximal ulna fracture.

with length-unstable ulna fractures, can initially be managed non-operatively, without compromising outcomes or complications; surgery should only be pursued when a conservative approach fails, with the aim of avoiding surgical overtreatment of these injuries. Compared with adults, children with Monteggia fractures have a higher chance of success without surgery for several reasons, including their thicker periosteum (which helps maintain stability of the ulna), less complex ulna fracture patterns, typically lower energy mechanisms, faster healing times and greater remodeling potential[9,10]. Failure or loss of reduction and late instability may occur in up to 20% of cases with this conservative treatment because of the deforming muscular forces and joint disruption[11,12]. Therefore, although most acute Monteggia fractures are treated non-operatively, certain fracture patterns require surgical stabilization[4]. The indications for surgical treatment are complete fracture, unstable and irreducible fractures, open fractures, and fractures with neurovascular compromise[5]. Variations in the treatment of Monteggia fractures can be found among multiple authors. Ring *et al*[13] affirmed that maintaining ulnar length and anatomic alignment was the key to treating acute Monteggia injuries, because the radial head will remain reduced through healing of the ulnar fracture. Treatment algorithms, based upon the ulnar fracture pattern, have the purpose of minimizing complications and maximizing outcomes through restoration and maintenance of ulnar alignment. The treatment algorithms assert that length-stable fracture patterns with incomplete fracture or plastic deformation of the ulna are treated with closed reduction and casting; length-stable fractures with a complete fracture of the ulna (transverse or short oblique) are treated with intramedullary pin fixation; and length-unstable fractures with comminution of the ulna or a long oblique fracture (fracture line measuring more than twice the cortical diameter) of the ulna are treated with plate fixation[13]. The objective of this algorithm is to avoid loss of reduction and its associated morbidity. Ramski *et al* [11], in a retrospective study performed on 112 patients, asserts that recurrent instability of the radial head and loss of ulnar fracture reduction only occurred in patients who were not treated according to the ulnar-based algorithm. Failures occurred in patients treated less rigorously than the recommended algorithm, and in particular, failures occurred in complete fractures treated non-operatively with closed reduction and cast immobilization[11]. Furthermore, the authors observed that although the algorithm strategy recommends plate fixation for all long oblique or comminuted fractures, there were no failures of intramedullary pin fixation of long oblique fractures in this clinical study.

Nevertheless, several authors advocate more aggressive treatment with open reduction and plate fixation for unstable fractures[14]. Leonidou *et al*[14], in a retrospective study of 40 paediatric Monteggia fractures, asserts that although conservative management has been shown to correlate with good results, unstable fractures of the ulna need to be treated with plate fixation to ensure good reduction of the radial head and to avoid the possibility of prolonged immobilization leading to elbow stiffness in children[14]. Moreover, Hetthéssy *et al*[3] in a retrospective analysis of 23

acute pediatric Monteggia fractures, affirms that if the dislocation of the radial head is accompanied by an unstable fracture of the ulna, a more stable osteosynthesis plate is required.

Nowadays, intramedullary nailing fixation is the main method of fracture stabilization in acute, stable and unstable Monteggia injuries, while plate fixations are widely used in patients with neglected Monteggia fractures[15]. Many authors use a cut-off of four weeks before considering a Monteggia fracture to be “neglected”. He *et al*[15], through a retrospective comparison study of 42 patients, showed that the rate of patients that needed open reduction or complex immobilization methods was higher in the neglected group than in the acute group. Therefore, only for early diagnosis of Monteggia injury can we rely upon minimally invasive methods such as intramedullary pin fixation[15-17]. Open reduction combined with ulnar plate fixation is the most common approach to treating missed Monteggia fractures or acute Monteggia fractures in the case of failure of closed radiocapitellar joint reduction[15].

In contrast to short oblique or transverse ulna fractures, long oblique and comminuted fractures are considered “length unstable” and therefore are treated with plate and screw fixation; open reduction and plate fixation are frequently indicated by some orthopaedists because angulation, malalignment and shortening of the ulna often occur after closed reduction and intramedullary wire fixation. In this case report, intramedullary fixation of the ulna allowed a stable reduction and ulnar length and alignment to be achieved as well as radio capitellar reduction despite the fact that the orthopaedic surgeon did not use the plate and screws for ulnar fracture. Therefore, even if not indicated in treatment algorithms, length-unstable Monteggia fractures can be successfully treated with an elastic intramedullary device with the aim of using a minimally invasive technique and enabling a low complication rate.

CONCLUSION

Treatment of acute paediatric Monteggia fractures is still being debated and there is currently no standard treatment. In fresh Monteggia fractures, the decision to treat the ulna with an intramedullary device or plate is made according to the surgeon's own preference with the aim of facilitating the correct alignment of the radiocapitellar joint and avoiding recurrent dislocation. In recent years, the use of intramedullary nails for the management of acute Monteggia fractures in children has gained popularity regardless of the ulnar fracture type. Delayed diagnosis and inadequate treatment of radial head dislocation will cause complications such as elbow pain, decreased joint range of motion, increased valgus deformity and neurologic problems. Flexible nails or wires are excellent devices combining stability and elasticity in children with fractures. Intramedullary fixation of unstable Monteggia fractures results in excellent outcomes, providing reliable reduction and causing fewer complications.

REFERENCES

- 1 **Bruce HE**, Harvey JP, Wilson JC Jr. Monteggia fractures. *J Bone Joint Surg Am* 1974; **56**: 1563-1576 [PMID: 4434024]
- 2 **Bado JL**. The Monteggia lesion. *Clin Orthop Relat Res* 1967; **50**: 71-86 [PMID: 6029027]
- 3 **Hetthéssy JR**, Sebők B, Vadász A, Kassai T. The Three Step Approach to the management of acute pediatric Monteggia lesions. *Injury* 2021; **52** Suppl 1: S57-S62 [PMID: 32147142 DOI: 10.1016/j.injury.2020.02.033]
- 4 **Foran I**, Upasani VV, Wallace CD, Britt E, Bastrom TP, Bomar JD, Pennock AT. Acute Pediatric Monteggia Fractures: A Conservative Approach to Stabilization. *J Pediatr Orthop* 2017; **37**: e335-e341 [PMID: 28520680 DOI: 10.1097/BPO.0000000000001001]
- 5 **Poutoglidou F**, Metaxiotis D, Kazas C, Alvanos D, Mpeletsiotis A. Flexible intramedullary nailing in the treatment of forearm fractures in children and adolescents, a systematic review. *J Orthop* 2020; **20**: 125-130 [PMID: 32025135 DOI: 10.1016/j.jor.2020.01.002]
- 6 **Fernandez FF**, Langendörfer M, Wirth T, Eberhardt O. Failures and complications in intramedullary nailing of children's forearm fractures. *J Child Orthop* 2010; **4**: 159-167 [PMID: 21455473 DOI: 10.1007/s11832-010-0245-y]
- 7 **Beutel BG**. Monteggia fractures in pediatric and adult populations. *Orthopedics* 2012; **35**: 138-144 [PMID: 22300997 DOI: 10.3928/01477447-20120123-32]
- 8 **Miller TC**, Fishman FG. Management of Monteggia Injuries in the Pediatric Patient. *Hand Clin* 2020; **36**: 469-478 [PMID: 33040959 DOI: 10.1016/j.hcl.2020.07.001]
- 9 **Rodgers WB**, Waters PM, Hall JE. Chronic Monteggia lesions in children. Complications and results of reconstruction. *J Bone Joint Surg Am* 1996; **78**: 1322-1329 [PMID: 8816646 DOI: 10.1016/j.jor.2020.01.002]

- 10.2106/00004623-199609000-00005]
- 10 **Sessa G**, Evola FR, Costarella L. Osteosynthesis systems in fragility fracture. *Aging Clin Exp Res* 2011; **23**: 69-70 [PMID: [21970929](#)]
- 11 **Ramski DE**, Hennrikus WP, Bae DS, Baldwin KD, Patel NM, Waters PM, Flynn JM. Pediatric monteggia fractures: a multicenter examination of treatment strategy and early clinical and radiographic results. *J Pediatr Orthop* 2015; **35**: 115-120 [PMID: [24978320](#) DOI: [10.1097/BPO.0000000000000213](#)]
- 12 **Peshin C**, Ratra R, Juyal AK. Step-cut osteotomy in neglected Monteggia fracture dislocation in pediatric and adolescent patients: A retrospective study. *J Orthop Surg (Hong Kong)* 2020; **28**: 2309499020964082 [PMID: [33267739](#) DOI: [10.1177/2309499020964082](#)]
- 13 **Ring D**, Jupiter JB, Waters PM. Monteggia fractures in children and adults. *J Am Acad Orthop Surg* 1998; **6**: 215-224 [PMID: [9682084](#) DOI: [10.5435/00124635-199807000-00003](#)]
- 14 **Leonidou A**, Pagkalos J, Lepetos P, Antonis K, Flieger I, Tsiroidis E, Leonidou O. Pediatric Monteggia fractures: a single-center study of the management of 40 patients. *J Pediatr Orthop* 2012; **32**: 352-356 [PMID: [22584834](#) DOI: [10.1097/BPO.0b013e31825611fc](#)]
- 15 **He JP**, Hao Y, Shao JF. Comparison of treatment methods for pediatric Monteggia fracture: Met vs missed radial head dislocation. *Medicine (Baltimore)* 2019; **98**: e13942 [PMID: [30633171](#) DOI: [10.1097/MD.00000000000013942](#)]
- 16 **Kruppa C**, Bunge P, Schildhauer TA, Dudda M. Low complication rate of elastic stable intramedullary nailing (ESIN) of pediatric forearm fractures: A retrospective study of 202 cases. *Medicine (Baltimore)* 2017; **96**: e6669 [PMID: [28422876](#) DOI: [10.1097/MD.0000000000000669](#)]
- 17 **Yuan Z**, Xu H, Li Y, Li J, Liu Y, Canavese F. Functional and radiological outcome in patients with acute Monteggia fracture treated surgically: a comparison between closed reduction and external fixation versus closed reduction and elastic stable intramedullary nailing. *J Pediatr Orthop B* 2020; **29**: 438-444 [PMID: [31305359](#) DOI: [10.1097/BPB.0000000000000645](#)]



Published by **Baishideng Publishing Group Inc**
7041 Koll Center Parkway, Suite 160, Pleasanton, CA 94566, USA

Telephone: +1-925-3991568

E-mail: bpgoffice@wjgnet.com

Help Desk: <https://www.f6publishing.com/helpdesk>

<https://www.wjgnet.com>

