

World Journal of *Orthopedics*

World J Orthop 2021 September 18; 12(9): 620-726



MINIREVIEWS

- 620** Coronaviruses: An overview with special emphasis on COVID-19 outbreak with musculoskeletal manifestations
Ali S, Singh A, Sharief N, Yadav M, Siddiqui S, Pandey V, Raikwar A, Singh A
- 629** Hip prosthetic loosening: A very personal review
Mjöberg B
- 640** Jones type fifth metatarsal fracture fixation in athletes: A review and current concept
Albloushi M, Alshanqiti A, Qasem M, Abitbol A, Gregory T
- 651** Effects of sclerostin antibody on bone healing
Mihara A, Yukata K, Seki T, Iwanaga R, Nishida N, Fujii K, Nagao Y, Sakai T
- 660** Current concepts in the management of bisphosphonate associated atypical femoral fractures
Rudran B, Super J, Jandoo R, Babu V, Nathan S, Ibrahim E, Wiik AV
- 672** Virtual orthopedic assessment: Main principles and specific regions
Emara KM, Diab RA, Amr M, Mahmoud SA, Nour M, Abdelsalam A, Elshobaky MA, Farhan M, Gemeah M, Emara AK
- 685** Machine learning in orthopaedic surgery
Lalehzarian SP, Gowd AK, Liu JN

ORIGINAL ARTICLE**Clinical and Translational Research**

- 700** Trends and risk factors for opioid administration for non-emergent lower back pain
Gwam CU, Emara AK, Chughtai N, Javed S, Luo TD, Wang KY, Chughtai M, O'Gara T, Plate JF

Retrospective Study

- 710** Correlation of stress radiographs to injuries associated with lateral ankle instability
Sy JW, Lopez AJ, Lausé GE, Deal JB, Lustik MB, Ryan PM

CASE REPORT

- 720** Atypical osteochondroma of the lumbar spine associated with suprasellar pineal germinoma: A case report
Suwak P, Barnett SA, Song BM, Heffernan MJ

ABOUT COVER

Editorial Board Member of *World Journal of Orthopedics*, Vasileios S Nikolaou, MD, MSc, PhD, Associate Professor, Surgeon, The Second Orthopaedic Department, School of Medicine, National and Kapodistrian University of Athens, Athens 14233, Greece. vassilios.nikolaou@gmail.com

AIMS AND SCOPE

The primary aim of *World Journal of Orthopedics* (*WJO*, *World J Orthop*) is to provide scholars and readers from various fields of orthopedics with a platform to publish high-quality basic and clinical research articles and communicate their research findings online.

WJO mainly publishes articles reporting research results and findings obtained in the field of orthopedics and covering a wide range of topics including arthroscopy, bone trauma, bone tumors, hand and foot surgery, joint surgery, orthopedic trauma, osteoarthropathy, osteoporosis, pediatric orthopedics, spinal diseases, spine surgery, and sports medicine.

INDEXING/ABSTRACTING

The *WJO* is now abstracted and indexed in PubMed, PubMed Central, Emerging Sources Citation Index (Web of Science), Scopus, China National Knowledge Infrastructure (CNKI), China Science and Technology Journal Database (CSTJ), and Superstar Journals Database. The 2021 edition of Journal Citation Reports® cites the 2020 Journal Citation Indicator (JCI) for *WJO* as 0.66. The *WJO*'s CiteScore for 2020 is 3.2 and Scopus CiteScore rank 2020: Orthopedics and Sports Medicine is 87/262.

RESPONSIBLE EDITORS FOR THIS ISSUE

Production Editor: Lin-YuTong Wang; Production Department Director: Xiang Li; Editorial Office Director: Jin-Lai Wang.

NAME OF JOURNAL

World Journal of Orthopedics

ISSN

ISSN 2218-5836 (online)

LAUNCH DATE

November 18, 2010

FREQUENCY

Monthly

EDITORS-IN-CHIEF

Massimiliano Leigheb

EDITORIAL BOARD MEMBERS

<http://www.wjgnet.com/2218-5836/editorialboard.htm>

PUBLICATION DATE

September 18, 2021

COPYRIGHT

© 2021 Baishideng Publishing Group Inc

INSTRUCTIONS TO AUTHORS

<https://www.wjgnet.com/bpg/gerinfo/204>

GUIDELINES FOR ETHICS DOCUMENTS

<https://www.wjgnet.com/bpg/GerInfo/287>

GUIDELINES FOR NON-NATIVE SPEAKERS OF ENGLISH

<https://www.wjgnet.com/bpg/gerinfo/240>

PUBLICATION ETHICS

<https://www.wjgnet.com/bpg/GerInfo/288>

PUBLICATION MISCONDUCT

<https://www.wjgnet.com/bpg/gerinfo/208>

ARTICLE PROCESSING CHARGE

<https://www.wjgnet.com/bpg/gerinfo/242>

STEPS FOR SUBMITTING MANUSCRIPTS

<https://www.wjgnet.com/bpg/GerInfo/239>

ONLINE SUBMISSION

<https://www.f6publishing.com>



Atypical osteochondroma of the lumbar spine associated with suprasellar pineal germinoma: A case report

Patrik Suwak, Scott A Barnett, Bryant M Song, Michael J Heffernan

ORCID number: Patrik Suwak 0000-0001-6232-4359; Scott A Barnett 0000-0003-2038-1608; Bryant M Song 0000-0003-3795-2913; Michael J Heffernan 0000-0002-0632-3367.

Author contributions: Suwak P contributed to the case report design, image formatting, manuscript preparation; Barnett SA, and Song BM contributed to the image formatting, manuscript preparation; Heffernan MJ contributed to the case report design, manuscript preparation.

Informed consent statement: Informed consent was obtained, and the study was approved by the institutional review board.

Conflict-of-interest statement: Heffernan MJ reports personal fees from Zimmer Biomet, Inc. Barnett SA, Suwak P, and Song BM have nothing to disclose.

CARE Checklist (2016) statement: The CARE Checklist guidelines were followed for the production of this case report.

Open-Access: This article is an open-access article that was selected by an in-house editor and fully peer-reviewed by external reviewers. It is distributed in accordance with the Creative Commons Attribution NonCommercial (CC BY-NC 4.0)

Patrik Suwak, Scott A Barnett, Bryant M Song, Michael J Heffernan, Department of Orthopaedic Surgery, Louisiana State University Health Sciences Center, New Orleans, LA 70112, United States

Michael J Heffernan, Department of Orthopaedic Surgery, Children's Hospital New Orleans, New Orleans, LA 70118, United States

Corresponding author: Michael J Heffernan, MD, Associate Professor, Department of Orthopaedic Surgery, Children's Hospital New Orleans, 200 Henry Clay Ave, New Orleans, LA 70118, United States. mheffl@lsuhsc.edu

Abstract

BACKGROUND

Osteochondromas are the most common benign bone tumor, accounting for 36% of benign bone tumors. Often found within the appendicular skeleton, osteochondromas of the spine are rare, comprising 4% to 7% of primary benign spinal tumors.

CASE SUMMARY

We report a case of a solitary lumbar osteochondroma in an 18-year-old male with a history of a suprasellar pineal germinoma treated with combined chemotherapy and radiation. He underwent mass excision and partial laminectomy with the ultrasonic bone scalpel (Misonix, Farmingdale, NY, United States) at the L5 Level without the use of adjuvants. The patient returned to work and full activities without back pain at 3 mo postoperatively.

CONCLUSION

Osteochondromas are common tumors of the appendicular skeleton but rarely occur within the spine. This case discussion supplements current osteochondroma literature by describing an unusual presentation of this tumor.

Key Words: Spine osteochondroma; Lumbar osteochondroma; Laminectomy; Radiation-induced osteochondroma; Spine surgery; Case report

©The Author(s) 2021. Published by Baishideng Publishing Group Inc. All rights reserved.

license, which permits others to distribute, remix, adapt, build upon this work non-commercially, and license their derivative works on different terms, provided the original work is properly cited and the use is non-commercial. See: <http://creativecommons.org/licenses/by-nc/4.0/>

Manuscript source: Unsolicited manuscript

Specialty type: Orthopedics

Country/Territory of origin: United States

Peer-review report's scientific quality classification

Grade A (Excellent): 0
Grade B (Very good): 0
Grade C (Good): 0
Grade D (Fair): 0
Grade E (Poor): 0

Received: April 1, 2021

Peer-review started: April 1, 2021

First decision: June 7, 2021

Revised: June 19, 2021

Accepted: August 20, 2021

Article in press: August 20, 2021

Published online: September 18, 2021

P-Reviewer: Vahedi P

S-Editor: Wang JL

L-Editor: A

P-Editor: Ma YJ



Core Tip: Osteochondromas of the spine are a rare but treatable condition. For symptomatic lesions, complete resection is largely curative without adjuvant therapy. The patient in this case report was pain free at his post-operative visits without signs or symptoms of recurrence or complication. He returned to work as a manual laborer at 3 mo. Further reports of patients diagnosed with osteochondromas and a history of childhood radiation will enable better understanding of radiation-induced osteochondromas and the rates and locations at which they occur.

Citation: Suwak P, Barnett SA, Song BM, Heffernan MJ. Atypical osteochondroma of the lumbar spine associated with suprasellar pineal germinoma: A case report. *World J Orthop* 2021; 12(9): 720-726

URL: <https://www.wjgnet.com/2218-5836/full/v12/i9/720.htm>

DOI: <https://dx.doi.org/10.5312/wjo.v12.i9.720>

INTRODUCTION

Osteochondromas are the most common benign bone tumor, accounting for 36% of benign bone tumors[1]. Often found within the appendicular skeleton, osteochondromas of the spine are rare, comprising 4% to 7% of primary benign spinal tumors[2, 3]. Spine osteochondromas typically originate in the posterior elements as opposed to the vertebral bodies. The cervical spine is most affected (50%), followed by the thoracic and lumbar regions[4]. Characterized as outgrowths of bone covered with a cartilaginous cap, these lesions are considered aberrations of normal growth. Perichondral ring disruption at an active physis leads to cartilage herniation through the periosteal layer. Over time, the cartilaginous fragments undergo ossification and expand[5]. Their expansile nature may cause compression of surrounding structures resulting in pain and neurologic symptoms[4,6,7].

Radiation-induced osteochondroma is a known phenomenon that occurs in patients with a childhood history of radiation therapy[8]. Compared to spontaneous solitary osteochondromas and hereditary multiple exostosis, radiation-induced lesions are radiologically and pathologically identical[8,9]. The presence of a radiation-induced osteochondroma in the lumbar spine is extremely unusual, as in our presented case. A review of literature reveals only two cases of radiation induced osteochondroma occurring in the lumbar spine (one occurring in the L1 body of a 29-year-old female and the L3 spinous process of a 15-year-old female[10-12]. The case of the 15-year-old female appeared in a larger childhood post-radiative tumor study and was not formally presented. Difficulty in diagnosis stems from inconsistent visualization on plain radiographs. Computed tomography (CT) and magnetic resonance imaging (MRI) are the gold standard in the evaluation of spinal osteochondromas, especially in the setting of spinal cord compressive symptoms[13,14].

We present an atypical, symptomatic lumbar spine osteochondroma in an 18-year-old male with a history of chemotherapy and radiation. This case report received institutional review board approval.

CASE PRESENTATION

Chief complaints

An 18-year-old-male presented to the pediatric orthopaedic clinic with the complaint of a posterior midline protuberance at the level of the lumbar spine.

History of present illness

Per the patient, the mass had been present for one year and was gradually enlarging. He noted pain with prolonged sitting and while lying supine.

History of past illness

There was no history of prior trauma or activity-related injury to his low back, however the patient worked as a manual laborer. The patient denied constitutional or neurologic symptoms. His history was significant for a suprasellar pineal germinoma

successfully treated with chemotherapy and radiation at 9-years of age.

Personal and family history

No family history of hereditary multiple exostosis was reported.

Physical examination

On physical examination, there was a palpable osseous protuberance approximately 5 cm in width along the posterior midline at the level of the lumbar spine. The mass was fixed and exquisitely tender to palpation. Further examination of the body and extremities revealed no other masses. Neurologic testing was benign with normal sensorimotor response in all extremities, symmetric reflexes, no upper motor neuron or radicular signs, and no balance or gait abnormalities.

Laboratory examinations

No laboratory examinations were performed.

Imaging examinations

Initial radiographic evaluation demonstrated a large osteochondroma arising from the right spinous process/Lamina junction at the level of the L5 vertebral body (Figure 1). Subsequent CT and MRI imaging confirmed the radiographic findings without evidence of intraspinal abnormality or encroachment on the vertebral canal (Figures 2 and 3). Given the symptomatic nature and location of the mass, the patient was offered surgical treatment in the form of mass excision.

FINAL DIAGNOSIS

A diagnosis of an osteochondroma arising from the right spinous process/Lamina junction at the level of the L5 vertebral body was made, and this was later confirmed with surgical pathology.

TREATMENT

Intraoperatively, mass excision with partial laminectomy was performed through a posterior midline incision. Careful paramedian dissection was performed in order to free the soft tissues surrounding the mass without destabilization of the interspinous ligaments or the right L5-S1 facet joint. Once isolated, the mass was excised *en bloc* with use of a harmonic bone scalpel. A Woodson elevator was utilized under the lamina to gauge depth and ensure that the ventral surface of the lamina remained intact. After excision, a paraspinal muscular flap closure was performed to minimize the potential space created by the mass. Gross surgical pathology revealed a large bony mass measuring 3.8 cm × 3.5 cm × 2.5 cm that included a 1 cm thick sessile cartilaginous cap. Surgical margins were noted to be smooth (Figure 4). Microscopic examination demonstrated mature hyaline cartilage, fibrous perichondrium, and trabecular bone without cellular atypia or malignant features. Enchondral ossification was present within the sample without marrow elements identifiable within the trabecular bone. Pathology was consistent with benign osteochondroma (Figure 5).

OUTCOME AND FOLLOW-UP

Post-operatively, the patient was discharged on postoperative day 1 following removal of his drain. His post-operative course was uncomplicated. He returned to his work as a manual labor without pain or limitation at three months following surgery.

DISCUSSION

Osteochondromas are benign osteocartilaginous proliferations at a growth plate that typically stop increasing in size at skeletal maturity[5,15]. They infrequently occur in the spine (1% to 4% of osteochondromas) with the majority localized to the cervical spine[4]. Cases of lumbar osteochondromas, like the case presented, are scarce.

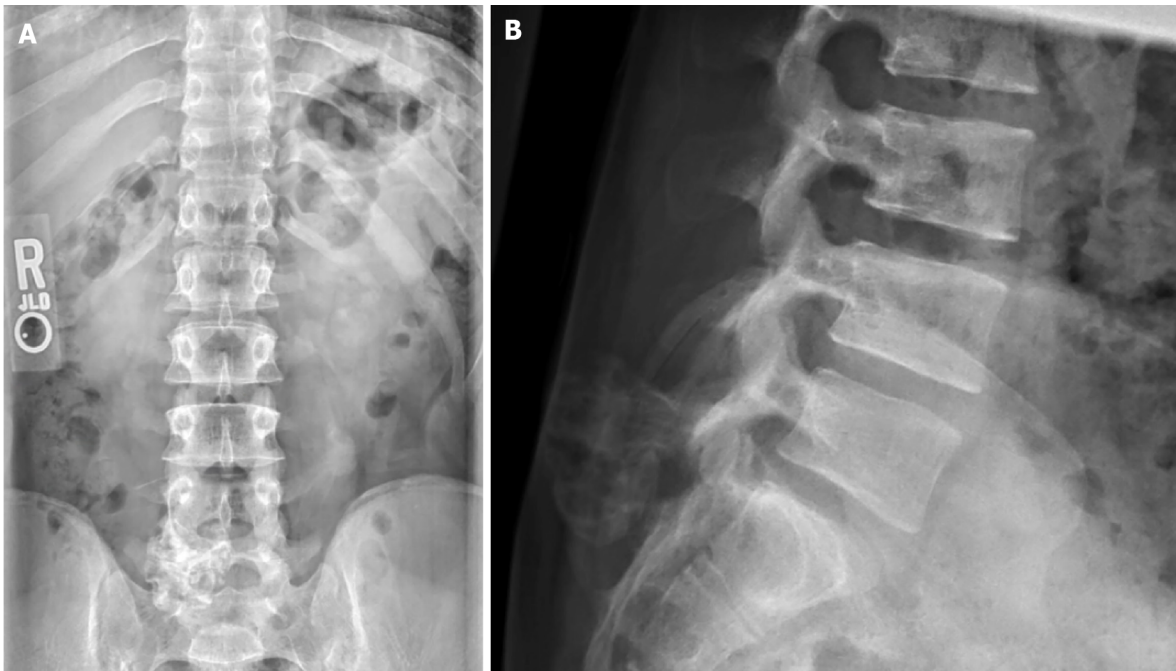


Figure 1 Anterior to posterior and lateral radiographs demonstrating calcified, pedunculated mass protruding from the posterior elements of the L5-S1 vertebral interval. A: Anterior to posterior radiograph; B: Lateral radiograph.

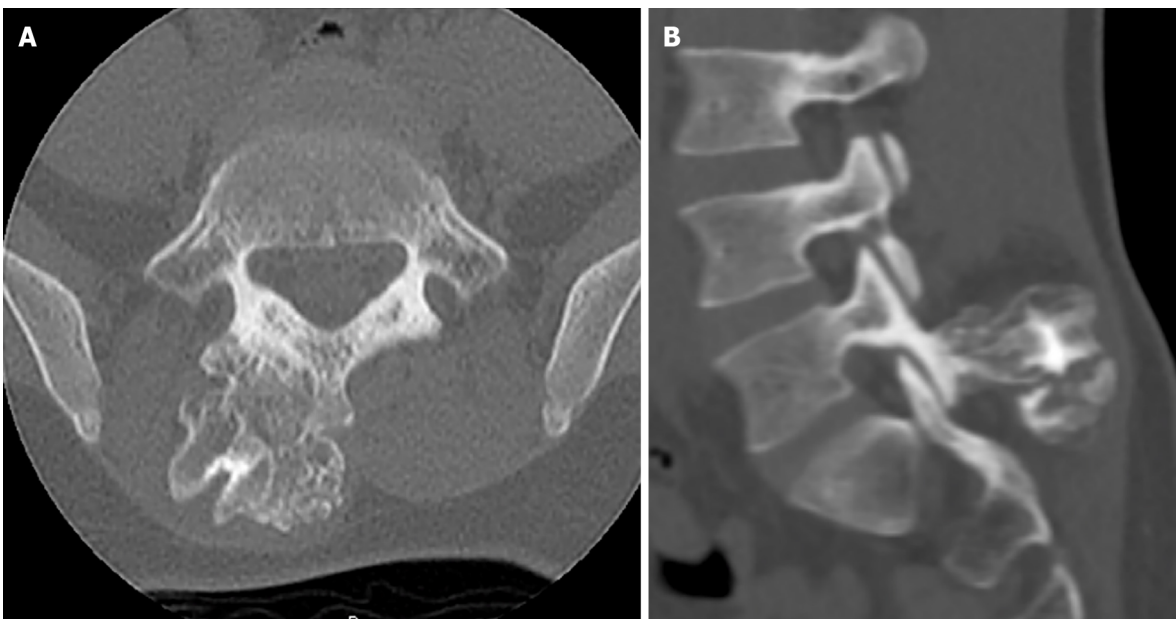


Figure 2 Computed tomography images. A: Axial computed tomography imaging demonstrating osteochondroma protruding from right spinous process/Lamina junction; B: Sagittal computed tomography imaging at the level of the L5/S1 facet joint depicts mass involvement of the right inferior articular process of L5. An ultrasonic bone scalpel was used to remove the mass *en bloc* from the articular process without disrupting the facet capsule.

Patients typically present with axial pain which may be exacerbated with certain positions or activity like the patient in this study. Neurological manifestations from cord compression are rare but have previously been reported[16]. Initial radiographic evaluation may reveal a spinal lesion composed of a cortical protuberance in continuity with the medullary canal. Advanced imaging is recommended to aid in diagnosis. CT imaging provides detail of the osseous and cartilaginous margins whereas MRI can provide the thickness and architecture of the cartilaginous cap. A cartilage cap > 3 cm thickness can indicate malignant transformation[1,4].

Lumbar involvement of these exostoses is rare, perhaps due to increased stiffness of the lumbar spine when compared to the cervical spine and therefore less microtrauma to the epiphyseal cartilage. Osteochondromas occur within the posterior elements of

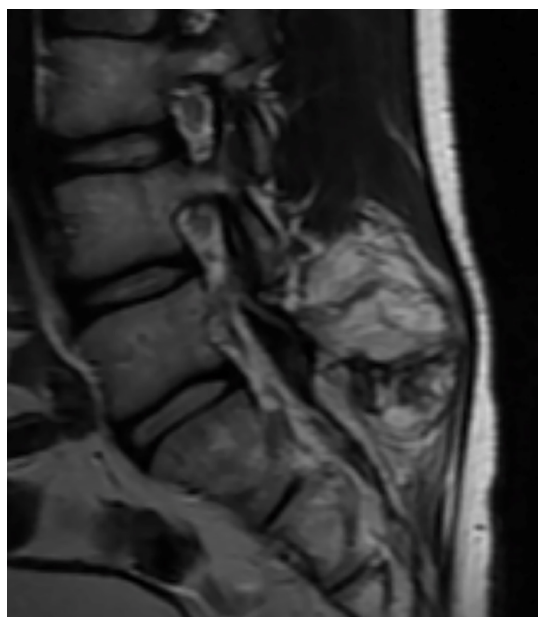


Figure 3 Sagittal T2 magnetic resonance image demonstrating the well-defined 1.5 cm cartilaginous cap of the lumbar osteochondroma extending into the right paraspinal musculature.

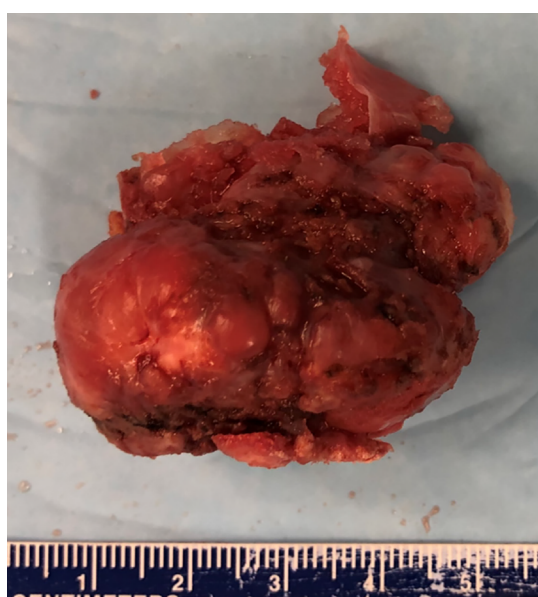

Figure 4 Gross specimen of excised lumbar mass measuring 3.8 cm × 3.5 cm × 2.5 cm with cartilaginous cap and smooth muscle margin.

the spine and may become symptomatic with growth into the paraspinal musculature [17]. A review of lumbosacral osteochondromas performed by Kuraishi *et al* [16] noted radicular symptoms in 4 out of 5 cases. In that series, involvement of the L4 inferior articular processes resulted in an L5 radiculopathy whereas involvement of the superior articular process of S1 corresponded with an L5 radiculopathy.

Given our patient's history of a suprasellar pineal germinoma requiring chemotherapy and radiation, the spinal lesion was potentially radiation-induced. Pediatric oncology literature describes osteochondroma growth as a complication of both localized radiation therapy as well as total body irradiation [18]. The proposed pathogenesis is radiative damage to the epiphyseal plate resulting in immature cartilage fragment migration to the epiphysis and periosteal layers. These cartilage fragments expand during subsequent maturation and ossification. Radiation-induced osteochondromas have been reported in the ulna, tibia, and hands [18-20]. To our knowledge, this is the first detailed case report of a spinal osteochondroma in a

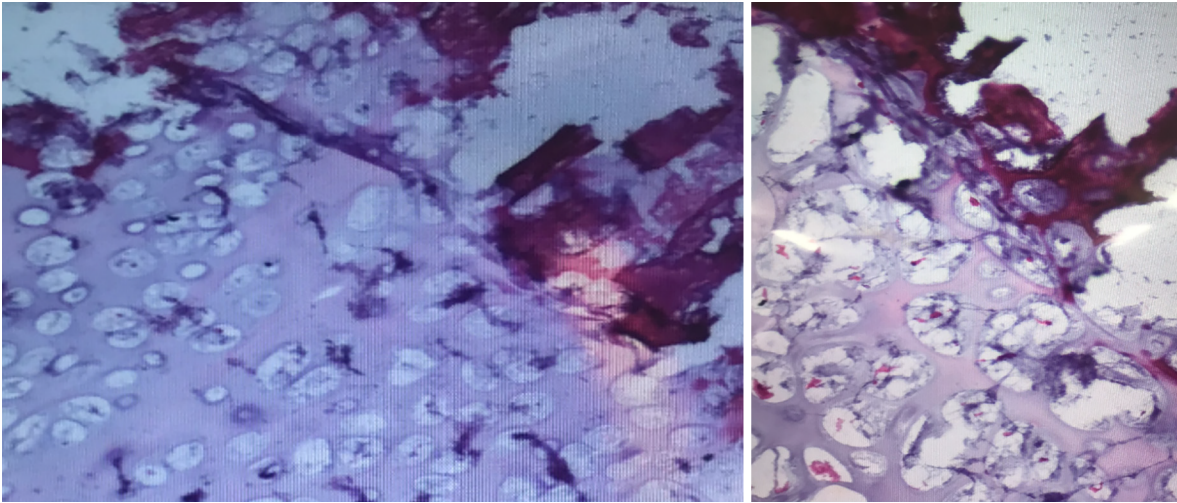


Figure 5 Histology of excised mass demonstrating mature cartilage, fibrous perichondrium, and trabecular bone without evidence of cellular atypia or malignant transformation; consistent with osteochondroma.

pediatric patient with previous radiation treatment.

Painful lesions or those causing neurologic deficit require surgical intervention. If resection entails destabilizing the spine, instrumentation and arthrodesis should be considered. The goal of surgery should be complete resection of the lesion[21]. Surgical nuance of our lumbar osteochondroma excision was the use of an ultrasonic bone scalpel. The ultrasonic bone scalpel amplifies electrical signals that oscillate a blunt blade, allowing for targeted resection of cortical bone without violation of soft tissues [22]. Given the location of our patients osteochondroma with abutment of the right L5 interspinous ligament and right L5-S1 facet capsule, excision of the mass without violating the soft tissues prevented posterior spinal destabilization requiring subsequent instrumentation and fusion.

CONCLUSION

Osteochondromas of the spine are a rare but treatable condition. For symptomatic lesions, complete resection is largely curative without adjuvant therapy. The patient in this case report was pain free at his post-operative visits without signs or symptoms of recurrence or complication. He returned to work as a manual laborer at 3 mo. Further reports of patients diagnosed with osteochondromas and a history of childhood radiation will enable better understanding of radiation-induced osteochondromas and the rates and locations at which they occur.

REFERENCES

- 1 **Motamedi K**, Seeger LL. Benign bone tumors. *Radiol Clin North Am* 2011; **49**: 1115-1134, v [PMID: 22024291 DOI: 10.1016/j.rcl.2011.07.002]
- 2 **O'Brien MF**, Bridwell KH, Lenke LG, Schoenecker PL. Intracanalicular osteochondroma producing spinal cord compression in hereditary multiple exostoses. *J Spinal Disord* 1994; **7**: 236-241 [PMID: 7919647 DOI: 10.1097/00002517-199407030-00007]
- 3 **Pham MH**, Cohen J, Tuchman A, Commins D, Acosta FL. Large solitary osteochondroma of the thoracic spine: Case report and review of the literature. *Surg Neurol Int* 2016; **7**: S323-S327 [PMID: 27274405 DOI: 10.4103/2152-7806.182542]
- 4 **Thakur NA**, Daniels AH, Schiller J, Valdes MA, Czerwein JK, Schiller A, Esmende S, Terek RM. Benign tumors of the spine. *J Am Acad Orthop Surg* 2012; **20**: 715-724 [PMID: 23118137 DOI: 10.5435/JAAOS-20-11-715]
- 5 **Murphey MD**, Choi JJ, Kransdorf MJ, Flemming DJ, Gannon FH. Imaging of osteochondroma: variants and complications with radiologic-pathologic correlation. *Radiographics* 2000; **20**: 1407-1434 [PMID: 10992031 DOI: 10.1148/radiographics.20.5.g00se171407]
- 6 **Sinelnikov A**, Kale H. Osteochondromas of the spine. *Clin Radiol* 2014; **69**: e584-e590 [PMID: 25282617 DOI: 10.1016/j.crad.2014.08.017]
- 7 **Lotfinia I**, Vahedi P, Tubbs RS, Ghavame M, Meshkini A. Neurological manifestations, imaging

- characteristics, and surgical outcome of intraspinal osteochondroma. *J Neurosurg Spine* 2010; **12**: 474-489 [PMID: [20433295](#) DOI: [10.3171/2009.11.SPINE0980](#)]
- 8 **Gorospe L**, Madrid-Muñiz C, Royo A, García-Raya P, Alvarez-Ruiz F, López-Barea F. Radiation-induced osteochondroma of the T4 vertebra causing spinal cord compression. *Eur Radiol* 2002; **12**: 844-848 [PMID: [11960236](#) DOI: [10.1007/s003300101034](#)]
- 9 **Chew FS**, Weissleder R. Radiation-induced osteochondroma. *AJR Am J Roentgenol* 1991; **157**: 792 [PMID: [1892038](#) DOI: [10.2214/ajr.157.4.1892038](#)]
- 10 **Libshitz HI**, Cohen MA. Radiation-induced osteochondromas. *Radiology* 1982; **142**: 643-647 [PMID: [6278535](#) DOI: [10.1148/radiology.142.3.6278535](#)]
- 11 **Heaston DK**, Libshitz HI, Chan RC. Skeletal effects of megavoltage irradiation in survivors of Wilms' tumor. *AJR Am J Roentgenol* 1979; **133**: 389-395 [PMID: [223422](#) DOI: [10.2214/ajr.133.3.389](#)]
- 12 **Cree AK**, Hadlow AT, Taylor TK, Chapman GK. Radiation-induced osteochondroma in the lumbar spine. *Spine (Phila Pa 1976)* 1994; **19**: 376-379 [PMID: [8171375](#) DOI: [10.1097/00007632-199402000-00023](#)]
- 13 **Moriwaka F**, Hozen H, Nakane K, Sasaki H, Tashiro K, Abe H. Myelopathy due to osteochondroma: MR and CT studies. *J Comput Assist Tomogr* 1990; **14**: 128-130 [PMID: [2298977](#) DOI: [10.1097/00004728-199001000-00025](#)]
- 14 **Sultan M**, Khursheed N, Makhdooni R, Ramzan A. Compressive Myelopathy due to Osteochondroma of the Atlas and Review of the Literature. *Pediatr Neurosurg* 2016; **51**: 99-102 [PMID: [26734949](#) DOI: [10.1159/000442473](#)]
- 15 **Gunay C**, Atalar H, Yildiz Y, Saglik Y. Spinal osteochondroma: a report on six patients and a review of the literature. *Arch Orthop Trauma Surg* 2010; **130**: 1459-1465 [PMID: [20107821](#) DOI: [10.1007/s00402-010-1058-7](#)]
- 16 **Kuraishi K**, Hanakita J, Takahashi T, Watanabe M, Honda F. Symptomatic osteochondroma of lumbosacral spine: report of 5 cases. *Neurol Med Chir (Tokyo)* 2014; **54**: 408-412 [PMID: [24172589](#) DOI: [10.2176/nmc.cr2012-0049](#)]
- 17 **Nakaya Y**, Ohue M, Baba I, Fujiwara K, Nakano A, Fukumoto S, Fujishiro T, Neo M. Paraarticular osteochondroma of a lumbar facet joint presenting with radiculopathy. *J Orthop Sci* 2018; **23**: 592-595 [PMID: [27503186](#) DOI: [10.1016/j.jos.2016.03.012](#)]
- 18 **King EA**, Hanauer DA, Choi SW, Jong N, Hamstra DA, Li Y, Farley FA, Caird MS. Osteochondromas after radiation for pediatric malignancies: a role for expanded counseling for skeletal side effects. *J Pediatr Orthop* 2014; **34**: 331-335 [PMID: [23965908](#) DOI: [10.1097/BPO.0000000000000081](#)]
- 19 **Taitz J**, Cohn RJ, White L, Russell SJ, Vowels MR. Osteochondroma after total body irradiation: an age-related complication. *Pediatr Blood Cancer* 2004; **42**: 225-229 [PMID: [14752859](#) DOI: [10.1002/pbc.10426](#)]
- 20 **Jaffe N**, Ried HL, Cohen M, McNeese MD, Sullivan MP. Radiation induced osteochondroma in long-term survivors of childhood cancer. *Int J Radiat Oncol Biol Phys* 1983; **9**: 665-670 [PMID: [6853265](#) DOI: [10.1016/0360-3016\(83\)90232-8](#)]
- 21 **Raswan US**, Bhat AR, Tanki H, Samoon N, Kirmani AR. A solitary osteochondroma of the cervical spine: a case report and review of literature. *Childs Nerv Syst* 2017; **33**: 1019-1022 [PMID: [28349494](#) DOI: [10.1007/s00381-017-3394-1](#)]
- 22 **Chen Y**, Chang Z, Yu X, Song R, Huang W. Use of Ultrasonic Device in Cervical and Thoracic Laminectomy: a Retrospective Comparative Study and Technical Note. *Sci Rep* 2018; **8**: 4006 [PMID: [29507350](#) DOI: [10.1038/s41598-018-22454-y](#)]



Published by **Baishideng Publishing Group Inc**
7041 Koll Center Parkway, Suite 160, Pleasanton, CA 94566, USA

Telephone: +1-925-3991568

E-mail: bpgoffice@wjgnet.com

Help Desk: <https://www.f6publishing.com/helpdesk>

<https://www.wjgnet.com>

