

World Journal of *Orthopedics*

World J Orthop 2022 October 18; 13(10): 876-948



MINIREVIEWS

- 876 Hamstring autograft utilization in reconstructing anterior cruciate ligament: Review of harvesting techniques, graft preparation, and different fixation methods
Albishi W, Baltow B, Albusayes N, Sayed AA, Alrabai HM

STANDARD AND CONSENSUS

- 891 Baishideng's Reference Citation Analysis database announces the first Journal Article Influence Index of 104 core journals and a list of high-quality academic journals in orthopedics
Wang JL, Ma YJ, Ma L, Ma N, Guo DM, Ma LS

ORIGINAL ARTICLE**Retrospective Cohort Study**

- 903 Preoperative and postoperative risk factors for periprosthetic joint infection in primary total hip arthroplasty: A 1-year experience
Tella GF, Donadono C, Castagnini F, Bordini B, Cosentino M, Di Liddo M, Traina F

- 911 Adjunctive platelet-rich plasma and hyaluronic acid injection after arthroscopic debridement in Kellgren-Lawrence grade 3 and 4 knee osteoarthritis
Tirtosuharto H, Wiratnaya IGE, Astawa P

Retrospective Study

- 921 Utilising the impact of COVID-19 on trauma throughput to adapt elective care models for more efficient trauma care
Kulkarni K, Shah R, Mangwani J, Ullah A, Gabbar O, James E, Dias J

Clinical Trials Study

- 932 Traditional Chinese medicine ointment combined with tuina therapy in treatment of pain and swelling after total knee arthroplasty
Xing L, Xu HR, Wang QL, Kong H, Zhang H, Tian J, Ding Y, Yang RX, Zhang L, Jiang B

CASE REPORT

- 940 Derotational osteotomy and internal fixation of a 180° malrotated humerus: A case report
Wenning KE, Schildhauer TA, Jones CB, Hoffmann MF

ABOUT COVER

Editorial Board Member of *World Journal of Orthopedics*, Vito Pavone, MD, PhD, Associate Professor, Department of General Surgery and Medical Surgical Specialties, Section of Orthopaedics and Traumatology, University Hospital Policlinico-Vittorio Emanuele, University of Catania, Catania 95100, Italy. vpavone@unict.it

AIMS AND SCOPE

The primary aim of *World Journal of Orthopedics* (*WJO*, *World J Orthop*) is to provide scholars and readers from various fields of orthopedics with a platform to publish high-quality basic and clinical research articles and communicate their research findings online.

WJO mainly publishes articles reporting research results and findings obtained in the field of orthopedics and covering a wide range of topics including arthroscopy, bone trauma, bone tumors, hand and foot surgery, joint surgery, orthopedic trauma, osteoarthropathy, osteoporosis, pediatric orthopedics, spinal diseases, spine surgery, and sports medicine.

INDEXING/ABSTRACTING

WJO is now abstracted and indexed in PubMed, PubMed Central, Emerging Sources Citation Index (Web of Science), Scopus, Reference Citation Analysis, China National Knowledge Infrastructure, China Science and Technology Journal Database, and Superstar Journals Database. The 2022 edition of Journal Citation Reports® cites the 2021 Journal Citation Indicator (JCI) for *WJO* as 0.62. The *WJO*'s CiteScore for 2021 is 2.4 and Scopus CiteScore rank 2021: Orthopedics and Sports Medicine is 139/284.

RESPONSIBLE EDITORS FOR THIS ISSUE

Production Editor: *Ying-Yi Yuan*, Production Department Director: *Xiang Li*, Editorial Office Director: *Jin-Lei Wang*.

NAME OF JOURNAL

World Journal of Orthopedics

ISSN

ISSN 2218-5836 (online)

LAUNCH DATE

November 18, 2010

FREQUENCY

Monthly

EDITORS-IN-CHIEF

Massimiliano Leigheb

EDITORIAL BOARD MEMBERS

<http://www.wjgnet.com/2218-5836/editorialboard.htm>

PUBLICATION DATE

October 18, 2022

COPYRIGHT

© 2022 Baishideng Publishing Group Inc

INSTRUCTIONS TO AUTHORS

<https://www.wjgnet.com/bpg/gerinfo/204>

GUIDELINES FOR ETHICS DOCUMENTS

<https://www.wjgnet.com/bpg/GerInfo/287>

GUIDELINES FOR NON-NATIVE SPEAKERS OF ENGLISH

<https://www.wjgnet.com/bpg/gerinfo/240>

PUBLICATION ETHICS

<https://www.wjgnet.com/bpg/GerInfo/288>

PUBLICATION MISCONDUCT

<https://www.wjgnet.com/bpg/gerinfo/208>

ARTICLE PROCESSING CHARGE

<https://www.wjgnet.com/bpg/gerinfo/242>

STEPS FOR SUBMITTING MANUSCRIPTS

<https://www.wjgnet.com/bpg/GerInfo/239>

ONLINE SUBMISSION

<https://www.f6publishing.com>



Derotational osteotomy and internal fixation of a 180° malrotated humerus: A case report

Katharina Elisabeth Wenning, Thomas Armin Schildhauer, Clifford Barry Jones, Martin Franz Hoffmann

Specialty type: Surgery

Provenance and peer review:

Unsolicited article; Externally peer reviewed.

Peer-review model: Single blind

Peer-review report's scientific quality classification

Grade A (Excellent): 0

Grade B (Very good): 0

Grade C (Good): C, C

Grade D (Fair): D

Grade E (Poor): 0

P-Reviewer: Abulsoud MI, Egypt; Abulsoud MI, Egypt; Muthu S, India

Received: October 4, 2021

Peer-review started: October 4, 2021

First decision: January 11, 2022

Revised: March 28, 2022

Accepted: October 11, 2022

Article in press: October 11, 2022

Published online: October 18, 2022



Katharina Elisabeth Wenning, Thomas Armin Schildhauer, Martin Franz Hoffmann, Department of General and Trauma Surgery, BG University Hospital Bergmannsheil Bochum, Bochum 44789, Germany

Clifford Barry Jones, Department of Orthopaedic Surgery, Creighton Medical School Phoenix, Phoenix, 85012, United States

Corresponding author: Katharina Elisabeth Wenning, MD, Doctor, Surgeon, Department of General and Trauma Surgery, BG University Hospital Bergmannsheil Bochum, Buerkle de la Camp-Platz 1, Bochum 44789, Germany. katharina.wenning@bergmannsheil.de

Abstract

BACKGROUND

Humeral shaft fractures are relatively common in adults. Rotational malalignment is reported as one complication but severe rotational deformity of the humerus is extremely rare. To our knowledge, only three cases of symptomatic humeral malrotation have been reported. There are sparse literature reports of humeral reconstruction correction.

CASE SUMMARY

We present a case of extreme rotational deformity of the humerus (180°) after humeral shaft fracture. The patient complained of pain and difficulties with activities of daily living. In addition, she found the deformity cosmetically unacceptable. Therefore, she was searching for surgical correction. Neurolysis of the radial nerve followed by derotational osteotomy of the humerus and internal fixation were performed. Postoperatively, the patient demonstrated transient iatrogenic radial nerve palsy which recovered completely during postoperative follow-up. The Disabilities of the Arm, Shoulder, and Hand score improved from 55 preoperatively to 16 at the final 2-year follow-up.

CONCLUSION

Single-stage radial neurolysis, derotational osteotomy and stable fixation is a feasible option to improve anatomic and functional problems of severely malrotated humeral shaft fractures.

Key Words: Humerus; Malrotation; Corrective osteotomy; Plate osteosynthesis; Radial nerve palsy; Case report

Core Tip: We present a case of extreme rotational deformity of the humerus (180°) after humeral shaft fracture. The patient complained about pain and difficulties with activities of daily living. A neurolysis of the radial nerve followed by derotational osteotomy of the humerus and internal fixation were performed. Postoperatively, the patient demonstrated transient iatrogenic radial nerve palsy which had complete recovery at 2 years postoperatively. The Disabilities of the Arm, Shoulder, and Hand score improved from a preoperative 55 to a final 16 at the final 2-year follow-up.

Citation: Wenning KE, Schildhauer TA, Jones CB, Hoffmann MF. Derotational osteotomy and internal fixation of a 180° malrotated humerus: A case report. *World J Orthop* 2022; 13(10): 940-948

URL: <https://www.wjgnet.com/2218-5836/full/v13/i10/940.htm>

DOI: <https://dx.doi.org/10.5312/wjo.v13.i10.940>

INTRODUCTION

Humeral shaft fractures are relatively common, accounting for approximately 1%-5% of all fractures and 20% of humeral fractures in adults[1-2]. These fractures have been historically regarded as benign fractures; as such, most are managed nonoperatively with functional bracing. The assumption of benign nature is based on the robust blood supply of the humerus, its limited weight-bearing characteristics and the technical ease of splint application[3-4].

Upper extremity function is primarily dependent on the hand's ability to reach a desired point in space. Most studies of malalignment have focused on angulation[5-6]. Rotational malalignment has been reported as a possible complication of humeral shaft fractures, but considered normally tolerated and to not necessitate a surgical intervention. Nevertheless, extreme rotational deformity following humeral shaft fractures can occur and the recommended treatment for these entities has been rarely touched upon in the literature.

Herein, we describe a case of a 180° rotational deformity that developed after a midshaft humeral fracture that had been clinically addressed by nonoperative treatment which had resulted in shortening of the humerus, limited range of motion (ROM) of the shoulder, and flexion contracture of the elbow.

CASE PRESENTATION

Chief complaints

The patient complained of resting pain exacerbated with activities and severe limitations in activities of daily living. Furthermore, the cosmetic deformity was repulsive to her.

History of present illness

In 2009, the right-hand-dominant patient had sustained a traumatic left humeral shaft fracture which was treated nonoperatively. In 2019 at age 27, she was referred to our institution with severe malrotation of her left humerus associated with shortening of the upper arm and limited ROM of the shoulder and elbow. The patient complained about consistent pain which increases during activities and severe limitations of activities of daily living. Furthermore, the cosmetic deformity was repulsive to her.

History of past illness

There is no history of past illness.

Personal and family history

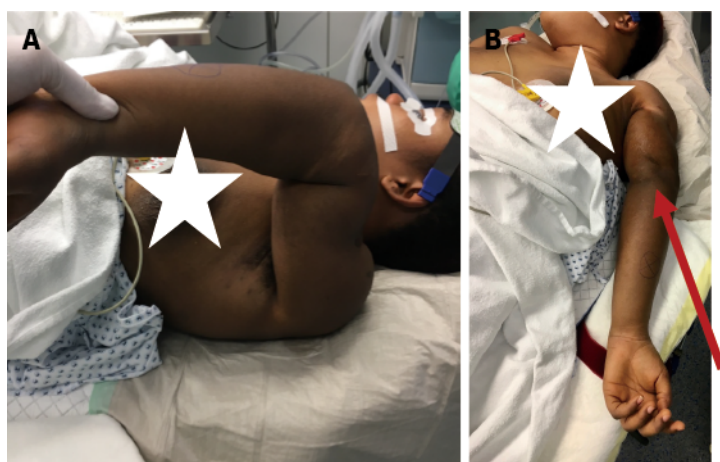Personal and family history are not known.

Physical examination

Physical examination detected a rotational deformity of the left upper arm of 180°. In supine position, the palm of her left hand and her olecranon were facing up (Figure 1). The Patient's left arm was 5 cm shorter than her right (51 cm vs 56 cm). She complained of tenderness over the whole upper arm and movement-dependent pain in the shoulder region. No neurological deficits were diagnosed. Shoulder ROM was presented with only 80° of abduction (Table 1). The elbow demonstrated a flexion contracture of 85°. The patient's forearm was fixed in neutral with total loss of pronation and supination. Wrist ROM was about normal.

Table 1 Range of motion of the patient's left upper extremity

	Preoperative	Postoperative
Shoulder		
Flexion/anteversion	80°	140°
Extension/retroversion	20°	25°
External rotation	30°	30°
Internal rotation	60°	60°
Abduction	80°	80°
Adduction	10°	20°
Elbow		
Flexion	85°	90°
Extension	0°	0°
Pronation	0°	80°
Supination	0°	80°
Wrist		
Flexion	50°	50°
Extension	50°	50°
Radial deviation	20°	20°
Ulnar deviation	30°	30°



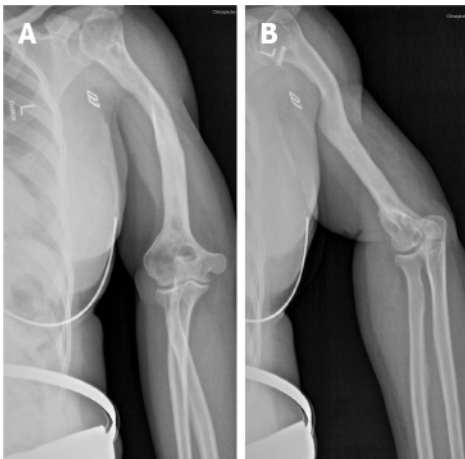
DOI: 10.5312/wjo.v13.i10.940 Copyright ©The Author(s) 2022.

Figure 1 Severe malalignment of the patient's left arm. A: The patient in the operating room demonstrating the extreme deformity of the left upper extremity; B: In the supine position the palm of her hand and her olecranon (red arrow) were facing up.**Laboratory examinations**

Laboratory examinations were unnecessary.

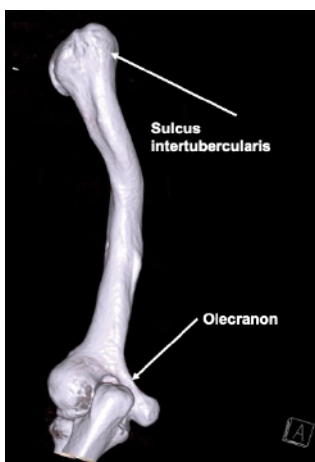Imaging examinations

Radiographic imaging of the left shoulder and humerus demonstrated a malunited humeral shaft fracture with extensive remodeling and consolidated fracture site (Figure 2A). In addition, the shoulder displayed classic signs of post-traumatic osteoarthritis (Figure 2B). Preoperative three-dimensional computed tomography (3D CT) imaging confirmed a 180° malrotation of the humerus (Figure 3).



DOI: 10.5312/wjo.v13.i10.940 Copyright ©The Author(s) 2022.

Figure 2 Preoperative X-ray of the patient's left upper extremity. A: Preoperative X-rays of the left shoulder and upper arm of the patient revealed a deformed humerus and a complete consolidation; B: In addition, the X-ray displayed classic signs of post-traumatic osteoarthritis of the shoulder.



DOI: 10.5312/wjo.v13.i10.940 Copyright ©The Author(s) 2022.

Figure 3 Preoperative three-dimensional computed tomography of the patient's humerus. Extreme malrotation of 180° was detectable. The sulcus intertubercularis and olecranon served as landmarks.

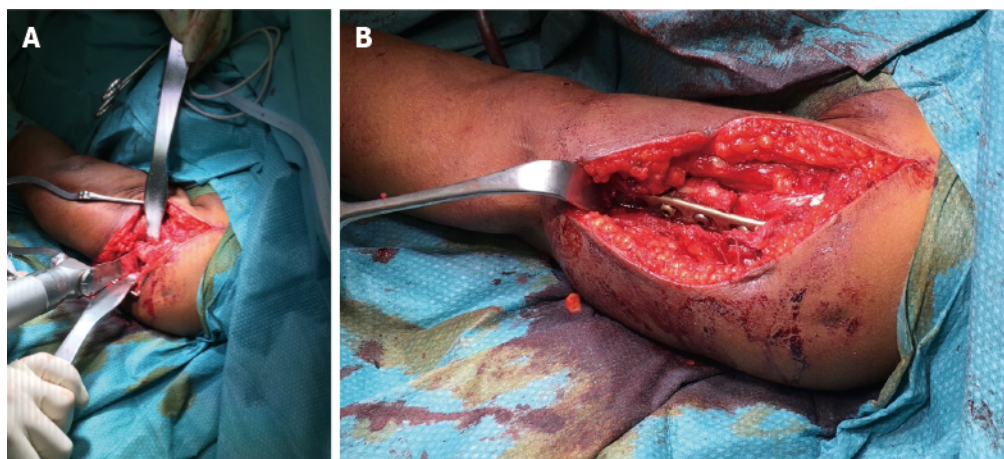
FINAL DIAGNOSIS

The patient demonstrated with rotational deformity of the left upper arm of 180°. Imaging of the left shoulder and upper arm revealed a malunited humeral fracture with extensive remodeling and fracture site consolidation.

TREATMENT

Preoperatively, different surgical options were discussed with the patient and her family. The patient gave informed consent for a single staged procedure with complete radial nerve neurolysis followed by corrective osteotomy and internal fixation *via* plate fixation.

Ten years after the initial injury, the patient finally underwent derotational osteotomy with internal fixation of the left humerus and radial nerve exploration. Surgery was performed in the supine position under brachial plexus blocking and general anesthesia. Proximal humerus and the humeral shaft were exposed through a deltopectoral approach with extension distally anteriorly, following the anatomic muscles of the upper arm. Through the same anterior extensile incision, the radial nerve was exposed and released from the posterior aspect of the deltoid, through the lateral intermuscular septum, to the distal the arm in order not to lessen tension during the humeral derotation. A transverse osteotomy at the level of the consolidated fracture was performed carefully with a micro-oscillating saw and using instruments to protect surrounding and posterior soft tissues (Figure 4A). Subsequently, the entire distal



DOI: 10.5312/wjo.v13.i10.940 Copyright ©The Author(s) 2022.

Figure 4 Intraoperative photographs. A: Transversal osteotomy of the humerus was performed at the level of the former fracture; B: Internal fixation was done with the use of an eight-hole dynamic compression plate (Limited Contact Dynamic Compression Plate System).

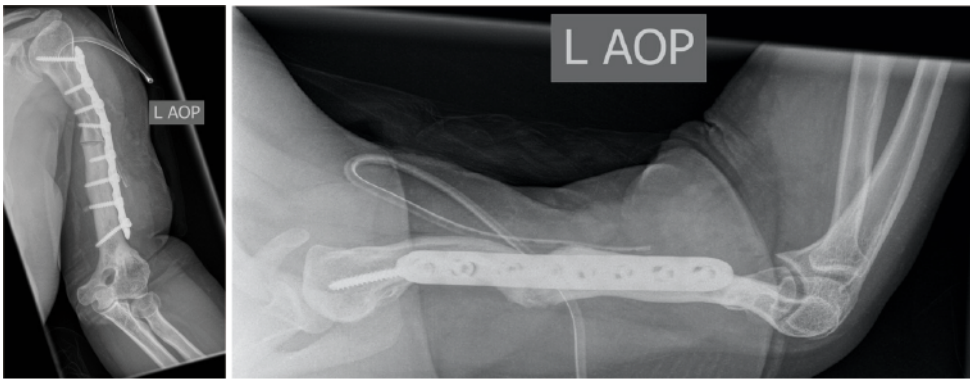
humerus was rotated 180° demonstrating no tension to the radial nerve under direct visualization. Finally, internal fixation was performed utilizing an (3.5 mm or 4.5 mm) eight-hole dynamic compression plate [Limited Contact Dynamic Compression Plate System (LC-DCP); DePuySynthes, Warsaw, IN, United States] (Figures 4B and 5). Postoperatively, normal vascularity was noted, and soft compartments were noted, but a secondary or iatrogenic partial radial nerve palsy with weak wrist and digit extension and decreased light touch sensation in the radial nerve distribution. This injury was related to devascularization from dissection and manipulation of the nerve and less likely from the preoperative brachial plexus regional block. Secondary to the known intact and not impinged radial nerve at the end of the procedure, the patient and surgeons agreed to treat this transient radial nerve palsy with observation and did not re-explore the dissection.

The osteotomy zone was immobilized utilizing a Gilchrist-bandage for 4 wk postoperatively. Physical therapy with shoulder mobilization was initiated immediately after surgery. Shoulder and elbow ROM gradually increased and full ROM was allowed after 6 wk. Additionally, the weakened wrist muscles were immobilized in a functional splint and daily passive exercises were performed to maintain full ROM and to avoid contractures.

Initially, the skin incision had healed uneventfully and no signs of superficial or deep surgical site infection were noted. However, approximately 4 mo postoperatively, the patient presented with a deep surgical site infection with involvement of the osteosynthesis material and a non-consolidated osteotomy zone (an infected nonunion with fixation failure). Since the patient was healthy without comorbidities, she wanted to continue with therapy and avoid recurrence of the deformity. Therefore, a single stage revision was reviewed with the patient. Operative treatment consisted of plate removal with thorough excisional debridement, recanalization of the humerus, followed by re-osteosynthesis as a single staged procedure. *Aerococcus viridans* bacteria were detected in the deep intraoperative tissue cultures. Therefore, an antimicrobial therapy with clindamycin was initiated and continued for 6 wk.

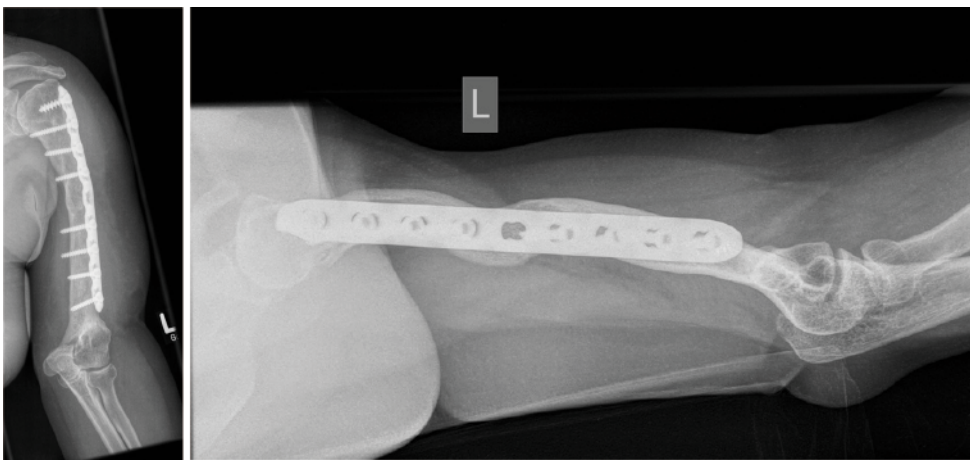
OUTCOME AND FOLLOW-UP

After revision surgery, the patient did not present for follow-up appointments. We assumed that she was satisfied with the operative outcome and had resolution of the infection and preoperative functional difficulties. Approximately 2 years after initial surgery, we contacted the patient and scheduled an appointment. She reported a high level of satisfaction, resolution of infection, diminishment of pain, and a complete return to daily activities and caring of her two toddlers. Physical exam demonstrated complete healing of the soft tissues and resolution of the infection and imaging demonstrated consolidation of the osteotomy zone (Figure 6). The patient only complained of pain in her left upper arm and shoulder when carrying heavy objects or after a strenuous day with constant use of her arm. She demonstrated increased shoulder ROM: flexion/extension 140-0-25°, abduction/adduction 80-0-20° and improved elbow ROM: flexion/extension 0-0-90°, with free supination and pronation. Compared to preoperative function, she demonstrated a marked improvement in all areas of arm motion. She did not have full shoulder ROM secondary to the preoperative, degenerative changes of her left shoulder (Figure 7). The patient described gradual improvement in the radial function within 3-4 mo of the initial surgery with complete recovery of the transient radial nerve palsy at the time of the follow-up examination. The patient completed the follow up Disabilities of the Arm, Shoulder, and



DOI: 10.5312/wjo.v13.i10.940 Copyright ©The Author(s) 2022.

Figure 5 Postoperative X-rays of the patient's left humerus after corrective osteotomy and internal fixation.



DOI: 10.5312/wjo.v13.i10.940 Copyright ©The Author(s) 2022.

Figure 6 X-rays at the patient's 2-year follow-up appointment. There was complete consolidation of the osteotomy zone.



DOI: 10.5312/wjo.v13.i10.940 Copyright ©The Author(s) 2022.

Figure 7 Postoperative cosmetic and functional outcome.

Hand (DASH) questionnaire comparing the pre- and post-operative scores. The DASH score improved from a preoperative score of 55 to 16 at the final follow-up.

DISCUSSION

Although rotational malalignment is recognized as a possible complication of humeral shaft fractures in adults, extreme rotational deformities are extremely rare. Accordingly, the literature regarding this topic is sparse. To our knowledge, only three cases have been reported[7,8] and there are only a few papers regarding upper limb correction in general, with most focusing on non-traumatic and pediatric indications[9,10]. In contrast, deformity correction and bone lengthening of the lower extremities are standard techniques with an increasing number of reports appearing in the literature. External fixators (unilateral, multi-axial, or circular) are utilized. Bulky techniques, like Ilizarov external fixation or Taylor-Spatial-Frame are still practiced and offered as reliable treatment options[11,12]. For upper limb treatment, circular fixation techniques like the Ilizarov external fixator and Taylor-Spatial-Frame pose problems of discomfort because of the limited distance to the thorax. Additionally, proximal or midshaft humeral fractures provide only limited bone stock for proximal fixation for all external fixation systems.

In our patient, the indications for operative intervention were the cosmetically unacceptable condition of a 180° malrotated arm as well as the inability to perform routine daily activities. She also reported limited ROM and severe pain of her left arm during shoulder movement. More extensive deformity corrections are usually performed as staged or continuous procedures utilizing external fixation to preserve neural structures and blood supply[13]. In our case, we decided against surgical correction by an external fixator for several reasons. On the one hand, the patient declined treatment with an Ilizarov fixator, citing the extensive follow-up care associated with it. Additionally, we needed a quick solution because it was unclear how long the patient would be in the area and available for follow-up and stepwise correction.

Although the patient's left arm already presented with a shorter length preoperatively, this condition did not bother our patient. Due to the decision just to perform a rotational correction and no lengthening of the arm, we chose derotational osteotomy, and exposure and release of the radial nerve by internal fixation. We assumed that exposing the nerve would reduce the risk for radial nerve injury. Nevertheless, the patient experienced radial nerve palsy postoperatively. Because of the good visualization of the radial nerve, we were able to rule out disruption or compression. There are reports of radial nerve injuries after deformity correction of the upper limb with different fixation systems[11,14] as well as after closed reduction of severe rotational deformity of the humerus[8]. Data on iatrogenic radial nerve injuries for open procedures vary between 6%-32%[15,16].

Regarding treatment, no clear consensus exists regarding if and when the nerve should be surgically explored[17]. Some authors recommend early exploration in cases of secondary nerve palsy[18], others advocate observation for a 4-to-6-mo period[19,20]. According to the literature, secondary radial nerve palsy has a good overall recovery rate of 93%[21]. In our case, the "wait and see" strategy was sufficient as the patient achieved complete neurological recovery. An increasing improvement in the radial nerve palsy was observed already after 4 mo. Two years after the initial surgery, the neurologic deficit had completely recovered, but the exact time point remains unclear because of the discontinued follow-up visits.

Different treatment options for surgical site infections and infected nonunions during a single or staged procedure have been discussed[22,23]. Due to the fact that our patient presented with infection 4 mo postoperatively, nonunion with secondary infection was assumed. Wu *et al*[24] reported a preference for single-stage treatment to address infected nonunions with Ilizarov fixation. Since our patient was healthy without comorbidities, we respected her request to continue with the initial therapy in order to avoid external fixation or recurrence of the deformity. Therefore, thorough debridement and hardware exchange were performed as a single-stage revision. Olszewski *et al*[22] reported their support of such an approach, based upon their data showing that 78% of patients healed after an index procedure and were able to avoid external fixation.

Bae *et al*[25] also described a case of severe malrotation of the humerus after humeral shaft fracture. Similar to our treatment, those authors described the performance of a derotation osteotomy of the left humerus with internal fixation and exposure of the radial nerve. They also reported a good postoperative result without neurological deficits.

In our case, the patient benefited greatly from the surgical procedure. Her preoperative DASH score was quite high (at 55) and had improved significantly after the deformity correction (to 16). Her 180° malrotated left upper arm represented a cosmetic problem, serving as a mental burden and significantly impairing her functional activities of daily living. Therefore, our treatment aimed for correction of the deformity, improvement of function, pain reduction, and achievement of the desired cosmetic result. These goals were achieved with very good results. The humeral malrotation has been entirely corrected and the overall deformity was reduced. Above all, shoulder ROM (especially shoulder flexion: 80° *vs* 140°) and pronation/supination of the elbow (0° *vs* 80°) increased significantly due to a more anatomic position of the humeral head articular surface. Some limitations persisted due to pre-existing degenerative changes. Furthermore, the flexion contracture of the elbow could not be resolved because of the long existing malalignment of the upper limb.

The patient noticed relevant pain relief from "severe" (preoperative) to "no" or "mild" pain postoperatively. At the 2-year follow-up appointment, she was very satisfied with the result of the operation. She indicated that she occasionally has pain in her left arm while carrying heavy objects. Ultimately, she

stated that she is now living a normal life with her children without limitations in her everyday activities.

Our case complements the sparse literature of extreme malrotation deformity of the humerus and illustrates that corrective osteotomy with internal fixation may be a feasible treatment approach to avoid uncomfortable circular external fixation and to reach good postoperative results. It is a valid method that improved outcomes following deformity correction. We admit that a stepwise procedure utilizing a fixator (*e.g.*, a Taylor-Spatial frame) would have offered the option of additional lengthening.

CONCLUSION

Malalignment after humeral shaft fractures often includes a malrotation component. Extensive rotational correction is rare and the literature is sparse. Common procedures for extensive alignment correction utilizing circular external fixations cause a great amount of discomfort, especially when utilized on the proximal or midshaft humerus. Acute rotational correction of 180° is feasible and can lead to good clinical results when performed carefully.

FOOTNOTES

Author contributions: Wenning KE helped with data collection, interpretation and writing the case report; Hoffmann MF contributed to study concept/design and data analysis; Jones CB, Schildhauer TA and Hoffmann MF helped with interpretation and contributed to the review of the final manuscript and final submission of the paper.

Informed consent statement: Written informed consent was obtained from the patient for publication of this case report and accompanying images.

Conflict-of-interest statement: All authors report no relevant conflict of interest for this article.

CARE Checklist (2016) statement: The authors have read the CARE Checklist (2016), and the manuscript was prepared and revised according to the CARE Checklist (2016).

Open-Access: This article is an open-access article that was selected by an in-house editor and fully peer-reviewed by external reviewers. It is distributed in accordance with the Creative Commons Attribution NonCommercial (CC BY-NC 4.0) license, which permits others to distribute, remix, adapt, build upon this work non-commercially, and license their derivative works on different terms, provided the original work is properly cited and the use is non-commercial. See: <https://creativecommons.org/licenses/by-nc/4.0/>

Country/Territory of origin: Germany

ORCID number: Katharina Elisabeth Wenning 0000-0003-0044-8107; Thomas Armin Schildhauer 0000-0002-3232-9869; Clifford Barry Jones 0000-0003-0273-676X; Martin Franz Hoffmann 0000-0003-0194-1497.

S-Editor: Wu YXJ

L-Editor: Filipodia

P-Editor: Wu YXJ

REFERENCES

- 1 Gallusser N, Barimani B, Vauclair F. Humeral shaft fractures. *EFORT Open Rev* 2021; **6**: 24-34 [PMID: 33532084 DOI: 10.1302/2058-5241.6.200033]
- 2 Brinker MR, O'Connor DP. The incidence of fractures and dislocations referred for orthopaedic services in a capitated population. *J Bone Joint Surg Am* 2004; **86**: 290-297 [PMID: 14960673 DOI: 10.2106/00004623-200402000-00011]
- 3 Rämö L, Sumrein BO, Lepola V, Lähdeoja T, Ranstam J, Paavola M, Järvinen T, Taimela S; FISH Investigators. Effect of Surgery vs Functional Bracing on Functional Outcome Among Patients With Closed Displaced Humeral Shaft Fractures: The FISH Randomized Clinical Trial. *JAMA* 2020; **323**: 1792-1801 [PMID: 32396179 DOI: 10.1001/jama.2020.3182]
- 4 Garavito C. Humeral Shaft Fractures. Rockwood Green's Fract Adults Philadelphia Wolters Kluwer. 2020; 1: 1231-1291
- 5 Arora R, Fichadia U, Hartwig E, Kannikeswaran N. Pediatric upper-extremity fractures. *Pediatr Ann* 2014; **43**: 196-204 [PMID: 24877490 DOI: 10.3928/00904481-20140417-12]
- 6 Robinson CM, Wylie JR, Ray AG, Dempster NJ, Olabi B, Seah KT, Akhtar MA. Proximal humeral fractures with a severe varus deformity treated by fixation with a locking plate. *J Bone Joint Surg Br* 2010; **92**: 672-678 [PMID: 20436005 DOI: 10.1302/0301-620X.92B5.22849]
- 7 Hawi N, Razaian S, Krettek C, Meller R, Liodakis E. [Torsional malalignment of the humerus]. *Unfallchirurg* 2018; **121**:

- 199-205 [PMID: [29305619](#) DOI: [10.1007/s00113-017-0453-8](#)]
- 8 **Chan D**, Petricciuolo F, Maffulli N. Fracture of the humeral diaphysis with extreme rotation. *Acta Orthop Belg* 1991; **57**: 427-429
- 9 **Farr S**, Mindler G, Ganger R, Girsch W. Bone Lengthening in the Pediatric Upper Extremity. *J Bone Joint Surg Am* 2016; **98**: 1490-1503 [PMID: [27605694](#) DOI: [10.2106/JBJS.16.00007](#)]
- 10 **Tellisi N**, Ilizarov S, Fragomen AT, Rozbruch SR. Humeral lengthening and deformity correction in Ollier's disease: distraction osteogenesis with a multiaxial correction frame. *J Pediatr Orthop B* 2008; **17**: 152-157 [PMID: [18391816](#) DOI: [10.1097/BPB.0b013e3282f548dc](#)]
- 11 **Hosny GA**. Humeral lengthening and deformity correction. *J Child Orthop* 2016; **10**: 585-592 [PMID: [27826910](#) DOI: [10.1007/s11832-016-0789-6](#)]
- 12 **Malkova TA**, Borzunov DY. International recognition of the Ilizarov bone reconstruction techniques: Current practice and research (dedicated to 100th birthday of G. A. Ilizarov). *World J Orthop* 2021; **12**: 515-533 [PMID: [34485099](#) DOI: [10.5312/wjo.v12.i8.515](#)]
- 13 **Goodier WD**, Calder PR. External fixation for the correction of adult post-traumatic deformities. *Injury* 2019; **50** Suppl 1: S36-S44 [PMID: [31054864](#) DOI: [10.1016/j.injury.2019.03.040](#)]
- 14 **Malot R**, Park KW, Song SH, Kwon HN, Song HR. Role of hybrid monolateral fixators in managing humeral length and deformity correction. *Acta Orthop* 2013; **84**: 280-285 [PMID: [23506166](#) DOI: [10.3109/17453674.2013.786636](#)]
- 15 **Hak DJ**. Radial nerve palsy associated with humeral shaft fractures. *Orthopedics* 2009; **32**: 111 [DOI: [10.3928/01477447-20090201-26](#)]
- 16 **Bumbasirević M**, Lesić A, Bumbasirević V, Cobeljić G, Milosević I, Atkinson HD. The management of humeral shaft fractures with associated radial nerve palsy: a review of 117 cases. *Arch Orthop Trauma Surg* 2010; **130**: 519-522 [PMID: [19669771](#) DOI: [10.1007/s00402-009-0951-4](#)]
- 17 **Schwab TR**, Stillhard PF, Schibli S, Furrer M, Sommer C. Radial nerve palsy in humeral shaft fractures with internal fixation: analysis of management and outcome. *Eur J Trauma Emerg Surg* 2018; **44**: 235-243 [PMID: [28280873](#) DOI: [10.1007/s00068-017-0775-9](#)]
- 18 **Kwasny O**, Maier R, Kutscha-Lissberg F, Scharf W. [Treatment procedure in humeral shaft fractures with primary or secondary radial nerve damage]. *Unfallchirurgie* 1992; **18**: 168-173 [PMID: [1636222](#) DOI: [10.1007/BF02588269](#)]
- 19 **Liu GY**, Zhang CY, Wu HW. Comparison of initial nonoperative and operative management of radial nerve palsy associated with acute humeral shaft fractures. *Orthopedics* 2012; **35**: 702-708 [PMID: [22868596](#) DOI: [10.3928/01477447-20120725-10](#)]
- 20 **Wang JP**, Shen WJ, Chen WM, Huang CK, Shen YS, Chen TH. Iatrogenic radial nerve palsy after operative management of humeral shaft fractures. *J Trauma* 2009; **66**: 800-803 [PMID: [19276756](#) DOI: [10.1097/TA.0b013e31816142cf](#)]
- 21 **Korompilias AV**, Lykissas MG, Kostas-Agnantis IP, Vekris MD, Soucacos PN, Beris AE. Approach to radial nerve palsy caused by humerus shaft fracture: is primary exploration necessary? *Injury* 2013; **44**: 323-326 [PMID: [23352153](#) DOI: [10.1016/j.injury.2013.01.004](#)]
- 22 **Olszewski D**, Streubel PN, Stucken C, Ricci WM, Hoffmann MF, Jones CB, Sietsema DL, Tornetta P 3rd. Fate of Patients With a "Surprise" Positive Culture After Nonunion Surgery. *J Orthop Trauma* 2016; **30**: e19-e23 [PMID: [26270457](#) DOI: [10.1097/BOT.0000000000000417](#)]
- 23 **Nasser AAH**, Fenton P, Bose D. Single stage versus two-stage orthoplastic management of bone infection. *Injury* 2022; **53**: 984-991 [PMID: [35063261](#) DOI: [10.1016/j.injury.2022.01.020](#)]
- 24 **Wu CC**. Single-stage surgical treatment of infected nonunion of the distal tibia. *J Orthop Trauma* 2011; **25**: 156-161 [PMID: [21278604](#) DOI: [10.1097/BOT.0b013e3181eaa35](#)]
- 25 **Bae H**, Widmann RF, Hotchkiss RN. Extreme rotational malunion of the humerus. A case report. *J Bone Joint Surg Am* 2001; **83**: 424-427 [PMID: [11263648](#) DOI: [10.2106/00004623-200103000-00016](#)]



Published by **Baishideng Publishing Group Inc**
7041 Koll Center Parkway, Suite 160, Pleasanton, CA 94566, USA

Telephone: +1-925-3991568

E-mail: bpgoffice@wjgnet.com

Help Desk: <https://www.f6publishing.com/helpdesk>

<https://www.wjgnet.com>

