

# World Journal of *Orthopedics*

*World J Orthop* 2022 May 18; 13(5): 411-543



## REVIEW

- 411 Update in combined musculoskeletal and vascular injuries of the extremities  
*Stefanou N, Arnaoutoglou C, Papageorgiou F, Matsagkas M, Varitimidis SE, Dailiana ZH*
- 427 Coronal plane deformity around the knee in the skeletally immature population: A review of principles of evaluation and treatment  
*Coppa V, Marinelli M, Procaccini R, Falcioni D, Farinelli L, Gigante A*

## ORIGINAL ARTICLE

## Retrospective Study

- 444 Insufficient lateral stem contact is an influencing factor for significant subsidence in cementless short stem total hip arthroplasty  
*Suksathien Y, Chuvanichanon P, Tippimanchai T, Sueajui J*
- 454 Distal femur complex fractures in elderly patients treated with megaprosthesis: Results in a case series of 11 patients  
*Zanchini F, Piscopo A, Cipolloni V, Fusini F, Cacciapuoti S, Piscopo D, Pripp C, Nasto LA, Pola E*

## Observational Study

- 465 Prevalence and factors of work-related musculoskeletal disorders among hand surgeons  
*Alqahtani SM, Alzahrani MM, Bicknell R, Pichora D*
- 472 What factors are important to new patients when selecting an orthopedic oncologist?  
*Gusho CA, Patel V, Lee L, Blank AT*

## SYSTEMATIC REVIEWS

- 481 Anterior vertebral body tethering for idiopathic scoliosis in growing children: A systematic review  
*Bizzoca D, Piazzolla A, Moretti L, Vicenti G, Moretti B, Solarino G*
- 494 Effect of non-steroidal anti-inflammatory drugs on fracture healing in children: A systematic review  
*Stroud S, Katyal T, Gornitzky AL, Swarup I*
- 503 Prosthetic joint infection of the hip and knee due to *Mycobacterium* species: A systematic review  
*Santoso A, Phatama KY, Rhatomy S, Budhiparama NC*
- 515 Prophylactic fixation of the unaffected contralateral side in children with slipped capital femoral epiphysis seems favorable: A systematic review  
*Vink SJC, van Stralen RA, Moerman S, van Bergen CJA*

**CASE REPORT**

- 528** Intramedullary bone pedestal formation contributing to femoral shaft fracture nonunion: A case report and review of the literature

*Pasque CB, Pappas AJ, Cole Jr CA*

- 538** Extensive adhesion formation in a total knee replacement in the setting of a gastrointestinal stromal tumor: A case report

*Mitchell S, Lee A, Stenquist R, Yatsosky II D, Mooney ML, Shendge VB*

**ABOUT COVER**

Editorial Board Member of *World Journal of Orthopedics*, Farid Amirouche, MS, PhD, Professor, Department of Orthopedics Surgery, University of Illinois at Chicago, Chicago, IL 60612, United States. amirouch@uic.edu

**AIMS AND SCOPE**

The primary aim of *World Journal of Orthopedics* (WJO, *World J Orthop*) is to provide scholars and readers from various fields of orthopedics with a platform to publish high-quality basic and clinical research articles and communicate their research findings online.

WJO mainly publishes articles reporting research results and findings obtained in the field of orthopedics and covering a wide range of topics including arthroscopy, bone trauma, bone tumors, hand and foot surgery, joint surgery, orthopedic trauma, osteoarthropathy, osteoporosis, pediatric orthopedics, spinal diseases, spine surgery, and sports medicine.

**INDEXING/ABSTRACTING**

The WJO is now abstracted and indexed in PubMed, PubMed Central, Emerging Sources Citation Index (Web of Science), Scopus, Reference Citation Analysis, China National Knowledge Infrastructure, China Science and Technology Journal Database, and Superstar Journals Database. The 2021 edition of Journal Citation Reports® cites the 2020 Journal Citation Indicator (JCI) for WJO as 0.66. The WJO's CiteScore for 2020 is 3.2 and Scopus CiteScore rank 2020: Orthopedics and Sports Medicine is 87/262.

**RESPONSIBLE EDITORS FOR THIS ISSUE**

**Production Editor:** Ying-Yi Yuan; **Production Department Director:** Xiang Li; **Editorial Office Director:** Jin-Lai Wang.

**NAME OF JOURNAL**

*World Journal of Orthopedics*

**ISSN**

ISSN 2218-5836 (online)

**LAUNCH DATE**

November 18, 2010

**FREQUENCY**

Monthly

**EDITORS-IN-CHIEF**

Massimiliano Leigheb

**EDITORIAL BOARD MEMBERS**

<http://www.wjgnet.com/2218-5836/editorialboard.htm>

**PUBLICATION DATE**

May 18, 2022

**COPYRIGHT**

© 2022 Baishideng Publishing Group Inc

**INSTRUCTIONS TO AUTHORS**

<https://www.wjgnet.com/bpg/gerinfo/204>

**GUIDELINES FOR ETHICS DOCUMENTS**

<https://www.wjgnet.com/bpg/gerinfo/287>

**GUIDELINES FOR NON-NATIVE SPEAKERS OF ENGLISH**

<https://www.wjgnet.com/bpg/gerinfo/240>

**PUBLICATION ETHICS**

<https://www.wjgnet.com/bpg/gerinfo/288>

**PUBLICATION MISCONDUCT**

<https://www.wjgnet.com/bpg/gerinfo/208>

**ARTICLE PROCESSING CHARGE**

<https://www.wjgnet.com/bpg/gerinfo/242>

**STEPS FOR SUBMITTING MANUSCRIPTS**

<https://www.wjgnet.com/bpg/gerinfo/239>

**ONLINE SUBMISSION**

<https://www.f6publishing.com>



## Prosthetic joint infection of the hip and knee due to *Mycobacterium* species: A systematic review

Asep Santoso, Krisna Yuarno Phatama, Sholahuddin Rhatomy, Nicolaas Cyrillus Budhiparama

**Specialty type:** Orthopedics

**Provenance and peer review:**

Unsolicited article; Externally peer reviewed.

**Peer-review model:** Single blind

**Peer-review report's scientific quality classification**

Grade A (Excellent): 0

Grade B (Very good): 0

Grade C (Good): C, C

Grade D (Fair): 0

Grade E (Poor): 0

**P-Reviewer:** Luo ZW, China

**Received:** July 4, 2021

**Peer-review started:** July 4, 2021

**First decision:** October 18, 2021

**Revised:** November 7, 2021

**Accepted:** April 21, 2022

**Article in press:** April 21, 2022

**Published online:** May 18, 2022



**Asep Santoso**, Department of Orthopaedic and Traumatology, Universitas Sebelas Maret, Surakarta and Prof. Dr. R. Soeharso Orthopaedic Hospital, Sukoharjo 57162, Indonesia

**Krisna Yuarno Phatama**, Department of Orthopaedic and Traumatology, Universitas Brawijaya, Saiful Anwar General Hospital, Malang 65112, Indonesia

**Sholahuddin Rhatomy**, Department of Orthopaedic and Traumatology, Universitas Gadjah Mada, Yogyakarta and Dr. Soeradji Tirtonegoro General Hospital, Klaten 57424, Indonesia

**Nicolaas Cyrillus Budhiparama**, Nicolaas Institute of Constructive Orthopaedic Research and Education Foundation at Medistra Hospital, Jakarta 12950, Indonesia

**Nicolaas Cyrillus Budhiparama**, Faculty of Medicine, Universitas Airlangga, Jawa Timur 60132, Indonesia

**Nicolaas Cyrillus Budhiparama**, Department of Orthopaedics, Leiden University Medical Center, Leiden 2333, Netherlands

**Corresponding author:** Nicolaas Cyrillus Budhiparama, MD, PhD, Professor, Nicolaas Institute of Constructive Orthopaedic Research and Education Foundation at Medistra Hospital, Jl. Jendral Gatot Subroto Kav. 59, Jakarta 12950, Indonesia. [n.c.budhiparama@gmail.com](mailto:n.c.budhiparama@gmail.com)

### Abstract

#### BACKGROUND

*Mycobacterium* species (*Mycobacterium* sp) is an emerging cause of hip and knee prosthetic joint infection (PJI), and different species of this organism may be responsible for the same.

#### AIM

To evaluate the profile of hip and knee *Mycobacterium* PJI cases as published in the past 30 years.

#### METHODS

A literature search was performed in PubMed using the MeSH terms "Prosthesis joint infection" AND "Mycobacterium" for studies with publication dates from January 1, 1990, to May 30, 2021. To avoid missing any study, another search was performed with the terms "Arthroplasty infection" AND "Mycobacterium" in the same period as the previous search. The Preferred Reporting Items for Systematic Reviews and Meta-Analyses chart was used to evaluate the included studies for further review. In total, 51 studies were included for further evaluation of the

cases, type of pathogen, and treatment of PJI caused by *Mycobacterium sp.*

## RESULTS

Seventeen identified *Mycobacterium sp* were reportedly responsible for hip/knee PJI in 115 hip/knee PJI cases, whereas in two cases there was no mention of any specific *Mycobacterium sp*. *Mycobacterium tuberculosis* (*M. tuberculosis*) was detected in 50/115 (43.3%) of the cases. Nontuberculous mycobacteria (NTM) included *M. fortuitum* (26/115, 22.6%), *M. abscessus* (10/115, 8.6%), *M. chelonae* (8/115, 6.9%), and *M. bovis* (8/115, 6.9%). Majority of the cases (82/114, 71.9%) had an onset of infection > 3 mo after the index surgery, while in 24.6% (28/114) the disease had an onset in ≤ 3 mo. Incidental intraoperative PJI diagnosis was made in 4 cases (3.5%). Overall, prosthesis removal was needed in 77.8% (84/108) of the cases to treat the infection. Overall infection rate was controlled in 88/102 (86.3%) patients with *Mycobacterium* PJI. Persistent infection occurred in 10/108 (9.8%) patients, while 4/108 (3.9%) patients died due to the infection.

## CONCLUSION

At least 17 *Mycobacterium sp* can be responsible for hip/knee PJI. Although *M. tuberculosis* is the most common causal pathogen, NTM should be considered as an emerging cause of hip/knee PJI.

**Key Words:** *Mycobacterium species*; Prosthetic joint infection; Hip; Knee; Systematic review

©The Author(s) 2022. Published by Baishideng Publishing Group Inc. All rights reserved.

**Core Tip:** Prosthetic joint infection (PJI) is a difficult complication after total hip/knee arthroplasty. *Mycobacterium species* (*Mycobacterium sp*) is one of the emerging causes of hip and knee PJI, and various species could be responsible for it. This study aimed to evaluate the profile of hip and knee *Mycobacterium* PJI cases published in the past 30 years. This study resulted the information regarding the distribution of *Mycobacterium sp* that related to PJI hip/knee. This paper also evaluated the disease course, treatment and outcome of *Mycobacterium* PJI.

**Citation:** Santoso A, Phatama KY, Rhatomy S, Budhiparama NC. Prosthetic joint infection of the hip and knee due to *Mycobacterium species*: A systematic review. *World J Orthop* 2022; 13(5): 503-514

**URL:** <https://www.wjgnet.com/2218-5836/full/v13/i5/503.htm>

**DOI:** <https://dx.doi.org/10.5312/wjo.v13.i5.503>

## INTRODUCTION

The incidence of prosthetic joint infection (PJI) has increased with an increase in the number of patients undergoing total joint arthroplasty, particularly hip and knee arthroplasties[1]. The cumulative incidence of PJI after total hip arthroplasty (THA) and total knee arthroplasty remains unclear; however, it is believed to range between 2.05% and 2.18%. The majority of PJI cases are caused by gram-positive cocci such as *Staphylococcus aureus* and coagulase-negative *Staphylococci* (60%); however, sometimes they can also be caused by gram-negative bacteria, such as *Mycobacteria* or fungi[2,3]. *Mycobacterial* infections account for approximately 2% of all PJI cases[4]. *Mycobacterium tuberculosis* (*M. tuberculosis*) is an infrequent cause of PJI, accounting for only 7 cases (0.3%) as reported during a 22-year period at one center[5]. However, in tuberculosis-endemic countries, patients undergoing joint arthroplasty with previous tuberculous septic arthritis are at an increased risk of developing *M. tuberculosis* complex PJI [1]. Some other *Mycobacteria* (rapidly growing *Mycobacteria*) are reported to grow rapidly, and they spread in various environments worldwide[4].

Appropriate management is mandatory to prevent complications that arise from PJI. Successful management of PJI is achieved by a combination of surgical intervention and appropriate medical therapeutic strategies to eradicate infection, reduce pain, restore function, and prevent prolonged antimicrobial therapy in patients[1,2,6]. The diagnosis of mycobacterial infections is often delayed due to the low index of suspicion, clinical and laboratory presentation that mimics bacterial infections, and low yield of smears and culture for acid-fast bacilli. Moreover, mycobacterial infections are often known to occur together with other bacteria, such as coinfection or superinfection[2,6]. Delayed diagnosis and prevention of PJI can lead to prolonged illness with various dangerous manifestations that can threaten the patient's life. Although *Mycobacteria* are not among the common causative agents of PJI, it is important to recognize and treat them differently from non-mycobacterial infections. The aim of this study was to identify and evaluate the profile of PJI cases due to mycobacterial infection in the hip and knee as published over the past 30 years.

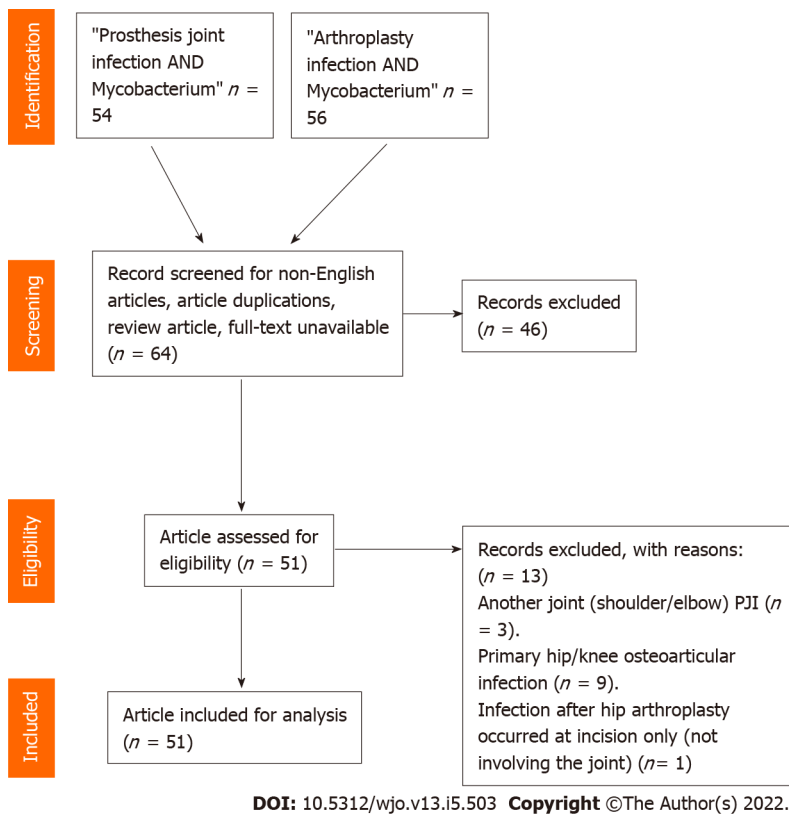
Table 1 Articles included in the systematic review

| No | Ref.                               | Joint involvement (No. of cases) | Pathogens  | Onset of disease (early: $\leq 3$ mo; late: $> 3$ mo) | Treatment  | Outcome                                  |
|----|------------------------------------|----------------------------------|--|---|--|--|
| 1  | Ribeiro <i>et al</i> [7], 2020     | Hip (1)                          | <i>M. tuberculosis</i>   | Early   | Removal of prosthesis                              | Controlled                               |
| 2  | Patel <i>et al</i> [8], 2019       | Hip (1)                          | <i>M. bovis</i>  | Late  | Removal of prosthesis                              | Controlled                               |
| 3  | Sixt <i>et al</i> [9], 2020        | Hip (1)                          | <i>M. avium</i>  | Late  | Removal of prosthesis                              | Controlled                               |
| 4  | Barry <i>et al</i> [10], 2019      | Knee (1)                         | <i>M. tuberculosis</i>   | Late  | Antimicrobials only                                | Controlled                               |
| 5  | Goldstein <i>et al</i> [11], 2019  | Hip (2), knee (4)                | <i>M. intracellulare</i> (1), <i>M. abscessus</i> (1), <i>M. fortuitum</i> (1), <i>M. goodii</i> (1), NA (2) | Early (1), late (4), NA (1)                           | Removal prosthesis (5), amputation (1)             | Controlled                               |
| 6  | Buser <i>et al</i> [12], 2019      | Hip (5), knee (4)                | <i>M. fortuitum</i> (7), <i>M. goodii</i> (2)  | Early (1), late (8)                                   | NA   | NA                                       |
| 7  | Spanyer <i>et al</i> [13], 2018    | Knee (1)                         | <i>M. abscessus</i>  | NA  | Removal of prosthesis                              | Controlled                               |
| 8  | Meyssonier <i>et al</i> [14], 2019 | Hip (9)                          | <i>M. tuberculosis</i> (9)   | Late (5), intraoperative (4)                          | Antimicrobials only (5), removal of prosthesis (4) | Controlled                               |
| 9  | Chang <i>et al</i> [15], 2018      | Hip (7), knee (6)                | <i>M. tuberculosis</i> (13), mixed infection (6)   | Early (2), late (11)                                  | Removal of prosthesis (11), debridement (2)        | Controlled (8), persistent (3), dead (2) |
| 10 | Metayer <i>et al</i> [16], 2018    | Hip (1)                          | <i>M. bovis</i>  | Late  | Removal of prosthesis                              | Controlled                               |
| 11 | Elzein <i>et al</i> [5], 2017      | Knee (1)                         | <i>M. tuberculosis</i>   | Late  | Removal of prosthesis                              | Controlled                               |
| 12 | Kim <i>et al</i> [17], 2017        | Knee (2)                         | <i>M. abscessus</i>  | Early (1), late (1)                                   | Removal of prosthesis (2)                          | Controlled                               |
| 13 | Henry <i>et al</i> [18], 2016      | Hip (1), knee (1)                | <i>M. abscessus</i>  | Late  | Removal of prosthesis (2)                          | Controlled                               |
| 14 | Jeong <i>et al</i> [19], 2012      | Knee (1)                         | <i>M. wolinskyi</i>  | NA  | Debridement  | NA                                       |
| 15 | Lee <i>et al</i> [20], 2012        | Knee (1)                         | <i>M. chelonae</i>   | Late  | Removal of prosthesis                              | Controlled                               |
| 16 | Wang <i>et al</i> [21], 2011       | Knee (1)                         | <i>M. abscessus</i> , <i>M. fortuitum</i>  | Early   | Removal of prosthesis                              | NA                                       |
| 17 | Ahmad <i>et al</i> [22], 2010      | Knee (1)                         | <i>M. goodii</i>   | Early   | Removal of prosthesis                              | Controlled                               |
| 18 | Gupta <i>et al</i> [23], 2009      | Hip (1)                          | <i>M. avium</i> complex  | Late  | Removal of prosthesis                              | Controlled                               |
| 19 | Porat <i>et al</i> [24], 2008      | Knee (2) bilateral               | <i>M. fortuitum</i>  | Late  | Antimicrobials only                                | Persistent                               |
| 20 | Reigstad <i>et al</i> [25], 2008   | Hip (1)                          | <i>M. bovis</i>  | Late  | Removal of prosthesis                              | Controlled                               |
| 21 | Brown <i>et al</i> [26], 2008      | Hip (1)                          | <i>M. tuberculosis</i> , <i>M. chelonae</i>  | Late  | Removal of prosthesis                              | Controlled                               |
| 22 | Cheung <i>et al</i> [27], 2008     | Knee (1)                         | <i>M. fortuitum</i>  | Early   | Removal of prosthesis                              | Controlled                               |
| 23 | Eid <i>et al</i> [28], 2007        | Knee (7), hip (1)                | <i>M. chelonae</i> (3), <i>M. abscessus</i> (2), <i>M. fortuitum</i> (3), <i>M. smegmatis</i> (1)            | Early (3), late (5)                                   | Removal of prosthesis                              | Controlled (7), persistent (1)           |
| 24 | Segal <i>et al</i> [29], 2007      | Hip (1)                          | <i>M. bovis</i>  | Late  | Removal of prosthesis                              | Controlled                               |
| 25 | Khater <i>et al</i> [30], 2007     | Knee (1)                         | <i>M. tuberculosis</i>   | Early   | Removal of prosthesis                              | Controlled                               |
| 26 | Pulcini <i>et al</i> [31],         | Hip (1)                          | <i>M. wolinskyi</i>  | Late  | Removal of prosthesis                              | Controlled                               |

|    |                                    |                    |  |                     |   |  |
|----|------------------------------------|--------------------|--|---------------------|---|--|
|    | 2006                               |                    |  |                     |   |  |
| 27 | Neuberger <i>et al</i> [32], 2006  | Knee (1)           | <i>M. kansasii</i>   | Late                | Removal of prosthesis   | Controlled                               |
| 28 | Wong <i>et al</i> [33], 2005       | Hip (1)            | <i>M. farcinogenes</i>   | Late                | Removal of prosthesis   | Controlled                               |
| 29 | Yim <i>et al</i> [34], 2004        | Hip (10)           | <i>M. xenopi</i>   | Late                | Removal of prosthesis   | Controlled                               |
| 30 | Spinner <i>et al</i> [35], 1996    | Knee (1)           | <i>M. tuberculosis</i>   | Early               | Debridement   | Controlled                               |
| 31 | Pring <i>et al</i> [36], 1996      | Knee (1)           | <i>M. chelonae</i>   | Early               | Removal of prosthesis   | Controlled                               |
| 32 | Kreder <i>et al</i> [37], 1996     | Hip (1)            | <i>M. tuberculosis</i>   | Late                | Removal of prosthesis   | Controlled                               |
| 33 | Lusk <i>et al</i> [38], 1995       | Knee (1)           | <i>M. tuberculosis</i>   | Late                | Removal of prosthesis   | Dead                                     |
| 34 | Tokumoto <i>et al</i> [39], 1995   | Knee (2), hip (1)  | <i>M. tuberculosis</i>   | Late                | Removal of prosthesis (3)   | Controlled                               |
| 35 | Ueng <i>et al</i> [40], 1995       | Hip (2)            | <i>M. tuberculosis</i>   | Late                | Removal of prosthesis (2)   | Controlled                               |
| 36 | Heathcock <i>et al</i> [41], 1994  | Hip (1)            | <i>M. chelonae</i>   | Late                | Removal of prosthesis   | Controlled                               |
| 37 | Leach <i>et al</i> [42], 1993      | Hip (1)            | <i>M. bovis</i>  | Late                | Removal of prosthesis   | Controlled                               |
| 38 | Guerra <i>et al</i> [43], 1998     | Hip (1)            | <i>M. bovis</i>  | Late                | Removal of prosthesis   | Controlled                               |
| 39 | LaBombardi <i>et al</i> [44], 2005 | Knee (1)           | <i>M. thermoresistibile</i>  | Early               | Removal of prosthesis   | Controlled                               |
| 40 | Saccante [45], 2006                | Knee (1)           | <i>M. fortuitum</i>  | Early               | Removal of prosthesis   | Controlled                               |
| 41 | Wang <i>et al</i> [46], 2007       | Knee (1)           | <i>M. tuberculosis</i>   | Late                | Debridement   | Dead                                     |
| 42 | Klein <i>et al</i> [47], 2012      | Knee (1)           | <i>M. tuberculosis</i>   | Late                | Removal of prosthesis   | Controlled                               |
| 43 | Srivastava <i>et al</i> [48], 2011 | Hip (1)            | <i>M. bovis</i>  | Late                | Removal of prosthesis   | Controlled                               |
| 44 | Rispler <i>et al</i> [49], 2015    | Knee (1)           | <i>M. bovis</i>  | Late                | Debridement   | Controlled                               |
| 45 | Vutescu and Koenig [50], 2017      | Knee (1)           | <i>M. cosmeticum</i>   | Late                | Removal of prosthesis   | Controlled                               |
| 46 | Jitmuang <i>et al</i> [4], 2017    | Knee (10), hip (1) | <i>M. fortuitum</i> (9), <i>M. abscessus</i> (1), <i>M. peregrinum</i> (1) (mixed cases 2) | Early (9), late (2) | Removal of prosthesis (10), debridement (1)                         | Controlled (6), persistent (1), NA (4)   |
| 47 | Mannelli <i>et al</i> [51], 2018   | Hip (1)            | <i>M. chelonae</i>   | Late                | Antimicrobials only   | Persistent                               |
| 48 | Uhel <i>et al</i> [52], 2019       | Hip (6), knee (6)  | <i>M. tuberculosis</i>   | Late (12)           | Antimicrobials only (4), removal of prosthesis (5), debridement (3) | Controlled (8), persistent (3), dead (1) |
| 49 | Rodari <i>et al</i> [53], 2020     | Hip (1)            | <i>M. xenopi</i>   | Late                | Removal prosthesis  | Controlled                               |
| 50 | Congia <i>et al</i> [54], 2020     | Knee (1)           | <i>M. tuberculosis</i>   | Early               | Debridement   | Controlled                               |
| 51 | Fix <i>et al</i> [55], 2020        | Hip (1)            | <i>M. fortuitum</i>  | Early               | Removal prosthesis  | Controlled                               |

Removal of prosthesis: With or without revision. *M.*: *Mycobacteria*; NA: Not available.





**Figure 1** Flow diagram of the study. PJI: Prosthetic joint infection.

### Search strategy

A literature search was performed using MeSH terms on PubMed from January 1, 1990, to May 30, 2021. The following two search scenarios were used accordingly: "Prosthesis joint infection AND *Mycobacterium*" and "Arthroplasty infection AND *Mycobacterium*". The articles were screened based on the Preferred Reporting Items for Systematic Reviews and Meta-Analyses statement.

### Inclusion and exclusion criteria

The following inclusion criteria were used in our systematic review: (1) Clinical studies; (2) All levels of evidence; and (3) PJI of the hip or knee due to any *Mycobacterium species* (*Mycobacterium sp*). Studies were excluded if they met any of the following criteria: (1) Non-English articles; (2) PJI not involving the hip or knee joint; (3) Primary *Mycobacterium* hip/knee osteoarticular infection prior to arthroplasty; (4) Articles published in abstract form only; (5) Review articles; and (6) Technique articles.

### Data collection/extraction

Three authors (Santoso A, Phatama KY, and Rhatomy S) independently screened the titles and abstracts of the included studies. The first search with the terms "Prosthetic joint infection AND *Mycobacterium*" revealed 54 records. Of these, 6 records were excluded for not being in English, 5 for presenting primary osteoarticular hip/knee infection, 2 for presenting shoulder/elbow PJI, 1 for presenting wound infection after THA without involvement of the joint, and 3 for unavailability of the full-text articles. The remaining 37 records were included in the further analysis. The second search method was performed with the words "Arthroplasty infection AND *Mycobacterium*", which revealed 56 records. Of these, 33 records were excluded for duplicating previous search results, 4 for presenting primary hip/knee osteoarticular infection, 1 for presenting shoulder PJI, 1 for being a non-English article, 2 for being review articles, and 1 for unavailability of the full-text article. Thus, 14 records were finally included from the second search in the analysis. Considering the 37 records from the first search and 14 from the second search, a total of 51 records were included in the final analysis (Figure 1). The analysis included type of study, demographics, number of patients, hip or knee PJI cases, *Mycobacterium sp* strain, treatment, and outcomes of the mycobacterial PJI cases (Table 1). Furthermore, we performed a descriptive comparison between PJI caused by *M. tuberculosis* ( $n = 43$ ) and nontuberculous mycobacteria (NTM) ( $n = 63$ ). This comparative evaluation excluded all cases of mixed infections of *M. tuberculosis* and NTM ( $n = 1$ ), NTM and *Staphylococcus species* (*Staphylococcus sp*) ( $n = 2$ ), and *M. tuberculosis* and *Staphylococcus sp* ( $n = 6$ ). Two cases with no data 5 regarding the specific species of *Mycobacteria* were also excluded at this stage (Table 2). Comparative analysis of categorical data was performed using the chi-square test.

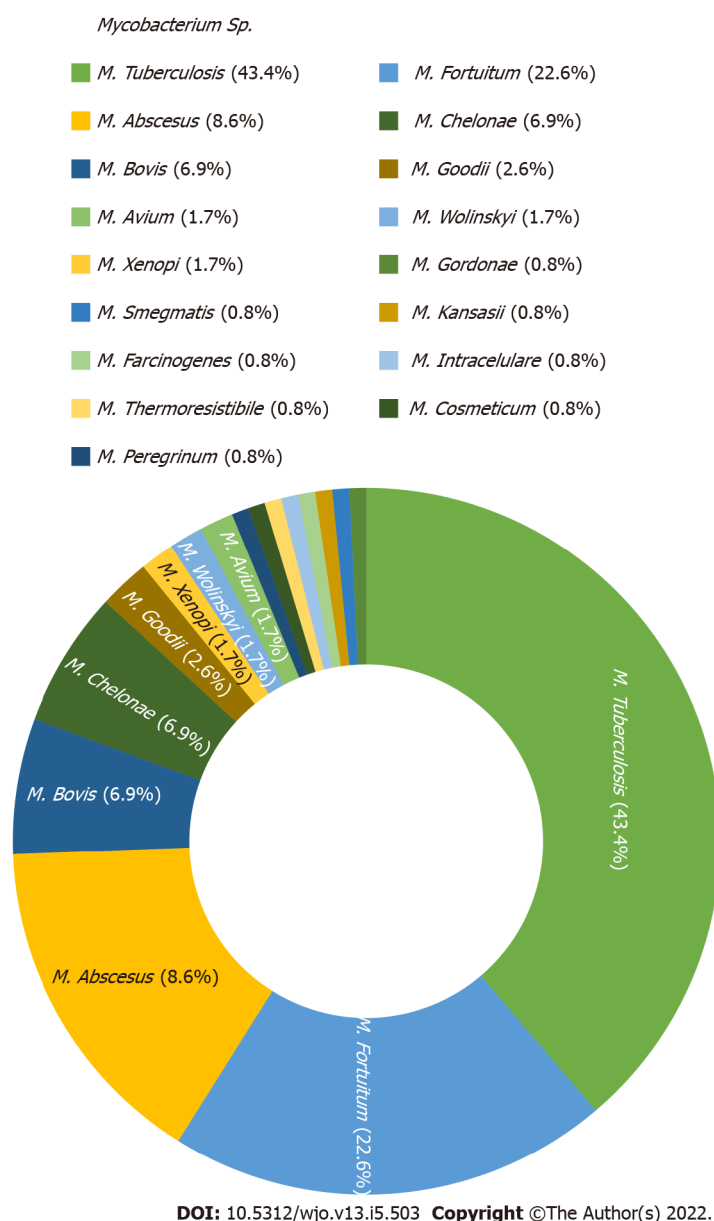
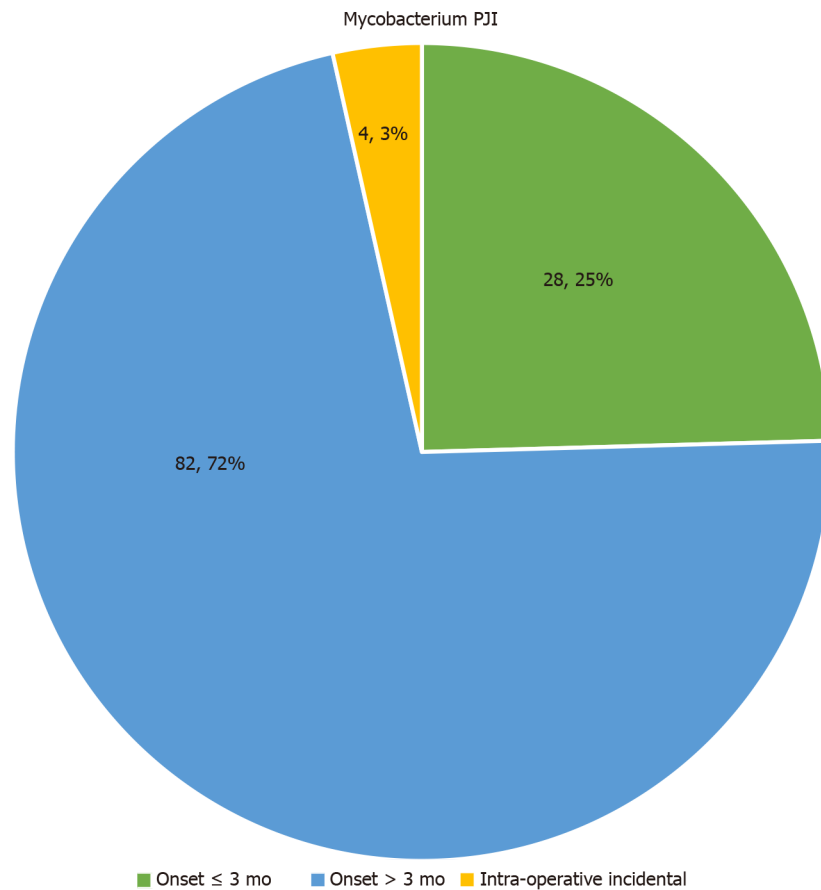
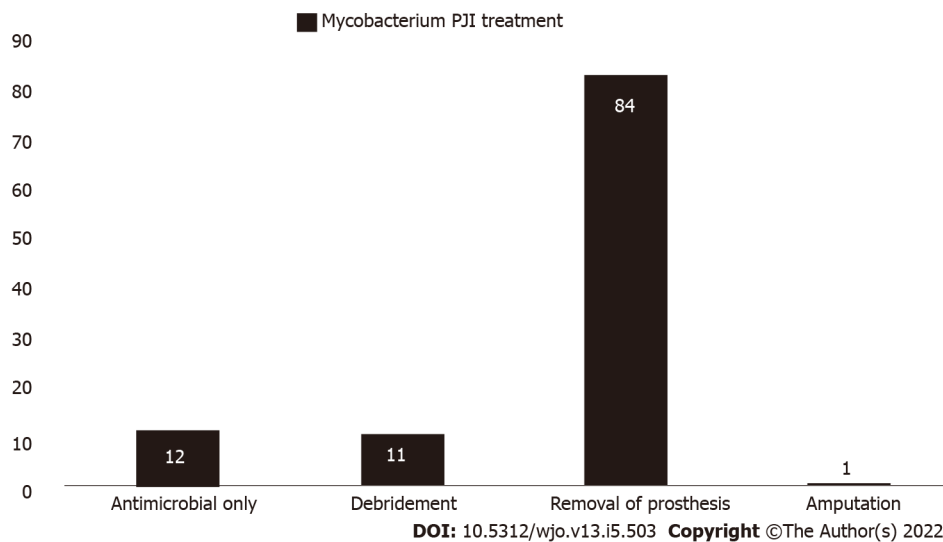


Figure 2 Distribution of *Mycobacterium* strains as the cause of hip/knee prosthetic joint infection ( $n = 115$ ). *M.*: *Mycobacteria*.

## RESULTS

Of the 51 included studies, 40 (80.3%) were case reports and 11 (19.6%) studies were of the retrospective series type. There were studies from America (27/51, 52.9%), Europe (12/51, 23.5%), and Asia-Pacific (12/51, 23.5%) included in the analysis. In total, 117 *Mycobacterium* hip/knee PJI cases were reported across 51 studies. There were 46.15% (54/117) cases of knee PJI and 53.85% (63/117) of hip PJI, and the age range of the patients was 17-101 years. In total, 17 types of *Mycobacteria* sp recorded in this review were responsible for PJI in 115 hip/knee PJI cases, whereas in 2 cases there was no mention of any specific *Mycobacterium* sp. *M. tuberculosis* was detected in 50/115 (43.3%) of the cases. The NTM included *M. fortuitum* (26/115, 22.6%), *M. abscessus* (10/115, 8.6%), *M. chelonae* (8/115, 6.9%), and *M. bovis* (8/115, 6.9%). Other strains with a smaller number of cases were also isolated as the causes of hip/knee PJI (Figure 2). Mixed infections in mycobacterial PJI cases were noted in 8 cases caused by *M. abscessus* and *M. fortuitum* (all NTM) in 1 case and by *M. tuberculosis* and *M. chelonae* in another. The other six cases showed co infection with *Staphylococcus* sp. The majority of the cases (82/114, 71.9%) showed an onset of infection > 3 mo after the index surgery, whereas 24.6% (28/114) of patients showed disease onset in ≤ 3 mo. Incidental intraoperative PJI diagnosis was reported in 4 cases (3.5%) (Figure 3A), and it was not specified in 9 cases. Removal of the prosthesis (with or without revision) was needed in 77.8% (84/108) of cases to treat the infection (Figure 3B). While debridement was needed in 11/108 (10.2%) cases, antimicrobial therapy was needed in 12/108 (11.1%), and amputation was performed in 1 case. The overall infection rate was controlled in 88/102 (86.3%) mycobacterial PJI cases. Persistent infection occurred in 10/102 (9.8%) patients, and 4/102 (3.9%) patients died due to the infection (Figure 4).

**A****B**

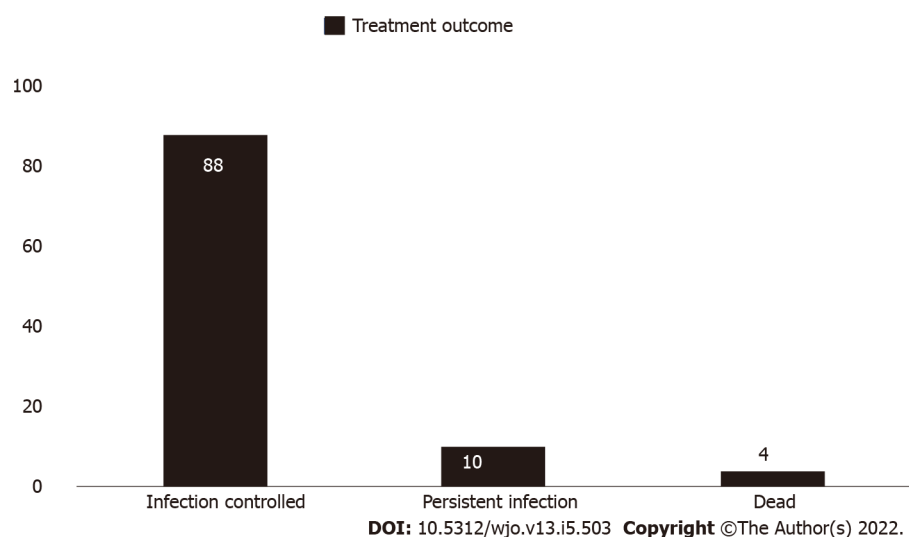
**Figure 3 Distribution of overall *Mycobacterium* prosthetic joint infection cases.** A: By onset of infection after index surgery ( $n = 114$ ); B: By treatment ( $n = 108$ ). PJI: Prosthetic joint infection.

Comparative analysis showed no difference in the rate of hip or knee involvement in PJI with *M. tuberculosis* or NTM ( $P > 0.05$ ). Both *tuberculosis* and *nontuberculosis* PJI cases predominantly showed disease onset of  $> 3$  mo (79.1% and 63.3%, respectively). However, *nontuberculosis* PJI cases showed a higher rate of early onset ( $< 3$  mo) of disease than those cases with *tuberculosis* PJI (36.7% *vs* 11.6%). Removal of the prosthesis was needed in more cases of *nontuberculosis* PJI than in cases of *tuberculosis* PJI (88.9% *vs* 58.1%). The infection control rates were comparable between the *tuberculosis* and *nontuberculosis* PJI cases (81.4% and 91.7%, respectively) (Table 2).

**Table 2 Descriptive comparison between tuberculous and nontuberculous *Mycobacteria* prosthetic joint infection cases (excluding mixed-infection cases)**

|                                      | Tuberculous PJI (n = 43) | Nontuberculous PJI (n = 63) | P value |
|--------------------------------------|--------------------------|-----------------------------|---------|
| Joint involvement                    |                          |                             |         |
| Hip                                  | 22/43 (55.1%)            | 22/63 (34.9%)               | 0.096   |
| Knee                                 | 21/43 (44.9%)            | 41/63 (65.1%)               |         |
| Onset of disease after index surgery |                          |                             |         |
| ≤ 3 mo                               | 5/43 (11.6%)             | 22/60 (36.7%)               | 0.002   |
| > 3 mo                               | 34/43 (79.1%)            | 38/60 (63.3%)               |         |
| Intraoperative                       | 4/43 (9.3%)              | 0                           | 0.002   |
| NA                                   | 0                        | 3                           |         |
| Treatment                            |                          |                             |         |
| Antimicrobial therapy only           | 10/43 (23.3%)            | 2/54 (3.7%)                 | 0.002   |
| Debridement                          | 8/43 (18.6%)             | 3/54 (5.5%)                 |         |
| Removal of prosthesis                | 25/43 (58.1%)            | 48/54 (88.9%)               | 0.092   |
| Amputation                           | 0                        | 1/54 (1.8%)                 |         |
| NA                                   | 0                        | 9                           |         |
| Outcome                              |                          |                             |         |
| Infection controlled                 | 35/43 (81.4%)            | 44/48 (91.7%)               | 0.092   |
| Persistent infection                 | 4/43 (9.3%)              | 4/48 (8.3%)                 |         |
| Dead                                 | 4/43 (9.3%)              | 0                           |         |
| NA                                   | 0                        | 15                          |         |

$P < 0.05$ : Significant. NA: Data not available; PJI: Prosthetic joint infection.

**Figure 4 Distribution of overall final outcome of *Mycobacterium* prosthetic joint infection treatments (n = 102).**

## DISCUSSION

More than 150 *Mycobacterium* *sp* have been officially recognized until now, in literature which consist of tuberculous mycobacteria and NTM[56]. One of the purposes of this systematic review was to evaluate the various *Mycobacteria* *sp* that can cause hip/knee PJI, and at least 17 *Mycobacterium* *sp* were identified accordingly. They comprised of *M. tuberculosis* and 16 NTM. The NTM was further divided into rapidly

growing and slowly growing mycobacteria[56]. Several studies have reported rapidly growing NTM as the cause of early hip/knee PJI[4,17,18,28]. Early PJI ( $\leq 3$  mo) was noted in 36% of the NTM cases in this review, which was higher than that in tuberculous PJI cases (11%). The rapidly growing NTM hence needs to be considered as a differential diagnosis in cases of early hip/knee PJI. The diagnosis of *Mycobacterium* PJI is sometimes delayed, leading to delays in appropriate management[6,8]. Several treatment options were noted in this review. Removal of the prosthesis was the most commonly performed procedure, which was required in  $> 75\%$  of cases. Additionally, a greater number of NTM PJI cases required removal of the prosthesis compared to the tuberculous PJI cases (88.9% *vs* 58.1%). There were no data regarding specific procedures, such as revision surgery, resection arthroplasty, or arthrodesis after the prosthesis removal procedure due to incomplete data in every published article. Another interesting finding was that conservative treatment with only antimicrobial therapy successfully controlled tuberculous hip/knee PJI in approximately 23% of the cases. This indicates that early recognition of sensitive antimicrobial agents is highly important in treating *Mycobacterium* PJI. However, the isolation of *Mycobacterium* with standard culture procedures may be sometimes difficult and more advanced techniques with gene sequencing are hence needed to isolate the *Mycobacterium sp* [19]. This could be a hindrance, especially in developing countries. Based on the pooled case analyses reported from the studies included in this systematic review, the outcome of the treatment of *Mycobacterium* PJI reportedly had an infection control rate of approximately 86%. Among the mycobacterial PJI cases, the infection control rate of nontuberculous PJI was comparable to that of tuberculous PJI (91.7% *vs* 81.4%,  $P = 0.092$ ). This was comparable to that of PJI hip/knee associated with non-mycobacterial pathogens or even a negative-culture PJI that showed an infection control rate of 70%-90% [3,57]. *Mycobacterium* PJI has also been correlated with culture-negative PJI. A study by Palan *et al* [58] reported that fungi and mycobacteria are responsible for over 85% of negative-culture PJI. Arthroplasty surgeons need to consider *Mycobacterium* as the causal pathogen of PJI when negative culture results are obtained in clinical practice. Further diagnosis using histopathology or polymerase chain reaction assay is needed accordingly.

This study had a few limitations. First, the systematic review only included studies indexed in PubMed; therefore, some other studies may have been missed in this review. However, the wider search period (30 years) of this systematic review ensured the inclusion of several important studies from literature. Second, the studies included in this systematic review were mostly retrospective case reports or case series, which had their own limitations. It is difficult to obtain a higher level of evidence from relatively rare cases, such as those of *Mycobacterium* PJI. Third, some bias of treatment and outcome evaluation may have occurred, as every author may have used a different standard. This study also could not suggest any advisable best treatment for *Mycobacterium* PJI due to the lack of available data for evaluation. Despite these limitations, we believe that this systematic review could provide some insights into the profile of *Mycobacterium* hip/knee PJI, including its treatment options and outcomes.

## CONCLUSION

At least 17 *Mycobacterium sp* can be responsible for PJI of the hip and knee. Although *M. tuberculosis* is the most common causal pathogen, NTM should be considered as an emerging cause of hip/knee PJI.

## ARTICLE HIGHLIGHTS

### Research background

There were many species of *Mycobacterium* that may be associated as a causal pathogens for prosthetic joint infection (PJI) of the hip and knee. However, no available literature which provides compilation data regarding this issue.

### Research motivation

To do compilation data of *Mycobacterium species* (*Mycobacterium sp*) which may cause hip and knee PJI.

### Research objectives

This study aimed to evaluate PJI associated with *Mycobacterium sp*.

### Research methods

Systematic review of PubMed article.

### Research results

Among reviewed 51 articles. We found several species of *Mycobacterium* may be associated with hip and knee PJI.

## Research conclusions

We found at least 17 species of *Mycobacterium* could be responsible for hip and knee PJI.

## Research perspectives

This study may open the knowledge of various species of *Mycobacterium* that can be associated with hip and knee PJI.

## ACKNOWLEDGEMENTS

We highly thank Denny Adriansyah, MD for his assistance in data collection and analysis.

## FOOTNOTES

**Author contributions:** Santoso A, Phatama KY, and Rhatomy S contributed to the data collection and analysis; Santoso A and Phatama KY wrote the paper; Budhiparama NC contributed to the study design, analysis and finalization.

**Conflict-of-interest statement:** All of the author have none to disclose.

**PRISMA 2009 Checklist statement:** This study has been presented following the PRISMA 2019 Checklist.

**Open-Access:** This article is an open-access article that was selected by an in-house editor and fully peer-reviewed by external reviewers. It is distributed in accordance with the Creative Commons Attribution NonCommercial (CC BY-NC 4.0) license, which permits others to distribute, remix, adapt, build upon this work non-commercially, and license their derivative works on different terms, provided the original work is properly cited and the use is non-commercial. See: <https://creativecommons.org/licenses/by-nc/4.0/>

**Country/Territory of origin:** Indonesia

**ORCID number:** Asep Santoso 0000-0002-8170-4055; Krisna Yuarno Phatama 0000-0003-1050-7561; Sholahuddin Rhatomy 0000-0002-5512-6706; Nicolaas Cyrillus Budhiparama 0000-0002-0801-7400.

**S-Editor:** Wang JJ

**L-Editor:** A

**P-Editor:** Wang JJ

## REFERENCES

- 1 Tande AJ, Patel R. Prosthetic joint infection. *Clin Microbiol Rev* 2014; **27**: 302-345 [PMID: 24696437 DOI: 10.1128/CMR.00111-13]
- 2 Aggarwal VK, Rasouli MR, Parvizi J. Periprosthetic joint infection: Current concept. *Indian J Orthop* 2013; **47**: 10-17 [PMID: 23531512 DOI: 10.4103/0019-5413.106884]
- 3 Santoso A, Park KS, Shin YR, Yang HY, Choi IS, Yoon TR. Two-stage revision for periprosthetic joint infection of the hip: Culture-negative versus culture-positive infection. *J Orthop* 2018; **15**: 391-395 [PMID: 29881161 DOI: 10.1016/j.jor.2018.03.002]
- 4 Jitmuang A, Yuenyongviwat V, Charoencholvanich K, Chayakulkeeree M. Rapidly-growing mycobacterial infection: a recognized cause of early-onset prosthetic joint infection. *BMC Infect Dis* 2017; **17**: 802 [PMID: 29281992 DOI: 10.1186/s12879-017-2926-3]
- 5 Elzein FE, Haris M, Alolayan SS, Al Sherbini N. Total knee prosthesis infected with *Mycobacterium tuberculosis*. *BMJ Case Rep* 2017; **2017** [PMID: 28883009 DOI: 10.1136/ber-2017-220596]
- 6 Osmon DR, Berbari EF, Berendt AR, Lew D, Zimmerli W, Steckelberg JM, Rao N, Hanssen A, Wilson WR; Infectious Diseases Society of America. Executive summary: diagnosis and management of prosthetic joint infection: clinical practice guidelines by the Infectious Diseases Society of America. *Clin Infect Dis* 2013; **56**: 1-10 [PMID: 23230301 DOI: 10.1093/cid/cis966]
- 7 Ribeiro AF, Inacio Oliveira M, Jordão P, Tavares D, Varandas L, Gouveia C. Mycobacterium tuberculosis prosthesis joint infection. *Pediatr Int* 2020; **62**: 97-99 [PMID: 31916331 DOI: 10.1111/ped.14037]
- 8 Patel A, Elzweig J. *Mycobacterium bovis* prosthetic joint infection following intravesical instillation of BCG for bladder cancer. *BMJ Case Rep* 2019; **12** [PMID: 31857290 DOI: 10.1136/ber-2019-231830]
- 9 Sixt T, Bador J, Amoureux L, Piroth L, Blot M. Prosthetic joint infection caused by *Mycobacterium avium* complex. *QJM* 2020; **113**: 278-279 [PMID: 31764970 DOI: 10.1093/qjmed/hcz306]
- 10 Barry M, Akkielah L, Askar MA, Bin Nasser AS. Miliary tuberculosis with delayed-onset total knee arthroplasty *Mycobacteria tuberculosis* infection successfully treated with medical therapy alone: A case report and literature review.



- Knee* 2019; **26**: 1152-1158 [PMID: 31427242 DOI: 10.1016/j.knee.2019.07.010]
- 11 **Goldstein N**, St Clair JB, Kasperbauer SH, Daley CL, Lindeque B. Nontuberculous Mycobacterial Musculoskeletal Infection Cases from a Tertiary Referral Center, Colorado, USA. *Emerg Infect Dis* 2019; **25**: 1075-1083 [PMID: 31107224 DOI: 10.3201/eid2406.181041]
  - 12 **Buser GL**, Laidler MR, Cassidy PM, Moulton-Meissner H, Beldavs ZG, Cieslak PR. Outbreak of Nontuberculous Mycobacteria Joint Prosthesis Infections, Oregon, USA, 2010-2016. *Emerg Infect Dis* 2019; **25**: 849-855 [PMID: 31002056 DOI: 10.3201/eid2505.181687]
  - 13 **Spanyer JM**, Foster S, Thum-DiCesare JA, Kwon YM, Burke DW, Nelson SB. Mycobacterium abscessus: A Rare Cause of Periprosthetic Knee Joint Infection. *Am J Orthop (Belle Mead NJ)* 2018; **47** [PMID: 30296310 DOI: 10.12788/ajo.2018.0077]
  - 14 **Meyssonier V**, Zeller V, Malbos S, Heym B, Lhotellier L, Desplaces N, Marmor S, Ziza JM. Prosthetic joint infections due to Mycobacterium tuberculosis: A retrospective study. *Joint Bone Spine* 2019; **86**: 239-243 [PMID: 30266444 DOI: 10.1016/j.jbspin.2018.09.008]
  - 15 **Chang CH**, Hu CC, Chang Y, Hsieh PH, Shih HN, Ueng SW. Two-stage revision arthroplasty for Mycobacterium Tuberculosis periprosthetic joint infection: An outcome analysis. *PLoS One* 2018; **13**: e0203585 [PMID: 30192830 DOI: 10.1371/journal.pone.0203585]
  - 16 **Metayer B**, Menu P, Khatchatourian L, Preuss P, Dauty M, Fouasson-Chailloux A. Prosthetic joint infection with pseudo-tumoral aspect due to Mycobacterium bovis infection after Bacillus-Calmette-Guerin therapy. *Ann Phys Rehabil Med* 2018; **61**: 62-64 [PMID: 28890342 DOI: 10.1016/j.rehab.2017.08.001]
  - 17 **Kim M**, Ha CW, Jang JW, Park YB. Rapidly growing non-tuberculous mycobacteria infection of prosthetic knee joints: A report of two cases. *Knee* 2017; **24**: 869-875 [PMID: 28551202 DOI: 10.1016/j.knee.2017.04.015]
  - 18 **Henry MW**, Miller AO, Kahn B, Windsor RE, Brause BD. Prosthetic joint infections secondary to rapidly growing mycobacteria: Two case reports and a review of the literature. *Infect Dis (Lond)* 2016; **48**: 453-460 [PMID: 27030918 DOI: 10.3109/23744235.2016.1142673]
  - 19 **Jeong JH**, Seo YH, Kim KH, Ahn JY, Park PH, Park YK. Mycobacterium wolinskyi infection confirmed by rpoB gene sequencing. *J Clin Lab Anal* 2012; **26**: 325-327 [PMID: 23001976 DOI: 10.1002/jcla.21526]
  - 20 **Lee RP**, Cheung KW, Chiu KH, Tsang ML. Mycobacterium chelonae infection after total knee arthroplasty: a case report. *J Orthop Surg (Hong Kong)* 2012; **20**: 134-136 [PMID: 22535831 DOI: 10.1177/230949901202000130]
  - 21 **Wang SX**, Yang CJ, Chen YC, Lay CJ, Tsai CC. Septic arthritis caused by Mycobacterium fortuitum and Mycobacterium abscessus in a prosthetic knee joint: case report and review of literature. *Intern Med* 2011; **50**: 2227-2232 [PMID: 21963746 DOI: 10.2169/internalmedicine.50.5610]
  - 22 **Ahmad S**, Khakoo RA. Left knee prosthesis-related Mycobacterium goodii infection. *Int J Infect Dis* 2010; **14**: e1115-e1116 [PMID: 21071255 DOI: 10.1016/j.ijid.2010.02.2245]
  - 23 **Gupta A**, Clauss H. Prosthetic joint infection with Mycobacterium avium complex in a solid organ transplant recipient. *Transpl Infect Dis* 2009; **11**: 537-540 [PMID: 19656344 DOI: 10.1111/j.1399-3062.2009.00433.x]
  - 24 **Porat MD**, Austin MS. Bilateral knee periprosthetic infection with Mycobacterium fortuitum. *J Arthroplasty* 2008; **23**: 787-789 [PMID: 18534520 DOI: 10.1016/j.arth.2007.07.010]
  - 25 **Reigstad O**, Siewers P. A total hip replacement infected with mycobacterium bovis after intravesicular treatment with Bacille-Calmette-Guérin for bladder cancer. *J Bone Joint Surg Br* 2008; **90**: 225-227 [PMID: 18256093 DOI: 10.1302/0301-620X.90B2.20038]
  - 26 **Brown A**, Grubbs P, Mongey AB. Infection of total hip prosthesis by Mycobacterium tuberculosis and Mycobacterium chelonae in a patient with rheumatoid arthritis. *Clin Rheumatol* 2008; **27**: 543-545 [PMID: 18034202 DOI: 10.1007/s10067-007-0788-6]
  - 27 **Cheung I**, Wilson A. Mycobacterium fortuitum infection following total knee arthroplasty: a case report and literature review. *Knee* 2008; **15**: 61-63 [PMID: 17869520 DOI: 10.1016/j.knee.2007.08.007]
  - 28 **Eid AJ**, Berbari EF, Sia IG, Wengenack NL, Osmon DR, Razonable RR. Prosthetic joint infection due to rapidly growing mycobacteria: report of 8 cases and review of the literature. *Clin Infect Dis* 2007; **45**: 687-694 [PMID: 17712751 DOI: 10.1086/520982]
  - 29 **Segal A**, Krauss ES. Infected total hip arthroplasty after intravesical bacillus Calmette-Guérin therapy. *J Arthroplasty* 2007; **22**: 759-762 [PMID: 17689788 DOI: 10.1016/j.arth.2006.07.010]
  - 30 **Khater FJ**, Samnani IQ, Mehta JB, Moorman JP, Myers JW. Prosthetic joint infection by Mycobacterium tuberculosis: an unusual case report with literature review. *South Med J* 2007; **100**: 66-69 [PMID: 17269530 DOI: 10.1097/01.smj.0000232972.50186.4c]
  - 31 **Pulcini C**, Vandenbussche E, Podglajen I, Sougakoff W, Truffot-Pernot C, Buu-Hoi A, Varon E, Mainardi JL. Hip prosthesis infection due to Mycobacterium wolinskyi. *J Clin Microbiol* 2006; **44**: 3463-3464 [PMID: 16954303 DOI: 10.1128/JCM.02685-05]
  - 32 **Neuberger A**, Sprecher H, Oren I. Septic arthritis caused by Mycobacterium kansasii in a prosthetic knee joint. *J Clin Microbiol* 2006; **44**: 2648-2649 [PMID: 16825405 DOI: 10.1128/JCM.00087-06]
  - 33 **Wong TC**, Chan WF, Tsang WL, Yeung SH, Ip FK. Mycobacterium farcinogenes infection after total hip arthroplasty. *J Arthroplasty* 2005; **20**: 684-687 [PMID: 16310009 DOI: 10.1016/j.arth.2005.03.001]
  - 34 **Yim K**, Nazeer SH, Kiska D, Rose FB, Brown D, Cynamon MH. Recurrent Mycobacterium xenopi infection in a patient with rheumatoid arthritis receiving etanercept. *Scand J Infect Dis* 2004; **36**: 150-154 [PMID: 15061673 DOI: 10.1080/00365540310017474]
  - 35 **Spinner RJ**, Sexton DJ, Goldner RD, Levin LS. Periprosthetic infections due to Mycobacterium tuberculosis in patients with no prior history of tuberculosis. *J Arthroplasty* 1996; **11**: 217-222 [PMID: 8648322 DOI: 10.1016/s0883-5403(05)80023-3]
  - 36 **Pring M**, Eckhoff DG. Mycobacterium chelonae infection following a total knee arthroplasty. *J Arthroplasty* 1996; **11**: 115-116 [PMID: 8676110 DOI: 10.1016/s0883-5403(96)80170-7]
  - 37 **Kreder HJ**, Davey JR. Total hip arthroplasty complicated by tuberculous infection. *J Arthroplasty* 1996; **11**: 111-114

- [PMID: 8676109 DOI: 10.1016/s0883-5403(96)80169-0]
- 38 **Lusk RH**, Wienke EC, Milligan TW, Albus TE. Tuberculous and foreign-body granulomatous reactions involving a total knee prosthesis. *Arthritis Rheum* 1995; **38**: 1325-1327 [PMID: 7575728 DOI: 10.1002/art.1780380921]
  - 39 **Tokumoto JI**, Follansbee SE, Jacobs RA. Prosthetic joint infection due to *Mycobacterium tuberculosis*: report of three cases. *Clin Infect Dis* 1995; **21**: 134-136 [PMID: 7578722 DOI: 10.1093/clinids/21.1.134]
  - 40 **Ueng WN**, Shih CH, Hseuh S. Pulmonary tuberculosis as a source of infection after total hip arthroplasty. A report of two cases. *Int Orthop* 1995; **19**: 55-59 [PMID: 7768660 DOI: 10.1007/BF00184916]
  - 41 **Heathcock R**, Dave J, Yates MD. *Mycobacterium chelonae* hip infection. *J Infect* 1994; **28**: 104-105 [PMID: 8163823 DOI: 10.1016/s0163-4453(94)94533-0]
  - 42 **Leach WJ**, Halpin DS. *Mycobacterium bovis* infection of a total hip arthroplasty: a case report. *J Bone Joint Surg Br* 1993; **75**: 661-662 [PMID: 8331128 DOI: 10.1302/0301-620X.75B4.8331128]
  - 43 **Guerra CE**, Betts RF, O'Keefe RJ, Shilling JW. *Mycobacterium bovis* osteomyelitis involving a hip arthroplasty after intravesicular bacille Calmette-Guérin for bladder cancer. *Clin Infect Dis* 1998; **27**: 639-640 [PMID: 9770167 DOI: 10.1086/514714]
  - 44 **LaBombardi VJ**, Shastry L, Tischler H. *Mycobacterium thermoresistibile* infection following knee-replacement surgery. *J Clin Microbiol* 2005; **43**: 5393-5394 [PMID: 16208028 DOI: 10.1128/JCM.43.10.5393-5394.2005]
  - 45 **Saccante M**. *Mycobacterium fortuitum* group periprosthetic joint infection. *Scand J Infect Dis* 2006; **38**: 737-739 [PMID: 16857632 DOI: 10.1080/00365540500504133]
  - 46 **Wang PH**, Shih KS, Tsai CC, Wang HC. Pulmonary tuberculosis with delayed tuberculosis infection of total knee arthroplasty. *J Formos Med Assoc* 2007; **106**: 82-85 [PMID: 17282976 DOI: 10.1016/S0929-6646(09)60221-7]
  - 47 **Klein GR**, Jacquette GM. Prosthetic knee infection in the young immigrant patient--do not forget tuberculosis! *J Arthroplasty* 2012; **27**: 1414.e1-4 [PMID: 22088780 DOI: 10.1016/j.arth.2011.09.020]
  - 48 **Srivastava A**, Ostrander J, Martin S, Walter N. *Mycobacterium bovis* infection of total hip arthroplasty after intravesicular bacille Calmette-Guérin therapy. *Am J Orthop (Belle Mead NJ)* 2011; **40**: E226-E228 [PMID: 22263218]
  - 49 **Rispler DT**, Stirtion JW, Gilde AK, Kane KR. *Mycobacterium bovis* infection of total knee arthroplasty after bacille Calmette-Guérin therapy for bladder cancer. *Am J Orthop (Belle Mead NJ)* 2015; **44**: E46-E48 [PMID: 25658082]
  - 50 **Vutescu ES**, Koenig KM. *Mycobacterium cosmeticum* Infection After Total Knee Arthroplasty: A Case Report. *JBJS Case Connect* 2017; **7**: e3 [PMID: 29244685 DOI: 10.2106/JBJS.CC.16.00099]
  - 51 **Mannelli VK**, Rai MP, Nemakayala DR, Kadiri NP. *Mycobacterium Chelonae* Developing Multidrug Resistance. *BMJ Case Rep* 2018; **2018** [PMID: 29472421 DOI: 10.1136/bcr-2017-222569]
  - 52 **Uhel F**, Corvaisier G, Poinsignon Y, Chirouze C, Beraud G, Grossi O, Varache N, Arvieux C, Berre RL, Tattevin P; Groupe d'Epidémiologie et Recherche en Infectiologie Clinique Centre-Ouest (GERICCO). *Mycobacterium tuberculosis* prosthetic joint infections: A case series and literature review. *J Infect* 2019; **78**: 27-34 [PMID: 30138639 DOI: 10.1016/j.jinf.2018.08.008]
  - 53 **Rodari P**, Marocco S, Buonfrate D, Beltrame A, Piubelli C, Orza P, Fittipaldo VA, Bisoffi Z. Prosthetic joint infection due to *Mycobacterium xenopi*: a review of the literature with a new case report. *Infection* 2020; **48**: 165-171 [PMID: 31098926 DOI: 10.1007/s15010-019-01318-1]
  - 54 **Congia S**, Puddu G, Sorrentino G, Dessì G, Marongiu G. Conservative treatment of early-onset tubercular periprosthetic joint infection following total knee arthroplasty. *J Infect Dev Ctries* 2020; **14**: 223-227 [PMID: 32146458 DOI: 10.3855/jidc.12053]
  - 55 **Fix WC**, Sheth NP, Braffman MN. *Mycobacterium fortuitum* Prosthetic Joint Infection After Total Hip Arthroplasty: A Case Report. *JBJS Case Connect* 2020; **10**: e0343 [PMID: 32649134 DOI: 10.2106/JBJS.CC.18.00343]
  - 56 **Tortoli E**. Microbiological features and clinical relevance of new species of the genus *Mycobacterium*. *Clin Microbiol Rev* 2014; **27**: 727-752 [PMID: 25278573 DOI: 10.1128/CMR.00035-14]
  - 57 **Santoso A**, Yoon TR, Park KS, Anwar IB, Utomo P, Soetjahjo B, Sibarani T. The Results of Two-stage Revision for Methicillin-resistant Periprosthetic Joint Infection (PJI) of the Hip. *Malays Orthop J* 2020; **14**: 18-23 [PMID: 32296477 DOI: 10.5704/MOJ.2003.003]
  - 58 **Palan J**, Nolan C, Sarantos K, Westerman R, King R, Foguet P. Culture-negative periprosthetic joint infections. *EFORT Open Rev* 2019; **4**: 585-594 [PMID: 31754464 DOI: 10.1302/2058-5241.4.180067]





Published by **Baishideng Publishing Group Inc**  
7041 Koll Center Parkway, Suite 160, Pleasanton, CA 94566, USA

**Telephone:** +1-925-3991568

**E-mail:** [bpgoffice@wjgnet.com](mailto:bpgoffice@wjgnet.com)

**Help Desk:** <https://www.f6publishing.com/helpdesk>

<https://www.wjgnet.com>

