

World Journal of *Orthopedics*

World J Orthop 2022 August 18; 13(8): 679-776



REVIEW

- 679 Anterolateral complex of the knee: State of the art
Sabatini L, Capella M, Vezza D, Barberis L, Camazzola D, Risitano S, Drocco L, Massè A

ORIGINAL ARTICLE**Clinical and Translational Research**

- 693 Social media growth of orthopaedic surgery residency programs in response to the COVID-19 pandemic
Geller JS, Massel DH, Rizzo MG, Schwartz E, Milner JE, Donnally III CJ

Retrospective Cohort Study

- 703 Fluctuation of visual analog scale pain scores and opioid consumption before and after total hip arthroplasty
Singh V, Tang A, Bieganski T, Anil U, Macaulay W, Schwarzkopf R, Davidovitch RI
- 714 Functional and clinical outcome with modified lateral approach total hip arthroplasty in stiff hips with ankylosing spondylitis
Jacob MK, Reddy PK, Kuruvilla RS, John CV, Poonnoose PM, Oommen AT
- 725 Higher cost of arthroplasty for hip fractures in patients transferred from outside hospitals vs primary emergency department presentation
Haug EC, Pehlivan H, Macdonell JR, Novicoff W, Browne J, Brown T, Cui Q

Retrospective Study

- 733 Risk modeling of femoral neck fracture based on geometric parameters of the proximal epiphysis
Shitova AD, Kovaleva ON, Olsufieva AV, Gadzhimuradova IA, Zubkov DD, Kniazev MO, Zharikova TS, Zharikov YO
- 744 Epidemiology of pelvic and acetabular fractures across 12-mo at a level-1 trauma centre
Cuthbert R, Walters S, Ferguson D, Karam E, Ward J, Arshad H, Culpan P, Bates P
- 753 Effect of pelvic fixation on ambulation in children with neuromuscular scoliosis
Drake L, Sukkarieh H, McDonald T, Bhanat E, Quince E, Atkins M, Wright P, Brooks J

Prospective Study

- 760 Quantitative alpha-defensin testing: Is synovial fluid dilution important?
Abdo RCT, Gobbi RG, Leite CBG, Pasoto SG, Leon EP, Lima ALLM, Bonfá E, Pécora JR, Demange MK

CASE REPORT

- 768 Bilateral hip heterotopic ossification with sciatic nerve compression on a paediatric patient—An individualized surgical approach: A case report
Nóbrega JPG, Jordão P, Arcângelo J

LETTER TO THE EDITOR

- 775 Rates of readmission and reoperation after operative management of midshaft clavicle fractures in adolescents

Mesregah MK

ABOUT COVER

Editorial Board Member of *World Journal of Orthopedics*, Dimitrios Kitridis, MD, MSc, Doctor, Surgeon, The First Orthopaedic Department, Aristotle University of Thessaloniki, Thessaloniki 57010, Greece. dkitridis@gmail.com

AIMS AND SCOPE

The primary aim of *World Journal of Orthopedics* (WJO, *World J Orthop*) is to provide scholars and readers from various fields of orthopedics with a platform to publish high-quality basic and clinical research articles and communicate their research findings online.

WJO mainly publishes articles reporting research results and findings obtained in the field of orthopedics and covering a wide range of topics including arthroscopy, bone trauma, bone tumors, hand and foot surgery, joint surgery, orthopedic trauma, osteoarthropathy, osteoporosis, pediatric orthopedics, spinal diseases, spine surgery, and sports medicine.

INDEXING/ABSTRACTING

WJO is now abstracted and indexed in PubMed, PubMed Central, Emerging Sources Citation Index (Web of Science), Scopus, Reference Citation Analysis, China National Knowledge Infrastructure, China Science and Technology Journal Database, and Superstar Journals Database. The 2022 edition of Journal Citation Reports® cites the 2021 Journal Citation Indicator (JCI) for WJO as 0.62. The WJO's CiteScore for 2021 is 2.4 and Scopus CiteScore rank 2021: Orthopedics and Sports Medicine is 139/284.

RESPONSIBLE EDITORS FOR THIS ISSUE

Production Editor: Ying-Yi Yuan; **Production Department Director:** Xiang Li; **Editorial Office Director:** Jin-Lai Wang.

NAME OF JOURNAL

World Journal of Orthopedics

ISSN

ISSN 2218-5836 (online)

LAUNCH DATE

November 18, 2010

FREQUENCY

Monthly

EDITORS-IN-CHIEF

Massimiliano Leigheb

EDITORIAL BOARD MEMBERS

<http://www.wjgnet.com/2218-5836/editorialboard.htm>

PUBLICATION DATE

August 18, 2022

COPYRIGHT

© 2022 Baishideng Publishing Group Inc

INSTRUCTIONS TO AUTHORS

<https://www.wjgnet.com/bpg/gerinfo/204>

GUIDELINES FOR ETHICS DOCUMENTS

<https://www.wjgnet.com/bpg/GerInfo/287>

GUIDELINES FOR NON-NATIVE SPEAKERS OF ENGLISH

<https://www.wjgnet.com/bpg/gerinfo/240>

PUBLICATION ETHICS

<https://www.wjgnet.com/bpg/GerInfo/288>

PUBLICATION MISCONDUCT

<https://www.wjgnet.com/bpg/gerinfo/208>

ARTICLE PROCESSING CHARGE

<https://www.wjgnet.com/bpg/gerinfo/242>

STEPS FOR SUBMITTING MANUSCRIPTS

<https://www.wjgnet.com/bpg/GerInfo/239>

ONLINE SUBMISSION

<https://www.f6publishing.com>



Anterolateral complex of the knee: State of the art

Luigi Sabatini, Marcello Capella, Daniele Vezza, Luca Barberis, Daniele Camazzola, Salvatore Risitano, Luca Drocco, Alessandro Massè

Specialty type: Orthopedics

Provenance and peer review:

Invited article; Externally peer reviewed.

Peer-review model: Single blind

Peer-review report's scientific quality classification

Grade A (Excellent): 0
Grade B (Very good): B, B
Grade C (Good): 0
Grade D (Fair): 0
Grade E (Poor): 0

P-Reviewer: Koumantakis GA, Greece; Luo ZW, China

Received: December 28, 2021

Peer-review started: December 28, 2021

First decision: February 21, 2022

Revised: May 7, 2022

Accepted: July 24, 2022

Article in press: July 24, 2022

Published online: August 18, 2022



Luigi Sabatini, Marcello Capella, Daniele Vezza, Luca Barberis, Daniele Camazzola, Salvatore Risitano, Luca Drocco, Alessandro Massè, Department of Orthopaedics and Traumatology, Università degli Studi di Torino, Torino 10126, Italy

Corresponding author: Luigi Sabatini, MD, Doctor, Surgeon, Department of Orthopaedics and Traumatology, Università degli Studi di Torino, Via Zuretti 29, Torino 10126, Italy.
luigisabatini.ort@gmail.com

Abstract

Rotatory instability of the knee represents the main reason for failure and poor clinical outcomes regarding anterior cruciate ligament (ACL) reconstruction techniques. It is now clear that the anterolateral complex (ALC) of the knee possesses a fundamental role, in association with the ACL, in controlling internal rotation. Over the past decade, ever since the anterolateral ligament has been identified and described as a distinct structure, there has been a renewed interest in the scientific community about the whole ALC: Lateral extra-articular tenodesis have made a comeback in association with ACL reconstructions to improve functional outcomes, reducing the risks of graft failure and associated injuries. Modern ACL reconstruction surgery must therefore investigate residual instability and proceed, when necessary, to extra-articular techniques, whether functional tenodesis or anatomical reconstruction. This review aims to investigate the latest anatomical and histological descriptions, and the role in rotational control and knee biomechanics of the ALC and its components. The diagnostic tools for its identification, different reconstruction techniques, and possible surgical indications are described. In addition, clinical and functional results available in the literature are reported.

Key Words: Knee; Knee dislocation; Anterior cruciate ligament reconstruction; Fascia lata; Tenodesis; Joint instability

©The Author(s) 2022. Published by Baishideng Publishing Group Inc. All rights reserved.

Core Tip: Residual rotatory instability is present in a significant percentage of patients who underwent anterior cruciate ligament (ACL) reconstruction. Regardless of the injured structure of the anterolateral complex involved, whether the anterolateral ligament itself or different iliotibial band layers, the combination of a lateral extra-articular tenodesis technique has proven to be a safe, easily reproducible, and effective practice in reducing tibial internal rotation, improving ACL graft survival, reducing the overall reintervention rate, and improving the rate of return to previous athletic activity.

Citation: Sabatini L, Capella M, Vezza D, Barberis L, Camazzola D, Risitano S, Drocco L, Massè A. Anterolateral complex of the knee: State of the art. *World J Orthop* 2022; 13(8): 679-692

URL: <https://www.wjgnet.com/2218-5836/full/v13/i8/679.htm>

DOI: <https://dx.doi.org/10.5312/wjo.v13.i8.679>

INTRODUCTION

Anterior cruciate ligament (ACL) reconstruction techniques have sought to restore knee kinematics and reduce rotational instability. Since the 1970s[1] the idea that anterolateral rotatory instability (ALRI) was due not only to ACL injury, but also to the structures of the anterolateral complex (ALC), began to catch on. Over the last decade, awareness of the ALC has increased, especially since the anterolateral ligament (ALL) has been described and identified[2]. Several biomechanical studies have been carried out and different reconstruction techniques have been proposed.

The anterolateral ligament of the knee is a distinct ligamentous structure about which there is no consensus regarding its function and existence. Some authors deny the existence of such a structure, emphasizing the importance of other anatomical structures, such as the deeper portion of the iliotibial band (ITB) and the anterolateral capsule[3,4]. In contrast, other studies have identified the ALL as a ligament in its own right[5,6]. This disagreement originates from the anatomic dissection techniques that are performed[7,8].

Associated ACL and ALL injury have been shown to significantly increase knee rotational laxity and tibial internal rotation (IR), posing as the background for suboptimal outcomes, potential failure of an isolated ACL reconstruction (ACLR), and secondary meniscal or cartilage injury, as well as for early development of arthritic degeneration[9]. Controlling rotational laxity in ACLR still remains a challenge, with evidence of ALRI persistence in up to 25% of patients regardless of the ACLR technique used[10]. Several studies, in the last years, have identified the ALC as responsible for this residual instability and have pointed at the ALL and the ITB as the main players to internal tibial rotation restrain.

To improve residual rotational instability, more anatomical ACLR techniques have been developed, seeking a more oblique path of the femoral tunnel using the medial portal technique. Recently, the addition of a posterolateral bundle to the anteromedial bundle in double-bundle ACLR has been proposed; however, the technique did not improve rotatory stability and it has now been almost abandoned[11].

HISTORY

Although there have been sporadic references before 2013 about the existence of a capsuloligamentous structure connecting the femur and tibia in the anterolateral region, descriptions have been vague and often in disagreement. The first reference to the ALL date back more than 100 years. Segond[12], in 1879, described an avulsion fracture of the anterolateral margin of the tibia. He reported a "pearly band extending in an oblique fashion from the femur inserting into the avulsed tibial bone" without elaborating further on the details and anatomical relationships of this structure. However, this finding was ignored until it was rediscovered in a study by Hughston *et al*[1] in the 1970s in which they illustrated different patterns of rotational instability. They described a structure, called the "mid-third lateral capsular ligament", that was intimately connected to the lateral meniscus and how it could be involved in rotational instability. This structure, however, was not mentioned again, except sporadically in subsequent studies. In the same year, Johnson[13] described "the anterior oblique band of the lateral collateral ligament." On the other hand, Terry *et al*[14] pointed out that the main players in the anterolateral region were the deep, capsulo-osseous and superficial layers of the ITB without making references to distinct structures that could refer to the ALL.

In 2007, Vieira *et al*[15] described how the capsulo-osseous layer acts as "an anterolateral ligament". This term was used a few years later by Vincent *et al*[16] who identified, during TKA implantation, a ligamentous structure with connections to the distal femur, proximal tibia, and lateral meniscus in the anterolateral region of the knee. Nevertheless, before the study by Claes *et al*[2] in 2013 that was the first to provide a detailed description of ALL, this term was used to identify likely different structures and to

describe their role in the rotational control.

ANATOMY

According to Claes *et al*[2], a distinct anatomical structure connecting the distal femur and proximal tibia can be distinguished on the anterolateral portion of the knee. The structure is entirely extracapsular. The proximal insertion point lies on the prominence of the lateral femoral epicondyle, anterior to the fibular collateral ligament (FCL) insertion and proximal and posterior to the insertion of the popliteus tendon; the distal insertion of the ALL is located posterior to Gerdy's tubercle and anterior to the head of the fibula[17-19]. However, it is possible to recognize more superficial fibers that continue into the lateral intermuscular septum of the thigh and more posterior fibers that are closely connected to the more proximal portion of the FCL[2]. Connections to the body of the lateral meniscus also belong to the ALL, divided into menisiofemoral and menisiotibial portions. The lateral inferior geniculate artery and the vein invariably run between the ALL and the lateral meniscus.

Since the femoral insertion points of ALL and FCL are in close relationship, both structures can be described with the term "lateral collateral ligament complex." Likewise, the ALL could be the lateral counterpart of the deep medial collateral ligament[2]. However, some studies, have emphasized how the ALL structure and location can vary[20]. While several authors agree in identifying the tibial insertion, the disagreement about the femoral insertion is of particular interest. This discordance has biomechanical implications: The femoral insertion has been described as anterior and distal to the insertion of the FCL[2] or posterior and proximal with the fibers overlapping the FCL itself[18,21]. It is unclear whether this difference is due to interindividual differences or different dissection techniques.

In contrast, another model described by Helito *et al*[22] shows the existence of 2 distinct bundles: A more superficial one with femoral insertion posterior and proximal to the epicondyle and a deeper one with insertion in the center of the epicondyle. It is also likely that the ALL has an intimate relationship with the ITB, supported by a high association of lesions of the ALL and distal ITB[23].

The latest evidence emphasizes that the control of the ALRI is due to the entire anterolateral complex. The ALC works together with the ACL to restrain internal tibial rotation. The ALC consists of the ALL, the superficial and deep portion of the ITB, the capsulo-osseous layer, and the anterolateral capsule. Indeed, the deep part of the ITB and its complex insertion points at the distal femur contribute significantly to rotational control. Kaplan's fibers (KFs) play a role, along with the ITB, as a secondary passive stabilizer after the ACL[24]. They are described as a deep, posterior portion of the ITB connected to distal femur, divided into two bundles, the proximal fibers (PKF) and the distal fibers (DKF).

The capsulo-osseous layer has been described by Lobenhoffer *et al*[25] as a deep portion of the ITB, an arcuate retrograde fiber tract extending from the intermuscular septum of the femur in the lateral supracondylar region to the Gerdy's tubercle. This ligament-like unit forms a sling around the posterolateral aspect of the distal femur. More recent studies[26] have confirmed the presence of this layer as a distinct anatomic entity separated from the ALL and have also suggested a synergistic role of these structures in restraining IR.

HISTOLOGY

The histologic analysis provides evidence of particular interest in demonstrating the existence of the ALL as a distinct ligamentous structure with the presence of dense, well-arranged connective tissue and not as a simple capsular thickening that would have less organized and less cellular tissue[6]. The primary composition is type I collagen (90%) with a fibroblast concentration of 121/m² in adults and 1631/m² in fetal preparations[27]. In a study, by Catherine *et al*[28], the ALL shows fascicular organization in cross-section and also mechanoreceptors and nerve terminal fibers. Likewise, in an *in vivo* study of patients undergoing TKA, it was shown that the structure of ALL, compared to ACL, owned a similar pattern of collagen fibers orientation, nuclei's form, and a similar cellularity[29]. Furthermore, a clear distinction between ALL and capsule is present since the joint capsule resembles a loose connective tissue. Additionally, the ALL femoral insertion shows a transition from ligamentous tissue to mineralized cartilage and bone; this transition indicates ligamentous tissue[28].

IDENTIFICATION OF ALL

Although ALRI must be clinically assessed, there are diagnostic tools that allow visualization of the ALL.

Magnetic resonance imaging

Scientific studies that have investigated anterolateral complex lesions in patients with ACL injuries with

magnetic resonance imaging (MRI) often highlight conflicting results with association rates from 40% to 80% [30,31]. These discrepancies may be due to inclusion criteria, in some studies, of patients with chronic ACL injuries.

To visualize more easily a thin structure, such as the ALL, the use of a 3 T MRI with 0.4-mm slice and fat-suppressed acquisition is recommended [28] (Figure 1). In a study by Helito [32], MRIs of patients with acute ACL lesions were analyzed to point out the injured structures that were most frequently associated with an ALL lesion: FCL ($P = 0.004$), popliteal tendon ($P = 0.005$), MCL ($P = 0.011$), anterolateral capsule ($P = 0.000034$), and ITB with an increased correlation with a greater degree of injury ($P = 0.000021$). Tears of the ALL are found in 40% of acute ACL injuries, whereas no association was found with meniscal injuries. There was also no association between ALL injury and partial ACL injury, suggesting that the ALL is torn only in major traumas or that its integrity is a protective factor for ACL [32].

A systematic review by Puzzitiello *et al* [33] concluded that at least a portion of the ALL is visualizable on MRI in 76-100% of knees, and its possible injury in patients with acute ACL injury is identifiable from 10.8% to 62.5% of cases. Additionally, the level of inter- and intra-observer reliability varies from moderate to almost perfect. A higher prevalence of ALL lesions has been identified in MRI in patients with acute ACL injury and high-grade pivot shift with a positive correlation between pivot shift grade and lesion severity ($P < 0.013$) [34]. The finding of these injury associations helps to delineate how the anterolateral rotational stability of the knee is due to the synergistic work of these structures.

Arthroscopy

Several authors have described the possibility of arthroscopic identification of ALL and have provided step-by-step descriptions [35]. According to Zein [35], it is possible to identify it with a 30° scope through the AL portal. It is necessary to place the limb in a figure-of-4-position. In the lateral compartment, the popliteal tendon (PT), popliteal hiatus and synovial bulge anterior to the meniscal bare area are identified. By advancing the arthroscope into the lateral gutter above the synovial bulge, PT, FCL, and ALL can be identified, which run in different planes and directions. Applying an internal rotation, a tensioning of ALL can be observed. It is also possible to identify the meniscotibial attachment of the ALL below the lateral meniscus, anterior to the PT.

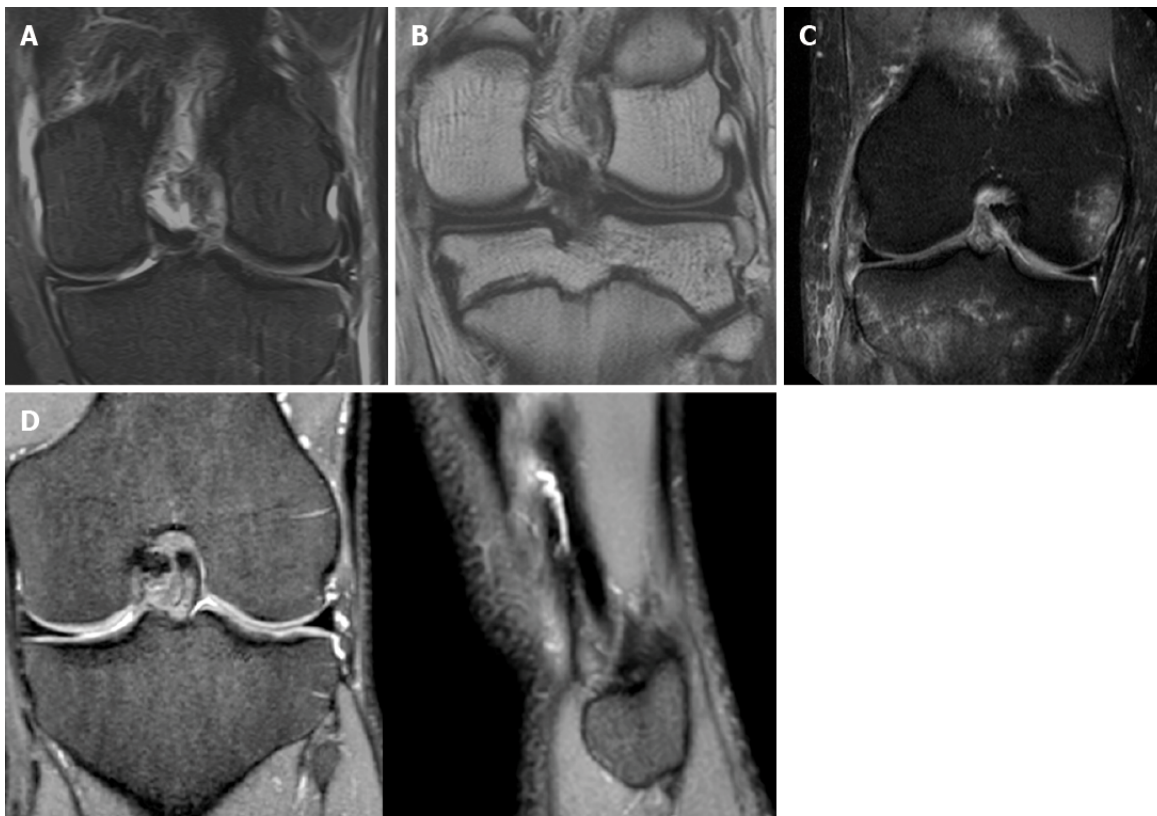
BIOMECHANICS

Regarding the ALL, there is no agreement in the literature regarding its role in knee biomechanics. While in some studies it has been shown that the ALL possesses a stabilizing role in an extension and internal rotation position [36], in a cadaveric study [37], the ALL limits internal rotation only at flexion angles greater than 35°, while providing minimal resistance to anteroposterior translation. However, it must be pointed out that the differences reported in these studies may be due to the dissection techniques adopted. In the study by Rasmussen *et al* [36], the ALL was not dissected but all anterolateral structures, from Gerdy's tubercle to the head of the fibula, were sectioned not considering that additional structures of the ALC might affect stabilization. Given that additional evidence points to the ITB as the main restraint to internal rotation [38], having it removed may have overestimated the role of the ALL.

It must be remembered that the ligamentous structures of the knee are unlikely to possess isometric behavior, and the various surgical techniques that seek isometric reconstruction fail to achieve anatomic positioning. Although the geometry of the condyles would make the area through which the transepicondylar axis passes a relatively isometric insertion zone, the roll-glide mechanism of the lateral condyle makes it impossible to find isometric femorotibial connections [39]. Structures, that therefore insert posteriorly to the epicondyle, are strained in extension, whereas anterior structures are strained in flexion.

In agreement with previous studies, Sonnery-Cottet *et al* [40] demonstrated how a section of the ALL did not lead to an increase in tibial IR at 20° of flexion angle but increased it at 90° and also showed that the ITB also participates in rotational control. In a study by Noyes *et al* [41], after sectioning of the ALL and the ITB, in agreement with evidence demonstrating a synergistic role of these structures in limiting IR, an increase of 5.1° at 60° of flexion and 6.7° at 90° of flexion has been observed. The latest evidence (in cadaver biomechanical studies) agrees that the ALL possesses an IR stabilizing function only at high degrees of flexion. Only at flexion angles of 60° and 90° a restriction to the IR by the ALL can be observed [42]. These results indicate that the ALL does not own a role in the pivot shift phenomenon that occurs at flexion degrees of 20°-30° [43], and one must therefore look for the ALRI responsible not in a single structure, but in the entire ALC. Terry *et al* [14] showed, in a cadaveric study of 82 knees, an anterolateral capsular lesion in 93% of patients with ACL injury and that this damage was significantly correlated with the degree of pivot shift.

It must be pointed out, however, that this evidence come from *in vitro* studies. Since anatomical dissections demonstrate connections between the ALL and ITB by Kaplan fibers, the actual function *in vivo* might prove to be different as the ITB might dynamically influence the ALL tension [42]. Zens *et al*



DOI: 10.5312/wjo.v13.i8.679 Copyright ©The Author(s) 2022.

Figure 1 Magnetic resonance imaging. A: Coronal T2 magnetic resonance imaging (MRI) showing a partial anterolateral ligament (ALL) lesion; B: Coronal T1 MRI showing a partial ALL lesion; C: Coronal STIR MRI showing a complete ALL lesion; D: Coronal and Sagittal T2 MRI showing an intact ALL.

[44] observed, in a cadaveric study, a progressive increase in the length of the ALL in the passive range of motion from 0° to 90° with an average increase of 0.15% per degree of flexion. They also observed that the greatest change in length ($+33.77\% \pm 9.62\%$) was observed at 90° flexion in 25° internal rotation.

Through biomechanical studies, the failure of the ALL has also been demonstrated to occur in: Ligamentous tear at the tibial or femoral insertion point, intrasubstance tear, or complete tibial detachment with bone fragment avulsion (Segond fracture)[45].

In contrast, according to a robotic study by Kittl *et al*[46], it is the ITB that provides the greatest resistance to tibial IR (44%). The deep fibers of the ITB, Kaplan fibers, act as an IR stabilizing ligament, fixing the ITB against the lateral epicondyle[47]. Indeed, after a section of the KFs, it's been observed that the ITB is no longer attached to the lateral epicondyle, thus losing its effectiveness in rotational control[48]. The role of the KFs was also confirmed by Geeslin *et al*[49], demonstrating that sectioning of the KFs resulted in an IR control loss from 30° to 90° of flexion.

In summary, anterolateral soft tissues contribute to rotational stability in ACL-deficient knees, with the deep ITB possibly playing a more important role closer to extension than the ALL, which has a greater control of IR at higher flexion angles.

ALC STIFFNESS

A study by Wytrykowski *et al*[50] analyzed the stiffness of the ALL (21 N/mm) and the load at failure (141 N), and also described the load at failure of the gracilis tendon (200.7 N) and ITB (161.1 N). Other biomechanical studies have measured the mean maximum load during pull-to-failure testing of KFs (170 N for DKF and 71.3 N for PKF), and thus, suggest an important role for resistant structures like the ALL[26]. It follows that both LETs and anterolateral ligament reconstructions (ALLRs) with ITB strips and gracilis grafts own sufficient strength for anterolateral procedures.

INDICATIONS

The clinical indications for ALLR or LET are not clearly defined, and level one clinical studies are currently lacking. It has not yet been established whether there is significant clinical knee instability that

requires correction with an additional procedure.

Currently, the indication to perform an extra articular procedure associated with ACL reconstruction is based on preoperative clinical evaluation and patient characteristics. Radiologic investigation is not routinely used as an objective assessment of ALL stability because relatively small lesions can be easily missed in a setting of more obvious associated injuries. Some authors recommend the routine use of such procedures in all ACL reconstruction[51,52].

In contrast, other authors recommend an associated procedure only in selected cases[41] based on comparative studies that have demonstrated significant benefits in specific populations, such as: ACL revisions[53,54], chronic ACL injuries[55], patients with high-grade pivot shift[10,56], patients with Segond's fracture[10], patients with hyperlaxity[55], or in high demanding patients with a need to return to high levels of sports activity and pivoting activities[52] (Table 1).

LATERAL EXTRA-ARTICULAR TENODESIS (LET)

Lateral extra-articular tenodesis was originally used as an isolated technique in patients with ACL deficiency. Several LET techniques showed good clinical results in the short term[57]. However, long-term results highlighted that isolated LETs tended to fail, returning again to a condition of rotatory instability[58].

After performing LETs extensively in the early 1980s, there is now renewed interest in these techniques as combined procedures for ACL reconstruction. These procedures were initially abandoned because of concerns about excessive constraint of the lateral compartment and potential development of osteoarthritis.

More than 12 LETs (Table 2) have been described, most of which use a variable-length ITB strip passed underneath the FCL and attached at various points on the lateral femoral condyle or at Gerdy's tubercle. The FCL acts as a pulley above the graft while maintaining a relative isometry of the graft itself. However, clinical studies to determine the superiority of one technique over the others are lacking. A correlation can be established on the biomechanical function of KF and LET techniques since both provide a connection between the ITB and the distal femur to control IR.

Recently, some authors have described a "more anatomical" extra-articular tenodesis that aims to tension the capsulo-osseous layer and reconstruct the distal KFs[59]. An ITB strip is elevated, maintaining the distal insertion, passed over the FCL, and then fixed into a tunnel drilled at the level of a bony prominence 31.4 mm proximal to the lateral epicondyle (DKF insertion point).

Over the past few years, the authors have tried the use of different LETs and have decided to use mainly the Cocker-Arnold technique. It is a simple technique, easily reproducible, and does not require the preparation of tunnels or the use of suture anchors. The Cocker Arnold technique has proven effective in patients with a preoperative pivot shift 2+ or 3+ at decreasing the phenomenon and reducing the ALRI[60]. Good results were also found in ACLR revisions in high function demand patients with an excellent return to sport rate[61].

Cocker Arnold Mod. Technique[62]

A longitudinal, 10-cm, slightly curved incision is made just posterior to the lateral femoral epicondyle. Dissection continues by identifying the posterior margin of the ITB and removing any fascial attachments down to the level of Gerdy's tubercle. A 1-cm-wide, 8 to 10-cm-long strip of ITB is elevated from the anterior aspect of the posterior half of the ITB. The insertion of the ITB strip to Gerdy's tubercle is preserved, removing any deep attachments of the strip from the vastus lateralis. Identification of the FCL is performed by palpation, facilitated by placing the knee in a figure-of-4 position, which stretches the ligament. Once the FCL has been identified, a blunt dissection is made anteriorly and posteriorly to the proximal portion of the ligament. Efforts should be made to remain extracapsular in order not to damage the popliteal tendon. The ITB graft is then guided under the FCL from distal to proximal, flipped over the Gerdy's tubercle, and sutured to itself using a high resistance non adsorbable suture, with the knee in near full extension and neutral rotation (Figure 2).

ANTEROLATERAL LIGAMENT RECONSTRUCTION

The concepts of ALLR and LET are sometimes used synonymously, since these procedures share conceptual similarities in terms of technique and goals. However, in ALLRs an anatomical reconstruction of the ALL is sought, while in LETs a functional and not an anatomical reconstruction is performed.

Several studies have shown that isometry of the graft used in ALLRs is achieved by fixing it distal to Gerdy's tubercle and very proximal and posterior to the distal metaepiphyseal junction of the femur [63]. However, this positioning does not match the anatomic insertions of the ALL. The ALL is an anisometric structure: the length and tension of the ligament changes with knee flexion. The best

Table 1 Indications for an extra-articular procedure**Patients with specific characteristics:**

ACL revisions

Chronic ACL injuries

High-grade pivot shifts

Segond's fracture

Hyperlaxity

High demanding patients

ACL: Anterior cruciate ligament.

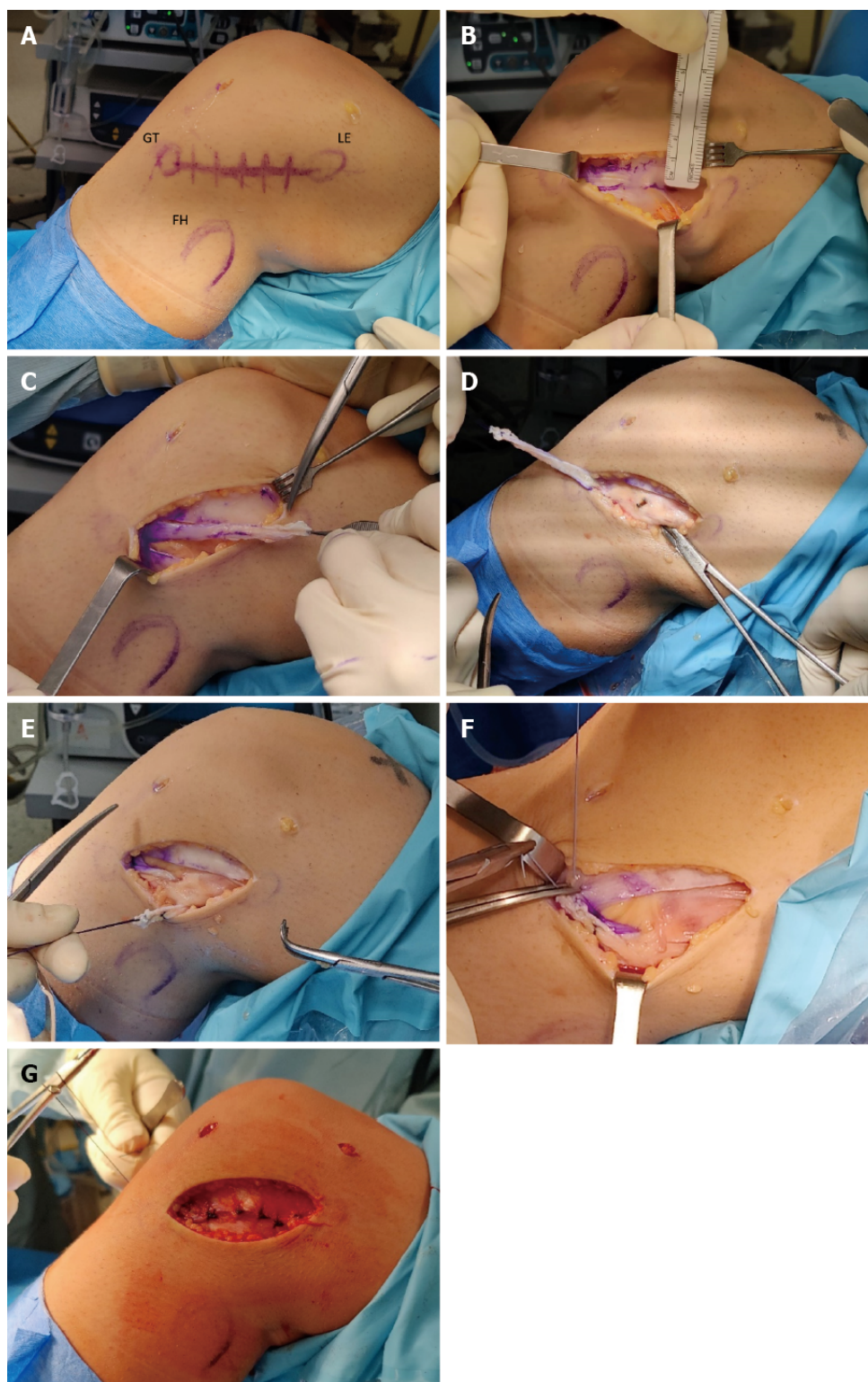
Table 2 The most performed lateral extra-articular tenodesis

Technique	Description
Lemaire <i>et al</i> [87], 1967	An ITB strip is harvested while maintaining the distal insertion, and then passed under the FCL and through a semi-circular tunnel created on the lateral aspect of the distal femur. The strip is then reflected and sutured onto itself.
Mod. Lemaire[21, 88,89]	An ITB strip is harvested while maintaining the distal insertion, passed under the FCL, and secured to the lateral condyle with an interference screw or a staple.
MacIntosh <i>et al</i> [90], 1976	An ITB strip is harvested while maintaining the distal insertion, passed under the FCL, through a subperiosteal tunnel, through the intermuscular septum, back under the FCL, and sutured onto itself.
Losee <i>et al</i> [91], 1978	An ITB strip is harvested while maintaining the distal insertion, passed under the FCL, through a femoral tunnel originating at the gastrocnemius insertion point and ending anterior to the FCL. The strip is then sutured onto itself.
Ellison <i>et al</i> [92], 1979	A strip of ITB is elevated distally with a bony bract, passed under the FCL, and attached anteriorly to the original insertion.
Arnold and Coker <i>et al</i> [62], 1979	An ITB strip is harvested while maintaining the distal insertion, passed under the FCL, reflected, and sutured to itself at Gerdy's tubercle.
Benum[93], 1982	A lateral portion of the patellar tendon is harvested while maintaining the distal insertion, passed under the FCL, and secured with a staple to the lateral condyle.
Andrews and Sanders[94], 1983	Two ITB strips are elevated proximally, whipstitched with sutures that are passed through two parallel tunnels from the lateral condyle to the medial condyle, and then tied together.
Zarins and Rowe [95], 1986	The semitendinosus tendon is harvested while maintaining the insertion, passed through a tibial tunnel, through the joint, and over the lateral condyle below the FCL, and sutured to the ITB. Similarly, a strip of ITB is harvested proximally, passed under the FCL, over the lateral condyle, through the tibial tunnel, and sutured to the semitendinosus tendon.
Wilson and Scranton[96], 1990	An ITB strip is harvested while maintaining the distal insertion, passed under the FCL and lateral gastrocnemius tendon, and sutured onto itself.
Marcacci and Zaffagnini[97], 1998	The semitendinosus and gracilis tendons are harvested while maintaining the insertion, sutured together, passed through a tibial tunnel, through the femoral notch, and over the top of the lateral condyle. The graft is then passed deep to the ITB, over the FCL, and attached distally to Gerdy's tubercle.

FCL: Fibular collateral ligament; ITB: Iliotibial band.

compromise[64,65] between the anatomic reconstruction and the ideal location of the graft insertions is as follows: At the femur, fixation proximal and posterior to the lateral epicondyle; at the tibia, fixation midway between Gerdy's tubercle and the ALL insertion. Fixation should also be done with the knee extended and the foot in neutral rotation. It is critical not to tension the graft in external rotation to avoid stiffening the knee and increasing stress.

The ALLR technique with the most clinical data available in the literature is reported by Sonnery-Cottet *et al*[10]: They described a combined ACL and ALL reconstruction technique using a 3-strand semitendinosus graft coupled with a free gracilis tendon graft. That resulted in a graft that, therefore, had a quadruple section, used for ACL reconstruction, that continues into a single gracilis strand used for ALL reconstruction. An isometric point near the femoral condyle is identified and drilled with an outside-in technique to serve as both the femoral tunnel for the intra-articular ACL and the femoral attachment for the extra-articular ALL reconstruction. The gracilis strand is then advanced distally into a tibial tunnel with an entry point superolateral to Gerdy's tubercle and then flipped back on itself, resulting in an inverted Y shape. This distal double bundle technique differs from most other ALL reconstruction techniques, which tend to use a free graft and a single tibial fixation point[66,67].



DOI: 10.5312/wjo.v13.i8.679 Copyright ©The Author(s) 2022.

Figure 2 Cocker Arnold Mod Technique. A: Bony landmarks on the anterolateral aspect of the knee: Gerdy's tubercle, lateral epicondyle, fibular head; B: An iliotibial band (ITB) strip 1cm-wide, 8 cm-long is prepared; C: ITB strip harvesting maintaining the distal insertion; D: Identification of the fibular collateral ligament (FCL) and blunt dissection; E: The graft is passed under the FCL and reflected to itself; F: The graft is sutured to Gerdy's tubercle with knee in extension and neutral rotation; G: The ITB is sutured in a standard fashion.

ALLR VS LET

Biomechanical studies explain that LET procedures have an advantageous lever arm in resisting IR compared to ALLR techniques. This is due to the more anterior point of fixation at Gerdy's tubercle, which provides a more efficient force vector[68].

Since a major concern lies in the overconstraint of the lateral compartment[69], several studies have been concerned with analyzing the effectiveness of different techniques at different degrees of tension [70]. The authors verified the optimal graft tension by applying different fixation tensions. The results show that a modified Lemaire tenodesis (in which an ITB strip is elevated, passed under the FCL, and fixed to the distal femur with a suture anchor) can restore proper knee kinematics with a tension of 20 N regardless of the degree of flexion (0°, 30°, and 60°) while maintaining the foot in neutral rotation. An ALL-anatomical reconstruction, on the other hand, cannot sufficiently reduce rotational laxity even at 40 N tension. According to the research of Inderhaug *et al*[71], a double-bundle ALLR (with one femoral attachment point and two distinct tibial attachment point) procedure can restore rotatory laxity when the graft is fixed in full extension. However, it has been reported that flexion-extension of the knee leads to the detensioning of one of the 2 bundles, and therefore the use of a stronger single bundle, has been recommended.

Long-term effects on articular cartilage wear in outcomes of LET or ALLR procedures do not yet have high levels of evidence[72]; however, it makes sense to opt for effective procedures at lower levels of tension in order not to increase the contact pressure of the articular surfaces. In a study by Marcacci *et al* [52], in which patients who underwent ACLR and LET were prospectively followed for up to 13 years, there was no evidence of increased arthritic degeneration when comparing patients who underwent ACLR alone.

Previous studies recommended fixation of the graft (in LET procedures) by maintaining the tibia in an external rotation position. However, more recent studies recommend fixing the graft while keeping the tibia in a neutral rotation position so as not to inhibit physiologic rotational motion[73]. Since anterolateral structures are thought to affect ALRI, it is reasonable to assume that fixation while keeping the knee in extension (at a flexion angle where pivot shift occurs) is favorable for seeking normal knee kinematics[71]. Additionally, the ALL or LET graft is stretched and fixed after ACL graft fixation to minimize the overconstraint.

Regarding the choice of graft, both an ITB strip and a gracilis graft own sufficient strength to vicariate the function of the ALL. In a study by Kittl *et al*[64], patterns of change in length and isometry in lateral extra-articular reconstructions were analyzed. Of the variables examined, only two effectively and reproducibly predicted a relative isometric graft behavior in different degrees of flexion: a graft path below the FCL and a femoral graft fixation proximal and posterior to the lateral epicondyle. In a biomechanical study, it was shown that an anatomic reconstruction of the ALL did not significantly reduce IR or anterior translation. In contrast, a LET procedure significantly improved anterior translation and rotational laxity[21].

Several *in vitro* biomechanical studies have attempted to quantify the efficacy of LET procedures. However, it is difficult to reach objective conclusions of superiority and durability given the large variability in different surgical techniques, graft selection, and type of fixation.

RESULTS

The indication for performing an anterolateral procedure is based on the concept of reducing stress forces on the ACL graft and more accurately restoring normal knee kinematics[74]. Improved knee stability results in a protective effect of the ACL graft and on the menisci[75]. These biomechanical advantages translate into clinical benefits, including reduced risk of ACL graft rupture, higher rates of return to previous sports physical activity, and lower risk of meniscal repair failure[76].

As early as 1990, LET combined with ACLR was shown to reduce graft stress by 43%[77] and combined use is being sought to improve joint kinematics and reduce graft failure rates[78].

Combining an ALLR reduces IR compared to isolated ACLR while having no significant effect on anterior translation. The resulting decrease in IR is more pronounced by increasing the degree of flexion. Specifically, applying a torque of 6 N/m decreased internal rotation of 1.64° ($P < 0.001$) in patients undergoing ACLR + ALLR compared to patients undergoing isolated ACLR[79].

Historically, several ACL reconstruction techniques have been proposed to restore rotational instability. Isolated ACL reconstructions, whether single or double bundle, have failed in the attempt by resulting in a residual rotational laxity. In a study by Monaco *et al*[51], it was demonstrated "*in vivo*" that the combination of a LET with a single-bundle ACLR procedure was significantly more effective than an isolated double-bundle technique ($P = 0.0001$) in reducing tibial IR.

In a study with 2-year follow-up in 502 patients[80], it was shown that the combination of ACLR (with hamstring graft) and ALLR had a 2.5-fold lower rate of ACL graft failure than isolated ACLR with BTPB and 3.1-fold lower rate than isolated ACLR with hamstring graft.

In a recent study by Sonnery-Cottet *et al*[81], it was shown at an average follow-up of 104 mo that patients undergoing ACLR combined with ALLR experienced significantly better ACL graft survival ($P = 0.0027$), lower overall revision rates ($P < 0.05$), lower ACLR revision rates ($P < 0.05$), and comparable complication rates to patients undergoing isolated ACLR. Overall, patients undergoing isolated ACLR had a 5-fold increased risk of ACL revision.

Regarding the concern of developing osteoarthritis in patients undergoing ALLR, there are two possible opposing scenarios to consider. The first factor relates to a possible overconstraint of the lateral compartment resulting in increased contact forces. The second factor, in contrast, concerns the possible residual rotational instability in case an ALLR is not performed, resulting in poor tibial rotation control and the consequent risk of secondary meniscal and chondral injuries. Several studies, however, state that there is no association between ALLR and early development of osteoarthritis compared with patients undergoing isolated ACLR[52,82]. In a multicenter study with 675 patients at 12 years of follow-up[83], there was no evidence of an association between ALLR and arthritic degeneration, which was instead reported mainly in cases of medial meniscectomy.

Recent literature states that, in agreement with biomechanical studies, associating an anterolateral procedure significantly improves a high-grade pivot shift, ensuring better clinical functional outcomes [84,85]. Additionally, subjective scores, such as IKDC and Lysholm and objective tests, such as the KT-1000, are also significantly better ($P < 0.05$) in patients who underwent a combined procedure[86].

ACTUAL LIMITS AND FUTURE PERSPECTIVES

A more complete and comprehensive understanding of ALC has encouraged surgeons to perform combined reconstructions to improve clinical results and long-term outcomes. It should be noted, however, that the heterogeneity of the techniques used in the studies examined cannot provide valid data and results for each anterolateral procedure. Although recent studies have shown the efficacy and safety of these techniques[80,81], randomized clinical trials and level one studies are required to analyze the superiority of a LET or ALLR technique over the others in terms of ALRI reduction and total revision rate.

CONCLUSION

From the latest evidence, it appears that it is not a single anterolateral structure that determines rotational stability, but rather that several structures act synergistically: the ALL, the superficial and deep layers of the ITB, the capsulo-osseous layer, and the Kaplan fibers. Regardless of the distinct structures that are injured and cause an ALRI, the authors consider it important to obtain a careful clinical evaluation of the patient, repeated just before the surgical procedure under anesthesia. In a scenario where there is no demonstrated superiority of one technique over the others, the authors opted to use the Cocker Arnold Modified Tenodesis as a combined procedure in ACLR deciding to perform it according to [...] patient's characteristics (such as a high-grade pivot shift, hyperlaxity, Segond's fracture) and functional demands. They also use it in any revision surgery where there has been a previous ACL graft failure in order to reduce the ACL graft stress and the risk rate of a new failure.

FOOTNOTES

Author contributions: Sabatini L provided the input in writing the paper; Risitano S, Drocco L, and Capella M collected the literature review; Vezza D, Barberis L, and Camazzola D wrote the paper; Massè A coordinated the writing of the paper.

Conflict-of-interest statement: All authors report no relevant conflict of interest for this article.

Open-Access: This article is an open-access article that was selected by an in-house editor and fully peer-reviewed by external reviewers. It is distributed in accordance with the Creative Commons Attribution NonCommercial (CC BY-NC 4.0) license, which permits others to distribute, remix, adapt, build upon this work non-commercially, and license their derivative works on different terms, provided the original work is properly cited and the use is non-commercial. See: <https://creativecommons.org/licenses/by-nc/4.0/>

Country/Territory of origin: Italy

ORCID number: Luigi Sabatini 0000-0003-4956-1303; Marcello Capella 0000-0002-6076-8527; Daniele Vezza 0000-0002-9710-402X; Luca Barberis 0000-0001-5994-2471; Daniele Camazzola 0000-0001-9701-1889; Salvatore Risitano 0000-0003-4595-1531; Luca Drocco 0000-0002-4982-9106; Alessandro Massè 0000-0003-3999-4121.

S-Editor: Wu YXJ

L-Editor: Filipodia

P-Editor: Wu YXJ

REFERENCES

- 1 **Hughston JC**, Andrews JR, Cross MJ, Moschi A. Classification of knee ligament instabilities. Part II. The lateral compartment. *J Bone Joint Surg Am* 1976; **58**: 173-179 [PMID: [1254620](#) DOI: [10.2106/00004623-197658020-00002](#)]
- 2 **Claes S**, Vereecke E, Maes M, Victor J, Verdonk P, Bellemans J. Anatomy of the anterolateral ligament of the knee. *J Anat* 2013; **223**: 321-328 [PMID: [23906341](#) DOI: [10.1111/joa.12087](#)]
- 3 **Urban S**, Pretterklieber B, Pretterklieber ML. The anterolateral ligament of the knee and the lateral meniscotibial ligament - Anatomical phantom vs constant structure within the anterolateral complex. *Ann Anat* 2019; **226**: 64-72 [PMID: [31330303](#) DOI: [10.1016/j.aanat.2019.06.005](#)]
- 4 **Sheean AJ**, Shin J, Patel NK, Lian J, Guenther D, Musahl V. The Anterolateral Ligament is Not the Whole Story: Reconsidering the Form and Function of the Anterolateral Knee and its Contribution to Rotatory Knee Instability. *Tech Orthop* 2018; **33**: 219-224 [PMID: [30542220](#) DOI: [10.1097/BTO.0000000000000303](#)]
- 5 **Cho HJ**, Kwak DS. Anatomical Consideration of the Anterolateral Ligament of the Knee. *Biomed Res Int* 2019; **2019**: 5740473 [PMID: [31111059](#) DOI: [10.1155/2019/5740473](#)]
- 6 **Helito CP**, Demange MK, Bonadio MB, Tírico LE, Gobbi RG, Pécora JR, Camanho GL. Anatomy and Histology of the Knee Anterolateral Ligament. *Orthop J Sports Med* 2013; **1**: 2325967113513546 [PMID: [26535259](#) DOI: [10.1177/2325967113513546](#)]
- 7 **Herbst E**, Albers M, Burnham JM, Fu FH, Musahl V. The Anterolateral Complex of the Knee. *Orthop J Sports Med* 2017; **5**: 2325967117730805 [PMID: [29051903](#) DOI: [10.1177/2325967117730805](#)]
- 8 **Ariel de Lima D**, Helito CP, Lacerda de Lima L, de Castro Silva D, Costa Cavalcante ML, Dias Leite JA. Anatomy of the Anterolateral Ligament of the Knee: A Systematic Review. *Arthroscopy* 2019; **35**: 670-681 [PMID: [30612770](#) DOI: [10.1016/j.arthro.2018.09.006](#)]
- 9 **Stergiou N**, Ristanis S, Moraiti C, Georgoulis AD. Tibial rotation in anterior cruciate ligament (ACL)-deficient and ACL-reconstructed knees: a theoretical proposition for the development of osteoarthritis. *Sports Med* 2007; **37**: 601-613 [PMID: [17595155](#) DOI: [10.2165/00007256-200737070-00004](#)]
- 10 **Sonnery-Cottet B**, Thaunat M, Freychet B, Pupim BH, Murphy CG, Claes S. Outcome of a Combined Anterior Cruciate Ligament and Anterolateral Ligament Reconstruction Technique With a Minimum 2-Year Follow-up. *Am J Sports Med* 2015; **43**: 1598-1605 [PMID: [25740835](#) DOI: [10.1177/0363546515571571](#)]
- 11 **Ferretti A**, Monaco E, Labianca L, Contedua F, De Carli A. Double-bundle anterior cruciate ligament reconstruction: a computer-assisted orthopaedic surgery study. *Am J Sports Med* 2008; **36**: 760-766 [PMID: [17702998](#) DOI: [10.1177/0363546507305677](#)]
- 12 **Segond P**. Recherches cliniques et expérimentales sur les épanchements sanguins du genou par entorse. Aux Bureaux du Progrès médical [DOI: [10.1192/bjp.42.177.369](#)]
- 13 **Johnson LL**. Lateral capsular ligament complex: anatomical and surgical considerations. *Am J Sports Med* 1979; **7**: 156-160 [PMID: [464170](#) DOI: [10.1177/036354657900700302](#)]
- 14 **Terry GC**, Hughston JC, Norwood LA. The anatomy of the iliopatellar band and iliotibial tract. *Am J Sports Med* 1986; **14**: 39-45 [PMID: [3752345](#) DOI: [10.1177/036354658601400108](#)]
- 15 **Vieira EL**, Vieira EA, da Silva RT, Berlfein PA, Abdalla RJ, Cohen M. An anatomic study of the iliotibial tract. *Arthroscopy* 2007; **23**: 269-274 [PMID: [17349469](#) DOI: [10.1016/j.arthro.2006.11.019](#)]
- 16 **Vincent JP**, Magnussen RA, Gezmez F, Uguen A, Jacobi M, Weppe F, Al-Saati MF, Lustig S, Demey G, Servien E, Neyret P. The anterolateral ligament of the human knee: an anatomic and histologic study. *Knee Surg Sports Traumatol Arthrosc* 2012; **20**: 147-152 [PMID: [21717216](#) DOI: [10.1007/s00167-011-1580-3](#)]
- 17 **Patel RM**, Brophy RH. Anterolateral Ligament of the Knee: Anatomy, Function, Imaging, and Treatment. *Am J Sports Med* 2018; **46**: 217-223 [PMID: [28320209](#) DOI: [10.1177/0363546517695802](#)]
- 18 **Ariel de Lima D**, Helito CP, Daggett M, Neto FMM, de Lima LL, Leite JAD, Cavalcante MLC. Anterolateral ligament of the knee: a step-by-step dissection. *BMC Musculoskelet Disord* 2019; **20**: 142 [PMID: [30947710](#) DOI: [10.1186/s12891-019-2517-0](#)]
- 19 **De Carli A**, Monaco E, Mazza D, Argento G, Redler A, Proietti L, Gaj E, Ferretti A. Assessment of the Anterolateral Ligament of the Knee by Magnetic Resonance Imaging. *Joints* 2018; **6**: 153-156 [PMID: [30582102](#) DOI: [10.1055/s-0038-1675163](#)]
- 20 **Sonnery-Cottet B**, Daggett M, Fayard JM, Ferretti A, Helito CP, Lind M, Monaco E, de Pádua VBC, Thaunat M, Wilson A, Zaffagnini S, Zijl J, Claes S. Anterolateral Ligament Expert Group consensus paper on the management of internal rotation and instability of the anterior cruciate ligament - deficient knee. *J Orthop Traumatol* 2017; **18**: 91-106 [PMID: [28220268](#) DOI: [10.1007/s10195-017-0449-8](#)]
- 21 **Spencer L**, Burkhart TA, Tran MN, Rezanoff AJ, Deo S, Catherine S, Getgood AM. Biomechanical analysis of simulated clinical testing and reconstruction of the anterolateral ligament of the knee. *Am J Sports Med* 2015; **43**: 2189-2197 [PMID: [26093007](#) DOI: [10.1177/0363546515589166](#)]
- 22 **Helito CP**, do Amaral C Jr, Nakamichi YD, Gobbi RG, Bonadio MB, Natalino RJ, Pécora JR, Cardoso TP, Camanho GL, Demange MK. Why Do Authors Differ With Regard to the Femoral and Meniscal Anatomic Parameters of the Knee Anterolateral Ligament? *Orthop J Sports Med* 2016; **4**: 2325967116675604 [PMID: [28203587](#) DOI: [10.1177/2325967116675604](#)]
- 23 **Mansour R**, Yoong P, McKean D, Teh JL. The iliotibial band in acute knee trauma: patterns of injury on MR imaging. *Skeletal Radiol* 2014; **43**: 1369-1375 [PMID: [24902510](#) DOI: [10.1007/s00256-014-1918-2](#)]
- 24 **Getgood A**, Brown C, Lording T, Amis A, Claes S, Geeslin A, Musahl V; ALC Consensus Group. The anterolateral complex of the knee: results from the International ALC Consensus Group Meeting. *Knee Surg Sports Traumatol Arthrosc* 2019; **27**: 166-176 [PMID: [30046994](#) DOI: [10.1007/s00167-018-5072-6](#)]
- 25 **Lobenhoffer P**, Posel P, Witt S, Piehler J, Wirth CJ. Distal femoral fixation of the iliotibial tract. *Arch Orthop Trauma Surg* 1987; **106**: 285-290 [PMID: [3632313](#) DOI: [10.1007/BF00454335](#)]
- 26 **Godin JA**, Chahla J, Moatshe G, Kruckeberg BM, Muckenhirn KJ, Vap AR, Geeslin AG, LaPrade RF. A Comprehensive

- Reanalysis of the Distal Iliotibial Band: Quantitative Anatomy, Radiographic Markers, and Biomechanical Properties. *Am J Sports Med* 2017; **45**: 2595-2603 [PMID: [28609131](#) DOI: [10.1177/0363546517707961](#)]
- 27 **Helito CP**, do Prado Torres JA, Bonadio MB, Aragão JA, de Oliveira LN, Natalino RJ, Pécora JR, Camanho GL, Demange MK. Anterolateral Ligament of the Fetal Knee: An Anatomic and Histological Study. *Am J Sports Med* 2017; **45**: 91-96 [PMID: [27624543](#) DOI: [10.1177/0363546516664888](#)]
- 28 **Catherine S**, Litchfield R, Johnson M, Chronik B, Getgood A. A cadaveric study of the anterolateral ligament: re-introducing the lateral capsular ligament. *Knee Surg Sports Traumatol Arthrosc* 2015; **23**: 3186-3195 [PMID: [24929656](#) DOI: [10.1007/s00167-014-3117-z](#)]
- 29 **Sabatini L**, Risitano S, Atzori F, Volante M, Aprato A, Indelli PF, Massè A. Histological analysis of the anterolateral ligament of the knee. *J Orthop* 2019; **16**: 368-372 [PMID: [31011250](#) DOI: [10.1016/j.jor.2019.03.019](#)]
- 30 **Claes S**, Bartholomeeusens S, Bellemans J. High prevalence of anterolateral ligament abnormalities in magnetic resonance images of anterior cruciate ligament-injured knees. *Acta Orthop Belg* 2014; **80**: 45-49 [PMID: [24873084](#)]
- 31 **Helito CP**, Helito PVP, Costa HP, Demange MK, Bordalo-Rodrigues M. Assessment of the Anterolateral Ligament of the Knee by Magnetic Resonance Imaging in Acute Injuries of the Anterior Cruciate Ligament. *Arthroscopy* 2017; **33**: 140-146 [PMID: [27324971](#) DOI: [10.1016/j.arthro.2016.05.009](#)]
- 32 **Helito CP**, Helito PVP, Leão RV, Demange MK, Bordalo-Rodrigues M. Anterolateral ligament abnormalities are associated with peripheral ligament and osseous injuries in acute ruptures of the anterior cruciate ligament. *Knee Surg Sports Traumatol Arthrosc* 2017; **25**: 1140-1148 [PMID: [28293698](#) DOI: [10.1007/s00167-017-4498-6](#)]
- 33 **Puzzitiello RN**, Agarwalla A, Zuke WA, Garcia GH, Forsythe B. Imaging Diagnosis of Injury to the Anterolateral Ligament in Patients With Anterior Cruciate Ligaments: Association of Anterolateral Ligament Injury With Other Types of Knee Pathology and Grade of Pivot-Shift Examination: A Systematic Review. *Arthroscopy* 2018; **34**: 2728-2738 [PMID: [30037574](#) DOI: [10.1016/j.arthro.2018.04.025](#)]
- 34 **Song GY**, Zhang H, Wu G, Zhang J, Liu X, Xue Z, Qian Y, Feng H. Patients with high-grade pivot-shift phenomenon are associated with higher prevalence of anterolateral ligament injury after acute anterior cruciate ligament injuries. *Knee Surg Sports Traumatol Arthrosc* 2017; **25**: 1111-1116 [PMID: [28243704](#) DOI: [10.1007/s00167-017-4492-z](#)]
- 35 **Zein AM**. Step-by-Step Arthroscopic Assessment of the Anterolateral Ligament of the Knee Using Anatomic Landmarks. *Arthrosc Tech* 2015; **4**: e825-e831 [PMID: [27284519](#) DOI: [10.1016/j.eats.2015.08.002](#)]
- 36 **Rasmussen MT**, Nitri M, Williams BT, Moulton SG, Cruz RS, Dornan GJ, Goldsmith MT, LaPrade RF. An In Vitro Robotic Assessment of the Anterolateral Ligament, Part 1: Secondary Role of the Anterolateral Ligament in the Setting of an Anterior Cruciate Ligament Injury. *Am J Sports Med* 2016; **44**: 585-592 [PMID: [26684663](#) DOI: [10.1177/0363546515618387](#)]
- 37 **Parsons EM**, Gee AO, Spiekerman C, Cavanagh PR. The biomechanical function of the anterolateral ligament of the knee. *Am J Sports Med* 2015; **43**: 669-674 [PMID: [25556221](#) DOI: [10.1177/0363546514562751](#)]
- 38 **Kittl C**, El-Daou H, Athwal KK, Gupte CM, Weiler A, Williams A, Amis AA. The Role of the Anterolateral Structures and the ACL in Controlling Laxity of the Intact and ACL-Deficient Knee. *Am J Sports Med* 2016; **44**: 345-354 [PMID: [26657572](#) DOI: [10.1177/0363546515614312](#)]
- 39 **Sidles JA**, Larson RV, Garbini JL, Downey DJ, Matsen FA 3rd. Ligament length relationships in the moving knee. *J Orthop Res* 1988; **6**: 593-610 [PMID: [3379513](#) DOI: [10.1002/jor.1100060418](#)]
- 40 **Sonnery-Cottet B**, Lutz C, Daggett M, Dalmay F, Freychet B, Niglis L, Imbert P. The Involvement of the Anterolateral Ligament in Rotational Control of the Knee. *Am J Sports Med* 2016; **44**: 1209-1214 [PMID: [26865395](#) DOI: [10.1177/0363546515625282](#)]
- 41 **Noyes FR**, Huser LE, Jurgensmeier D, Walsh J, Levy MS. Is an Anterolateral Ligament Reconstruction Required in ACL-Reconstructed Knees With Associated Injury to the Anterolateral Structures? *Am J Sports Med* 2017; **45**: 1018-1027 [PMID: [28056513](#) DOI: [10.1177/0363546516682233](#)]
- 42 **Drews BH**, Kessler O, Franz W, Dürselen L, Freutel M. Function and strain of the anterolateral ligament part I: biomechanical analysis. *Knee Surg Sports Traumatol Arthrosc* 2017; **25**: 1132-1139 [PMID: [28258329](#) DOI: [10.1007/s00167-017-4472-3](#)]
- 43 **Galway HR**, MacIntosh DL. The lateral pivot shift: a symptom and sign of anterior cruciate ligament insufficiency. *Clin Orthop Relat Res* 1980; **45**: 45-50 [PMID: [7371314](#) DOI: [10.1097/00003086-198003000-00008](#)]
- 44 **Zens M**, Niemeyer P, Ruhhammer J, Bernstein A, Woias P, Mayr HO, Südkamp NP, Feucht MJ. Length Changes of the Anterolateral Ligament During Passive Knee Motion: A Human Cadaveric Study. *Am J Sports Med* 2015; **43**: 2545-2552 [PMID: [26264771](#) DOI: [10.1177/0363546515594373](#)]
- 45 **Kennedy MI**, Claes S, Fuso FA, Williams BT, Goldsmith MT, Turnbull TL, Wijdicks CA, LaPrade RF. The Anterolateral Ligament: An Anatomic, Radiographic, and Biomechanical Analysis. *Am J Sports Med* 2015; **43**: 1606-1615 [PMID: [25888590](#) DOI: [10.1177/0363546515578253](#)]
- 46 **Kittl C**, Inderhaug E, Williams A, Amis AA. Biomechanics of the Anterolateral Structures of the Knee. *Clin Sports Med* 2018; **37**: 21-31 [PMID: [29173554](#) DOI: [10.1016/j.csm.2017.07.004](#)]
- 47 **Lutz C**, Sonnery-Cottet B, Niglis L, Freychet B, Clavert P, Imbert P. Behavior of the anterolateral structures of the knee during internal rotation. *Orthop Traumatol Surg Res* 2015; **101**: 523-528 [PMID: [26183087](#) DOI: [10.1016/j.otsr.2015.04.007](#)]
- 48 **Kennedy MI**, LaPrade CM, Geeslin AG, LaPrade RF. An Overview of Clinically Relevant Biomechanics of the Anterolateral Structures of the Knee. *Tech Orthop* 2018; **33**: 213-218 [PMID: [30542219](#) DOI: [10.1097/BTO.0000000000000300](#)]
- 49 **Geeslin AG**, Moatshe G, Chahla J, Kruckeberg BM, Muckenhirn KJ, Dornan GJ, Coggins A, Brady AW, Getgood AM, Godin JA, LaPrade RF. Anterolateral Knee Extra-articular Stabilizers: A Robotic Study Comparing Anterolateral Ligament Reconstruction and Modified Lemaire Lateral Extra-articular Tenodesis. *Am J Sports Med* 2018; **46**: 607-616 [PMID: [29268024](#) DOI: [10.1177/0363546517745268](#)]
- 50 **Wytrykowski K**, Swider P, Reina N, Murgier J, Laffosse JM, Chiron P, Cavaignac E. Cadaveric Study Comparing the Biomechanical Properties of Grafts Used for Knee Anterolateral Ligament Reconstruction. *Arthroscopy* 2016; **32**: 2288-

- 2294 [PMID: [27161509](#) DOI: [10.1016/j.arthro.2016.03.004](#)]
- 51 **Monaco E**, Labianca L, Contedua F, De Carli A, Ferretti A. Double bundle or single bundle plus extraarticular tenodesis in ACL reconstruction? *Knee Surg Sports Traumatol Arthrosc* 2007; **15**: 1168-1174 [PMID: [17589826](#) DOI: [10.1007/s00167-007-0368-y](#)]
- 52 **Marcacci M**, Zaffagnini S, Giordano G, Iacono F, Presti ML. Anterior cruciate ligament reconstruction associated with extra-articular tenodesis: A prospective clinical and radiographic evaluation with 10- to 13-year follow-up. *Am J Sports Med* 2009; **37**: 707-714 [PMID: [19193599](#) DOI: [10.1177/0363546508328114](#)]
- 53 **Ferretti A**, Contedua F, Monaco E, De Carli A, D'Arrigo C. Revision anterior cruciate ligament reconstruction with doubled semitendinosus and gracilis tendons and lateral extra-articular reconstruction. Surgical technique. *J Bone Joint Surg Am* 2007; **89** Suppl 2: 196-213 [PMID: [17768215](#) DOI: [10.2106/JBJS.G.00310](#)]
- 54 **Lee DW**, Kim JG, Cho SI, Kim DH. Clinical Outcomes of Isolated Revision Anterior Cruciate Ligament Reconstruction or in Combination With Anatomic Anterolateral Ligament Reconstruction. *Am J Sports Med* 2019; **47**: 324-333 [PMID: [30640514](#) DOI: [10.1177/0363546518815888](#)]
- 55 **Helito CP**, Sobrado MF, Giglio PN, Bonadio MB, Pécora JR, Camanho GL, Demange MK. Combined Reconstruction of the Anterolateral Ligament in Patients With Anterior Cruciate Ligament Injury and Ligamentous Hyperlaxity Leads to Better Clinical Stability and a Lower Failure Rate Than Isolated Anterior Cruciate Ligament Reconstruction. *Arthroscopy* 2019; **35**: 2648-2654 [PMID: [31421960](#) DOI: [10.1016/j.arthro.2019.03.059](#)]
- 56 **Monaco E**, Ferretti A, Labianca L, Maestri B, Speranza A, Kelly MJ, D'Arrigo C. Navigated knee kinematics after cutting of the ACL and its secondary restraint. *Knee Surg Sports Traumatol Arthrosc* 2012; **20**: 870-877 [PMID: [21877296](#) DOI: [10.1007/s00167-011-1640-8](#)]
- 57 **Andrews JR**, Sanders RA, Morin B. Surgical treatment of anterolateral rotatory instability. A follow-up study. *Am J Sports Med* 1985; **13**: 112-119 [PMID: [3985258](#) DOI: [10.1177/036354658501300206](#)]
- 58 **Amirault JD**, Cameron JC, MacIntosh DL, Marks P. Chronic anterior cruciate ligament deficiency. Long-term results of MacIntosh's lateral substitution reconstruction. *J Bone Joint Surg Br* 1988; **70**: 622-624 [PMID: [3403611](#) DOI: [10.1302/0301-620X.70B4.3403611](#)]
- 59 **Gali JC**, Gali Filho JC, Marques MF, Almeida TA, Cintra da Silva PA, LaPrade RF. Capsulo-osseous Layer Retensioning and Distal Kaplan Fiber Surgical Reconstruction: A Proposed Anatomical Lateral Extra-articular Tenodesis Approach. *Arthrosc Tech* 2021; **10**: e159-e164 [PMID: [33532223](#) DOI: [10.1016/j.eats.2020.09.021](#)]
- 60 **Vadalà AP**, Iorio R, De Carli A, Bonifazi A, Iorio C, Gatti A, Rossi C, Ferretti A. An extra-articular procedure improves the clinical outcome in anterior cruciate ligament reconstruction with hamstrings in female athletes. *Int Orthop* 2013; **37**: 187-192 [PMID: [22623063](#) DOI: [10.1007/s00264-012-1571-0](#)]
- 61 **Alessio-Mazzola M**, Formica M, Russo A, Sanguineti F, Capello AG, Lovisolo S, Felli L. Outcome after Combined Lateral Extra-articular Tenodesis and Anterior Cruciate Ligament Revision in Professional Soccer Players. *J Knee Surg* 2019; **32**: 906-910 [PMID: [30227449](#) DOI: [10.1055/s-0038-1672120](#)]
- 62 **Arnold JA**, Coker TP, Heaton LM, Park JP, Harris WD. Natural history of anterior cruciate tears. *Am J Sports Med* 1979; **7**: 305-313 [PMID: [507265](#) DOI: [10.1177/036354657900700601](#)]
- 63 **Kurosawa H**, Yasuda K, Yamakoshi K, Kamiya A, Kaneda K. An experimental evaluation of isometric placement for extraarticular reconstructions of the anterior cruciate ligament. *Am J Sports Med* 1991; **19**: 384-388 [PMID: [1897654](#) DOI: [10.1177/036354659101900411](#)]
- 64 **Kittl C**, Halewood C, Stephen JM, Gupte CM, Weiler A, Williams A, Amis AA. Length change patterns in the lateral extra-articular structures of the knee and related reconstructions. *Am J Sports Med* 2015; **43**: 354-362 [PMID: [25540293](#) DOI: [10.1177/0363546514560993](#)]
- 65 **Imbert P**, Lutz C, Daggett M, Niglis L, Freychet B, Dalmay F, Sonnery-Cottet B. Isometric Characteristics of the Anterolateral Ligament of the Knee: A Cadaveric Navigation Study. *Arthroscopy* 2016; **32**: 2017-2024 [PMID: [27157662](#) DOI: [10.1016/j.arthro.2016.02.007](#)]
- 66 **Chahla J**, Menge TJ, Mitchell JJ, Dean CS, LaPrade RF. Anterolateral Ligament Reconstruction Technique: An Anatomic-Based Approach. *Arthrosc Tech* 2016; **5**: e453-e457 [PMID: [27656361](#) DOI: [10.1016/j.eats.2016.01.032](#)]
- 67 **Smith JO**, Yassen SK, Lord B, Wilson AJ. Combined anterolateral ligament and anatomic anterior cruciate ligament reconstruction of the knee. *Knee Surg Sports Traumatol Arthrosc* 2015; **23**: 3151-3156 [PMID: [26387120](#) DOI: [10.1007/s00167-015-3783-5](#)]
- 68 **Amis AA**. Anterolateral knee biomechanics. *Knee Surg Sports Traumatol Arthrosc* 2017; **25**: 1015-1023 [PMID: [28299387](#) DOI: [10.1007/s00167-017-4494-x](#)]
- 69 **Slette EL**, Mikula JD, Schon JM, Marchetti DC, Kheir MM, Turnbull TL, LaPrade RF. Biomechanical Results of Lateral Extra-articular Tenodesis Procedures of the Knee: A Systematic Review. *Arthroscopy* 2016; **32**: 2592-2611 [PMID: [27324970](#) DOI: [10.1016/j.arthro.2016.04.028](#)]
- 70 **Inderhaug E**, Stephen JM, Williams A, Amis AA. Biomechanical Comparison of Anterolateral Procedures Combined With Anterior Cruciate Ligament Reconstruction. *Am J Sports Med* 2017; **45**: 347-354 [PMID: [28027653](#) DOI: [10.1177/0363546516681555](#)]
- 71 **Inderhaug E**, Stephen JM, Williams A, Amis AA. Anterolateral Tenodesis or Anterolateral Ligament Complex Reconstruction: Effect of Flexion Angle at Graft Fixation When Combined With ACL Reconstruction. *Am J Sports Med* 2017; **45**: 3089-3097 [PMID: [28898106](#) DOI: [10.1177/0363546517724422](#)]
- 72 **Dodds AL**, Gupte CM, Neyret P, Williams AM, Amis AA. Extra-articular techniques in anterior cruciate ligament reconstruction: a literature review. *J Bone Joint Surg Br* 2011; **93**: 1440-1448 [PMID: [22058292](#) DOI: [10.1302/0301-620X.93B11.27632](#)]
- 73 **Engelbrechtsen L**, Lew WD, Lewis JL, Hunter RE, Benum P. Anterolateral rotatory instability of the knee. Cadaver study of extraarticular patellar-tendon transposition. *Acta Orthop Scand* 1990; **61**: 225-230 [PMID: [2371815](#) DOI: [10.3109/17453679008993505](#)]
- 74 **Marom N**, Ouanezar H, Jahandar H, Zayyad ZA, Fraychineaud T, Hurwit D, Imhauser CW, Wickiewicz TL, Pearle AD, Nawabi DH. Lateral Extra-articular Tenodesis Reduces Anterior Cruciate Ligament Graft Force and Anterior Tibial

- Translation in Response to Applied Pivoting and Anterior Drawer Loads. *Am J Sports Med* 2020; **48**: 3183-3193 [PMID: 33017168 DOI: 10.1177/0363546520959322]
- 75 **Ferretti A**, Monaco E, Gaj E, Andreozzi V, Annibaldi A, Carrozzo A, Vieira TD, Sonnery-Cottet B, Saithna A. Risk Factors for Grade 3 Pivot Shift in Knees With Acute Anterior Cruciate Ligament Injuries: A Comprehensive Evaluation of the Importance of Osseous and Soft Tissue Parameters From the SANTI Study Group. *Am J Sports Med* 2020; **48**: 2408-2417 [PMID: 32631068 DOI: 10.1177/0363546520935866]
- 76 **Saithna A**, Daggett M, Helito CP, Monaco E, Franck F, Vieira TD, Pioger C, Kim JG, Sonnery-Cottet B. Clinical Results of Combined ACL and Anterolateral Ligament Reconstruction: A Narrative Review from the SANTI Study Group. *J Knee Surg* 2021; **34**: 962-970 [PMID: 32023631 DOI: 10.1055/s-0040-1701220]
- 77 **Engebretsen L**, Lew WD, Lewis JL, Hunter RE. The effect of an iliotibial tenodesis on intraarticular graft forces and knee joint motion. *Am J Sports Med* 1990; **18**: 169-176 [PMID: 2343985 DOI: 10.1177/036354659001800210]
- 78 **Duthon VB**, Magnussen RA, Servien E, Neyret P. ACL reconstruction and extra-articular tenodesis. *Clin Sports Med* 2013; **32**: 141-153 [PMID: 23177468 DOI: 10.1016/j.csm.2012.08.013]
- 79 **Kelly SR**, Cutter BM, Huish EG Jr. Biomechanical Effects of Combined Anterior Cruciate Ligament Reconstruction and Anterolateral Ligament Reconstruction: A Systematic Review and Meta-analysis. *Orthop J Sports Med* 2021; **9**: 23259671211009879 [PMID: 34250171 DOI: 10.1177/23259671211009879]
- 80 **Sonnery-Cottet B**, Saithna A, Cavalier M, Kajetanek C, Temponi EF, Daggett M, Helito CP, Thauinat M. Anterolateral Ligament Reconstruction Is Associated With Significantly Reduced ACL Graft Rupture Rates at a Minimum Follow-up of 2 Years: A Prospective Comparative Study of 502 Patients From the SANTI Study Group. *Am J Sports Med* 2017; **45**: 1547-1557 [PMID: 28151693 DOI: 10.1177/0363546516686057]
- 81 **Sonnery-Cottet B**, Haidar I, Rayes J, Fradin T, Ngbilo C, Vieira TD, Freychet B, Ouanezar H, Saithna A. Long-term Graft Rupture Rates After Combined ACL and Anterolateral Ligament Reconstruction Versus Isolated ACL Reconstruction: A Matched-Pair Analysis From the SANTI Study Group. *Am J Sports Med* 2021; **49**: 2889-2897 [PMID: 34351825 DOI: 10.1177/03635465211028990]
- 82 **Ferretti A**, Monaco E, Giannetti S, Caperna L, Luzon D, Contedua F. A medium to long-term follow-up of ACL reconstruction using double gracilis and semitendinosus grafts. *Knee Surg Sports Traumatol Arthrosc* 2011; **19**: 473-478 [PMID: 20602086 DOI: 10.1007/s00167-010-1206-1]
- 83 **Cantin O**, Lustig S, Rongieras F, Saragaglia D, Lefèvre N, Gravelleau N, Hulet C; Société Française de Chirurgie Orthopédique et Traumatologique. Outcome of cartilage at 12years of follow-up after anterior cruciate ligament reconstruction. *Orthop Traumatol Surg Res* 2016; **102**: 857-861 [PMID: 27544885 DOI: 10.1016/j.otsr.2016.06.011]
- 84 **Hewison CE**, Tran MN, Kaniki N, Remtulla A, Bryant D, Getgood AM. Lateral Extra-articular Tenodesis Reduces Rotational Laxity When Combined With Anterior Cruciate Ligament Reconstruction: A Systematic Review of the Literature. *Arthroscopy* 2015; **31**: 2022-2034 [PMID: 26116497 DOI: 10.1016/j.arthro.2015.04.089]
- 85 **Song GY**, Hong L, Zhang H, Zhang J, Li Y, Feng H. Clinical Outcomes of Combined Lateral Extra-articular Tenodesis and Intra-articular Anterior Cruciate Ligament Reconstruction in Addressing High-Grade Pivot-Shift Phenomenon. *Arthroscopy* 2016; **32**: 898-905 [PMID: 26524939 DOI: 10.1016/j.arthro.2015.08.038]
- 86 **Helito CP**, Camargo DB, Sobrado MF, Bonadio MB, Giglio PN, Pécora JR, Camanho GL, Demange MK. Combined reconstruction of the anterolateral ligament in chronic ACL injuries leads to better clinical outcomes than isolated ACL reconstruction. *Knee Surg Sports Traumatol Arthrosc* 2018; **26**: 3652-3659 [PMID: 29610972 DOI: 10.1007/s00167-018-4934-2]
- 87 **Lemaire M**. Ruptures anciennes du ligament croisé antérieur. *Fréquence-Clinique-Traitement. J Chir* 1967; **93**: 311-320 [DOI: 10.1016/b978-2-294-72966-9.00009-2]
- 88 **Jesani S**, Getgood A. Modified Lemaire Lateral Extra-Articular Tenodesis Augmentation of Anterior Cruciate Ligament Reconstruction. *JBJS Essent Surg Tech* 2019; **9** [PMID: 32051777 DOI: 10.2106/JBJS.ST.19.00017]
- 89 **Muller B**, Willinge GJA, Zijl JAC. Minimally Invasive Modified Lemaire Tenodesis. *Arthrosc Tech* 2021; **10**: e29-e36 [PMID: 33532204 DOI: 10.1016/j.eats.2020.09.006]
- 90 **MacIntosh DL**, Darby TA. Lateral substitution reconstruction. *J Bone Joint Surg* 1976; **58B**: 142
- 91 **Losee RE**, Johnson TR, Southwick WO. Anterior subluxation of the lateral tibial plateau. A diagnostic test and operative repair. *J Bone Joint Surg Am* 1978; **60**: 1015-1030 [PMID: 721850 DOI: 10.2106/00004623-197860080-00001]
- 92 **Ellison AE**. Distal iliotibial-band transfer for anterolateral rotatory instability of the knee. *J Bone Joint Surg Am* 1979; **61**: 330-337 [PMID: 429400 DOI: 10.2106/00004623-197961030-00002]
- 93 **Benum P**. Anterolateral rotary instability of the knee joint. Results after stabilization by extraarticular transposition of the lateral part of the patellar ligament. A preliminary report. *Acta Orthop Scand* 1982; **53**: 613-617 [PMID: 7102280 DOI: 10.3109/17453678208992267]
- 94 **Andrews JR**, Sanders R. A "mini-reconstruction" technique in treating anterolateral rotatory instability (ALRI). *Clin Orthop Relat Res* 1983; **93**: 93-96 [PMID: 6822011 DOI: 10.1097/00003086-198301000-00018]
- 95 **Zarins B**, Rowe CR. Combined anterior cruciate-ligament reconstruction using semitendinosus tendon and iliotibial tract. *J Bone Joint Surg Am* 1986; **68**: 160-177 [PMID: 3944155 DOI: 10.2106/00004623-198668020-00001]
- 96 **Wilson WJ**, Scranton PE Jr. Combined reconstruction of the anterior cruciate ligament in competitive athletes. *J Bone Joint Surg Am* 1990; **72**: 742-748 [PMID: 2355037 DOI: 10.2106/00004623-199072050-00015]
- 97 **Marcacci M**, Zaffagnini S, Iacono F, Neri MP, Loretto I, Petitto A. Arthroscopic intra- and extra-articular anterior cruciate ligament reconstruction with gracilis and semitendinosus tendons. *Knee Surg Sports Traumatol Arthrosc* 1998; **6**: 68-75 [PMID: 9604189 DOI: 10.1007/s001670050075]



Published by **Baishideng Publishing Group Inc**
7041 Koll Center Parkway, Suite 160, Pleasanton, CA 94566, USA

Telephone: +1-925-3991568

E-mail: bpgoffice@wjgnet.com

Help Desk: <https://www.f6publishing.com/helpdesk>

<https://www.wjgnet.com>

