


World Journal of *Orthopedics*

World J Orthop 2024 March 18; 15(3): 201-309



EDITORIAL

- 201 Cyclops syndrome following anterior cruciate ligament reconstruction: Can relapse occur after surgery?
Öztürk R
- 204 Update on the use of 45S5 bioactive glass in the treatment of bone defects in regenerative medicine
Nogueira DMB, Rosso MPO, Buchaim DV, Zangrando MSR, Buchaim RL

ORIGINAL ARTICLE**Retrospective Cohort Study**

- 215 Peri-articular elbow fracture fixations with magnesium implants and a review of current literature: A case series
Fang C, Premchand AXR, Park DH, Toon DH

Retrospective Study

- 230 Subsequent total joint arthroplasty: Are we learning from the first stage?
Wu CJ, Penrose C, Ryan SP, Bolognesi MP, Seyler TM, Wellman SS

Clinical Trials Study

- 238 Correction method for moderate and severe degrees of hallux valgus associated with transfer metatarsalgia
Zhanaspayev A, Bokembayev N, Zhanaspayev M, Tlemissov A, Aubakirova S, Prokazyuk A

Observational Study

- 247 Single-center experience with Knee+™ augmented reality navigation system in primary total knee arthroplasty
Sakellariou E, Alevrogiannis P, Alevrogianni F, Galanis A, Vavourakis M, Karampinas P, Gavriil P, Vlamis J, Alevrogiannis S

Prospective Study

- 257 Mid-term survival of the Optimys short stem: A prospective case series of 500 patients
Hamans B, de Waard S, Kaarsemaker S, Janssen ERC, Sierevelt IN, Kerkhoffs GMMJ, Haverkamp D

SYSTEMATIC REVIEWS

- 266 Does progress in microfracture techniques necessarily translate into clinical effectiveness?
Muthu S, Viswanathan VK, Sakthivel M, Thabrez M

META-ANALYSIS

- 285** Meta-analysis of the clinical efficacy of the Gamma3 nail *vs* Gamma3U-blade system in the treatment of intertrochanteric fractures
Wu X, Gao B
- 293** Pulsed lavage in joint arthroplasty: A systematic review and meta-analysis
Daher M, Haykal G, Aoun M, Moussallem M, Ghoul A, Tarchichi J, Sebaaly A

CASE REPORT

- 302** New method of local adjuvant therapy with bicarbonate Ringer's solution for tumoral calcinosis: A case report
Noguchi T, Sakamoto A, Kakehi K, Matsuda S

ABOUT COVER

Peer Reviewer of *World Journal of Orthopedics*, Ding-Wei Chen, MD, Chief Doctor, Surgeon, Department of General Surgery, Sir Run Run Shaw Hospital, School of Medicine, Zhejiang University, Hangzhou 310016, Zhejiang Province, China. 11118152@zju.edu.cn

AIMS AND SCOPE

The primary aim of *World Journal of Orthopedics* (*WJO*, *World J Orthop*) is to provide scholars and readers from various fields of orthopedics with a platform to publish high-quality basic and clinical research articles and communicate their research findings online.

WJO mainly publishes articles reporting research results and findings obtained in the field of orthopedics and covering a wide range of topics including arthroscopy, bone trauma, bone tumors, hand and foot surgery, joint surgery, orthopedic trauma, osteoarthropathy, osteoporosis, pediatric orthopedics, spinal diseases, spine surgery, and sports medicine.

INDEXING/ABSTRACTING

WJO is now abstracted and indexed in PubMed, PubMed Central, Emerging Sources Citation Index (Web of Science), Scopus, Reference Citation Analysis, China Science and Technology Journal Database, and Superstar Journals Database. The 2023 Edition of Journal Citation Reports® cites the 2022 impact factor (IF) for *WJO* as 1.9. The *WJO*'s CiteScore for 2022 is 2.6.

RESPONSIBLE EDITORS FOR THIS ISSUE

Production Editor: *Yu-Qing Zhao*; Production Department Director: *Xiang Li*; Editorial Office Director: *Jin-Li Wang*.

NAME OF JOURNAL

World Journal of Orthopedics

ISSN

ISSN 2218-5836 (online)

LAUNCH DATE

November 18, 2010

FREQUENCY

Monthly

EDITORS-IN-CHIEF

Massimiliano Leigheb, Xiao-Jian Ye

EXECUTIVE ASSOCIATE EDITORS-IN-CHIEF

Xin Gu

EDITORIAL BOARD MEMBERS

<http://www.wjgnet.com/2218-5836/editorialboard.htm>

PUBLICATION DATE

March 18, 2024

COPYRIGHT

© 2024 Baishideng Publishing Group Inc

PUBLISHING PARTNER

The Minimally Invasive Spine Surgery Research Center Of Shanghai Jiaotong University

INSTRUCTIONS TO AUTHORS

<https://www.wjgnet.com/bpg/gerinfo/204>

GUIDELINES FOR ETHICS DOCUMENTS

<https://www.wjgnet.com/bpg/GerInfo/287>

GUIDELINES FOR NON-NATIVE SPEAKERS OF ENGLISH

<https://www.wjgnet.com/bpg/gerinfo/240>

PUBLICATION ETHICS

<https://www.wjgnet.com/bpg/GerInfo/288>

PUBLICATION MISCONDUCT

<https://www.wjgnet.com/bpg/gerinfo/208>

POLICY OF CO-AUTHORS

<https://www.wjgnet.com/bpg/GerInfo/310>

ARTICLE PROCESSING CHARGE

<https://www.wjgnet.com/bpg/gerinfo/242>

STEPS FOR SUBMITTING MANUSCRIPTS

<https://www.wjgnet.com/bpg/GerInfo/239>

ONLINE SUBMISSION

<https://www.f6publishing.com>

PUBLISHING PARTNER'S OFFICIAL WEBSITE

https://www.shtrhospital.com/zkjs/info_29.aspx?itemid=647



Retrospective Cohort Study

Peri-articular elbow fracture fixations with magnesium implants and a review of current literature: A case series

Christopher Fang, Antony Xavier Rex Premchand, Derek Howard Park, Dong Hao Toon

Specialty type: Orthopedics

Provenance and peer review:

Unsolicited article; Externally peer reviewed.

Peer-review model: Single blind

Peer-review report's scientific quality classification

Grade A (Excellent): 0

Grade B (Very good): B

Grade C (Good): 0

Grade D (Fair): 0

Grade E (Poor): 0

P-Reviewer: Primadhi RA, Indonesia

Received: December 3, 2023

Peer-review started: December 3, 2023

First decision: January 6, 2024

Revised: January 11, 2024

Accepted: February 2, 2024

Article in press: February 2, 2024

Published online: March 18, 2024



Christopher Fang, Antony Xavier Rex Premchand, Derek Howard Park, Dong Hao Toon, Department of Orthopaedic Surgery, Khoo Teck Puat Hospital, National Healthcare Group, Singapore 768828, Singapore

Corresponding author: Christopher Fang, MBBS, MMed, Surgeon, Department of Orthopaedic Surgery, Khoo Teck Puat Hospital, National Healthcare Group, 90 Yishun Central, Singapore 768828, Singapore. chrisfang91@gmail.com

Abstract

BACKGROUND

In recent years, the use of Magnesium alloy implants have gained renewed popularity, especially after the first commercially available Conformité Européenne approved Magnesium implant became available (MAGNEZIX® CS, Syntellix) in 2013.

AIM

To document our clinical and radiographical outcomes using magnesium implants in treating peri-articular elbow fractures.

METHODS

Our paper was based on a retrospective case series design. Intra-operatively, a standardized surgical technique was utilized for insertion of the magnesium implants. Post - operatively, clinic visits were standardized and physical exam findings, functional scores, and radiographs were obtained at each visit. All complications were recorded.

RESULTS

Five patients with 6 fractures were recruited (2 coronoid, 3 radial head and 1 capitellum). The mean patient age and length of follow up was 54.6 years and 11 months respectively. All fractures healed, and none exhibited loss of reduction or complications requiring revision surgery. No patient developed synovitis of the elbow joint or suffered electrolytic reactions when titanium implants were used concurrently.

CONCLUSION

Although there is still a paucity of literature available on the subject and further studies are required, magnesium implants appear to be a feasible tool for fixation of peri-articular elbow fractures with promising results in our series.

Key Words: Magnesium screw; Fracture; Peri-articular; Elbow

©The Author(s) 2024. Published by Baishideng Publishing Group Inc. All rights reserved.

Core Tip: Magnesium implants can be a useful tool in fixation of peri-articular elbow fractures with promising results.

Citation: Fang C, Premchand AXR, Park DH, Toon DH. Peri-articular elbow fracture fixations with magnesium implants and a review of current literature: A case series. *World J Orthop* 2024; 15(3): 215-229

URL: <https://www.wjgnet.com/2218-5836/full/v15/i3/215.htm>

DOI: <https://dx.doi.org/10.5312/wjo.v15.i3.215>

INTRODUCTION

In recent years, the use of Magnesium alloy implants in orthopaedic surgeries have gained renewed popularity. Apart from being bioabsorbable, negating the need for implant removal, magnesium also has good osteoconductive properties [1-4]. Biomechanically, it exhibits greater biomechanical strength than any pre-existing polymers, and reduces the stress-shielding effect associated with titanium and steel implants as it has a Young's modulus closer to bone[4].

Currently, the main utility of magnesium implants in the orthopaedic community is within the foot and ankle community where satisfactory results have been reported with its utility in forefoot osteotomies[5-7]. However, its utility in the setting of orthopaedic trauma has been steadily increasing[8].

Our study aims to document our clinical and radiographical outcomes using magnesium implants to treat peri-articular elbow fractures. To our knowledge, our study is the first study analyzing outcomes in radial head and coronoid fractures in the English literature.

MATERIALS AND METHODS

This study is a retrospective case series analyzing the clinical and radiographical outcomes of patients with peri-articular fractures of the upper limb, specifically the radial head, coronoid and capitellum, that were surgically treated with bioabsorbable magnesium screws (MAGNEZIX®, Syntellix AG, Hanover, Germany).

Domain specific review board approval was obtained prior to initiation of the study. Patients were recruited over the duration of 8 months from May 2019 to December 2019. All patients recruited were adult aged 21 years old and above, with isolated, closed peri-articular fractures of the elbow and no neurovascular compromise presenting to our institution. Pre-operatively, all patients were counselled regarding the usage of the magnesium implants and the risks and benefits of surgical fixation were extensively explained.

Surgical technique

All patients recruited underwent surgery performed by one of the senior authors of this study with a standardised surgical technique for implantation of the magnesium compression screws in accordance with the manufacturers recommendation. Intra-operatively, after temporary reduction with Kirschner-wires, a cannulated drill was utilised to create a pilot hole before the main hole is drilled and the screw inserted over the Kirschner-wire. Care was taken not to apply excessive torque during screw insertion.

Post-operative regime

Post-operatively, all patients were started immediately on a progressive occupational therapy regime. Passive range of motion was allowed immediately post operatively followed by graduated progression to active range of motion within 2-3 wk. All patients had regular therapy visits post-operatively for supervised sessions. Patients underwent a standardised follow up regime with the primary surgeon at 2 wk, 4 wk, 6 wk, 3 months, 6 months and 1 year post-operatively. During each visit, clinical notes were taken for each patient documenting relevant history and physical exam findings. Two functional scores, namely the Mayo elbow performance score (MEPS) and disabilities of the arm, shoulder and hand (DASH) score was also recorded at each visit. All complications were recorded.

RESULTS

Our study studied a total of 5 patients with 6 fractures, 2 of the coronoid, 3 of the radial head and 1 of the capitellum. The mean age at the time of surgery was 54.6 years of age ranging from 34 to 76 years old, and the mean length of follow up was 11 months, ranging from 7 to 13 months.

Table 1 Results

Fracture sustained	Follow up	Clinical outcomes scores (At latest follow up)		ROM (Latest follow up)	Clinical outcomes
		Mayo score	DASH score		
67/F Bryan & Morrey Type 3 capitellum fracture	7 months	100 points	0.8 points	25-130 degrees; Full prono/supination	Pain free; Went back to work as a cleaner without issues
34/M Coronoid #: Regan and Morrey type 2	11 months	100 points	0.8 points	10-130 degrees; Full prono/supination	Pain free; Went back to recreational exercise (football)
58/M Comminuted olecranon #: Radial head #: Mason type 2	13 months	100 points	0.9 points	0-150 degrees; 80 degrees prono/supination	Went back to work as a machine operator
38/M Radial head #: Mason type 2	13 months	100 points	0.8 points	0-150 degrees; Full prono/supination	Pain free; Back to Gym work including weights
76/M Terrible triad injury; Coronoid #: Regan and Morrey type 3; Radial head #: Mason type 4	11 months	100 points	10.3 points	10-130 degrees; Full prono/supination	Posterior elbow pain (Olecranon bursitis) – Resolved; Pain free from six months onwards

DASH: Disabilities of the arm, shoulder and hand.

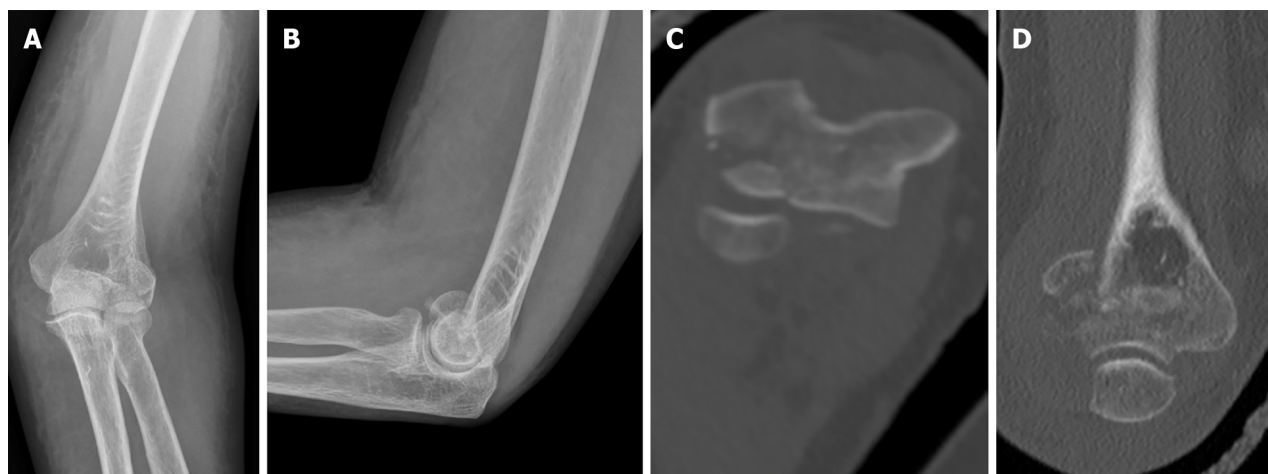

Figure 1 Injury films on presentation depicting a left Bryan and Morrey type 3 capitellar fracture. A-D: Anterior posterior (A) and lateral (B) radiographs, axial (C) and coronal (D) computer tomography cuts depicting the injury.

All 5 patients exhibited good short to medium term clinical outcomes with a mean MEPS of 100 points and a mean DASH score of 2.72 points (0.8–10.3 points) at final follow up. No fractures exhibited any loss of reduction at the point of final follow up, and there were no complications or revision surgeries required for all 5 patients. Notably, none of our patients developed any clinical signs or symptoms of synovitis of the elbow joint (Table 1).

Patient one

Patient one is a 67 year old, functionally active chinese lady with no past medical history who sustained a closed left Bryan and Morrey type 3 capitellar fracture after a mechanical fall from standing height (Figure 1).

Access to the elbow was obtained *via* a mid-axial approach after which fracture reduction was achieved under direct visualization and held with Kirschner wires. Four magnesium screws were then used to compress the fracture site before a 4 hole 1/3 tubular plate was cut and applied in a buttress fashion. Clinically, the patient was pain free by 2 wk and had obtained 25 to 130 degrees of elbow flexion and full prono/supination by the 6 months. At the point of latest follow up, she reported good functional outcomes scores, with a MEPS of 100 points and a DASH score of 0.8. She had also returned to her full time work as a cleaner without any difficulties.

One magnesium screw was noted to have broken at the 6 wk radiograph. However, there was no loss of fracture reduction and the fracture was noted to have united at 6 months post-op (Figure 2).

Patient two

Patient two is a 34 year old male with no significant past medical history who sustained an isolated closed Regan and

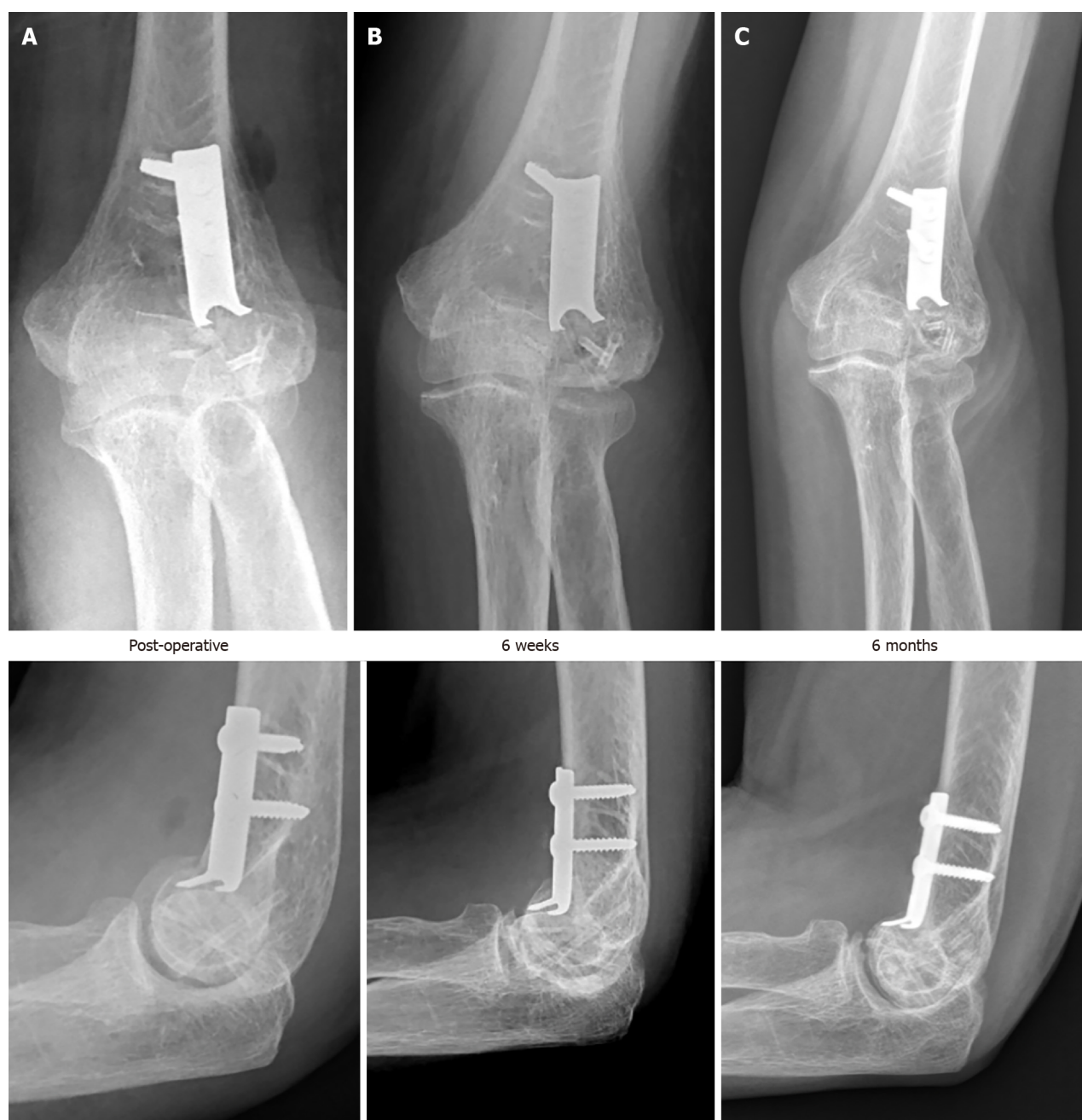

Figure 2 Post operative radiographs depicting progress. A-C: Radiographs immediately post op (A), at 6 wk (B) and at 6 months (C).

Morrey type 2 coronoid fracture. Intra-operatively the coronoid fracture was fixed using a Zimmer ALPS Coronoid plate applied in a buttress fashion and a Magnezix CS 2.7 mm compression screw for compression (Figure 3).

Fracture union was noted at 6 wk post-op, and by 6 months, he had obtained 10-130 degrees of elbow flexion, and managed to return to full work duties as well as recreational football. At the point of final follow up, he reported satisfactory functional outcome scores with a MEPS of 100 and a DASH score of 0.8 points (Figure 4).

Patient three

Patient three is a 58 year old functionally well lady with a significant past medical history of poorly controlled diabetes mellitus and hyperlipidaemia who sustained a closed Monteggia - variant fracture dislocation after a fall from standing height. (Figure 5) Pre - operatively, a computer tomography scan confirmed a comminuted olecranon fracture with a large ulnar butterfly fragment as well as a comminuted radial head fracture.

Intra-operatively, the olecranon fracture was fixed with traditional titanium implants (Zimmer ALPs system) whilst the radial head fracture was fixed with two Magnezix CS 2.7 mm headless compression screws.

By 6 wk post-operatively, she had obtained 10 to 130 degrees of elbow flexion, as well as 60 degrees and 50 degrees of pronation and supination respectively. At 6 months, this further improved to 0 to 150 degrees of flexion and 80 degrees of pronation and supination. At this point, she was pain free, and had returned to work as a machine operator without any difficulties. Fracture union was noted.

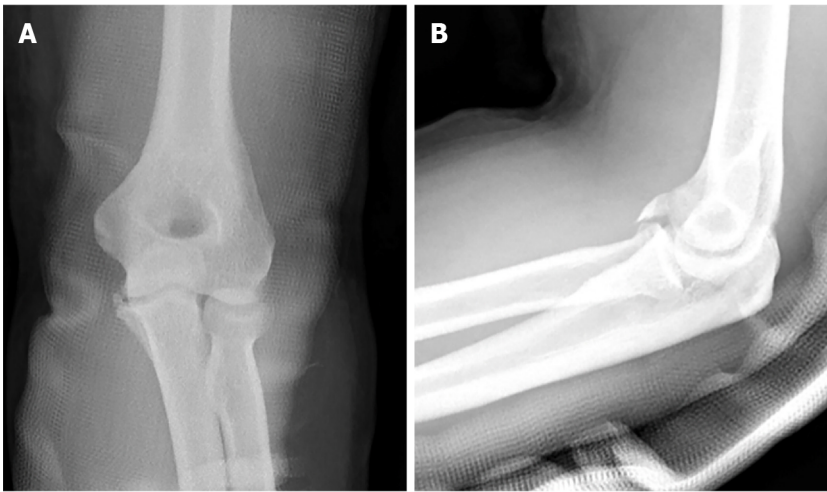


Figure 3 Injury films on presentation depicting a R&M type 2 coronoid fracture. A and B: Anterior – posterior (A) and lateral (B) views.

Radiographically, peri-implant radiolucencies became prominent around the 6 wk post-op, and gradually reduced up to the point of latest follow up at 1 year. At 6 months post-op, we noted breakage of one of the radial head screws, and by the 1 year post-op, the embedded magnesium implants were barely visible on the lateral view (Figure 6).

Patient four

Patient four is a 38 year old male with no significant past medical history who sustained a closed Mason type 2 radial head fracture after a fall from a height (Figure 7).

Intra-operatively, two Magnezix CS 2.7 mm screws were utilised for fixation and compression of the fracture. Full elbow range of motion was confirmed intra-operatively prior to closure (Figure 8).

By 6 wk post-op, he had obtained 0 to 150 degrees of elbow flexion and 90 degrees of both pronation and supination, almost identical to the contralateral limb (Figure 9).

Radiographically we noted the appearance of peri-implant radiolucencies at 2 wk post-operatively, which became more pronounced by 4 wk before reducing significantly by 6 months and almost completely disappearing by 1 year. This observation is in keeping with gradual dissipation of hydrogen produced as a result of magnesium degradation. The distal tip of one of the Magnezix CS screws was noted to have broken off at 6 months post-operatively, during which time the fracture had already healed with no loss of fracture reduction. At 1 year, the broken screw tip had resorbed and was barely visible (Figure 10).

At the point of last follow up, the patient remained clinically asymptomatic and reported no perceivable differences functionally with the contra-lateral limb with a MEP of 100 points and a DASH score of 0.8 points.

Patient five

Patient five is a 76 year old lady with good pre-morbid function who sustained a closed terrible triad injury (Regan and Morrey type 3 coronoid fracture and Mason 4 radial head fracture) (Figure 11).

Intra-operatively, both the radial head fracture and the coronoid fracture were fixed with a combination of one titanium (Medartis 2.0/2.5 mm Low Compression Screw) and one Magnezix CS 2.7 mm screw (Figure 12).

At 6 months post-op, the patient was noted to have elbow flexion from 10–130 degrees and full pronation/supination which was identical to the contra-lateral limb. At the point of last follow up, she was pain free and was independent in all activities of daily living, and reported a MEPS of 100 points and a DASH score of 10.3 points (Figure 13).

In similar fashion to patient two, at the 4 wk post-op, radiolucencies were noted over both Magnezix CS screws which reduced significantly by 6 months and almost completely disappeared by 1 year. Neither of screws had broken at 1 year post-op (Figure 14).

Radiographical findings

In our series of patients, we noted the presence of radiolucencies as early as 2 wk post-operatively, which consistently became more pronounced by 4 to 6 wk post-operatively. Significant reduction in radiolucencies were noted by 6 months post-operatively, and radiolucencies were minimal and barely visible by 1 year post-operatively.

At the one year mark post-operatively, we noted screw breakage in 3 out of 6 fractures, of which 2 occurred at 6 months post-operatively and 1 occurred within the first 6 wk. Two of these breakages (Patient three and four) occurred along the distal screw threads, whilst in the remaining case (Patient one), screw breakage occurred before the 6 wk post-operatively proximally near the screw head. We postulate that a potential reason for the earlier breakage is due to the longer length of screw used.

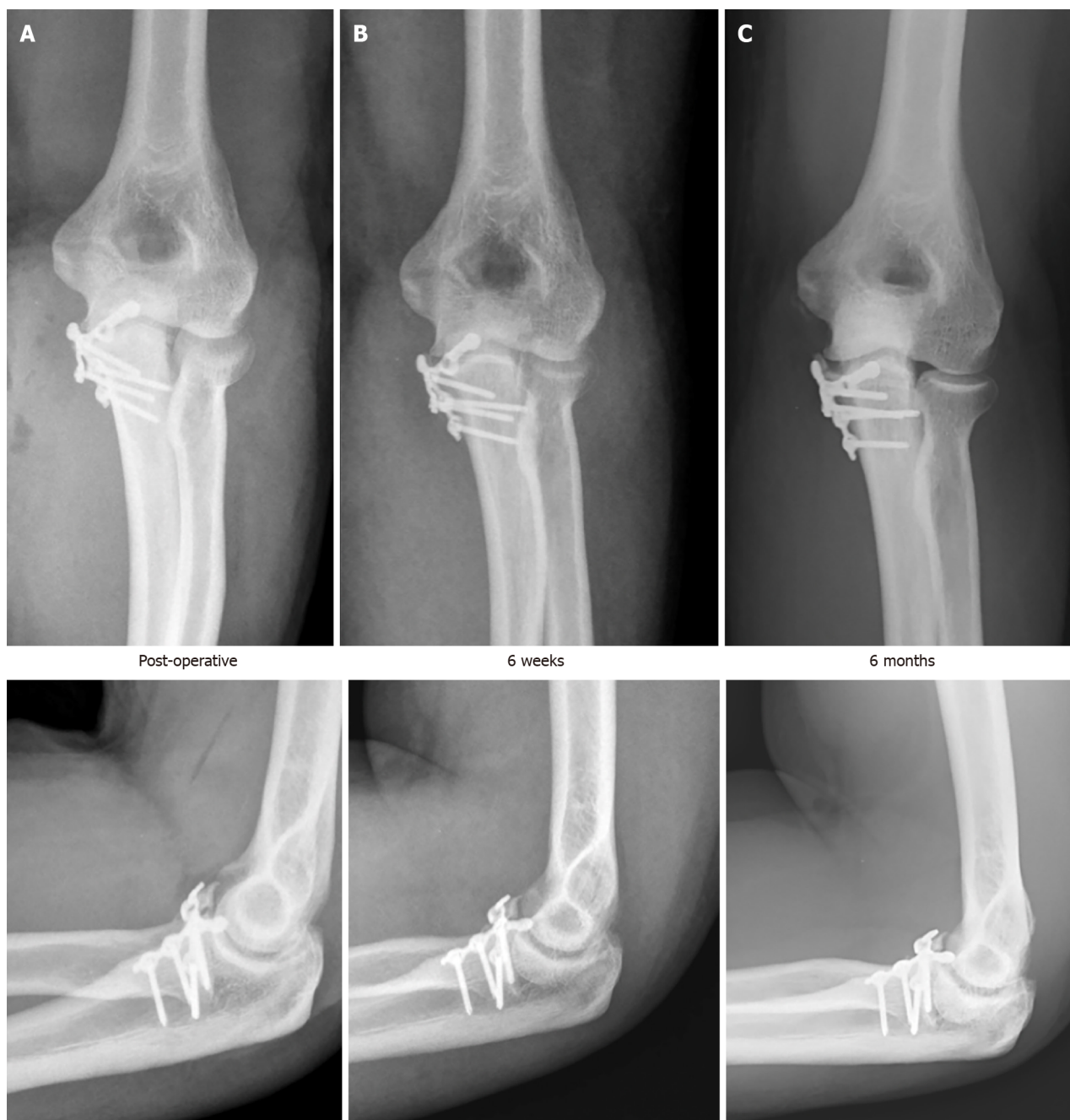

Figure 4 Post operative radiographs depicting progress. A-C: Radiographs immediately post op (A), at 6 wk (B) and at 6 months (C).

DISCUSSION

Magnesium implants were first described in an orthopaedic setting in 1906 by Lambotte[9] who then utilized a magnesium plate to treat a seventeen-year-old child with pseudoarthrosis and severe malalignment of the distal third of the tibia. Despite that, its popularity never took off due to two key reasons. Firstly, rapid corrosion of magnesium inadvertently resulted in pre-mature implant failure and secondly, contact of the magnesium implant with other metals resulted in a florid electrochemical reaction as Lambotte found out in his index experiment after his patient developed severe pain and extensive subcutaneous gas cavities post operatively due to the aforementioned reaction[9].

The advent of technologically advanced Magnesium Alloys, such as MgYREZr which solved the problem of rapid magnesium degradation, has prompted a re-birth in the utilization and popularity of these implants when the first commercially available Conformité Européenne approved magnesium implant became available in 2013 (MAGNEZIX® compression screw from Syntellix).

During this period of time, the vast majority of clinical studies published were in the setting of forefoot deformity correction surgeries such as chevron osteotomies of the first metatarsal, with only a handful of clinical studies documenting its use in the orthopaedic trauma setting.

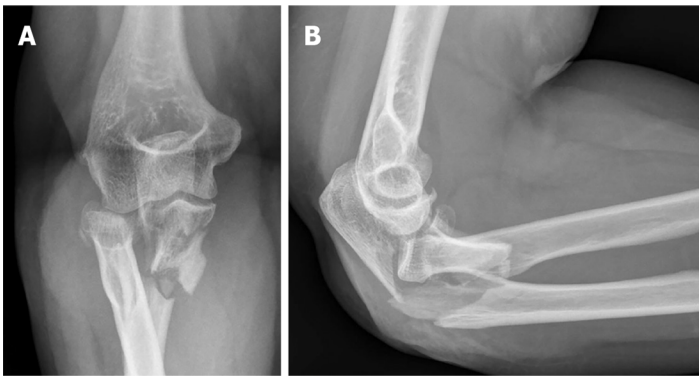


Figure 5 Injury films on presentation depicting a Monteggia variant type fracture. A and B: Anterior – posterior (A) and lateral (B) views.

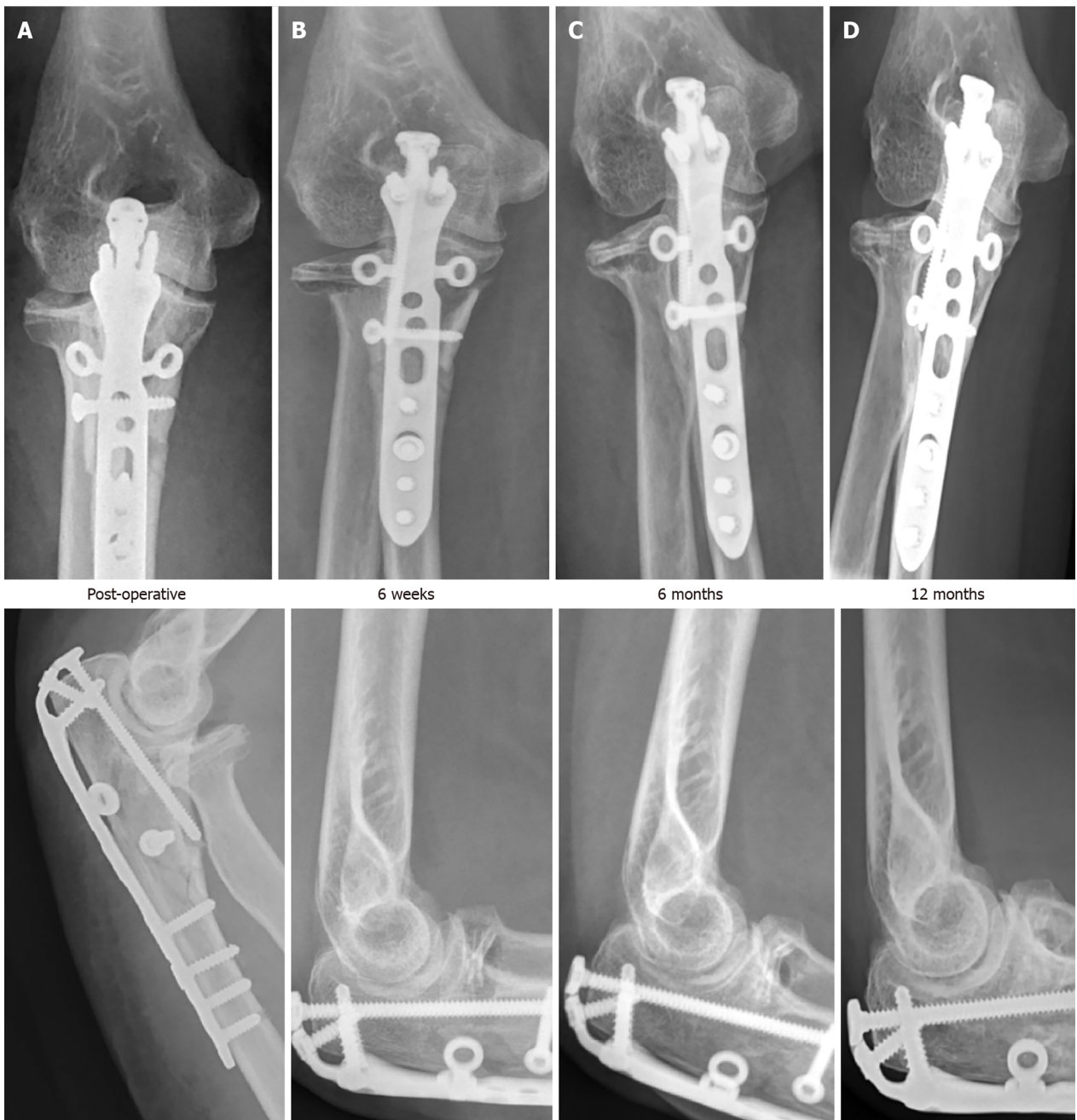

Figure 6 Post operative radiographs depicting progress. A-D: Radiographs immediately post op (A), at 6 wk (B), 6 months (C) and 12 months (D).

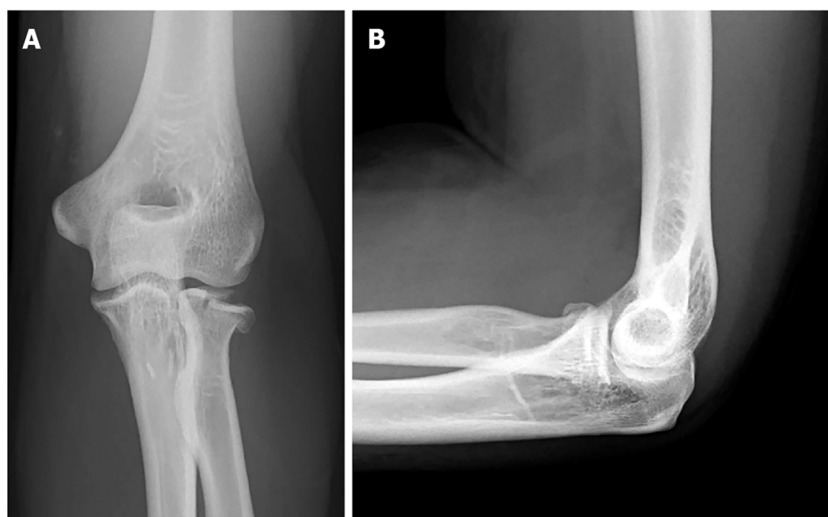


Figure 7 Injury films on presentation depicting a Mason type 2 radial head fracture. A and B: Anterior – posterior (A) and lateral (B) views.

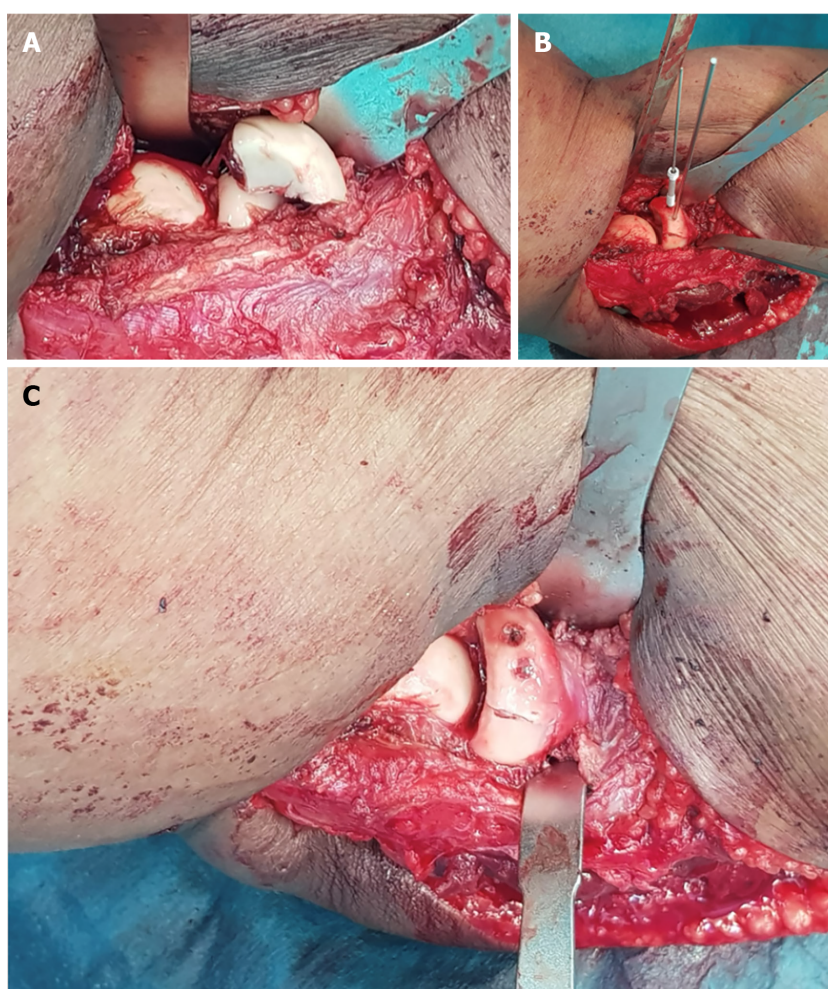


Figure 8 Intra-operative photos. A: Initial fracture configuration; B and C: Reduction and fixation with cannulated magnesium screws (B) and finally the end result (C).

In our review of the existing literature, we identified a total of 10 existing studies[10-19] reporting on the utilization of magnesium implants in the setting of orthopaedic trauma. Of these 10 studies, only 1 reported unsatisfactory outcomes [13] and did not recommend the use of magnesium implants, with 1 study still ongoing[15] (Table 2).

In fractures involving the elbow, Biber *et al*[10] and Aktan *et al*[11] both reported positive results utilizing magnesium implants intra-articular distal humerus fractures. Biber's case report documented the utility of the Magnezix CS



Figure 9 Post – operative range of motion at six wk post-operatively. A: Elbow extension; B: Flexion; C: External rotation; D: Internal rotation.

cannulated compression screw in a patient with a prior radial head replacement who suffered a capitellar fracture and Aktan *et al*[11] documented their experience utilizing two magnesium compression screws for reduction of the distal humerus articular surface in a patient with a distal humerus fracture. Both patients reported successful results with complete fracture union and functional elbow range of motion at the time of latest follow up.

Although there have been reports of magnesium screws being utilized for fractures of the phalanges mentioned, we were unable to find any case reports or studies in the English literature. Apart from Turan *et al*[12] case series documenting successful outcomes in two radial styloid fractures, the remaining existing studies in the setting of hand trauma primarily pertain to its utility in scaphoid fractures. This is natural as the Magnezix CS screw is based on a Herbert screw design (variable pitch, headless, cannulated design) which was originally developed for use in compressive osteosynthesis of scaphoid fractures[3].

In Meier *et al*'s 2016 review, a single magnesium compression screw was used for fixation of various scaphoid fractures [13]. Although all patients eventually exhibited excellent wrist functional outcome scores 1 year post-operatively and all fractures eventually consolidated, he observed significant osteolysis and bone cysts in 3 out of 5 patients which resulted in a significant delay of around six months before sufficient consolidation occurred to allow return to physical work, and hence did not recommend its use in scaphoid fractures. Conversely, Grieve *et al*[14] documented positive results in his series of 3 scaphoid fractures. At present, a multi-centre, randomized control trial comparing outcomes of scaphoid fractures treated with magnesium and titanium screws by Könneker *et al*[15] is ongoing (stated to conclude by late 2020) and will hopefully shed more light on the topic.

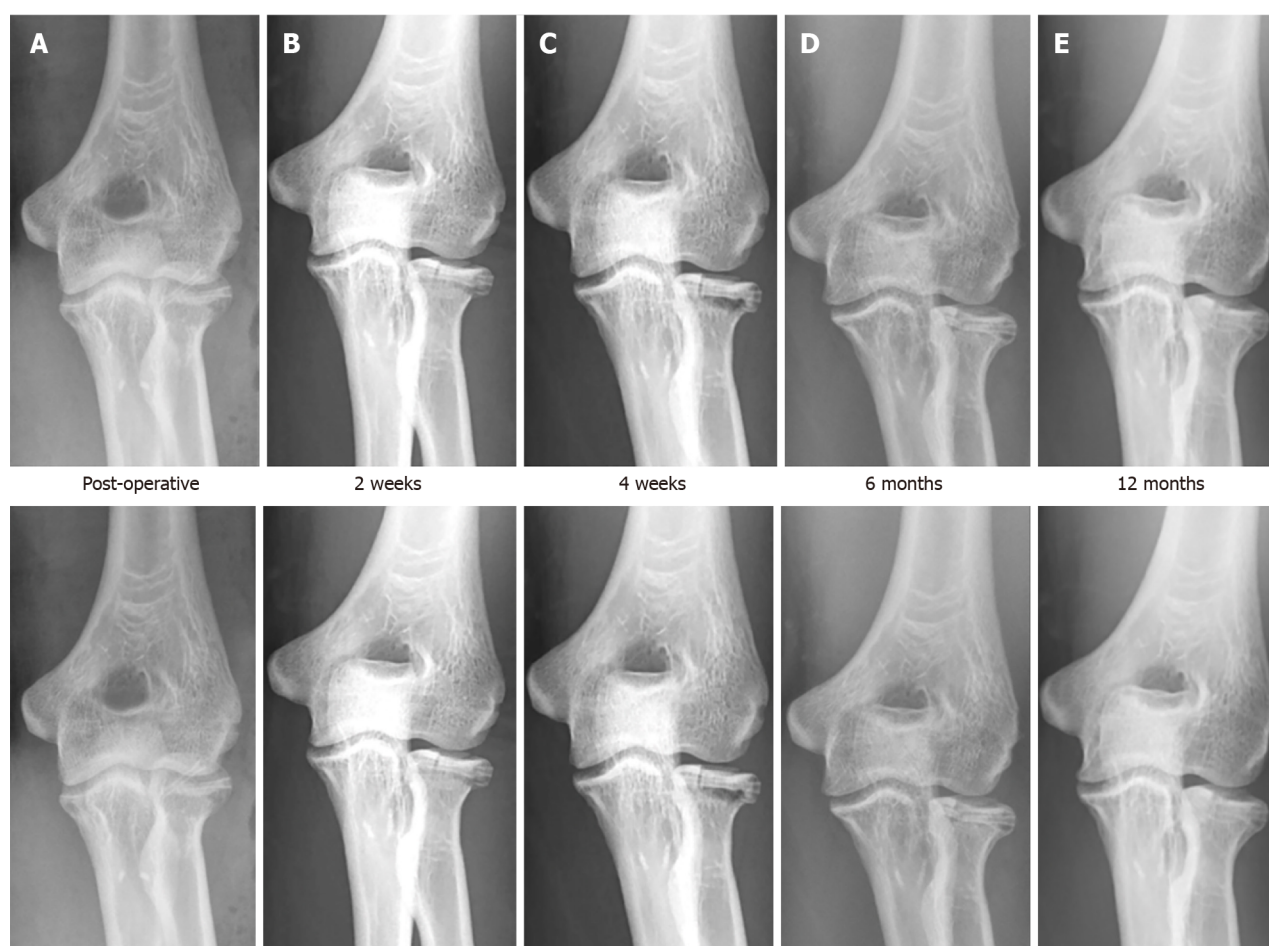


Figure 10 Post operative radiographs. A-E: Radiographs immediately post op (A), at 2 weeks (B), 4 wk (C), 6 months (D) and 12 months (E).

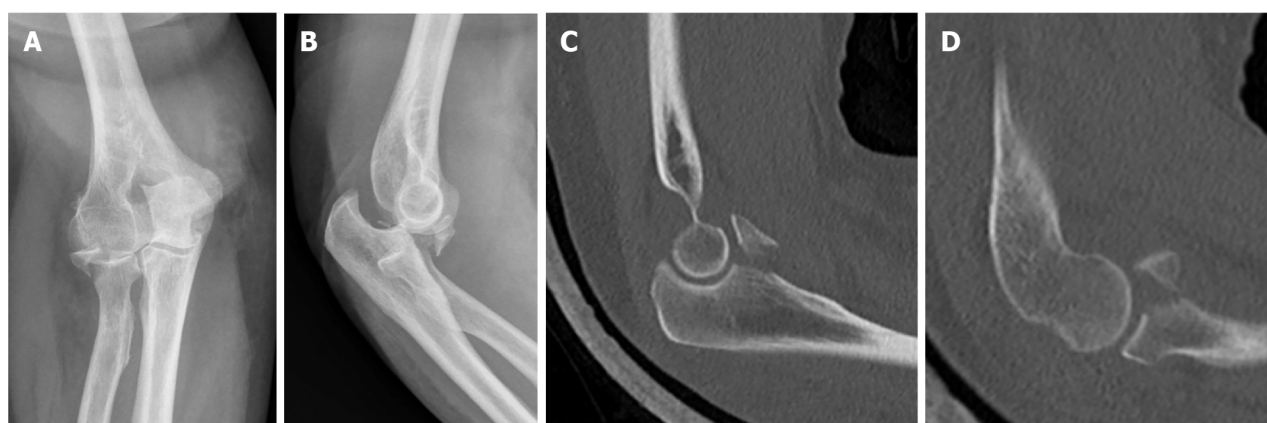


Figure 11 Injury films on presentation depicting a terrible triad fracture. A-D: Anterior posterior (A) and lateral (B) radiographs, sagittal computer tomography cuts showing coronoid fracture (C) and radial head fracture (D).

In fractures involving the lower limb, there is existing literature documenting outcomes when used as an adjunct in young neck of femur fractures[16], tibial spine fractures[17] in paediatric patients, as well as isolated lateral[18] and medial malleolus[19] fractures. All reported positive clinical and radiological outcomes.

Despite the multiple benefits[1-4,20-24] of these magnesium implants (Table 3) and the emergence of these aforementioned studies citing positive outcomes, it is important to also highlight several considerations when opting to utilize these implants.

The first important consideration, and arguably the biggest disadvantage of utilizing magnesium implants are the expected production of peri-implant lucencies due to hydrogen gas produced during the process of magnesium degradation. Clinicians may find it difficult to differentiate this from post-operative complications such as infection or loosening of implants. Although studies have demonstrated that these radiolucencies do gradually disappear from

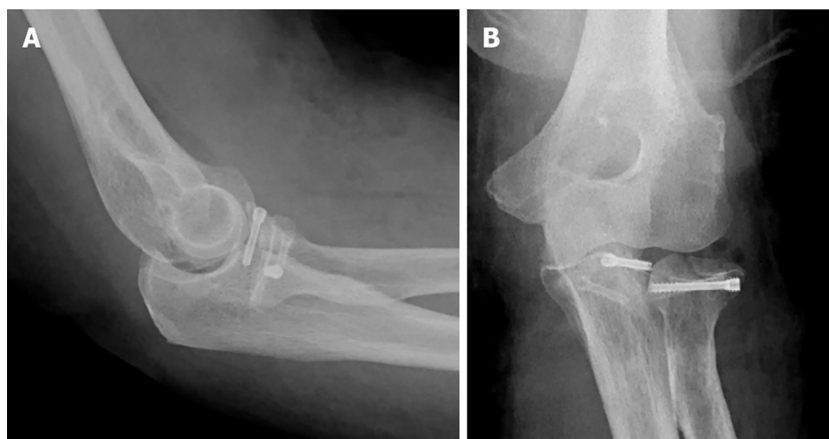


Figure 12 Immediate post-operative radiographs. A and B: Anterior – posterior (A) and lateral (B) views.




Figure 13 Post-operative range of motion at six months post operatively. A and B: Elbow flexion (A) and extension (B).

anywhere between 3 to 17 months[3], the presence of persistent radiolucencies (which appear as early as 2 wk post-operatively as seen in our series), may cause anxiety to both the clinician and the patient.

Secondly, magnesium implants are also known to be associated with osteolysis[24], which was postulated to occur when the body is unable to adequately clear the products of magnesium degeneration from the implantation site, leading to the migration of osteoclasts to the implantation site. This, coupled with the aforementioned issue of expected post-operative radiolucencies is particularly concerning given the fact that symptoms of osteolysis do not usually occur[25] until there is sufficient bone loss to result in aseptic loosening of the implant, by which point implant failure is likely to occur.

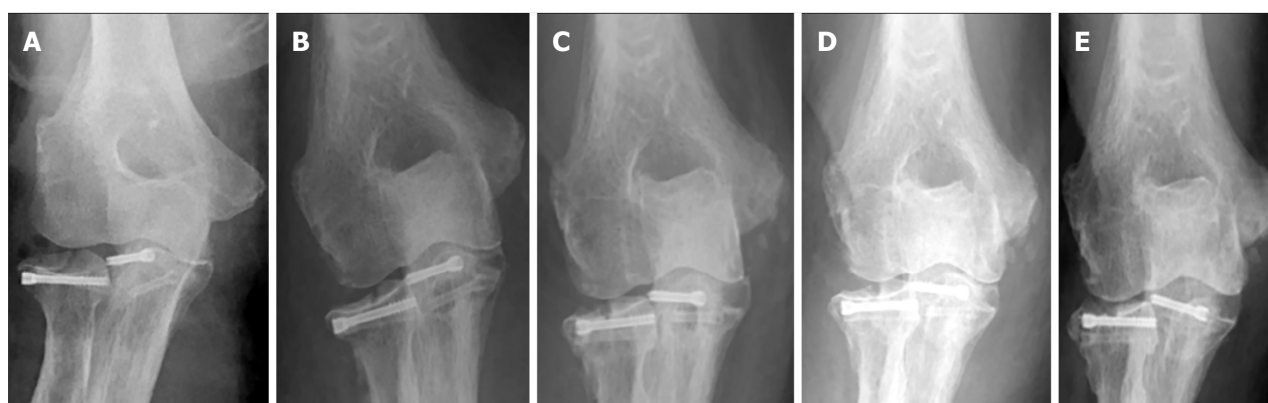
Comparison with conventional titanium implants

Our review of the literature identified 3 studies[5,26,27] comparing outcomes in magnesium and conventional implants. May *et al*'s study recruited a total of 48 patients with medial malleolus fractures undergoing compression screw fixation of which 23 had magnesium screws implanted whilst 25 had conventional screws implanted[26]. In his study, with a minimum follow up of 1 year, no differences in clinical outcomes between both groups were noted, with similar AOFAS clinical outcome scores, and a 100% union rate in both groups. Complication rates were also similar with no deep infection or osteomyelitis noted in both groups. However, 5 patients with conventional titanium implants, compared to

Table 2 Literature review

Fracture	Ref. and Journal	Methodology	Results
Elbow fractures – Capitellum fracture	Biber <i>et al</i> [10], 2016; <i>Case Reports in Orthopedics</i>	Case report of 73 yr old female with a humerus capitellum fracture	Successful results with complete fracture union and full elbow range of motion
Elbow fractures – Distal humerus fractures (Lateral column)	Aktan <i>et al</i> [11], 2018; <i>Cureus</i>	Case report of 50 yr old male with bi-column distal humerus fracture	Successful results with complete fracture union at four months, and elbow range of motion from 5-130 degrees
Hand fractures – Scaphoid fractures	Könneker <i>et al</i> [15], 2019	Multi-centre RCT: 190 patients	Pending
Hand fractures – Scaphoid fractures	Meier <i>et al</i> [13], 2016	Case series of five patients with acute scaphoid fractures treated with a single Magnesium screw	Unsatisfactory results with 3 out of 5 patients experiencing extensive osteolysis and bone cyst; All had good wrist scores and fracture union eventually
Hand fractures – Scaphoid fractures	Grieve <i>et al</i> [14], 2017; <i>Hand Surg Rehab</i>	Case series; 3 Scaphoid fractures (Two acute and one revision); 3 Intercarpal fusions	One acute scaphoid fracture lost to follow up; All other cases united except 1 case (partial union at twelve weeks)
Hand fractures – Radial styloid fractures	Turan <i>et al</i> [12]; <i>Thieme Medical Publishers</i>	Case series; 2 patients with isolated radial styloid fractures	Good fracture union in both patients with no complications
Young displaced neck of femur fractures	Yu <i>et al</i> [16], 2015; <i>BMC, Musculoskeletal disorders</i>	Case series of 19 patients; Mg screws used to fix vascularized iliac bone graft	Successful results with 94.7% union
Tibial spine avulsion fractures	Gigante <i>et al</i> [17], 2018; <i>Injury</i>	Case series of three paediatric patients treated surgically with Magnesium screws	Successful results with all three patients obtaining excellent functional recovery
Ankle fractures – Isolated lateral malleolus	Acar <i>et al</i> [18], 2018; <i>Cureus</i>	Case report of a 19 yr old female with an isolated Weber A fracture	Successful results with complete fracture union at 8 wk, AOFAS score 100 points at 2 yr
Ankle fractures – Medial malleolar fractures	Kose <i>et al</i> [19], 2018; <i>Archives of Orthopaedic and Trauma Surgery</i>	Case series of 11 medial malleolar fractures (Isolated, Bi-malleolar or Tri-malleolar)	Successful results with 100% fracture union, Mean AOFAS score of 94.9 at time of final follow up

RCT: Randomised controlled trial.

**Figure 14 Post operative radiographs.** A-E: Radiographs immediately post op (A), at 4 weeks (B), 4 months (C), 6 months (D) and 12 months (E).

none in the magnesium screw group required removal of implants for symptomatic hardware, highlighting the key benefit of using magnesium implants.

The remaining two studies recruited patients undergoing distal metatarsal osteotomies for hallux valgus. Acar *et al*[5] retrospectively compared two groups of 17 patients undergoing surgery with both implants, whilst Plaass *et al*[27] conducted a randomized control trial of 26 patients. Both studies reported similar therapeutic outcomes with regards to functional and radiographical outcomes, with no differences in complication rates or union rates.

Although the literature appears to suggest that these bioabsorbable magnesium screws provide similar efficacy to conventional implants, interpreting the data must be performed with caution at this juncture due to the small collective number of patients analysed, and the heterogeneity of clinical indications amongst studies. In our search of the literature, there were no comparative studies analyzing the efficacy of both implants when used in peri-articular fractures around the elbow, with only two case reports[10-11] available in the literature, similarly documenting successful outcomes as reported in our series.

Table 3 Magnesium implants pros & cons

Pros	Cons
Bioabsorbable and osteoconductive[1,20]; Higher stability than existing polymers[21,22]; Similar stiffness to bone – less stress shielding[4]; Good biocompatibility[1-4]; Minimal artefacts on MRI and CT[23]	Production of hydrogen gas creates peri-implant radiolucencies[3]; Risk of osteolysis[3,24]; Unproven long term track record

CT: Computed tomography; MRI: Magnetic resonance imaging.

Limitations of study

Limitations of our study include a relatively small sample size although our case series represents one of the largest case series documenting the outcomes of magnesium screws in upper limb fractures. Furthermore, as there are few other studies on the topic, comparing and analysing our outcomes is challenging. Further studies are needed to evaluate the topic further such as a study with a control group.

CONCLUSION

Our case series serves to add to the paucity of literature on the utilization of magnesium screws in upper limb fractures. In our series, all patients exhibited good short to medium term clinical outcomes with no complications or revision surgeries required, and significantly none of our patients developed any clinical signs or symptoms of synovitis or allergic reactions. Although further larger studies with longer follow-ups are required before the implant can be unequivocally proven superior or equal to conventional existing implants, these implants appear to be a promising innovation for the modern orthopaedic surgeon.

ARTICLE HIGHLIGHTS

Research background

Larger trials such as randomized control trials with larger patient numbers should be conducted.

Research motivation

Bio-absorbable magnesium screws can be used in peri-articular fractures of the elbow.

Research objectives

All fractures healed successfully and no patient required removal of implants or suffered any major complications.

Research methods

Our paper was based on a retrospective case series design. Intra-operatively, a standardized surgical technique was utilized for insertion of the magnesium implants. Post – operatively, clinic visits were standardized and physical exam findings, functional scores, and radiographs were obtained at each visit. All complications were recorded.

Research results

Our findings will help clinicians in two main areas. Firstly, clinicians considering using the implant for their patients have a detailed case series to refer to. Secondly, clinicians considering research on the topic have a large sample size (relative to the existing literature) to aid in conducting future studies especially systematic reviews or meta-analysis.

Research conclusions

To ascertain if bio-absorbable magnesium screws are clinically efficacious in treating peri-articular elbow fractures.

Research perspectives

Magnesium screws are gaining popularity in orthopaedic trauma surgery. No case series has been published documenting its use in peri-articular fractures of the elbow.

FOOTNOTES

Author contributions: Fang C contributed to data collection, statistical analysis and drafting of manuscript; Premchand A and Park DH contributed to invaluable guidance and providing post-operative care and documentation for post-operative patients; Toon DH contributed to performing the surgeries for the patients and overseeing all work on the original article.

Institutional review board statement: Our study was approved by our institutions local domain specific review board prior to commencement. All ethical protocols were followed.

Informed consent statement: As the study was retrospective and anonymous, no formal informed consent was deemed necessary and this was waived. Informal consent and verbal consent was documented in our hospitals electronic records system as per instruction by our IRB.

Conflict-of-interest statement: All authors declare that they have no conflict of interest.

Data sharing statement: All data collection and sharing was performed according to the methodology set out in the domain specific review board application.

STROBE statement: The authors have read the STROBE Statement – checklist of items, and the manuscript was prepared and revised according to the STROBE Statement – checklist of items.

Open-Access: This article is an open-access article that was selected by an in-house editor and fully peer-reviewed by external reviewers. It is distributed in accordance with the Creative Commons Attribution NonCommercial (CC BY-NC 4.0) license, which permits others to distribute, remix, adapt, build upon this work non-commercially, and license their derivative works on different terms, provided the original work is properly cited and the use is non-commercial. See: <https://creativecommons.org/licenses/by-nc/4.0/>

Country/Territory of origin: Singapore

ORCID number: Christopher Fang [0000-0003-1442-996X](https://orcid.org/0000-0003-1442-996X).

S-Editor: Liu JH

L-Editor: A

P-Editor: Li X

REFERENCES

- 1 **Waizy H**, Diekmann J, Weizbauer A, Reifenrath J, Bartsch I, Neubert V, Schavan R, Windhagen H. In vivo study of a biodegradable orthopedic screw (MgYREZr-alloy) in a rabbit model for up to 12 months. *J Biomater Appl* 2014; **28**: 667-675 [PMID: [23292720](https://pubmed.ncbi.nlm.nih.gov/23292720/) DOI: [10.1177/0885328212472215](https://doi.org/10.1177/0885328212472215)]
- 2 **Zhang E**, Xu L, Yu G, Pan F, Yang K. In vivo evaluation of biodegradable magnesium alloy bone implant in the first 6 months implantation. *J Biomed Mater Res A* 2009; **90**: 882-893 [PMID: [18618719](https://pubmed.ncbi.nlm.nih.gov/18618719/) DOI: [10.1002/jbm.a.32132](https://doi.org/10.1002/jbm.a.32132)]
- 3 **Kose O**. Magnesium (MgYREZr) bioabsorbable screws in orthopedic surgery, A narrative review, Military medicine worldwide, 2019. Available from: https://aleamed.eu/wp-content/uploads/2019/11/Köse_2019_Military_Medicine_Review.pdf
- 4 **Chakraborty Banerjee P**, Al-Saadi S, Choudhary L, Harandi SE, Singh R. Magnesium Implants: Prospects and Challenges. *Materials (Basel)* 2019; **12** [PMID: [30609830](https://pubmed.ncbi.nlm.nih.gov/30609830/) DOI: [10.3390/ma12010136](https://doi.org/10.3390/ma12010136)]
- 5 **Acar B**, Kose O, Turan A, Unal M, Kati YA, Guler F. Comparison of Bioabsorbable Magnesium versus Titanium Screw Fixation for Modified Distal Chevron Osteotomy in Hallux Valgus. *Biomed Res Int* 2018; **2018**: 5242806 [PMID: [30581858](https://pubmed.ncbi.nlm.nih.gov/30581858/) DOI: [10.1155/2018/5242806](https://doi.org/10.1155/2018/5242806)]
- 6 **Atkinson HD**, Khan S, Lashgari Y, Ziegler A. Hallux valgus correction utilising a modified short scarf osteotomy with a magnesium biodegradable or titanium compression screws - a comparative study of clinical outcomes. *BMC Musculoskelet Disord* 2019; **20**: 334 [PMID: [31319832](https://pubmed.ncbi.nlm.nih.gov/31319832/) DOI: [10.1186/s12891-019-2717-7](https://doi.org/10.1186/s12891-019-2717-7)]
- 7 **Choo JT**, Lai SHS, Tang CQY, Thevendran G. Magnesium-based bioabsorbable screw fixation for hallux valgus surgery - A suitable alternative to metallic implants. *Foot Ankle Surg* 2019; **25**: 727-732 [PMID: [30321917](https://pubmed.ncbi.nlm.nih.gov/30321917/) DOI: [10.1016/j.fas.2018.09.001](https://doi.org/10.1016/j.fas.2018.09.001)]
- 8 **Nabiyouni M**, Brückner T, Zhou H, Gbureck U, Bhaduri SB. Magnesium-based bioceramics in orthopedic applications. *Acta Biomater* 2018; **66**: 23-43 [PMID: [29197578](https://pubmed.ncbi.nlm.nih.gov/29197578/) DOI: [10.1016/j.actbio.2017.11.033](https://doi.org/10.1016/j.actbio.2017.11.033)]
- 9 **Witte F**. The history of biodegradable magnesium implants: a review. *Acta Biomater* 2010; **6**: 1680-1692 [PMID: [20172057](https://pubmed.ncbi.nlm.nih.gov/20172057/) DOI: [10.1016/j.actbio.2010.02.028](https://doi.org/10.1016/j.actbio.2010.02.028)]
- 10 **Biber R**, Pauser J, Geflein M, Bail HJ. Magnesium-Based Absorbable Metal Screws for Intra-Articular Fracture Fixation. *Case Rep Orthop* 2016; **2016**: 9673174 [PMID: [27833771](https://pubmed.ncbi.nlm.nih.gov/27833771/) DOI: [10.1155/2016/9673174](https://doi.org/10.1155/2016/9673174)]
- 11 **Aktan C**, Ertan MB, Turan A, Kose O. Fixation of Small Osteochondral Fragments in a Comminuted Distal Humerus Fracture with Magnesium Bioabsorbable Screws: A Case Report. *Cureus* 2018; **10**: e3752 [PMID: [30820372](https://pubmed.ncbi.nlm.nih.gov/30820372/) DOI: [10.7759/cureus.3752](https://doi.org/10.7759/cureus.3752)]
- 12 **Turan A**, Kati YA, Acar B, Kose O. Magnesium Bioabsorbable Screw Fixation of Radial Styloid Fractures: Case Report. *J Wrist Surg* 2020; **9**: 150-155 [PMID: [32257617](https://pubmed.ncbi.nlm.nih.gov/32257617/) DOI: [10.1055/s-0039-1685489](https://doi.org/10.1055/s-0039-1685489)]
- 13 **Meier R**, Panzica M. First results with a resorbable MgYREZr compression screw in unstable scaphoid fractures show extensive bone cysts. *Handchir Mikrochir Plast Chir* 2017; **49**: 37-41 [DOI: [10.1055/s-0042-121416](https://doi.org/10.1055/s-0042-121416)]
- 14 **Grieve P**, O'Carroll S, Albastaki O. Six cas de série de patients de Magnezix®. Une vis métallique absorbable pour la fixation de la fracture du carpe et des fusions entre les carpes. *Hand Surg Rehab* 2017; **36**: 488-489 [DOI: [10.1016/j.hansur.2017.10.184](https://doi.org/10.1016/j.hansur.2017.10.184)]
- 15 **Könneker S**, Krockenberger K, Pieh C, von Falck C, Brandewiede B, Vogt PM, Kirschner MH, Ziegler A. Comparison of SCAPHOID fracture osteosynthesis by MAGnesium-based headless Herbert screws with titanium Herbert screws: protocol for the randomized controlled SCAMAG clinical trial. *BMC Musculoskelet Disord* 2019; **20**: 357 [PMID: [31387574](https://pubmed.ncbi.nlm.nih.gov/31387574/) DOI: [10.1186/s12891-019-2723-9](https://doi.org/10.1186/s12891-019-2723-9)]
- 16 **Yu X**, Zhao D, Huang S, Wang B, Zhang X, Wang W, Wei X. Biodegradable magnesium screws and vascularized iliac grafting for displaced femoral neck fracture in young adults. *BMC Musculoskelet Disord* 2015; **16**: 329 [PMID: [26527162](https://pubmed.ncbi.nlm.nih.gov/26527162/) DOI: [10.1186/s12891-015-0790-0](https://doi.org/10.1186/s12891-015-0790-0)]

- 17 **Gigante A**, Setaro N, Rotini M, Finzi SS, Marinelli M. Intercondylar eminence fracture treated by resorbable magnesium screws osteosynthesis: A case series. *Injury* 2018; **49** Suppl 3: S48-S53 [PMID: [30415669](#) DOI: [10.1016/j.injury.2018.09.055](#)]
- 18 **Acar B**, Unal M, Turan A, Kose O. Isolated Lateral Malleolar Fracture Treated with a Bioabsorbable Magnesium Compression Screw. *Cureus* 2018; **10**: e2539 [PMID: [29951346](#) DOI: [10.7759/cureus.2539](#)]
- 19 **Kose O**, Turan A, Unal M, Acar B, Guler F. Fixation of medial malleolar fractures with magnesium bioabsorbable headless compression screws: short-term clinical and radiological outcomes in eleven patients. *Arch Orthop Trauma Surg* 2018; **138**: 1069-1075 [PMID: [29696362](#) DOI: [10.1007/s00402-018-2941-x](#)]
- 20 **Liu C**, Ren Z, Xu Y, Pang S, Zhao X, Zhao Y. Biodegradable Magnesium Alloys Developed as Bone Repair Materials: A Review. *Scanning* 2018; **2018**: 9216314 [PMID: [29725492](#) DOI: [10.1155/2018/9216314](#)]
- 21 **Losertova M**, Stamborska M. Comparison of deformation behaviour of 316L stainless steel and Ti6Al4V alloy applied in traumatology. *METABK* 2016; **55**: 667-670; ISSN 0543
- 22 **Sidambe AT**. Biocompatibility of Advanced Manufactured Titanium Implants-A Review. *Materials (Basel)* 2014; **7**: 8168-8188 [PMID: [28788296](#) DOI: [10.3390/ma7128168](#)]
- 23 **Sonnow L**, Könniker S, Vogt PM, Wacker F, von Falck C. Biodegradable magnesium Herbert screw - image quality and artifacts with radiography, CT and MRI. *BMC Med Imaging* 2017; **17**: 16 [PMID: [28196474](#) DOI: [10.1186/s12880-017-0187-7](#)]
- 24 **Maradze D**, Musson D, Zheng Y, Cornish J, Lewis M, Liu Y. High Magnesium Corrosion Rate has an Effect on Osteoclast and Mesenchymal Stem Cell Role During Bone Remodelling. *Sci Rep* 2018; **8**: 10003 [PMID: [29968794](#) DOI: [10.1038/s41598-018-28476-w](#)]
- 25 **Saleh KJ**, Thongtrangan I, Schwarz EM. Osteolysis: medical and surgical approaches. *Clin Orthop Relat Res* 2004; 138-147 [PMID: [15552150](#)]
- 26 **May H**, Alper Kati Y, Gumussuyu G, Yunus Emre T, Unal M, Kose O. Bioabsorbable magnesium screw versus conventional titanium screw fixation for medial malleolar fractures. *J Orthop Traumatol* 2020; **21**: 9 [PMID: [32451727](#) DOI: [10.1186/s10195-020-00547-7](#)]
- 27 **Plaass C**, von Falck C, Ettinger S, Sonnow L, Calderone F, Weizbauer A, Reifenrath J, Claassen L, Waizy H, Daniilidis K, Stukenborg-Colsman C, Windhagen H. Bioabsorbable magnesium versus standard titanium compression screws for fixation of distal metatarsal osteotomies - 3 year results of a randomized clinical trial. *J Orthop Sci* 2018; **23**: 321-327 [PMID: [29174422](#) DOI: [10.1016/j.jos.2017.11.005](#)]



Published by **Baishideng Publishing Group Inc**
7041 Koll Center Parkway, Suite 160, Pleasanton, CA 94566, USA

Telephone: +1-925-3991568

E-mail: office@baishideng.com

Help Desk: <https://www.f6publishing.com/helpdesk>

<https://www.wjgnet.com>

