

## Retrospective Study

# Titanium elastic nailing in diaphyseal femoral fractures of children below six years of age

Fabrizio Donati, Giuseppe Mazzitelli, Marco Lillo, Amerigo Menghi, Carla Conti, Antonio Valassina, Emanuele Marzetti, Giulio Maccauro

Fabrizio Donati, Giuseppe Mazzitelli, Marco Lillo, Amerigo Menghi, Carla Conti, Antonio Valassina, Emanuele Marzetti, Giulio Maccauro, Orthopedic and Traumatology Institute, Catholic University of the Sacred Heart, 00168 Rome, Italy

**Author contributions:** All the authors contributed equally to this work; Donati F, Mazzitelli G, Marzetti E and Maccauro G designed the research; Donati F, Lillo M, Menghi A, Conti C and Valassina A performed the research; Donati F, Conti C, Marzetti E and Maccauro G analyzed the data; Donati F, Mazzitelli G, Lillo M and Marzetti E wrote the paper.

**Institutional review board statement:** The study was reviewed and approved by the Internal ethics committee of orthopedics and traumatology department of Policlinico Gemelli Hospital.

**Informed consent statement:** All involved persons (subjects or legally authorized representative) gave their informed consent (written or verbal) prior to study inclusion.

**Conflict-of-interest statement:** No conflict of interest to be declared.

**Data sharing statement:** Technical appendix, statistical code, and dataset available the first author at [fabriziodonati2@hotmail.it](mailto:fabriziodonati2@hotmail.it).

**Open-Access:** This article is an open-access article which was selected by an in-house editor and fully peer-reviewed by external reviewers. It is distributed in accordance with the Creative Commons Attribution Non Commercial (CC BY-NC 4.0) license, which permits others to distribute, remix, adapt, build upon this work non-commercially, and license their derivative works on different terms, provided the original work is properly cited and the use is non-commercial. See: <http://creativecommons.org/licenses/by-nc/4.0/>

**Manuscript source:** Invited manuscript

**Correspondence to:** Emanuele Marzetti, MD, PhD, Orthopedic and Traumatology Institute, Catholic University of the Sacred Heart, L.go F. Vito 1, 00168 Rome, Italy. [emarzetti@live.com](mailto:emarzetti@live.com)

Telephone: +39-06-30155559  
Fax: +39-06-3051911

Received: July 21, 2016  
Peer-review started: July 26, 2016  
First decision: September 6, 2016  
Revised: October 18, 2016  
Accepted: November 21, 2016  
Article in press: November 23, 2016  
Published online: February 18, 2017

## Abstract

### AIM

To report the clinical and radiographic results of titanium elastic nail (TEN) in diaphyseal femoral fractures of children below age of six years.

### METHODS

A retrospective analysis of 27 diaphyseal femoral fractures in children younger than six years treated with TEN between 2005 and 2015 was conducted. Patients were immobilized in a cast for 5 wk and the nails were removed from 6 to 12 wk after surgery. Twenty-four cases were clinically and radiographically re-evaluated using the Flynn's scoring criteria, focusing on: Limb length discrepancy, rotational deformity, angulation, hip and knee range of motion (ROM), functional status, complications, and parent's satisfaction.

### RESULTS

Sixteen males and eight females with a mean age of 3.2 years at the time of treatment were re-evaluated at an average follow-up of 58.9 mo. No cases of delayed union were observed. The mean limb lengthening was 0.3 cm. Four cases experienced limb lengthening greater than 1 cm and always minor than 2 cm. Twelve point five percent of the cases showed an angulation < 10°. Complete functional recovery (hip and knee ROM, ability to run and

jump on the operated limb) occurred in 95.7% of cases. Complications included two cases of superficial infection of the TEN entry point, one case of refracture following a new trauma, and one TEN mobilization. According to the Flynn's scoring criteria, excellent results were obtained in 79.2% of patients and satisfactory results in the remaining 20.8%, with an average parent's satisfaction level of 9.1/10.

### CONCLUSION

TEN is as a safe, mini-invasive and surgeon-friendly technique and, considering specific inclusion criteria, it represents a useful and efficacy option for the treatment of diaphyseal femoral fractures even in patients younger than six years of age.

**Key words:** Titanium elastic nailing; Pediatric femoral fractures; Elastic stable intramedullary nailing; Surgical treatment; Femoral shaft

© The Author(s) 2017. Published by Baishideng Publishing Group Inc. All rights reserved.

**Core tip:** A retrospective analysis of 27 diaphyseal femoral fractures in children younger than six years treated with titanium elastic nailing (TEN) was conducted. Clinical and radiographic evaluations performed using Flynn's scoring criteria at an average follow-up of 58.9 mo showed 79.2% of excellent results and 20.8% satisfactory results, without delayed union or major complications. Considering the good clinical and radiographic results at mid-term follow-up, TEN showed to be a safe, mini-invasive and surgeon-friendly technique even in patients younger than six years of age.

Donati F, Mazzitelli G, Lillo M, Menghi A, Conti C, Valassina A, Marzetti E, Maccauro G. Titanium elastic nailing in diaphyseal femoral fractures of children below six years of age. *World J Orthop* 2017; 8(2): 156-162 Available from: URL: <http://www.wjgnet.com/2218-5836/full/v8/i2/156.htm> DOI: <http://dx.doi.org/10.5312/wjo.v8.i2.156>

### INTRODUCTION

The treatment of diaphyseal femoral fractures in pediatric age has traditionally been a matter of debate. Several conservative and surgical treatments have been proposed<sup>[1]</sup>. The treatment choice is typically based on patient's age, fracture type<sup>[2]</sup>, associated injuries, and the physical characteristics of the child. Diaphyseal femoral fractures in children less than six years of age are usually treated with nonsurgical methods, such as casting, tractions or Pavlik harness<sup>[3]</sup>. These methods show good clinical and radiological results at mid- and long-term follow-up and represent the gold standard treatment<sup>[4]</sup>. However conservative treatments are not suitable in specific cases such as polytraumatized patients, unstable fracture with risk of redisplacement and difficulty to

obtain an acceptable reduction.

Other concerns have been moved to conservative treatments like the long hospitalization, the necessity of general anesthesia and treatment in the operating theatre, prolonged weight-bearing restrictions and the high cost associated, sparking a renewed interest in surgical approaches<sup>[5]</sup>.

Intramedullary nailing with titanium elastic nails (TENs) offers several advantages, including early union, lower rate of malunion, spare of the physis, early mobilization and weight-bearing, mini-invasive approach with easy implant removal, and high patients' and parents' satisfaction rates. Good results at mid-term follow-up have been reported in children older than six years of age<sup>[6]</sup>. Little is known on the effectiveness of TEN for the treatment of diaphyseal femoral fractures in pre-school children. The present study was therefore undertaken to verify the clinical and surgical outcomes of intramedullary nailing with TEN in a sample of children younger than six years presenting with diaphyseal femoral fractures.

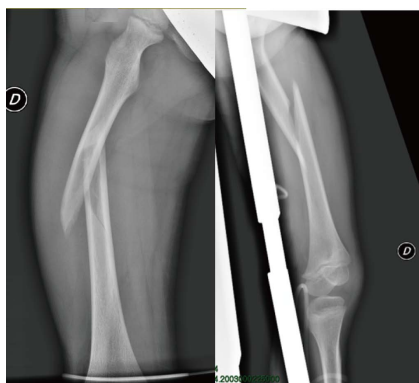### MATERIALS AND METHODS

#### Study design and participants

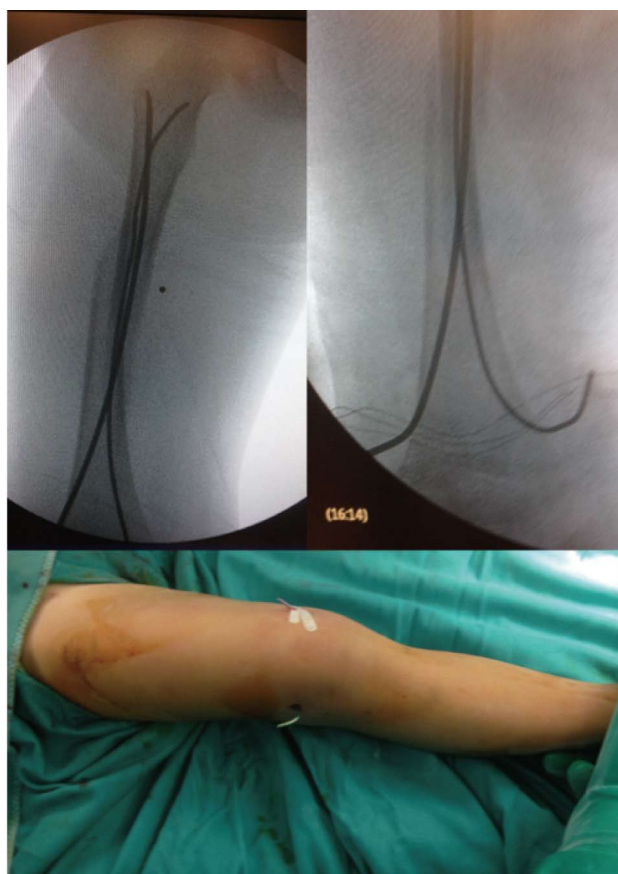The study was reviewed and approved by the Internal ethics committee of Orthopedics and Traumatology Department of Teaching Hospital "Agostino Gemelli" (Rome, Italy). We conducted a retrospective analysis in 27 patients younger than six years of age, surgically treated for diaphyseal femoral fractures in our center between 2005 and 2015. The sample comprised eighteen males and eight females with a mean age of 3.2 years (range: 1-6 years). The right femur was involved in 15 cases. One patient presented with bilateral femoral fracture, and one with an open fracture. The inclusion criteria for operative treatment should be reserved for certain cases such as polytraumatized patients, unstable fracture with risk of redisplacement and difficulty to obtain an acceptable reduction.

Twenty-four patients were treated for undisplaced fracture classified as 32-D/4.1 or 32-D/5.1 according to the AO pediatrics classification, while 3 cases showed slightly comminuted fractures classified as 32-D/4.2 or 32-D/5.2 (Figure 1).

Eight cases presented with associated lesions, involving the head, the abdom, or the thorax, or other fractures (one patellar fracture, three humeral fractures). Patients with associated neurological damage or pathological fracture were excluded. The more frequent cause of trauma was car accident (14 cases). The patients did not receive any other surgical treatment before orthopedic surgery. They were immobilized in a cast or with a skin traction and they were surgically treated as soon as their general conditions allowed surgery to be performed (on average, 36 h from their admission to the Emergency Department). The criteria of treatment were determined by a single operator and surgery performed by four different surgeons.



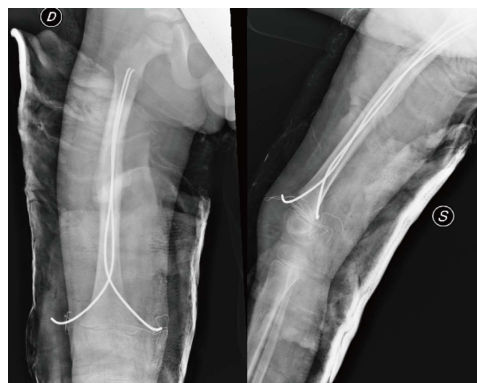
**Figure 1** Undisplaced diaphyseal femoral fracture classified as 32-D/5.1 according to AO pediatrics classification. Associated injuries, such as thoracic or abdominal traumata, often require surgical management of this kind of fracture.



**Figure 2** Intraoperative X-rays showing the correct positioning of titanium elastic nail. Entry points were performed, almost 2.5 cm proximal to the distal physis, one medial and one lateral. To facilitate the removal of the titanium elastic nail, its tail could be left over the skin surface as evident from the clinical intraoperative picture.

### **Surgical procedure and postoperative management**

Surgery was performed under general anesthesia, and reduction under fluoroscopic guide with the patient in supine position without the necessity of traction operating table. Only in 1 case was necessary to perform open reduction for soft tissue interposition. Two TENs of identical diameter (Synthes Italy, Milan®) were used calculating



**Figure 3** X-ray control at 5 wk of follow-up: Weight-bearing was allowed when advanced consolidation of the fracture with an evident bone callus formation was evident. Titanium elastic nail was then planned to be removed.

the diameter as the 40% of the medullary canal<sup>[7]</sup>. In two cases it was not possible to drive the second nail in the proximal fragment, and a nail with smaller diameter was used. The entry points in the bone were performed using a drill bit with a diameter of 3.5 mm, almost 2.5 cm proximal to the distal physis, one medial and one lateral. The nail was inserted retrogradely after adequate pre-bending to improve stability<sup>[8]</sup>. Long-knee brace was used in the postoperative period for an average of five weeks. Patients were discharged from hospital after an average of 5.7 d, and were followed up in our outpatients clinic after one week, at the fifth postoperative week, and at the end of treatment (8-14 wk from surgery). Patients were mobilized without weight-bearing during the fifth to seventh postoperative week, while full weight-bearing was allowed from six to eight weeks after surgery, depending on the fracture type, radiographic results and associated injuries. TENs were removed under general anesthesia when the fracture was considered healed, at an average of 7.8 wk (range: 6-12 wk) postoperatively, without encountering any intraoperative problems (Figures 2 and 3).

### **Patient follow-up**

The clinical evaluation was always performed in the presence of at least one of the patient's parents and after signing a detailed consensus about the study. The patients were evaluated in supine and standing positions focusing on limb length discrepancy, pelvic asymmetries, rotational deformity, axial angulation, and hip and knee range of motion (ROM). The occurrence of complications was explored by reviewing medical records whenever available or through the use of an ad hoc questionnaire.

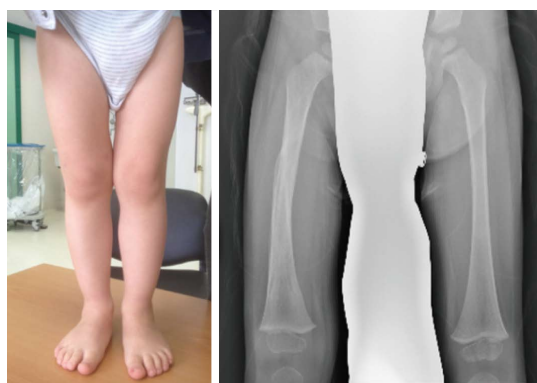A self-evaluation test was administered to the patient's parents to explore the functional level obtained by the patients about running, jumping on the injured limb, and participating in common sports or physical activity at the same level of other children. The parent's satisfaction about the treatment management was expressed on a scale ranging from 0 to 10.

The results were classified as excellent, satisfactory

**Table 1 Flynn scoring criteria for titanium elastic nail**

	Excellent result	Satisfactory result	Poor result
Leg length discrepancy	< 1 cm	< 2 cm	> 2 cm
Malalignment	< 5 degrees	< 10 degrees	> 10 degrees
Pain	None	None	Present
Complication	None	Minor and resolved complication	Major complication or lasting morbidity

According to Flynn scoring criteria for titanium elastic nail, a malalignment over 5°, internal or external rotation over 5° and shortening over 1 cm were considered pathological, in addition to the presence of pain or complications.



**Figure 4** Clinical and radiographic examination 12 mo after fracture with residual varus deformity (< 10°) of the fractured femur. At longer follow-up, no axial deformities were observed in any patient, while the lengthening of the fractured femur was a common finding, but always < 2 cm.

or poor according to the Flynn scoring criteria for TEN<sup>[9]</sup> (Table 1).

Radiographic evaluations were performed on the last full weight-bearing limb radiographs, in available antero-posterior and lateral views. Only in case of clinically evident limb length differences or malalignment, new X-rays were obtained. Limb lengthening and axial and rotational deformity were always considered in comparison to the contralateral limb.

## RESULTS

The average clinical follow-up was 58.9 mo (12–113 mo). Of the 27 cases, 24 were available for a new clinical and radiographic evaluation. Three cases were lost at follow-up because they lived in a different region. No functional limitations or complications were reported by those three cases according to phone interview and to available information.

No cases of delayed union were recorded. The mean limb lengthening was 0.3 cm (–0.5 cm/+1.6 cm), with three cases of shortening and seven of lengthening. In four cases, the limb length discrepancy was > 1 cm, but never > 2 cm.

Twelve point five percent of the cases showed a femoral angulation > 5°, but always < 10° (two varus and one valgus). No cases of significant rotational deformity were observed (Figure 4).

Complete hip ROM was recovered by 100% of patients. One patient showed a knee flexion < 120°

after an associated patellar fracture treated for hardware removal three weeks before our evaluation (Figure 5).

Complete functional recovery was reported by 95.7% of cases. All patients were able to run and to jump on the fractured femur. The most practiced sports were swimming and soccer. The average parent's satisfaction rate was 9.1/10. Lower results were observed in the cases who needed longer hospitalization or cast immobilization. No significant aesthetic concern was reported by any of the patients.

The reported complications included two cases of superficial infection/cutaneous irritation of the TEN entry point resolved after TEN removal or with short-term oral antibiotic treatment, one refracture of the same femur occurred three months after TEN removal following a new trauma, one TEN mobilization managed with prolonged casting and healed 10 wk from the trauma without surgery.

According to the Flynn's scoring criteria, excellent results were registered in 79.2% of the cases, and satisfactory results in the remaining 20.8%.

## DISCUSSION

The treatment of diaphyseal femoral fractures in preschool age is still debated. Conservative treatments remain the primary approach in most children of six years of age and younger considering the high healing power, the high remodeling power and the wide range of acceptance in this group of patients<sup>[1,10]</sup>. All conservative treatments have shown to be safe and to offer good clinical results. However, none of them has shown a clear superiority over the other methods<sup>[5,11]</sup>. Pavlik harness application vs spica casting were compared without showing any differences in clinical or radiographic outcomes<sup>[3]</sup>. Conservative treatments have many advantages being less invasive and practically without risk of soft tissues or growth plate injuries that are described in surgical procedures. On the other hand, conservative treatments present some important limitations: Prolonged skin traction with long hospitalization, significant patient discomfort, difficulties with hygienic care, and long weight-bearing restrictions<sup>[12]</sup>. Moreover, casting needs to be done in the operation theatre under general anaesthesia with similar time of surgical procedures, and similar radiation exposure for closed reductions in which sometimes it is necessary to use a specific invasive device<sup>[4]</sup>.

Considering such limitations, surgical treatments have



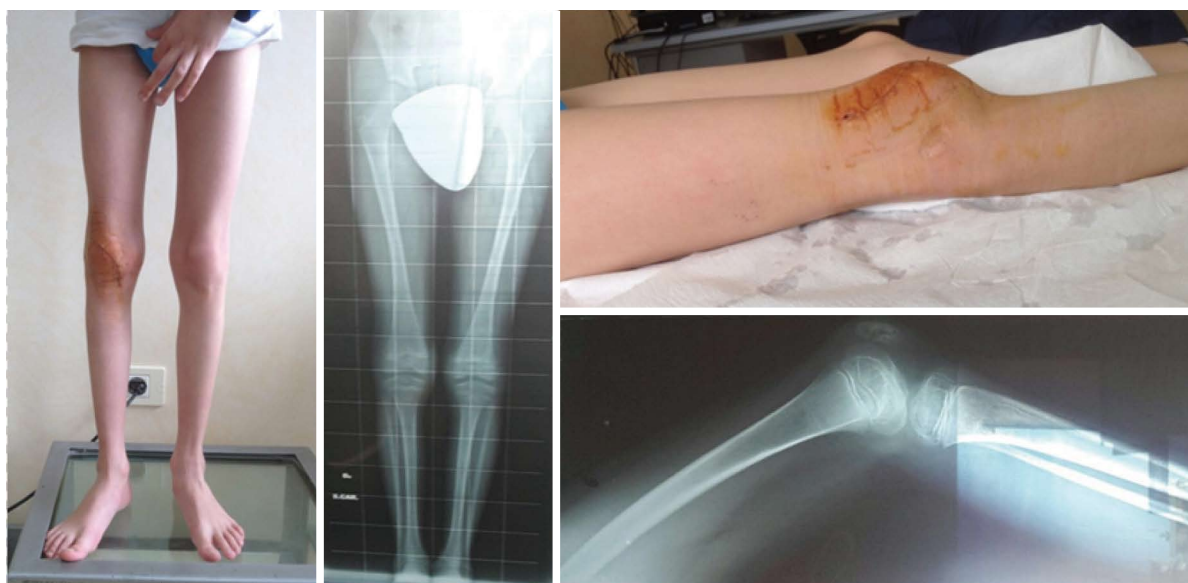

Figure 5 One patient had a limitation in knee flexion due to associated patellar fracture that was treated for hardware removal three weeks before our evaluation.

been increasingly used, particularly in patients with multiple traumata. Associated injuries involving the abdomen, the thorax, the spine or the head could represent a contraindication to conservative treatment<sup>[13,14]</sup>.

Different studies compared clinical and radiographic results obtained with conservative and surgical treatment after femoral fracture in adolescence. A recent systematic literature review of 531 femoral fractures confirmed comparable clinical results, with a slightly higher risk of malunion between conservative and surgical treatment (11.5% vs 8.1%), but a lower risk of complications (1% vs 4%)<sup>[5]</sup>. The authors concluded that there was insufficient evidence to determine if long-term function differed between surgical and conservative treatment.

Some authors recommend considering the characteristics of the fracture (*e.g.*, degree of displacement and possible comminution) and the child's weight (higher or lower than 80 pounds/35 kg) when deciding on the type of fracture treatment<sup>[1,3,7]</sup>.

TEN showed to be a safe and useful treatment in the management of such condition allowing for easier nursing and avoiding pressure ulcer<sup>[11]</sup>. Analyzing the good results obtained, TEN has become the first choice treatment even in isolated femoral fractures in children older than six years of age and under 45 kg of weight<sup>[6]</sup>. Most children and adolescents with femoral fractures can be treated successfully with a brief hospital course without compromising care or outcomes<sup>[15]</sup>.

Surgical management is being increasingly used to assure optimal alignment, allow early motion, or facilitate early weight bearing<sup>[16]</sup>. Intramedullary nailing with TEN offers a stable fixation controlling also the rotational deformity if applied according to the known basic surgical rule<sup>[17]</sup>. Moreover, TEN is minimally invasive, surgeon-friendly with a mean surgical time (after an appropriate learning curve) comparable with conservative treatment, and with

a low complication rate<sup>[13,18]</sup>.

Nevertheless, it is still unclear what the first-option treatment should be in pre-school children with diaphyseal femoral fracture. Indeed, these patients have a great potential of growth and bone remodeling after fracture. For many types of fractures, both nonsurgical and surgical methods have yielded good results, but conservative treatment has traditionally been the first choice<sup>[1,4]</sup>.

Considering the experience reported in older children undergone intramedullary nailing with TEN, it is evident that, besides clinical and radiographic outcomes, other parameters need to be taken into account for treatment choice<sup>[18]</sup>.

Long hospitalization with long time in traction or uncomfortable immobilization is no longer acceptable in many situations. A faster recovery with early motion and weight-bearing should therefore be prioritized also in very young patients. In addition, surgical treatment allows for reducing the care costs relative to conservative options<sup>[15]</sup>.

In our experience, treatment with TEN showed good mid-term clinical and radiographic results in patients younger than six years, in the absence of severe complications and with a high level of parents satisfaction rate even though a second operation to remove the pins was performed in each case treated.

Our results support the analysis of Rapp *et al.*<sup>[19]</sup> who extended the indication to TEN as the standard treatment to patients at least 3-year-old. External fixation is another option that could be considered in patients younger than six years, but it is less comfortable for the patients and less accepted by their parents, besides requiring longer time of treatment to achieve optimal healing<sup>[20,21]</sup>.

It should be considered that good results with TEN are only obtained when surgeons have a good

knowledge of the technique<sup>[22,23]</sup>. Complications are indeed mainly caused by technical errors including insertion of too thin nails, frame asymmetry, and implant malorientation<sup>[24]</sup>. This implies that the surgeon's experience remains one of the most important factors in the choice of treatment<sup>[25]</sup>.

Finally, radiation exposure could be a critical point of TEN treatment. However, even if intraoperative fluoroscopic exposure is higher than with conservative treatment, the higher stability obtained and the lower rate of malunion, allow reducing the number of postoperative X-ray control radiographs<sup>[5]</sup>.

Considering the good clinical and radiographic results at mid-term follow-up, TEN showed to be a safe, mini-invasive and surgeon-friendly technique even in patients younger than six years of age. Titanium elastic nailing, with specific indications, represents a useful and efficacy option for the treatment of diaphyseal femoral fractures even in patients younger than six years of age especially when the surgeon possesses good experience with this surgical technique. Further studies are necessary to evaluate if this method has any significant advantages in comparison to conservative treatments.

## COMMENTS

### Background

The treatment of diaphyseal femoral fractures in pediatric age is typically selected on the base of patient's age, fracture type, associated injuries, and the physical characteristics of the child. Diaphyseal femoral fracture in children less than six years of age is usually treated conservatively with several limitations. Intramedullary nailing with titanium elastic nails (TENs) shows good results at mid-term follow-up in children older than six years of age. The present study was therefore undertaken to verify the clinical and surgical outcomes of intramedullary nailing with TEN in a sample of children younger than six years presenting with diaphyseal femoral fractures.

### Research frontiers

Different studies compared clinical and radiographic results obtained with conservative and surgical treatment after femoral fracture in adolescence: both nonsurgical and surgical methods have yielded good results. A recent systematic review confirmed comparable clinical results, but conservative treatment was demonstrated more expensive, and was associated with longer hospitalization and longer weight bearing restriction. External fixation is another option that could be considered in patients younger than six years, but it is less comfortable for the patients and less accepted by their parents, besides requiring longer time of treatment to achieve optimal healing. On this basis, Rapp *et al* proposed to extended the indication to TEN as the standard treatment to patients at least 3-year-old.

### Innovations and breakthroughs

This retrospective study confirmed that TEN leads to good clinical and radiological results allowing optimal alignment, early motion and early weight bearing. TEN demonstrated to be effective for the treatment of diaphyseal femoral fractures even in patients younger than six years of age: It is a safe and surgeon-friendly technique and it is indicated particularly in patients with multiple traumata, and it guarantees a low rate of complications.

### Applications

TEN represents a useful and efficacy option for the treatment of diaphyseal femoral fractures even in patients younger than six years of age especially when the surgeon possesses a good experience with this surgical technique.

## Terminology

TEN: Titanium elastic nail.

## Peer-review

The authors demonstrated an excellent result for treatment of diaphyseal femoral fractures in children with TEN. The paper is well written.

## REFERENCES

- 1 **Buckley SL.** Current trends in the treatment of femoral shaft fractures in children and adolescents. *Clin Orthop Relat Res* 1997; **338**: 60-73 [PMID: 9170363 DOI: 10.1097/00003086-199705000-00009]
- 2 **Slongo TF, Audigé L.** Fracture and dislocation classification compendium for children: the AO pediatric comprehensive classification of long bone fractures (PCCF). *J Orthop Trauma* 2007; **21**: S135-S160 [PMID: 18277238]
- 3 **Podszwa DA, Mooney JF, Cramer KE, Mendelow MJ.** Comparison of Pavlik harness application and immediate spica casting for femur fractures in infants. *J Pediatr Orthop* 2004; **24**: 460-462 [PMID: 15308892 DOI: 10.1097/00004694-200409000-00002]
- 4 **Catena N, Sènès FM, Riganti S, Boero S.** Diaphyseal femoral fractures below the age of six years: Results of plaster application and long term followup. *Indian J Orthop* 2014; **48**: 30-34 [PMID: 24600060 DOI: 10.4103/0019-5413.125487]
- 5 **Madhuri V, Dutt V, Gahukamble AD, Tharyan P.** Interventions for treating femoral shaft fractures in children and adolescents. *Cochrane Database Syst Rev* 2014; (7): CD009076 [PMID: 25072888 DOI: 10.1002/14651858.CD009076.pub2]
- 6 **Saikia K, Bhuyan S, Bhattacharya T, Saikia S.** Titanium elastic nailing in femoral diaphyseal fractures of children in 6-16 years of age. *Indian J Orthop* 2007; **41**: 381-385 [PMID: 21139795 DOI: 10.4103/0019-5413.33876]
- 7 **Flynn JM, Skaggs DL, Sponseller PD, Ganley TJ, Kay RM, Leitch KK.** The surgical management of pediatric fractures of the lower extremity. *Instr Course Lect* 2003; **52**: 647-659 [PMID: 12690889]
- 8 **Ligier JN, Metaizeau JP, Prévot J, Lascombes P.** Elastic stable intramedullary nailing of femoral shaft fractures in children. *J Bone Joint Surg Br* 1988; **70**: 74-77 [PMID: 3339064]
- 9 **Flynn JM, Hresko T, Reynolds RA, Blasler RD, Davidson R, Kasser J.** Titanium elastic nails for pediatric femur fractures: a multicenter study of early results with analysis of complications. *J Pediatr Orthop* 2001; **21**: 4-8 [PMID: 11176345]
- 10 **Bowyer GW, Clarke NM.** Fractures of the femur in children. *J Bone Joint Surg Am* 1995; **77**: 1784-1785 [PMID: 7593090]
- 11 **Sanders JO, Browne RH, Mooney JF, Raney EM, Horn BD, Anderson DJ, Hennrikus WL, Robertson WW.** Treatment of femoral fractures in children by pediatric orthopedists: results of a 1998 survey. *J Pediatr Orthop* 2001; **21**: 436-441 [PMID: 11433152 DOI: 10.1097/00004694-200111000-00028]
- 12 **Khoriat AA, Jones C, Gelfer Y, Trompeter A.** The management of paediatric diaphyseal femoral fractures: a modern approach. *Strategies Trauma Limb Reconstr* 2016; **11**: 87-97 [PMID: 27401456 DOI: 10.1007/s11751-016-0258-2]
- 13 **Bhaskar A.** Treatment of long bone fractures in children by flexible titanium nails. *Indian J Orthop* 2005; **39**: 166-168 [DOI: 10.4103/0019-5413.36715]
- 14 **Metaizeau JP.** Stable elastic intramedullary nailing for fractures of the femur in children. *J Bone Joint Surg Br* 2004; **86**: 954-957 [PMID: 15446516 DOI: 10.1302/0301-620X.86B7.15620]
- 15 **Buechsenschuetz KE, Mehlman CT, Shaw KJ, Crawford AH, Immerman EB.** Femoral shaft fractures in children: traction and casting versus elastic stable intramedullary nailing. *J Trauma* 2002; **53**: 914-921 [PMID: 12435943 DOI: 10.1097/00005373-200211000-00017]
- 16 **Flynn JM, Luedtke LM, Ganley TJ, Dawson J, Davidson RS, Dormans JP, Ecker ML, Gregg JR, Horn BD, Drummond DS.** Comparison of titanium elastic nails with traction and a spica cast to treat femoral fractures in children. *J Bone Joint Surg Am* 2004; **86-A**:

- 770-777 [PMID: 15069142]
- 17 **Gwyn DT**, Olney BW, Dart BR, Czuwala PJ. Rotational control of various pediatric femur fractures stabilized with titanium elastic intramedullary nails. *J Pediatr Orthop* 2004; **24**: 172-177 [PMID: 15076602 DOI: 10.1097/01241398-200403000-00007]
- 18 **Narayanan UG**, Hyman JE, Wainwright AM, Rang M, Alman BA. Complications of elastic stable intramedullary nail fixation of pediatric femoral fractures, and how to avoid them. *J Pediatr Orthop* 2004; **24**: 363-369 [PMID: 15205616 DOI: 10.1097/01241398-200407000-00004]
- 19 **Rapp M**, Kaiser MM, Grauel F, Gielok C, Illing P. Femoral shaft fractures in young children (< 5 years of age): operative and non-operative treatments in clinical practice. *Eur J Trauma Emerg Surg* 2015; Epub ahead of print [PMID: 26335539]
- 20 **Aronson J**, Tursky EA. External fixation of femur fractures in children. *J Pediatr Orthop* 1992; **12**: 157-163 [PMID: 1552016 DOI: 10.1097/01241398-199203000-00003]
- 21 **Bar-On E**, Sagiv S, Porat S. External fixation or flexible intramedullary nailing for femoral shaft fractures in children. A prospective, randomised study. *J Bone Joint Surg Br* 1997; **79**: 975-978 [PMID: 9393916 DOI: 10.1302/0301-620X.79B6.7740]
- 22 **Letts M**, Jarvis J, Lawton L, Davidson D. Complications of rigid intramedullary rodding of femoral shaft fractures in children. *J Trauma* 2002; **52**: 504-516 [PMID: 11901327 DOI: 10.1097/00005373-200203000-00015]
- 23 **Ward WT**, Levy J, Kaye A. Compression plating for child and adolescent femur fractures. *J Pediatr Orthop* 1992; **12**: 626-632 [PMID: 1517424 DOI: 10.1097/01241398-199209000-00012]
- 24 **Lascombes P**, Haumont T, Journeau P. Use and abuse of flexible intramedullary nailing in children and adolescents. *J Pediatr Orthop* 2004; **26**: 827-834 [PMID: 17065959 DOI: 10.1097/01.bpo.0000235397.64783.d6]
- 25 **Andreacchio A**, Marengo L, Canavese F, Pedretti L, Memeo A. Comparison between external fixation and elastic stable intramedullary nailing for the treatment of femoral shaft fractures in children younger than 8 years of age. *J Pediatr Orthop B* 2016; **25**: 471-477 [PMID: 27261769 DOI: 10.1097/BPB.0000000000000342]

**P- Reviewer:** El-Alfy BS, Ohishi T, Tawonsawatruk T

**S- Editor:** Ji FF **L- Editor:** A **E- Editor:** Lu YJ





Published by **Baishideng Publishing Group Inc**

8226 Regency Drive, Pleasanton, CA 94588, USA

Telephone: +1-925-223-8242

Fax: +1-925-223-8243

E-mail: [bpgoffice@wjgnet.com](mailto:bpgoffice@wjgnet.com)

Help Desk: <http://www.wjgnet.com/esps/helpdesk.aspx>

<http://www.wjgnet.com>

