

World Journal of *Orthopedics*

World J Orthop 2017 August 18; 8(8): 606-659





EDITORIAL

- 606 Ultrasound diagnosis of fractures in mass casualty incidents
Abu-Zidan FM

MINIREVIEWS

- 612 Postoperative deep shoulder infections following rotator cuff repair
Atesok K, MacDonald P, Leiter J, McRae S, Stranges G, Old J
- 619 Synthesis of evidence for the treatment of intersection syndrome
Balakatounis K, Angoules AG, Angoules NA, Panagiotopoulou K

ORIGINAL ARTICLE

Retrospective Study

- 624 Ponseti method treatment of neglected idiopathic clubfoot: Preliminary results of a multi-center study in Nigeria
Adegbehingbe OO, Adetiloye AJ, Adewole L, Ajodo DU, Bello N, Esan O, Hoover AC, Ior J, Lasebikan O, Ojo O, Olasinde A, Songden D, Morcuende JA

Observational Study

- 631 Functional outcomes of traumatic and non-traumatic rotator cuff tears after arthroscopic repair
Abechain JJK, Godinho GG, Matsunaga FT, Netto NA, Daou JP, Tamaoki MJS

SYSTEMATIC REVIEWS

- 638 Ipsilateral femur and tibia fractures in pediatric patients: A systematic review
Anari JB, Neuwirth AL, Horn BD, Baldwin KD

META-ANALYSIS

- 644 Femoral positioning influences ipsi-and contralateral anterior cruciate ligament rupture following its reconstruction: Systematic review and meta-analysis
de Campos GC, Teixeira PEP, Castro A, Alves Junior WM

CASE REPORT

- 651 Open wound management of esophagocutaneous fistula in unstable cervical spine after corpectomy and multilevel laminectomy: A case report and review of the literature
Elgafy H, Khan M, Azurdia J, Peters N
- 656 Bennett's fracture associated with fracture of Trapezium - A rare injury of first carpo-metacarpal joint
Goyal T

Contents

World Journal of Orthopedics
Volume 8 Number 8 August 18, 2017

ABOUT COVER

Editorial Board Member of *World Journal of Orthopedics*, Melanie Jane Franklyn, PhD, Academic Fellow, Academic Research, Department of Mechanical Engineering, The University of Melbourne, Melbourne, Victoria 3010, Australia

AIM AND SCOPE

World Journal of Orthopedics (*World J Orthop*, *WJO*, online ISSN 2218-5836, DOI: 10.5312) is a peer-reviewed open access academic journal that aims to guide clinical practice and improve diagnostic and therapeutic skills of clinicians.

WJO covers topics concerning arthroscopy, evidence-based medicine, epidemiology, nursing, sports medicine, therapy of bone and spinal diseases, bone trauma, osteoarthropathy, bone tumors and osteoporosis, minimally invasive therapy, diagnostic imaging. Priority publication will be given to articles concerning diagnosis and treatment of orthopedic diseases. The following aspects are covered: Clinical diagnosis, laboratory diagnosis, differential diagnosis, imaging tests, pathological diagnosis, molecular biological diagnosis, immunological diagnosis, genetic diagnosis, functional diagnostics, and physical diagnosis; and comprehensive therapy, drug therapy, surgical therapy, interventional treatment, minimally invasive therapy, and robot-assisted therapy.

We encourage authors to submit their manuscripts to *WJO*. We will give priority to manuscripts that are supported by major national and international foundations and those that are of great basic and clinical significance.

INDEXING/ABSTRACTING

World Journal of Orthopedics is now indexed in Emerging Sources Citation Index (Web of Science), PubMed, PubMed Central and Scopus.

FLYLEAF

I-III Editorial Board

EDITORS FOR THIS ISSUE

Responsible Assistant Editor: *Xiang Li*
Responsible Electronic Editor: *Ya-Jing Lu*
Proofing Editor-in-Chief: *Lian-Sheng Ma*

Responsible Science Editor: *Fang-Fang Ji*
Proofing Editorial Office Director: *Jin-Lei Wang*

NAME OF JOURNAL
World Journal of Orthopedics

ISSN
ISSN 2218-5836 (online)

LAUNCH DATE
November 18, 2010

FREQUENCY
Monthly

EDITORS-IN-CHIEF
Quanjun (Trey) Cui, MD, Professor, Department of Orthopaedic Surgery, School of Medicine, University of Virginia, Charlottesville, VA 22908, United States

Bao-Gan Peng, MD, PhD, Professor, Department of Spinal Surgery, General Hospital of Armed Police Force, Beijing 100039, China

EDITORIAL BOARD MEMBERS
All editorial board members resources online at <http://www.wjgnet.com>

www.wjgnet.com/2218-5836/editorialboard.htm

EDITORIAL OFFICE
Xiu-Xia Song, Director
World Journal of Orthopedics
Baishideng Publishing Group Inc
7901 Stoneridge Drive, Suite 501, Pleasanton, CA 94588, USA
Telephone: +1-925-2238242
Fax: +1-925-2238243
E-mail: editorialoffice@wjgnet.com
Help Desk: <http://www.fjpublishing.com/helpdesk>
<http://www.wjgnet.com>

PUBLISHER
Baishideng Publishing Group Inc
7901 Stoneridge Drive,
Suite 501, Pleasanton, CA 94588, USA
Telephone: +1-925-2238242
Fax: +1-925-2238243
E-mail: bpgoffice@wjgnet.com
Help Desk: <http://www.fjpublishing.com/helpdesk>
<http://www.wjgnet.com>

PUBLICATION DATE
August 18, 2017

COPYRIGHT
© 2017 Baishideng Publishing Group Inc. Articles published by this Open-Access journal are distributed under the terms of the Creative Commons Attribution Non-commercial License, which permits use, distribution, and reproduction in any medium, provided the original work is properly cited, the use is non commercial and is otherwise in compliance with the license.

SPECIAL STATEMENT
All articles published in journals owned by the Baishideng Publishing Group (BPG) represent the views and opinions of their authors, and not the views, opinions or policies of the BPG, except where otherwise explicitly indicated.

INSTRUCTIONS TO AUTHORS
<http://www.wjgnet.com/bpg/gerinfo/204>

ONLINE SUBMISSION
<http://www.fjpublishing.com>

Retrospective Study

Ponseti method treatment of neglected idiopathic clubfoot: Preliminary results of a multi-center study in Nigeria

Olayinka O Adegbehingbe, Adeoye J Adetiloye, Ladipo Adewole, Dennis U Ajodo, Nosirudeen Bello, Oluwadare Esan, Alex C Hoover, James Ior, Omolade Lasebikan, Owolabi Ojo, Anthony Olasinde, David Songden, Jose A Morcuende

Olayinka O Adegbehingbe, Oluwadare Esan, Department of Orthopedic Surgery and Traumatology, Obafemi Awolowo University, Ile-Ife, Nigeria

Adeoye J Adetiloye, Gwarinpa General Hospital, Federal Capital Territory, Abuja, Nigeria

Ladipo Adewole, Lagos State University College of Medicine, Lagos, Lagos State, Nigeria

Dennis U Ajodo, Federal Medical Center Keffi, Keffi, Nasarawa State, Nigeria

Nosirudeen Bello, Federal Medical Center Abeokuta, Abeokuta, Ogun State, Nigeria

Alex C Hoover, Jose A Morcuende, Carver College of Medicine, University of Iowa, Iowa City, IA 52242, United States

James Ior, David Songden, NKST Hospital Mkar, Gboko, Benue State, Nigeria

Omolade Lasebikan, National Orthopedic Hospital, Enugu, Enugu State, Nigeria

Owolabi Ojo, Federal Medical Center Ido Ekiti, Ekiti State, Nigeria

Anthony Olasinde, Federal Medical Center, Owo, Ondo State, Nigeria

Author contributions: Hoover AC designed and performed the research and wrote the paper; Adegbehingbe OO and Morcuende JA designed the research and supervised the report; Adegbehingbe OO, Adetiloye AJ, Adewole L, Ajodo DU, Bello N, Esan O, Ior J, Lasebikan O, Ojo O, Olasinde A and Songden D performed clinical treatment and provided clinical advice; all the authors contributed to this article.

Institutional review board statement: This study was performed using anonymous patient data from the International

Clubfoot Registry. Copyright and information on the International Clubfoot Registry available from the Ponseti International Association, Iowa City, IA, United States.

Informed consent statement: Patients were not required to give informed consent to the study because the analysis used anonymous clinical data from the International Clubfoot Registry. Patients agreed to be a part of the registry at the commencement of treatment by written consent.

Conflict-of-interest statement: The authors have no financial relationships to disclose.

Data sharing statement: No additional data are available.

Open-Access: This article is an open-access article which was selected by an in-house editor and fully peer-reviewed by external reviewers. It is distributed in accordance with the Creative Commons Attribution Non Commercial (CC BY-NC 4.0) license, which permits others to distribute, remix, adapt, build upon this work non-commercially, and license their derivative works on different terms, provided the original work is properly cited and the use is non-commercial. See: <http://creativecommons.org/licenses/by-nc/4.0/>

Manuscript source: Unsolicited manuscript

Correspondence to: Olayinka O Adegbehingbe, FWACS, FICS, Professor, Department of Orthopedic Surgery and Traumatology, Obafemi Awolowo University, Ile Ife, Osun State, Nigeria. olayinkaadegbehingbe@yahoo.co.uk
Telephone: +234-36-7031367220

Received: August 25, 2016

Peer-review started: August 27, 2016

First decision: November 19, 2016

Revised: March 13, 2017

Accepted: April 18, 2017

Article in press: April 20, 2017

Published online: August 18, 2017

Abstract

AIM

To evaluate the effectiveness of the Ponseti method for initial correction of neglected clubfoot cases in multiple centers throughout Nigeria.

METHODS

Patient charts were reviewed through the International Clubfoot Registry for 12 different Ponseti clubfoot treatment centers and 328 clubfeet (225 patients) met inclusion criteria. All patients were treated by the method described by Ponseti including manipulation and casting with percutaneous Achilles tenotomy as needed.

RESULTS

A painless plantigrade foot was obtained in 255 feet (78%) without the need for extensive soft tissue release and/or bony procedures.

CONCLUSION

We conclude that the Ponseti method is a safe, effective and low-cost treatment for initial correction of neglected idiopathic clubfoot presenting after walking age. Long-term follow-up will be required to assess outcomes.

Key words: Ponseti method; Neglected clubfoot; Nigeria; Walking age

© The Author(s) 2017. Published by Baishideng Publishing Group Inc. All rights reserved.

Core tip: This is a retrospective study to evaluate the efficacy of the Ponseti method for initial correction of untreated, idiopathic clubfoot in patients above one year of age. The rate of initial correction to a painless, plantigrade foot without the need for soft tissue release was 78% in 255 evaluated clubfeet from 12 treatment centers in Nigeria. The Ponseti method, a non-operative treatment method involving serial manipulation and casting, is useful and effective for initial correction of clubfoot, even after walking age.

Adegbehingbe OO, Adetiloye AJ, Adewole L, Ajodo DU, Bello N, Esan O, Hoover AC, Ior J, Lasebikan O, Ojo O, Olasinde A, Songden D, Morcuende JA. Ponseti method treatment of neglected idiopathic clubfoot: Preliminary results of a multi-center study in Nigeria. *World J Orthop* 2017; 8(8): 624-630 Available from: URL: <http://www.wjgnet.com/2218-5836/full/v8/i8/624.htm> DOI: <http://dx.doi.org/10.5312/wjo.v8.i8.624>

INTRODUCTION

Idiopathic clubfoot is the most common musculoskeletal congenital birth defect, affecting between 1 and 7 births in every 1000^[1]. Left untreated, clubfoot may lead to pain, disability, discrimination, and hardship throughout the person's life. This is especially a problem in developing countries like Nigeria where 70% of the

population lives below the poverty line and has limited access to treatment. Although Nigeria has around half the population of the United States at about 180 million, it is estimated that the prevalence of clubfoot is at least three to five times higher than in the United States. This high prevalence is mainly a result of the number of people living with neglected clubfoot, defined as clubfoot that has not been treated before walking age^[2,3].

For many years in Nigeria and around the world, soft tissue release or extensive bony surgery were seen as the only options for the full correction of clubfoot. In the past two decades, the minimally invasive Ponseti method has been proven and accepted as the worldwide gold standard for treatment of clubfoot based on its success in both the short term and long term^[4]. Introduced in Nigeria in 2009, the Ponseti method is a safe, effective, and economical option for many patients who cannot afford an extensive surgery. The method involves skilled serial manipulation and plaster casting as well as a percutaneous Achilles tenotomy (PAT) to completely correct the deformity. After the correction is complete, the child wears a foot abduction brace at night for a few years to prevent relapse^[5-7].

There are few studies on the effectiveness of the Ponseti method for patients over age 1, but the early evidence has been promising. Studies in Brazil, Nepal, India and Ethiopia reported that use of the Ponseti method allowed for avoidance of soft tissue release in 66%-92% of cases above one year of age^[8-16].

The purpose of this study was to evaluate the effectiveness of the Ponseti method for initial correction of neglected clubfoot cases in multiple centers throughout Nigeria.

MATERIALS AND METHODS

The accepted definition of neglected clubfoot is true idiopathic clubfoot that has not been treated before walking age. In this study, age one will be used as representative of walking age. Through July 2015, 1137 clubfoot cases from 2010-2015 were recorded from Ponseti treatment centers in Nigeria into the International Clubfoot Registry with patient permission. Patient charts were reviewed through the registry. Two hundred and twenty-five patients (328 clubfeet) from 12 different centers (Figure 1) met inclusion criteria and are profiled in Table 1. Patients were excluded if they were younger than 1 year of age, had non-idiopathic clubfoot (syndromic, neuromuscular, etc.) or had other treatment prior to Ponseti method.

Treatment at all 12 centers, including casting and percutaneous Achilles tenotomy as necessary, was performed by orthopaedic surgeons who were properly trained in the technique according to Ponseti^[5-7]. Casts were changed at intervals of 7-10 d if possible but up to every 14 d depending on the ability of the patient to reach the clinic and pay for the treatment. All patients were treated on an outpatient basis although two of the twelve centers, including 18 total patients, performed

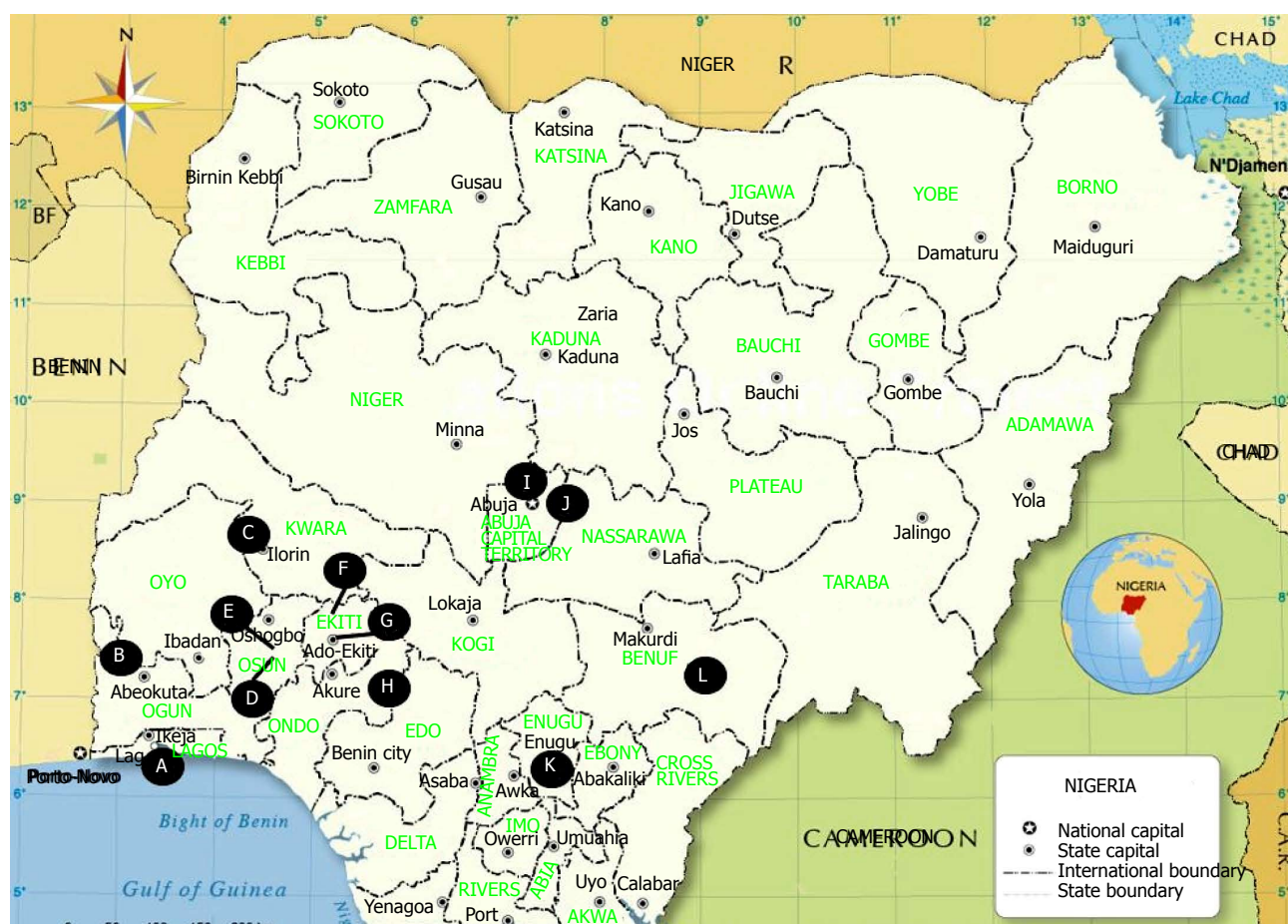


Figure 1 Map of clubfoot clinic sites. A: LASUCOM; B: FMC Abeokuta; C: University of Ilorin; D: Obafemi Awolowo University; E: Wesley Guild Hospital Ilesha; F: FMC Ido-Ekiti; G: Ekiti St Teaching Hospital; H: FMC Owo; I: Gwarinpa GH; J: FMC Keffi; K: NOH Enugu; L: NKST-Mkar, Benue.

Table 1 Phenotypic characteristics *n* (%)

	Cases
Female	94 (42)
Male	131 (58)
Bilateral	103 (46)
Right	66 (29)
Left	56 (25)
Age 1-2 yr	147 (65)
Age 3-9 yr	59 (26)
Age ≥ 10 yr	19 (9)

tenotomies in the operating theatre for optimal sterility. Although tendon transfer can be considered part of the Ponseti protocol, one of the main objectives of this study is to show that neglected clubfoot can be corrected non-operatively as that is most beneficial in the low resource setting. Therefore in this study, tendon transfer will be considered failure in treatment along with tendoachilles lengthening and major soft tissue release.

After completion of serial casting, correction was maintained with a foot abduction brace at night or in rare cases when braces were not available, with encouragement of active play (walking, running, etc.). Abduction braces were generally crafted by each hospital's orthotics department or local cobblers working

with the orthopaedic surgeons.

In the newborn population, Pirani and Dimeglio scoring systems are generally used to assess the severity and characteristics of a clubfoot. These systems have been validated and are useful for comparing the quality of correction^[17,18]. However, these have not been validated for the neglected population and no system exists yet for the qualification of neglected clubfoot^[19].

RESULTS

The study population consisted of 225 patients, 131 (58.2%) were male, and the clubfoot was bilateral in 103 cases (46%). One hundred and forty-seven patients were age 1 or 2, 59 were between the ages of 3 and 9, and 19 patients were age 10 to 16.

Of 328 neglected clubfeet studied, 255 feet (78%) achieved initial correction, a completely plantigrade foot, without soft tissue release or other surgical intervention besides PAT. Of the 73 other feet, 47 were lost to follow up mid-treatment and 26 of the feet were converted to Achilles tendon lengthening, tendon transfer procedures, or major soft tissue release.

A profile of the total number of casts required for complete correction and the PAT rates based on age group is shown in Table 2. A distribution of the number

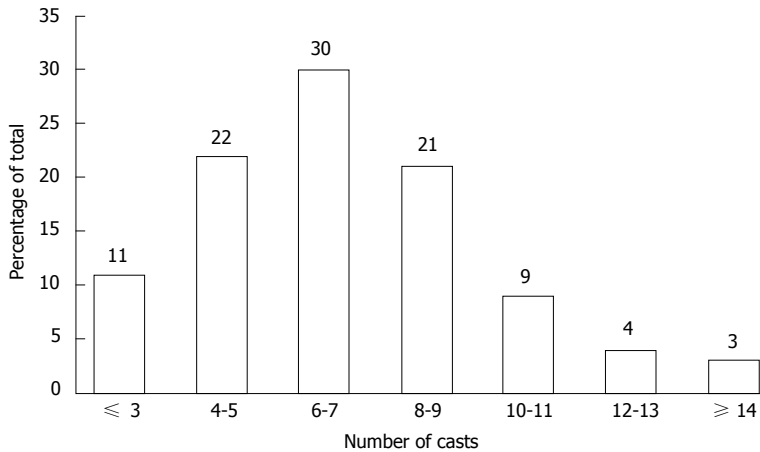


Figure 2 Number of casts required for correction.

Table 2 Number of casts and tenotomy rate

	Total	Age 1-2 yr	Age 3-9 yr	Age 10-16 yr
Mean casts ¹ , n (range)	6.84 (3-20)	6.71 (3-20)	7.03 (4-17)	7.43 (4-13)
Tenotomy rate	51%	42%	53%	60%

¹Between groups ANOVA *P*-value = 0.78.

of casts required across all age groups is shown in Figure 2. The average number of casts necessary for correction was 6.84, ranging from 6.71 casts/foot for 1 and 2 year olds up to 7.43 casts/foot for those above age 10. Analysis of variance between the groups shows no statistically significant difference ($P = 0.78$). The overall rate of percutaneous Achilles tenotomy was 51% and also tended to increase with patient age from 42% in the youngest age group to 60% in the oldest. There were no failures of PAT's reported.

DISCUSSION

Neglected clubfoot is a serious problem in developing nations where a significant number of children born with the deformity do not receive immediate treatment. It is common for parents to delay treatment due to cost, lack of transportation or limited availability of proper care. Frequently, children do not present until around the start of school age at 4 or 5 because of increased interaction with peers and social pressures to fit in. Neglected clubfoot can cause significant physical, psychological and financial burden to the child and the family. Adults with untreated clubfoot may experience significant pain and disability, be unable to work, and have difficulty performing daily activities of living.

Historically, neglected clubfoot has been treated with bony surgery and extensive soft tissue release. These techniques are difficult, costly, have substantial complication rates, and they are rarely feasible in the healthcare settings of developing nations^[20-23].

Our study has shown that the Ponseti method is

effective in the initial correction of neglected clubfoot and reduction of the need for surgical treatment beyond percutaneous tenotomy. Its suitability at the clinical level is imperative for use in developing countries like Nigeria, where operating room access comes at a premium. Our results are similar to multiple recent studies on Ponseti treatment of neglected clubfoot cases, shown in Table 3.

Ponseti *et al.*^[5] described successful results from Brazil after Ponseti treatment in 17 children (24 feet) with an average age at presentation of 3.9 (1.2-9.0). A full correction was achieved in 16 feet (67%) without the need for extensive surgery and it was found that those who eventually needed surgery ended up with a lesser surgical intervention. Six of the patients had recurrence, and the best results were achieved in the youngest group.

In Nepal, Ponseti *et al.*^[6] reported the use of Ponseti treatment in neglected cases between the age of 1 and 6. In 260 feet, 83% were able to avoid any surgery besides PAT. Similar to our study, with a broader range of ages and larger study group, they found a wider range of casts were necessary to achieve full correction.

Spiegel *et al.*^[9] in India had 37 neglected clubfoot patients (55 clubfeet) with a mean age of presentation of 2 (1-3) years. After a Ponseti trial, 4 patients (6 feet) were considered unfit for Ponseti treatment and had a posteromedial release, 4 patients (4 feet) relapsed and had tibialis tendon transfer and 3 patients (4 feet) required tendoachilles lengthening to obtain adequate dorsiflexion.

In Ethiopia, Khan *et al.*^[11] found that in 22 neglected clubfoot patients (32 feet), an open tendoachilles lengthening was required for 5 patients (7 feet) plus posterior capsulotomy in 3 additional patients (4 feet). Correction was achieved for the remaining 14 patients (21 feet) with the Ponseti method and PAT alone.

In our study, 78% of 328 feet achieved correction without major surgery. Some factors, such as time between casts, were variable between the 12 different treatment centers because of the socioeconomic differences between the regions of Nigeria. In a survey of

Table 3 Published results on correction of neglected clubfoot

	Brazil, 2007	Nepal, 2009	India, 2012	Ethiopia, 2014	Present study
Total number of feet	24	260	55	32	328
M/F	12/5	120/51	7/30	5/17	131/94
Mean casts, <i>n</i> (range)	9 (7-12)	7 (4-14)	10 (6-12)	8 (6-10)	7 (3-20)
Successful correction without surgery	67%	83%	71%	66%	78%

the providers at each center, reportedly patients who were wealthier or in more urban areas were more likely to have casts changed slightly more frequently, 7-8 d as opposed to 13-14. PAT's were performed under local anesthesia in clinics at 10 sites and in the operating theatre at 2 sites (18 study patients) for better infection control and sterile instruments.

If the number of casts required for correction can serve as a proxy for the severity of a clubfoot, neglected clubfoot can be described simply as a more severe form of idiopathic clubfoot in a newborn. The average number of casts required in newborns is around 5 with a correction rate around 90%^[4]. In our study and review of the literature, casts required for neglected cases is between 7 and 10 with successful correction rates from 66%-83%. The Ponseti method is nearly as successful on neglected clubfoot as in newborns at preventing the need for surgical intervention.

The phenotypic characteristics for cases in our study were similar to the reported rates of incidence of congenital idiopathic clubfoot in the literature^[24-27]. Fifty-eight percent of patients in our study population were male, consistent with the evidence that males are twice as likely to be affected. Also, in concordance with the evidence that half of cases occur bilaterally, 46% of our cases were bilateral and 54% were unilateral. This is significant because there has not been profound gender or laterality bias in presentation of neglected cases. Therefore, these factors do not seem to affect parents' willingness to seek treatment for their children before age 1.

One intriguing finding in our study is that the percutaneous Achilles tenotomy rate seems to be lower than in much of the literature^[5-11]. There are a few unique factors that could be causing this finding. The first is that there was considerable variability in rate of tenotomy between different centers. Costs for sterile equipment, local anesthetic and time required may be causing some providers to increase the number of casts to achieve necessary dorsiflexion rather than performing a PAT. It is also possible that some of the cases treated were actually positional equinovarus deformity rather than true talipes equinovarus, and did not require tenotomy. General guidelines for the Ponseti method recommend that a clubfoot achieve 15° of dorsiflexion to be considered corrected^[22]. More research into the tenotomy rate for neglected clubfoot worldwide and for all idiopathic clubfoot in Nigeria would be encouraged.

Our study has some potential limitations. During the course of treatment, 47 patients were lost to follow

up. In the setting of a developing country, patients are often lost to follow-up because of socioeconomic factors such as costs, transportation, and lack of social support and behavioral factors such as feeling improved function mid-treatment and knowledge deficit about duration of treatment^[24]. Data collection was variable between centers so 32 neglected clubfoot patients had to be excluded from the initial study population because there was not enough treatment data. If more data could be recorded, research into the feasibility of Pirani and Dimeglio scoring for neglected clubfoot would be very helpful and could aid providers in guiding their manipulation and casting to each individual. The current algorithm for Ponseti treatment of neglected clubfoot is provided in Figure 3.

In conclusion, this study has shown that the Ponseti method can be effectively used to correct neglected clubfoot in children older than walking age. If the method is performed properly, it will significantly reduce the need for bony surgery or major soft tissue release.

ACKNOWLEDGMENTS

This study was made possible by the creation of the Nigerian Sustainable Clubfoot Childcare Program (NS CCP), a nonprofit organization established to be a leader and model for clubfoot treatment throughout Africa. The NSCCP combines physicians, parents, and clubfoot advocates in efforts to increase public awareness, especially among local healthcare workers such as midwives. It also helps organize Ponseti trainings for orthopaedic surgeons and collaboration between those who are treating clubfoot frequently. It was the collaboration of the physicians who are part of the NSCCP that led this study and shows the benefit the Ponseti method has on neglected clubfoot in Nigeria.

COMMENTS

Background

Clubfoot is the most common musculoskeletal birth defect and left untreated, can result in lifelong disability and hardship. The Ponseti method involving serial manipulation and casting has become the gold standard in treatment of clubfoot. In low resource and developing countries, neglected clubfoot, or clubfoot that is untreated by one year of age, is a significant problem because of limited access to healthcare. In this study, the authors evaluated the efficacy of the Ponseti method in treating neglected clubfoot in 12 centers in Nigeria.

Research frontiers

Currently, there is very little literature on the effectiveness of the Ponseti method in clubfoot patients over age one. The current studies are on small populations

Algorithm No. 3
Management of idiopathic clubfoot
Patient walking

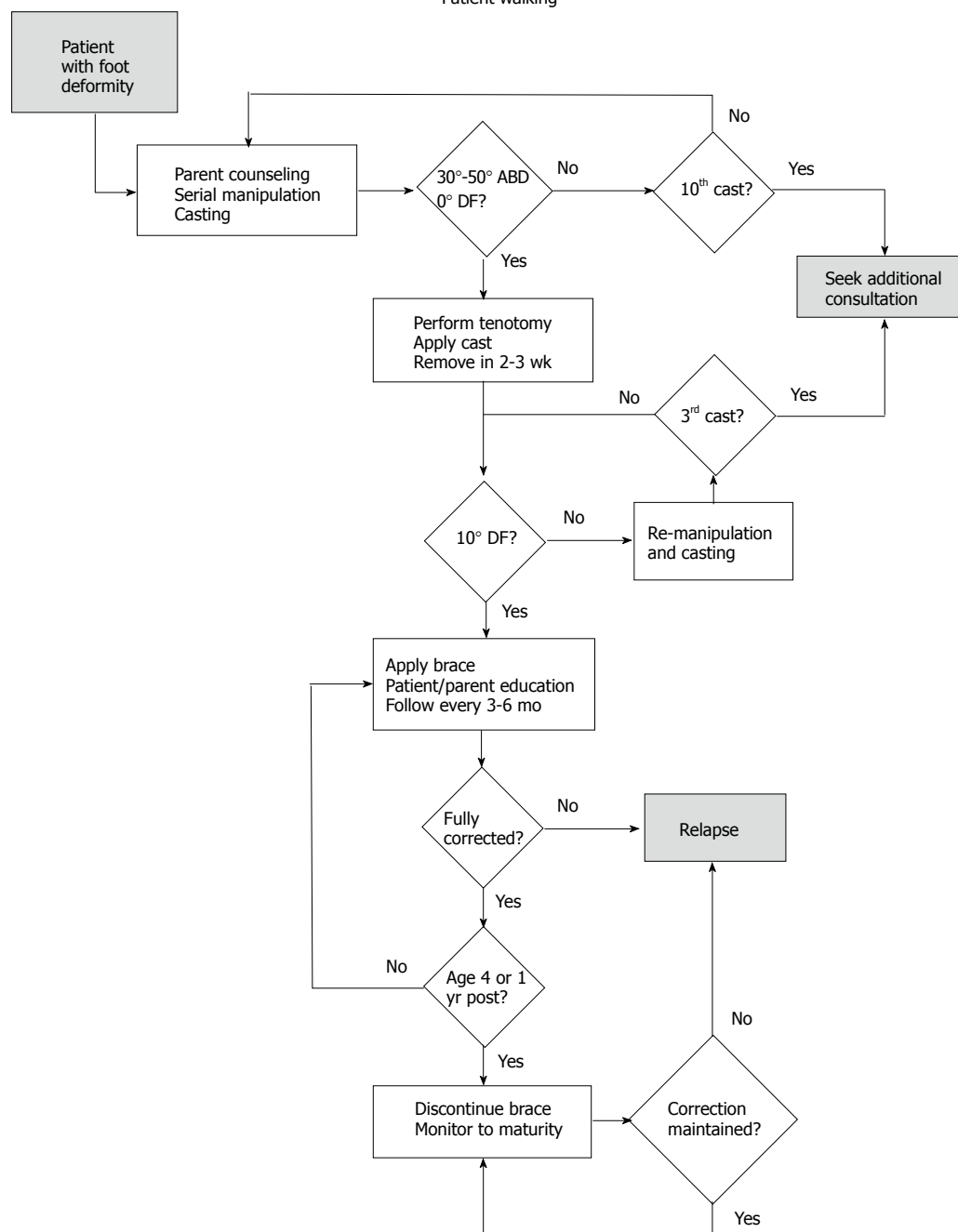


Figure 3 Neglected clubfoot treatment algorithm. Adapted form Ref. [29].

but have shown significant success.

Innovations and breakthroughs

In this study, the Ponseti method was successful in the initial correction of 78% of neglected clubfeet. These results are in concurrence with previous, smaller studies which showed similar correction rates.

Applications

This study suggests that providers throughout the world who are treating neglected clubfoot should begin with the Ponseti method as it can be performed at low cost and is highly effective.

Terminology

PAT: Percutaneous achilles tenotomy - minimally invasive procedure involving

the nicking of the heel cord in order to achieve maximal stretching in the final phase of treatment.

Peer-review

The paper is interesting and emphasizing the statement that Ponseti method can be effectively used to correct neglected clubfoot in children older than walking age, and significantly reduce the need for bony surgery or major soft tissue release.

REFERENCES

- 1 Wynne-Davies R. Genetic and environmental factors in the etiology of talipes equinovarus. *Clin Orthop Relat Res* 1972; **84**: 9-13 [PMID: 5032855]
- 2 “Nigeria”. The World Factbook. Central Intelligence Agency, 2016.

- [accessed 2016 Jan 1]. Available from: URL: <https://www.cia.gov/library/publications/the-world-factbook/geos/ni.html>
- 3 **Akintayo OA**, Adegbehingbe O, Cook T, Morcuende JA. Initial program evaluation of the Ponseti method in Nigeria. *Iowa Orthop J* 2012; **32**: 141-149 [PMID: 23576935]
 - 4 **Jowett CR**, Morcuende JA, Ramachandran M. Management of congenital talipes equinovarus using the Ponseti method: a systematic review. *J Bone Joint Surg Br* 2011; **93**: 1160-1164 [PMID: 21911524 DOI: 10.1302/0301-620X.93B9.26947]
 - 5 **Ponseti IV**. Treatment of congenital clubfoot. *J Bone Joint Surg Am* 1992; **74A**: 448-454 [DOI: 10.2106/00004623-199274030-00021]
 - 6 **Ponseti IV**. Common errors in the treatment of congenital clubfoot. *Int Orthop* 1997; **21**: 137-141 [PMID: 9195271 DOI: 10.1007/s002640050137]
 - 7 **Ponseti IV**. Congenital Clubfoot: Fundamentals of Treatment. UK: Oxford University Press, 1996
 - 8 **Lourenço AF**, Morcuende JA. Correction of neglected idiopathic club foot by the Ponseti method. *J Bone Joint Surg Br* 2007; **89**: 378-381 [PMID: 17356154 DOI: 10.1302/0301-620X.89B3.18313]
 - 9 **Spiegel DA**, Shrestha OP, Sitoula P, Rajbhandary T, Bijukachhe B, Banskota AK. Ponseti method for untreated idiopathic clubfeet in Nepalese patients from 1 to 6 years of age. *Clin Orthop Relat Res* 2009; **467**: 1164-1170 [PMID: 18987922 DOI: 10.1007/s11999-008-0600-1]
 - 10 **Banskota B**, Banskota AK, Regmi R, Rajbhandary T, Shrestha OP, Spiegel DA. The Ponseti method in the treatment of children with idiopathic clubfoot presenting between five and ten years of age. *Bone Joint J* 2013; **95-B**: 1721-1725 [PMID: 24293606 DOI: 10.1302/0301-620X.95B12.32173]
 - 11 **Khan SA**, Kumar A. Ponseti's manipulation in neglected clubfoot in children more than 7 years of age: a prospective evaluation of 25 feet with long-term follow-up. *J Pediatr Orthop B* 2010; **19**: 385-389 [PMID: 20581694 DOI: 10.1097/BPB.0b013e3283387cc8]
 - 12 **Verma A**, Mehtani A, Sural S, Maini L, Gautam VK, Basran SS, Arora S. Management of idiopathic clubfoot in toddlers by Ponseti's method. *J Pediatr Orthop B* 2012; **21**: 79-84 [PMID: 21666506 DOI: 10.1097/BPB.0b013e328347a329]
 - 13 **Faizan M**, Jilani LZ, Abbas M, Zahid M, Asif N. Management of Idiopathic Clubfoot by Ponseti Technique in Children Presenting After One Year of Age. *J Foot Ankle Surg* 2015; **54**: 967-972 [PMID: 25128311 DOI: 10.1053/j.jfas.2014.05.009]
 - 14 **Ayana B**, Klungsøyr PJ. Good results after Ponseti treatment for neglected congenital clubfoot in Ethiopia. A prospective study of 22 children (32 feet) from 2 to 10 years of age. *Acta Orthop* 2014; **85**: 641-645 [PMID: 25175659 DOI: 10.3109/17453674.2014.957085]
 - 15 **Sinha A**, Mehtani A, Sud A, Vijay V, Kumar N, Prakash J. Evaluation of Ponseti method in neglected clubfoot. *Indian J Orthop* 2016; **50**: 529-535 [PMID: 27746497 DOI: 10.4103/0019-5413.189597]
 - 16 **Bashi RH**, Baghdadi T, Shirazi MR, Abdi R, Aslani H. Modified Ponseti method of treatment for correction of neglected clubfoot in older children and adolescents--a preliminary report. *J Pediatr Orthop B* 2016; **25**: 99-103 [PMID: 26683370 DOI: 10.1097/BPB.0000000000000266]
 - 17 **Pirani S**, Outerbridge HK, Sawatzky B, Stothers K. A reliable method of clinically evaluating a virgin clubfoot evaluation. 21st SICOT Congress, 1999
 - 18 **Wientroub S**, Khermosh O. Comparative evaluation of initial surgical procedures in clubfoot. *J Pediatr Orthop* 1994; **3-B**: 171-179 [DOI: 10.1097/01202412-199403020-00009]
 - 19 **Dyer PJ**, Davis N. The role of the Pirani scoring system in the management of club foot by the Ponseti method. *J Bone Joint Surg Br* 2006; **88**: 1082-1084 [PMID: 16877610 DOI: 10.1302/0301-620X.88.B8.17482]
 - 20 **Carroll NC**. Clubfoot: what have we learned in the last quarter century? *J Pediatr Orthop* 1997; **17**: 1-2 [PMID: 8989690 DOI: 10.1097/01241398-199701000-00001]
 - 21 **Haasbeek JF**, Wright JG. A comparison of the long-term results of posterior and comprehensive release in the treatment of clubfoot. *J Pediatr Orthop* 1997; **17**: 29-35 [PMID: 8989698 DOI: 10.1097/0000-4694-199701000-00009]
 - 22 **Morcuende JA**, Dolan LA, Dietz FR, Ponseti IV. Radical reduction in the rate of extensive corrective surgery for clubfoot using the Ponseti method. *Pediatrics* 2004; **113**: 376-380 [PMID: 14754952 DOI: 10.1542/peds.113.2.376]
 - 23 **Adegbehingbe OO**, Oginni LM, Ogundele OJ, Ariyibi AL, Abiola PO, Ojo OD. Ponseti clubfoot management: changing surgical trends in Nigeria. *Iowa Orthop J* 2010; **30**: 7-14 [PMID: 21045965]
 - 24 **Kancherla V**, Romitti PA, Caspers KM, Puzhankara S, Morcuende JA. Epidemiology of congenital idiopathic talipes equinovarus in Iowa, 1997-2005. *Am J Med Genet A* 2010; **152A**: 1695-1700 [PMID: 20583169 DOI: 10.1002/ajmg.a.33481]
 - 25 **Alderman BW**, Takahashi ER, LeMier MK. Risk indicators for talipes equinovarus in Washington State, 1987-1989. *Epidemiology* 1991; **2**: 289-292 [PMID: 1912045 DOI: 10.1097/00001648-19910700-000009]
 - 26 **Palma M**, Cook T, Segura J, Pecho A, Morcuende JA. Descriptive epidemiology of clubfoot in Peru: a clinic-based study. *Iowa Orthop J* 2013; **33**: 167-171 [PMID: 24027478]
 - 27 **McConnell L**, Cosma D, Vasilescu D, Morcuende J. Descriptive epidemiology of clubfoot in Romania: a clinic-based study. *Eur Rev Med Pharmacol Sci* 2016; **20**: 220-224 [PMID: 26875888]
 - 28 **Tola HH**, Tol A, Shojaeizadeh D, Garmaroudi G. Tuberculosis Treatment Non-Adherence and Lost to Follow Up among TB Patients with or without HIV in Developing Countries: A Systematic Review. *Iran J Public Health* 2015; **44**: 1-11 [PMID: 26060770]
 - 29 **Clinical Practice Guidelines for the Management of Clubfoot Deformity Using the Ponseti Method**. Ponseti International Association, Publication Date: November 1, 2015. Iowa City, IA, United States: The University of Iowa, 2015

P- Reviewer: Ibrahim MM, Spiegel DA **S- Editor:** Kong JX

L- Editor: A **E- Editor:** Lu YJ





Published by **Baishideng Publishing Group Inc**
7901 Stoneridge Drive, Suite 501, Pleasanton, CA 94588, USA
Telephone: +1-925-223-8242
Fax: +1-925-223-8243
E-mail: bpgoffice@wjgnet.com
Help Desk: <http://www.f6publishing.com/helpdesk>
<http://www.wjgnet.com>

