

World Journal of *Orthopedics*

World J Orthop 2017 August 18; 8(8): 606-659





EDITORIAL

- 606 Ultrasound diagnosis of fractures in mass casualty incidents
Abu-Zidan FM

MINIREVIEWS

- 612 Postoperative deep shoulder infections following rotator cuff repair
Atesok K, MacDonald P, Leiter J, McRae S, Stranges G, Old J
- 619 Synthesis of evidence for the treatment of intersection syndrome
Balakatounis K, Angoules AG, Angoules NA, Panagiotopoulou K

ORIGINAL ARTICLE

Retrospective Study

- 624 Ponseti method treatment of neglected idiopathic clubfoot: Preliminary results of a multi-center study in Nigeria
Adegbehingbe OO, Adetiloye AJ, Adewole L, Ajodo DU, Bello N, Esan O, Hoover AC, Ior J, Lasebikan O, Ojo O, Olasinde A, Songden D, Morcuende JA

Observational Study

- 631 Functional outcomes of traumatic and non-traumatic rotator cuff tears after arthroscopic repair
Abechain JJK, Godinho GG, Matsunaga FT, Netto NA, Daou JP, Tamaoki MJS

SYSTEMATIC REVIEWS

- 638 Ipsilateral femur and tibia fractures in pediatric patients: A systematic review
Anari JB, Neuwirth AL, Horn BD, Baldwin KD

META-ANALYSIS

- 644 Femoral positioning influences ipsi-and contralateral anterior cruciate ligament rupture following its reconstruction: Systematic review and meta-analysis
de Campos GC, Teixeira PEP, Castro A, Alves Junior WM

CASE REPORT

- 651 Open wound management of esophagocutaneous fistula in unstable cervical spine after corpectomy and multilevel laminectomy: A case report and review of the literature
Elgafy H, Khan M, Azurdia J, Peters N
- 656 Bennett's fracture associated with fracture of Trapezium - A rare injury of first carpo-metacarpal joint
Goyal T

Contents

World Journal of Orthopedics
Volume 8 Number 8 August 18, 2017

ABOUT COVER

Editorial Board Member of *World Journal of Orthopedics*, Melanie Jane Franklyn, PhD, Academic Fellow, Academic Research, Department of Mechanical Engineering, The University of Melbourne, Melbourne, Victoria 3010, Australia

AIM AND SCOPE

World Journal of Orthopedics (*World J Orthop*, *WJO*, online ISSN 2218-5836, DOI: 10.5312) is a peer-reviewed open access academic journal that aims to guide clinical practice and improve diagnostic and therapeutic skills of clinicians.

WJO covers topics concerning arthroscopy, evidence-based medicine, epidemiology, nursing, sports medicine, therapy of bone and spinal diseases, bone trauma, osteoarthropathy, bone tumors and osteoporosis, minimally invasive therapy, diagnostic imaging. Priority publication will be given to articles concerning diagnosis and treatment of orthopedic diseases. The following aspects are covered: Clinical diagnosis, laboratory diagnosis, differential diagnosis, imaging tests, pathological diagnosis, molecular biological diagnosis, immunological diagnosis, genetic diagnosis, functional diagnostics, and physical diagnosis; and comprehensive therapy, drug therapy, surgical therapy, interventional treatment, minimally invasive therapy, and robot-assisted therapy.

We encourage authors to submit their manuscripts to *WJO*. We will give priority to manuscripts that are supported by major national and international foundations and those that are of great basic and clinical significance.

INDEXING/ABSTRACTING

World Journal of Orthopedics is now indexed in Emerging Sources Citation Index (Web of Science), PubMed, PubMed Central and Scopus.

FLYLEAF

I-III Editorial Board

EDITORS FOR THIS ISSUE

Responsible Assistant Editor: *Xiang Li*
Responsible Electronic Editor: *Ya-Jing Lu*
Proofing Editor-in-Chief: *Lian-Sheng Ma*

Responsible Science Editor: *Fang-Fang Ji*
Proofing Editorial Office Director: *Jin-Lei Wang*

NAME OF JOURNAL
World Journal of Orthopedics

ISSN
ISSN 2218-5836 (online)

LAUNCH DATE
November 18, 2010

FREQUENCY
Monthly

EDITORS-IN-CHIEF
Quanjun (Trey) Cui, MD, Professor, Department of Orthopaedic Surgery, School of Medicine, University of Virginia, Charlottesville, VA 22908, United States

Bao-Gan Peng, MD, PhD, Professor, Department of Spinal Surgery, General Hospital of Armed Police Force, Beijing 100039, China

EDITORIAL BOARD MEMBERS
All editorial board members resources online at <http://www.wjgnet.com>

www.wjgnet.com/2218-5836/editorialboard.htm

EDITORIAL OFFICE
Xiu-Xia Song, Director
World Journal of Orthopedics
Baishideng Publishing Group Inc
7901 Stoneridge Drive, Suite 501, Pleasanton, CA 94588, USA
Telephone: +1-925-2238242
Fax: +1-925-2238243
E-mail: editorialoffice@wjgnet.com
Help Desk: <http://www.fjpublishing.com/helpdesk>
<http://www.wjgnet.com>

PUBLISHER
Baishideng Publishing Group Inc
7901 Stoneridge Drive,
Suite 501, Pleasanton, CA 94588, USA
Telephone: +1-925-2238242
Fax: +1-925-2238243
E-mail: bpgoffice@wjgnet.com
Help Desk: <http://www.fjpublishing.com/helpdesk>
<http://www.wjgnet.com>

PUBLICATION DATE
August 18, 2017

COPYRIGHT
© 2017 Baishideng Publishing Group Inc. Articles published by this Open-Access journal are distributed under the terms of the Creative Commons Attribution Non-commercial License, which permits use, distribution, and reproduction in any medium, provided the original work is properly cited, the use is non commercial and is otherwise in compliance with the license.

SPECIAL STATEMENT
All articles published in journals owned by the Baishideng Publishing Group (BPG) represent the views and opinions of their authors, and not the views, opinions or policies of the BPG, except where otherwise explicitly indicated.

INSTRUCTIONS TO AUTHORS
<http://www.wjgnet.com/bpg/gerinfo/204>

ONLINE SUBMISSION
<http://www.fjpublishing.com>

Bennett's fracture associated with fracture of Trapezium - A rare injury of first carpo-metacarpal joint

Tarun Goyal

Tarun Goyal, Department of Orthopaedics, All India Institute of Medical Sciences, Rishikesh 248201, India

Author contributions: Goyal T conducted the study and compiled the report.

Institutional review board statement: Institutional review board approval granted from AIIMS Rishikesh.

Informed consent statement: Written informed consent taken from patient prior to inclusion.

Conflict-of-interest statement: Author declares that there is no conflict of interests.

Open-Access: This article is an open-access article which was selected by an in-house editor and fully peer-reviewed by external reviewers. It is distributed in accordance with the Creative Commons Attribution Non Commercial (CC BY-NC 4.0) license, which permits others to distribute, remix, adapt, build upon this work non-commercially, and license their derivative works on different terms, provided the original work is properly cited and the use is non-commercial. See: <http://creativecommons.org/licenses/by-nc/4.0/>

Manuscript source: Unsolicited manuscript

Correspondence to: Dr. Tarun Goyal, Assistant Professor, Department of Orthopaedics, All India Institute of Medical Sciences, Virbhadra Marg, Rishikesh 248201, India. goyal.tarun@gmail.com
Telephone: +91-847-5000283
Fax: +91-135-2462976

Revised: July 14, 2016

Peer-review started: July 29, 2016

First decision: October 21, 2016

Revised: January 22, 2017

Accepted: February 18, 2017

Article in press: February 20, 2017

Published online: August 18, 2017

Abstract

Association of fracture of trapezium with Bennett's

fracture is very rare and makes reduction and stabilisation more difficult. We are reporting a rare case of Bennett's fracture with fracture of the trapezium and subluxation of the carpo-metacarpal joint (CMC) joint. The patient was a 47-year-old school teacher who fell from his motorbike on his outstretched right dominant hand. Radiographs and computed tomography showed fracture of the trapezium with subluxation of the CMC joint, associated with Bennett's fracture. Open reduction and internal fixation was carried out. Trapezium was reduced first and secured with a 2 mm diameter screw. Bennett's fracture was then reduced and fixed with two per-cutaneously placed Kirchner's wires. CMC was stabilised with per-cutaneous Kirchner's wires. Latest follow up at 12 mo showed a healed fracture with good reduction of the CMC joint. Clinically patient had no pain and normal extension, abduction and opposition of the thumb. QuickDASH score was 3.9/100. Thus, fracture of trapezium associated with a Bennett's fracture is a rare injury and if ignored it may lead to poor results. This injury is more challenging to manage than an isolated Bennett's fracture as anatomical reduction of the trapezium with reduction of the first CMC is needed. Fracture of the trapezium should be fixed first as this will provide a stable base for reduction of the Bennett's fracture.

Key words: Bennett's fracture; Carpo-metacarpal joint; Trapezium

© **The Author(s) 2017.** Published by Baishideng Publishing Group Inc. All rights reserved.

Core tip: Association of fracture of the trapezium with Bennett's fracture is very rare and makes reduction and stabilisation more difficult. We are reporting a rare case of Bennett's fracture with fracture of the trapezium and subluxation of the carpo-metacarpal joint (CMC) joint, and describing a technique for successful reduction and stabilisation of these fractures. Trapezium should be reduced first and secured with a 2 mm diameter screw. Bennett's fracture should then be reduced and fixed with two per-cutaneously placed Kirchner's wires. CMC should

be stabilised with per-cutaneous Kirchner's wires. This is expected to result in good functional outcomes.

Goyal T. Bennett's fracture associated with fracture of Trapezium - A rare injury of first carpo-metacarpal joint. *World J Orthop* 2017; 8(8): 656-659 Available from: URL: <http://www.wjgnet.com/2218-5836/full/v8/i8/656.htm> DOI: <http://dx.doi.org/10.5312/wjo.v8.i8.656>

INTRODUCTION

Bennett's fracture typically involves an intra-articular fracture of the base of the first metacarpal with dislocation of the carpo-metacarpal joint (CMC). This represents avulsion of the attachment of the volar oblique ligament. Most common mechanism is fall on hand with thumb in abduction or extension. Fractures of the trapezium are rare and accounts for only 3%-5% of carpal fractures^[1,2]. Association of fracture of trapezium with a Bennett's fracture is very rare. Presence of fracture of trapezium makes reduction and stabilisation of the Bennett's fracture more challenging. High degree of clinical suspicion is necessary as CMC injuries may be a result of indirect force resulting in little swelling^[3]. Neglected or untreated injuries may lead to degenerative changes of the CMC joint resulting in pain during grip and pinch.

We are reporting a case of Bennett's fracture with fracture of the trapezium and disruption of CMC joint. This is an extremely rare injury and only a few cases have been mentioned in literature before^[4-7]. Open reduction and internal fixation was carried out and clinical and radiological outcomes were good at 6 mo of follow up.

CASE REPORT

The patient was a 47-year-old school teacher who fell from his motorbike on his outstretched right hand. He was right hand dominant. Radiographs showed fracture of the trapezium with subluxation of the CMC joint, associated with Bennett's fracture (Figure 1).

Patient was operated five days after the injury under general anaesthesia. Fracture site was approached using a curved incision beginning at the dorso-radial border of the first metacarpal bone, curving along the junction of the palmar and dorsal skin, to the distal wrist crease. Base of the first metacarpal was recognised which helped in identification of the CMC joint and the trapezium. Trapezium was reduced first and secured with a 0.045-inch Kirchner wire (Figure 2). A 2 mm diameter screw was used to secure the fracture. Bennett's fracture was reduced and fixed with two per-cutaneously inserted 0.045-inch Kirchner's wires (Figure 3). The CMC joint was further stabilised with a per-cutaneously inserted 0.045-inch Kirchner's

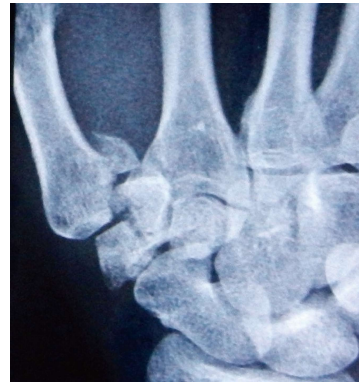

Figure 1 Preoperative radiograph showing the Bennett's fracture with fracture of the trapezium.

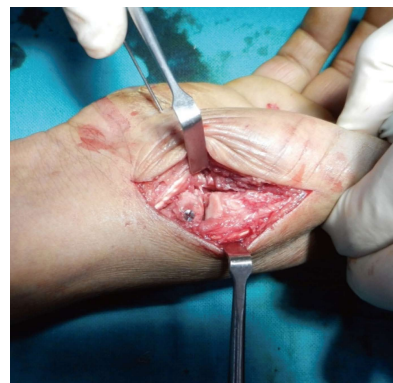

Figure 2 Intraoperative photograph showing the surgical approach, fixation of the capitulum with screw and reduction of the carpo-metacarpal joint.

wire. Limb was put in a thumb spica cast.

Sutures were removed at 10 d followed by removal of Kirchner wires at 3 wk. Cast was continued for a total of 8 wk after the surgery. Range of motion and gripping exercises were begun after the cast was removed.

Latest follow up at 12 mo showed no fracture lines, with good reduction of the CMC joint. Clinically patient had no pain and normal extension, abduction and opposition of the thumb (Figure 4). Stress testing of the CMC revealed normal ligaments. QuickDASH score was 3.9/100^[8].

DISCUSSION

Most probable mechanism of Bennett's fracture with fracture of the trapezium is axial loading of a partially flexed metacarpal bone. Axial loading in a flexed thumb may initially result in a Bennett's type fracture due to bony avulsion of the anterior oblique ligament. This Bennett's fragment represents the ulnar-volar part of the base of the metacarpal and has strong capsulo-ligamentous attachments. If the Bennett's fragment is small and axial loading continues, trapezium will be impacted between the remaining part of metacarpal base and the radial styloid resulting in a vertically split or

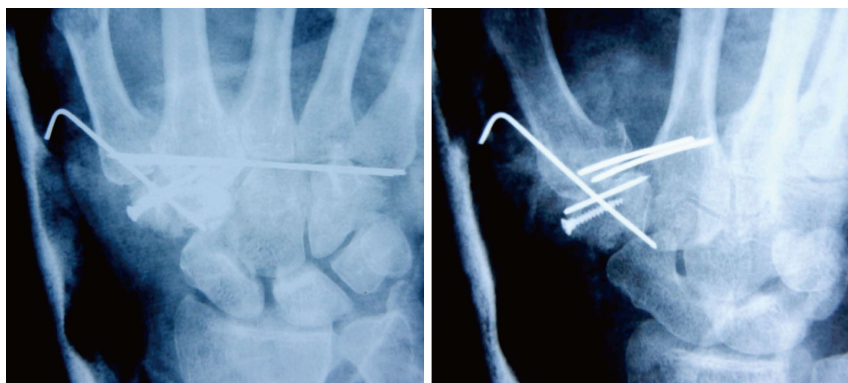


Figure 3 Postoperative radiograph showing reduction of fracture fragments and the carpo-metacarpal joint.

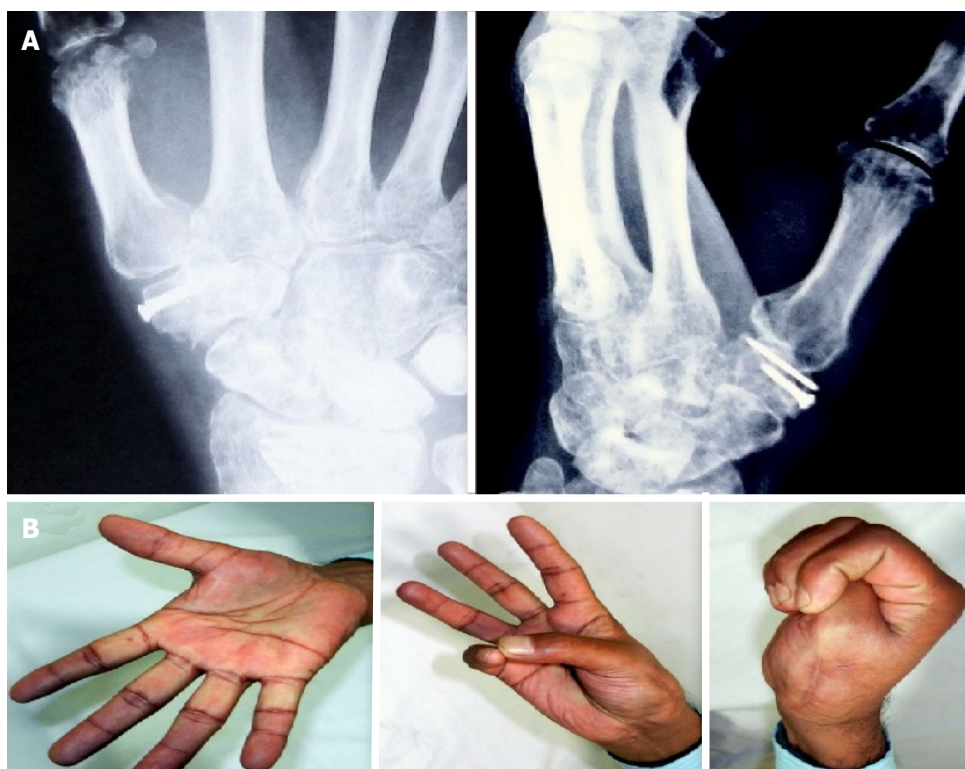

Figure 4 Clinico-radiological follow-up at 6 mo. A: Radiograph at 6 mo follow up showing a healed fracture with maintainance of joint reduction; B: Clinical photograph showing good range of motion.

comminuted fracture of the trapezium. An alternative mechanism of injury could be a hyper-abduction shearing force on the first web-space. This can be seen commonly if a person suffers deceleration injury while holding a handlebar, resulting a commissural shearing force on the first web-space. This may also occur if a person falls on the radial side of the hand with thumb in abduction, so that the first web-space suffers a commissural force.

Stable reduction of the CMC joint and restoring congruity of the articular surface is the goal of treatment^[9,10]. Residual subluxation of the joint or intra-articular displacement of more than 4 mm may lead to poor functional outcomes^[11].

Fractures of carpal bones of hand, and subluxations

of CMCs may be overlooked as soft tissue injuries unless specifically looked for. This will result in poor functional outcomes in long-term follow-up. The type of views imaged or quality of the radiographs may frequently contribute to a missed diagnosis. Appropriate true antero-posterior and lateral radiographs of CMC joint should be insisted. Special views such as Bett view is useful, in which the hand is pronated approximately 20°-30° and the imaging beam is directed obliquely at 15° in a distal to proximal direction, centered over the trapeziometacarpal joint. Computed tomography is a useful imaging modality to study complex fractures of the hand and provides better anatomical details.

Injuries to the CMC joint should be carefully searched

for in patients with intra-articular fractures of the trapezium. These may be associated with the Bennett's fracture, as in this case, or with purely ligamentous injury to the CMC joint. McGuigan and Culp reported 11 patients with intra-articular fractures of the trapezium, four of which were associated with the Bennett's fracture^[4]. Three of these fractures were initially unnoticed. All these patients had good clinical outcomes with open reduction and internal fixation in terms of range of motion, pain and patient satisfaction.

In this case the Bennett's fracture was associated with the vertically split fracture of the trapezium. These fractures require open reduction and internal fixation in order to control reduction of both these fractures. The fracture of trapezium was fixed first with a K wire and a screw to provide a stable platform for reduction of the Bennett's fracture. Bennett's fracture was then fixed with K wires. This gave excellent results at follow up.

Thus, fracture of trapezium associated with a Bennett's fracture is a rare injury and if ignored it may lead to poor results. Fracture of the trapezium should be fixed first as this will provide a stable base for reduction of the Bennett's fracture.

COMMENTS

Case characteristics

This was a rare case of carpal injuries.

Clinical diagnosis

Bennett's fracture dislocation with fracture of Trapezium.

Differential diagnosis

Bennett's fracture dislocation.

Imaging diagnosis

Plain radiographs and computed tomography scan confirmed the diagnosis

Treatment

The fracture of trapezium was fixed first with a K wire and a screw to provide a stable platform for reduction of the Bennett's fracture which was then fixed with K wires.

Experiences and lessons

This is a rare injury and if missed may make the reduction and stabilisation of Bennett's fracture dislocation difficult.

Peer-review

This is generally a good paper.

REFERENCES

- 1 **Borgeskov S**, Christiansen B, Kjaer A, Balslev I. Fractures of the carpal bones. *Acta Orthop Scand* 1966; **37**: 276-287 [PMID: 5955131 DOI: 10.3109/17453676608989415]
- 2 **Kam ML**, Sreedharan S, Teoh LC, Chew WY. Severe isolated trapezoid fracture: a case report. *Hand Surg* 2011; **16**: 185-187 [PMID: 21548157 DOI: 10.1142/S0218810411005321]
- 3 **Ramoutar DN**, Katevu C, Titchener AG, Patel A. Trapezium fracture - a common technique to fix a rare injury: a case report. *Cases J* 2009; **2**: 8304 [PMID: 19918416 DOI: 10.4076/1757-16262-8304]
- 4 **McGuigan FX**, Culp RW. Surgical treatment of intra-articular fractures of the trapezium. *J Hand Surg Am* 2002; **27**: 697-703 [PMID: 12132098 DOI: 10.1053/jhsu.2002.33705]
- 5 **El Ibrahim A**, Amar F, Chbani B, Daoudi A, Elmrini A, Boutayeb F. Dislocation of the carpometacarpal joint of the thumb associated with trapezium and Bennett's fractures. *Hand (N Y)* 2009; **4**: 191-193 [PMID: 19156465 DOI: 10.1007/s11552-008-9162-7]
- 6 **Garcia-Elias M**, Henríquez-Lluch A, Rossignani P, Fernandez de Retana P, Orovio de Elizaga J. Bennett's fracture combined with fracture of the trapezium. A report of three cases. *J Hand Surg Br* 1993; **18**: 523-526 [PMID: 8409673 DOI: 10.1016/0266-7681(93)90164-B]
- 7 **Radford PJ**, Wilcox DT, Holdsworth BJ. Simultaneous trapezium and Bennett's fractures. *J Hand Surg Am* 1992; **17**: 621-623 [PMID: 1308096 DOI: 10.1016/0363-5023(92)90304-8]
- 8 **Beaton DE**, Wright JG, Katz JN; Upper Extremity Collaborative Group. Development of the QuickDASH: comparison of three item-reduction approaches. *J Bone Joint Surg Am* 2005; **87**: 1038-1046 [PMID: 15866967 DOI: 10.2106/JBJS.D.02060]
- 9 **Thurston AJ**, Dempsey SM. Bennett's fracture: a medium to long-term review. *Aust N Z J Surg* 1993; **63**: 120-123 [PMID: 8297298 DOI: 10.1111/j.1445-2197.1993.tb00058.x]
- 10 **Timmenga EJ**, Blokhuis TJ, Maas M, Raaijmakers EL. Long-term evaluation of Bennett's fracture. A comparison between open and closed reduction. *J Hand Surg Br* 1994; **19**: 373-377 [PMID: 8077832 DOI: 10.1016/0266-7681(94)90093-0]
- 11 **Walker JL**, Greene TL, Lunseth PA. Fractures of the body of the trapezium. *J Orthop Trauma* 1988; **2**: 22-28 [PMID: 3225697 DOI: 10.1097/00005131-198802000-00006]

P- Reviewer: Franklyn MJ, Karalezli N, Martin-Ferrero M

S- Editor: Ji FF L- Editor: A E- Editor: Lu YJ





Published by **Baishideng Publishing Group Inc**
7901 Stoneridge Drive, Suite 501, Pleasanton, CA 94588, USA
Telephone: +1-925-223-8242
Fax: +1-925-223-8243
E-mail: bpgoffice@wjgnet.com
Help Desk: <http://www.f6publishing.com/helpdesk>
<http://www.wjgnet.com>

