

World Journal of *Orthopedics*

World J Orthop 2017 September 18; 8(9): 660-746



**DIAGNOSTIC ADVANCES**

- 660 Clinical applications of advanced magnetic resonance imaging techniques for arthritis evaluation
Martín Noguerol T, Luna A, Gómez Cabrera M, Riofrio AD

MINIREVIEWS

- 674 Mesenchymal stem cells for cartilage regeneration in osteoarthritis
Kristjánsson B, Honsawek S

ORIGINAL ARTICLE**Basic Study**

- 681 Electron probe microanalysis of experimentally stimulated osteoarthrosis in dogs
Stupina T, Shchudlo M, Stepanov M
- 688 Benefits of Ilizarov automated bone distraction for nerves and articular cartilage in experimental leg lengthening
Shchudlo N, Varsegova T, Stupina T, Shchudlo M, Saifutdinov M, Yemanov A

Retrospective Study

- 697 Lumbar ganglion cyst: Nosology, surgical management and proposal of a new classification based on 34 personal cases and literature review
Domenicucci M, Ramieri A, Marruzzo D, Missori P, Miscusi M, Tarantino R, Delfini R
- 705 Acetabular components with or without screws in total hip arthroplasty
Pepe M, Kocadal O, Erener T, Ceritoglu K, Aksahin E, Aktekin CN
- 710 Single-stage anterior debridement and reconstruction with tantalum mesh cage for complicated infectious spondylitis
Yang SC, Chen HS, Kao YH, Tu YK

Prospective Study

- 719 Association of adiponectin gene polymorphisms with knee osteoarthritis
Zhan D, Thumtecho S, Tanavalee A, Yuktanandana P, Anomasiri W, Honsawek S

SYSTEMATIC REVIEWS

- 726 Osteoarthritis action alliance consensus opinion - best practice features of anterior cruciate ligament and lower limb injury prevention programs
Trojan T, Driban J, Nuti R, Distefano L, Root H, Nistler C, LaBella C

CASE REPORT

- 735 Using humeral nail for surgical reconstruction of femur in adolescents with osteogenesis imperfecta
Sa-ngasoongsong P, Saisongcroh T, Angsanuntsukh C, Woratanarat P, Mulpruek P
- 741 Hernia mesh prevent dislocation after wide excision and reconstruction of giant cell tumor distal radius
Wiratnaya IGE, Budiarta IGBAM, Setiawan IGNU, Sindhughosa DA, Kawiya IKS, Astawa P

ABOUT COVER

Editorial Board Member of *World Journal of Orthopedics*, Michel PJ van den Bekerom, MD, Staff Physician, Department of Orthopaedic Surgery, Shoulder and Elbow Unit, OLVG, Amsterdam 1090, The Netherlands

AIM AND SCOPE

World Journal of Orthopedics (*World J Orthop*, *WJO*, online ISSN 2218-5836, DOI: 10.5312) is a peer-reviewed open access academic journal that aims to guide clinical practice and improve diagnostic and therapeutic skills of clinicians.

WJO covers topics concerning arthroscopy, evidence-based medicine, epidemiology, nursing, sports medicine, therapy of bone and spinal diseases, bone trauma, osteoarthritis, bone tumors and osteoporosis, minimally invasive therapy, diagnostic imaging. Priority publication will be given to articles concerning diagnosis and treatment of orthopedic diseases. The following aspects are covered: Clinical diagnosis, laboratory diagnosis, differential diagnosis, imaging tests, pathological diagnosis, molecular biological diagnosis, immunological diagnosis, genetic diagnosis, functional diagnostics, and physical diagnosis; and comprehensive therapy, drug therapy, surgical therapy, interventional treatment, minimally invasive therapy, and robot-assisted therapy.

We encourage authors to submit their manuscripts to *WJO*. We will give priority to manuscripts that are supported by major national and international foundations and those that are of great basic and clinical significance.

INDEXING/ABSTRACTING

World Journal of Orthopedics is now indexed in Emerging Sources Citation Index (Web of Science), PubMed, PubMed Central and Scopus.

FLYLEAF

I-III Editorial Board

EDITORS FOR THIS ISSUE

Responsible Assistant Editor: *Xiang Li*
Responsible Electronic Editor: *Ya-Jing Lu*
Proofing Editor-in-Chief: *Lian-Sheng Ma*

Responsible Science Editor: *Fang-Fang Ji*
Proofing Editorial Office Director: *Jin-Lai Wang*

NAME OF JOURNAL
World Journal of Orthopedics

ISSN
ISSN 2218-5836 (online)

LAUNCH DATE
November 18, 2010

FREQUENCY
Monthly

EDITORS-IN-CHIEF
Quanjun (Trey) Cui, MD, Professor, Department of Orthopaedic Surgery, School of Medicine, University of Virginia, Charlottesville, VA 22908, United States

Bao-Gan Peng, MD, PhD, Professor, Department of Spinal Surgery, General Hospital of Armed Police Force, Beijing 100039, China

EDITORIAL BOARD MEMBERS
All editorial board members resources online at <http://www.wjgnet.com>

www.wjgnet.com/2218-5836/editorialboard.htm

EDITORIAL OFFICE
Xiu-Xia Song, Director
World Journal of Orthopedics
Baishideng Publishing Group Inc
7901 Stoneridge Drive, Suite 501, Pleasanton, CA 94588, USA
Telephone: +1-925-2238242
Fax: +1-925-2238243
E-mail: editorialoffice@wjgnet.com
Help Desk: <http://www.fjpublishing.com/helpdesk>
<http://www.wjgnet.com>

PUBLISHER
Baishideng Publishing Group Inc
7901 Stoneridge Drive,
Suite 501, Pleasanton, CA 94588, USA
Telephone: +1-925-2238242
Fax: +1-925-2238243
E-mail: bpgoffice@wjgnet.com
Help Desk: <http://www.fjpublishing.com/helpdesk>
<http://www.wjgnet.com>

PUBLICATION DATE
September 18, 2017

COPYRIGHT
© 2017 Baishideng Publishing Group Inc. Articles published by this Open-Access journal are distributed under the terms of the Creative Commons Attribution Non-commercial License, which permits use, distribution, and reproduction in any medium, provided the original work is properly cited, the use is non commercial and is otherwise in compliance with the license.

SPECIAL STATEMENT
All articles published in journals owned by the Baishideng Publishing Group (BPG) represent the views and opinions of their authors, and not the views, opinions or policies of the BPG, except where otherwise explicitly indicated.

INSTRUCTIONS TO AUTHORS
<http://www.wjgnet.com/bpg/gerinfo/204>

ONLINE SUBMISSION
<http://www.fjpublishing.com>

Using humeral nail for surgical reconstruction of femur in adolescents with osteogenesis imperfecta

Paphon Sa-ngasoongsong, Tanyawat Saisongcroh, Chanika Angsanuntsukh, Patarawan Woratanarat, Pornchai Mulpruek

Paphon Sa-ngasoongsong, Tanyawat Saisongcroh, Chanika Angsanuntsukh, Patarawan Woratanarat, Pornchai Mulpruek, Department of Orthopedics, Faculty of Medicine Ramathibodi Hospital, Mahidol University, Bangkok 10400, Thailand

Author contributions: Sa-ngasoongsong P and Mulpruek P performed all operations together; Sa-ngasoongsong P drafted manuscript; Saisongcroh T collected the patients' clinical data and drafted the manuscript; Angsanuntsukh C and Woratanarat P provided material and technical support; Mulpruek P designed the study and revised manuscript for important intellectual content; all authors have read and approved the final version to be published.

Institutional review board statement: The study was reviewed and approved by the Ethical Clearance Committee on Human Rights to Research Including Human Subjects, Faculty of Medicine Ramathibodi Hospital, Mahidol University (Protocol ID 02-58-67).

Informed consent statement: According to the ethical approval, there was no need for informed consent from individual patients in retrospective study (all data were retrieved from medical records).

Conflict-of-interest statement: All of the authors declare that they have no conflict of interest.

Open-Access: This article is an open-access article which was selected by an in-house editor and fully peer-reviewed by external reviewers. It is distributed in accordance with the Creative Commons Attribution Non Commercial (CC BY-NC 4.0) license, which permits others to distribute, remix, adapt, build upon this work non-commercially, and license their derivative works on different terms, provided the original work is properly cited and the use is non-commercial. See: <http://creativecommons.org/licenses/by-nc/4.0/>

Manuscript source: Invited manuscript

Correspondence to: Pornchai Mulpruek, MD, Clinical Professor, Department of Orthopedics, Faculty of Medicine Ramathibodi Hospital, Mahidol University, 270, Rama VI Road, Ratchathewi, Bangkok 10400, Thailand. pornchai.mul@mahidol.ac.th
Telephone: +66-2-2011589

Fax: +66-2-2011599

Received: January 27, 2017

Peer-review started: February 12, 2017

First decision: June 12, 2017

Revised: June 16, 2017

Accepted: July 21, 2017

Article in press: July 22, 2017

Published online: September 18, 2017

Abstract

Osteogenesis imperfecta (OI) is a rare inherited connective tissue disorder caused by mutation of collagen which results in a wide spectrum of clinical manifestations including long bone fragility fractures and deformities. While the treatment for these fractures was recommended as using intramedullary fixation for minimizing stress concentration, the selection of the best implant in the adolescent OI patients for the surgical reconstruction of femur was still problematic, due to anatomy distortion and implant availability. We are reporting the surgical modification by using a humeral nail for femoral fixation in three adolescent OI patients with favorable outcomes.

Key words: Osteogenesis imperfecta; Adolescent; Humeral nail; Femoral fracture; Femoral bowing deformity

© **The Author(s) 2017.** Published by Baishideng Publishing Group Inc. All rights reserved.

Core tip: This case report presented the satisfactory clinical outcome of the adolescent osteogenesis imperfecta patients suffering from femoral fracture or bowing deformity which had been treated with the modification of humeral nail as intramedullary implant.

Sa-ngasoongsong P, Saisongcroh T, Angsanuntsukh C, Woratanarat

P, Mulpruek P. Using humeral nail for surgical reconstruction of femur in adolescents with osteogenesis imperfecta. *World J Orthop* 2017; 8(9): 735-740 Available from: URL: <http://www.wjgnet.com/2218-5836/full/v8/i9/735.htm> DOI: <http://dx.doi.org/10.5312/wjo.v8.i9.735>

INTRODUCTION

Osteogenesis imperfecta (OI) is a rare hereditary connective tissue disorders with the common clinical presentation of excessive bone fragility caused by mutations in collagen^[1]. Clinical manifestations of OI are wide spectrum and could be vary from lethal forms in the perinatal period to the subtle forms, which could be hardly identified and comparable to a normal person. However, the common orthopaedic problems in the OI patients, that is related to the excessive fragility, are frequent fractures, progressive deformity of long bones and impaired ambulation. The treatment of OI requires a multidisciplinary approach including both medical treatment, such as using bisphosphonates therapy to increase bone mineral density and reduce long bone fractures rate^[2-4], and surgical treatment for fracture fixation or deformity correction^[4].

Regarding surgical management of OI, the treatment goals are to minimize the incidence of fracture, restore bone axis and avoid bone bowing^[4]. The recommended surgical implant in OI was a load-sharing intramedullary (IM) device, with the largest diameter as possible, due to the better biomechanical property in fragile bone over plate construct^[1] and avoid plate-related complications, such as bony resorption from stress shielding, implant failure, and subsequent fracture at the plate ending^[5,6]. However, the surgical fixation in OI, especially in adolescent OI patients with femoral fracture or nonunion, are still problematic due to particular abnormal femoral anatomy (such as short limb, non-anatomical alignment secondary to previous injury, and narrow and non-linear medullary canal with superphysiologic bowing)^[1] resulting in implant selection difficulty which was suitable for medullary canal size and bone length. Although there is an advanced surgical system, like a telescopic rod, which is specifically designed for OI patients with many different sizes that allow fixation in all age groups, this implant is not available everywhere, including our country. Moreover, the traditional implant standard pediatric IM devices such as single Rush pin might not be appropriate in these adolescent OI patients due to its small size and inability to provide rotational stability^[6-8]. Recently, there has been a few studies which reported that the small IM interlocking nail, such as humeral nail, could be used in femoral fixation in normal adolescent patients due to the advantages of the entry point lateral to tip of greater trochanter resulting in avoiding iatrogenic vascular injury and being the IM locking device with smaller diameter and shorter length than conventional femoral

nail which was appropriate for small-sized adolescent femoral anatomy^[9,10]. Therefore, this humeral nail should be also suitable for femoral fixation in adolescent OI patients. This study aimed to demonstrate the outcome of adolescent OI patients with femoral fracture or deformity and treated with humeral nail fixation.

CASE REPORT

Case 1

A 12-year-old girl with type I OI presented with progressive left femur deformity (August, 2013). Her height and weight were 138 cm and 51 kg. Initially, she had been diagnosed as type I b (Silence classification)/Tarda B (Shapiro classification) and received treatment since age of 7 years. Three years ago (2010), she had been treated with corrective osteotomy and Ender nail fixation for left femur bowing deformity and the fracture was united uneventfully. However, she had experienced the progressive deformity on her left thigh without pain on weight bearing. The radiographs showed anterolateral femoral bowing due to femoral varus and flexion deformity with 8.5-mm medullary canal diameter (Figure 1A).

Preoperative planning for progressive left femoral deformity was discussed. The goal of treatment was rigid fixation with load-sharing intramedullary (IM) device^[1]. The IM instrument options were K-wire, Rush pin, and telescoping IM device. K-wire and Rush was suitable only for small children with small IM canal due to the size of implant. Telescoping IM device was suitable for older children with larger IM canal, although this device was not available in our country. Therefore, we decided to use humeral IM nail for femoral osteotomy stabilization in this case due to two reasons. Firstly, the humeral nail was the interlocking nail that was available in smaller size and shorter length than conventional femoral nail. Thus, the humeral nail would be better in biomechanical property than single Rush pin. Secondly, the humeral nail geometry was rather straight than femoral nail resulting in the more lateral entry point for humeral nail insertion at the lateral to the tip of greater trochanter, and so avoiding the iatrogenic vascular injury on piriformis fossa.

Surgical technique: The patient was placed in lateral decubitus position under general anesthesia (GA). Multi-level corrective osteotomy was performed with drill and osteotome. Then the femur was reduced to acceptable alignment. The entry point was made at the tip of greater trochanter (GT), and the medullary canal was gently prepared by hand reaming using 6-mm and 7-mm T-reamer. Then a 7-mm diameter Expert humeral nail (Synthes®, Inc.) with 290-mm length was inserted following by proximal blade and distal locking screw insertion under fluoroscopic guidance. One additional wiring was performed due to iatrogenic cortical crack on the osteotomized fragment (Figure 1B). The operative time was 4 h, and the total length of hospital stay was 6

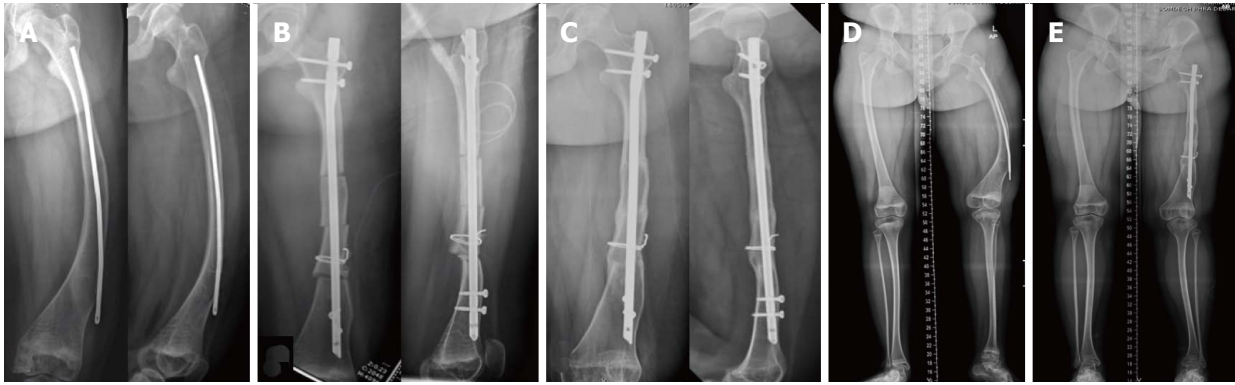


Figure 1 Clinical presentation of case 1. A 12-year-old girl with type I osteogenesis imperfecta presented with progressive bowing of left shaft femur after ender nail fixation for 3 years. Plain radiographs of left femur in anteroposterior and lateral views on preoperative period (A), immediately after multi-level osteotomy and internal fixation with humeral nail (B), 9-mo after humeral nail fixation (C), preoperative scanogram (D) compared with 1-year postoperative scanogram (E).

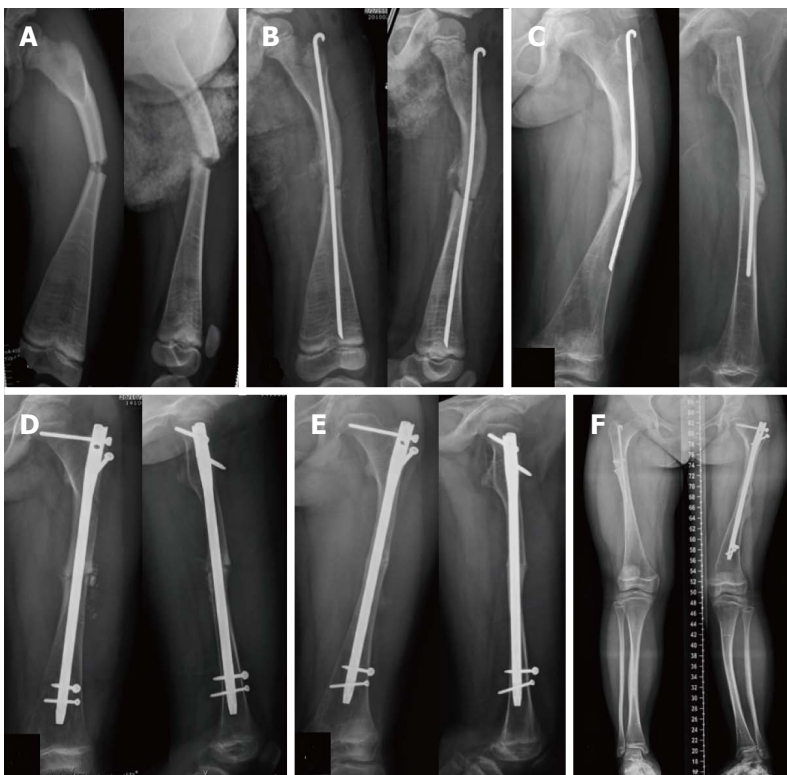


Figure 2 Clinical presentation of case 2. A 12-year-old girl with type III osteogenesis imperfecta presented with limping and pain on full weight bearing after Rush pin fixation for 4 years. Plain radiographs in anteroposterior and lateral views after injury (A), immediately after Rush pin fixation (B), 4 years after Rush pin fixation (C), immediately after humeral nail fixation (D), 9 mo after humeral nail fixation (E), and 1-year postoperative scanogram after humeral nail fixation (F).

d. Estimated blood loss was 350 mL.

1D and E).

Postoperative care and rehabilitation: The postoperative protocol was initially 6-wk toe touch weight bearing with gait aids following by progressive weight bearing as tolerated. The patient reported clinical union (pain-free full weight bearing without tenderness on osteotomy site) at 6 mo postoperatively, and the radiographic union was completed at 9 mo postoperatively (Figure 1C). On 3-year postoperative follow-up period, the patient had normal hip range of motion and function. The radiographs showed no evidence of avascular necrosis of femoral head (Figure

Case 2

A 12-year-old girl with type III OI presented with left femoral shaft oligotrophic nonunion with failed Rush pin fixation (2014). Her height and weight were 122 cm and 25 kg. She had been diagnosed as type III (Silence classification)/Tarda A (Shapiro classification) after birth and treated with intravenous bisphosphate therapy since the age of 3 mo. On 2010, at the age of 7 years, she sustained left femoral shaft fracture and had been treated with single Rush pin fixation (Figure 2A and B). After surgery, she was lost to follow-up for 3 years

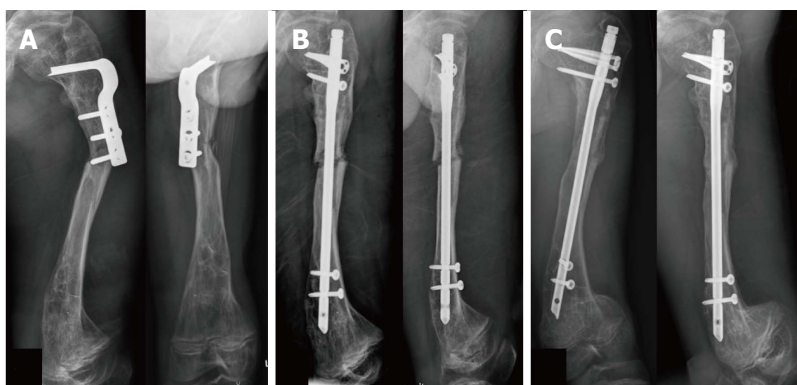


Figure 3 Clinical presentation of case 3 during the first operation. A 16-year-old male with type III osteogenesis imperfecta presented with subtrochanteric peri-implant fracture of left femur after corrective osteotomy and fixation with osteotomy plate for 10 mo. Plain radiographs in anteroposterior and lateral views after injury (A), immediately after humeral nail fixation (B), and 8 mo after humeral nail fixation (C).

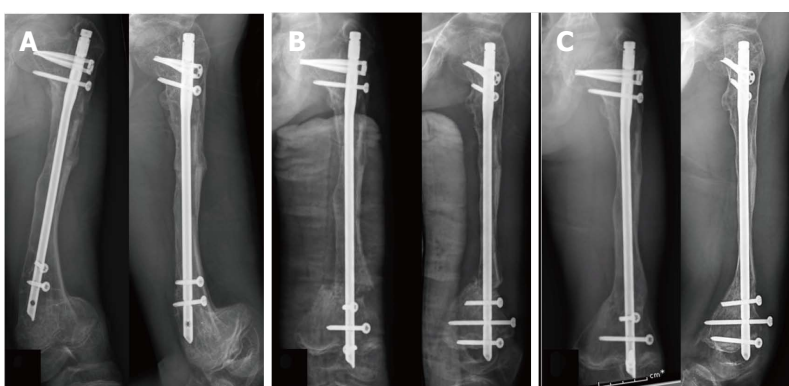


Figure 4 Clinical presentation of case 3 during the second operation. A 16-year-old male with type III osteogenesis imperfecta presented with progressive deformity of left distal femur after first humeral nail fixation for 10 mo. Plain radiographs in anteroposterior and lateral views on preoperative period (A), immediately after corrective osteotomy with humeral nail fixation (B), and 9 mo after humeral nail fixation (C).

(2011-2014) and then came back to our clinic 4-year postoperatively with limping and mild pain on full weight bearing. The radiographs showed that the fracture was still non-united with progressive bending of Rush pin (Figure 2C), and the medullary canal diameter was 9.2 mm. Therefore, the revision operation was planned as Rush pin removal with nonunion resection and humeral nail insertion with local bone graft.

Surgical technique: The patient was placed on lateral decubitus position under general anesthesia. The Rush pin was removed from old surgical scar. The nonunion site was opened directly with subvastus approach. Nonunion fibrous tissue was resected and previous bony callus was harvested for local bone graft. The humeral nail insertion was performed, with the same technique as above, using previous Rush pin entry point at the tip of GT. A 8-mm diameter M/DN Humeral Intramedullary nail (Zimmer, Warsaw, IN) with 255-mm length was applied and locked proximally and distally. Then local bone graft was inserted around the fracture site (Figure 2D). The operative time was 3.5 h, and the total length of hospital stay was 5 d. Estimated blood loss was 300 mL.

Postoperative care and rehabilitation: The patient was allowed 6-wk toe touch weight bearing followed by progressive weight bearing as tolerated. The clinical union was achieved within 6 mo and the radiographic union was completed within 9 mo postoperatively (Figure 2E). On 2-year postoperative follow-up period, the patient had normal function without pain on FWB. The radiographs showed no evidence of avascular necrosis of femoral head (Figure 2F).

Case 3

A 16-year-old male with type III OI presented with left subtrochanteric peri-implant fracture after falling on the ground (September, 2014). His height and weight were 130 cm and 27 kg. He was diagnosed as type III (Silence classification)/Congenita A (Shapiro classification) during antenatal care period, and treated with intravenous bisphosphonate therapy since the age of 19 mo. He had previous bilateral leg deformity and had been treated with bilateral femoral and tibial corrective osteotomy. The radiographs showed displaced left subtrochanteric fracture below osteotomy plate with varus angulation, and bilateral distal femur extension deformity (Figures 3A, 4A, and 5A). The left and right medullary canal

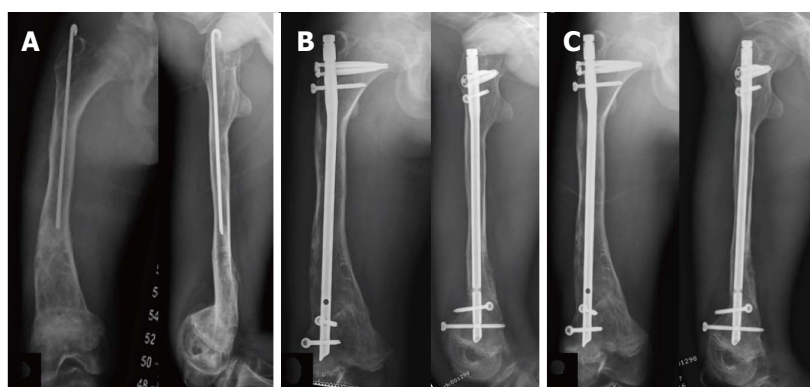


Figure 5 Clinical presentation of case 3 during the third operation. A 17-year-old male with type III osteogenesis imperfecta presented with progressive deformity after Rush pin fixation right shaft femur at early childhood. Plain radiographs in anteroposterior and lateral views on preoperative period (A), immediately after corrective osteotomy with humeral nail fixation (B), and 6 mo after humeral nail fixation (C).

diameters were 8.6 and 9.0 mm respectively.

Surgical technique: After preoperative planning was discussed, bilateral staged femoral reconstructions were planned as: (1) osteotomy plate removal and humeral nail insertion (August, 2014) (Figure 3B); (2) corrective hinged osteotomy left distal femur with humeral nail (June 2015) (Figure 4B); and (3) corrective osteotomy right distal femur with humeral nail (March, 2016) (Figure 5B). All operations were performed using the same technique as mentioned above with Expert humeral nail (Synthes®, Inc.). The operative times were 2.5, 3.5, and 3 h respectively. The lengths of hospital stay were 4, 4, and 3 d. Estimated blood loss were 200, 500, and 350 mL, respectively.

Postoperative care and rehabilitation: After the first and second operation on left femur, due to bilateral deformity, the patient was allowed for 8-wk wheel chair mobilization, and followed by weight bearing as tolerated with full weight bearing after 3 mo postoperatively. The subtrochanteric fracture and osteotomy site both showed clinical union and radiographic union at 3-mo and 8-mo postoperatively (Figures 3C and 4C). After the third operation on his right femur, the postoperative protocol was the same as case no.1 and no.2 due to complete fracture healing with good alignment on left femur. The clinical and radiographic union were shown at 3-mo and 5-mo postoperatively, respectively (Figure 5C). At the most recent follow-up (postoperative 10 mo after the third operation), the patient showed normal hip range of motion with pain-free weight bearing. No avascular necrosis of femoral head was found.

DISCUSSION

OI is a heritable disorder of collagen synthesis that commonly presents as bone fragility with multiple long bone fractures and deformities. These bony problems usually require surgical management for fracture fixation or reconstruction by the load-sharing IM device. However, the surgical fixation in OI patients, especially

in the older children with femoral fracture or deformity, is very difficult due to the abnormal femoral anatomy resulting in implant selection problems such as a mismatch with conventional femoral IM nail, the poor fixation stability of standard pediatric IM device (Rush pin), and the high cost of advanced telescopic rod. This study aimed to present the usefulness of humeral nail fixation as a surgical tool for femoral reconstruction in adolescent OI patients.

The humeral nail application for femoral fixation in adolescent OI patients has many advantages. Firstly, humeral nail implant, which is available in smaller diameter and shorter length than conventional femoral IM nail, is more suitable with these patients' femoral anatomy with narrow medullary canal and short limb. Secondly, humeral nail geometry has narrow width and is easier to insert into the lateral transtrochanter area^[9] which can avoid the risk of iatrogenic injury to greater trochanter physis^[11] or medial femoral circumflex artery^[12]. Thirdly, due to the interlocking nail property, the humeral nail would offer superior biomechanical benefits than the standard Rush pin fixation as better in rotational stability and leg length control, especially for the patients with multilevel corrective osteotomy.

However, there were also some limitations for using humeral nail for femoral reconstruction in adolescent OI patients. First, most of the humeral nail designs had only 90-100 degree of the cephalomedullary angle for proximal locking blade/screw, which was more varus than the neck-shaft angle of the femur and resulting in suboptimal fixation for proximal femur. Therefore, we recommended carefully adjustment of the proximal blade/screw position to achieve the best position and longest length as possible for the stable femoral head and neck fixation (Figures 2-5). Second, the required length for distal locking screw was usually longer than normal due to the wider width of distal femur than distal humerus, thus it was necessary to prepare the extra-length distal locking screw or using the other types of screw, such as 3.5 mm or 4.5 mm cortical screw, instead. Lastly, due to the abnormal femoral anatomy and using humeral nail design, we recommended

performing the rotational alignment examination by intraoperative checking hip rotation in every cases.

The results of this study showed that using humeral nail implant in femoral fixation was possible and could be used in proximal, middle or distal location. Moreover, this option could be indicated for fixation of fracture and nonunion, or corrective osteotomy. Our study also demonstrated the favorable outcome with 100% fracture healing [the mean clinical union time of 4.2 mo (range 3-6 mo) and the mean radiographic union time of 7.8 mo (range 5-9 mo)] and without the implant-related complications such as infection, nonunion, or AVN. Therefore, we concluded that the humeral nail application for femoral fixation in adolescent OI patients would be one of the possible options with satisfactory outcomes.

COMMENTS

Case characteristics

Three adolescent patients with underlying osteogenesis imperfecta presented with progressive femoral deformity (case 1) or nonunion (case 2) or peri-implant fracture and bilateral distal femur deformity (case 3).

Clinical diagnosis

Case 1: Varus and flexion deformity on left femur without local tenderness. Case 2: Antalgic gait with pain on weight bearing, and local tenderness on the fracture site. Case 3: Moderate swelling, local tenderness on left thigh, and limited movement by pain with bilateral distal thigh deformity.

Differential diagnosis

Progressive deformity associated with osteogenesis imperfecta (OI), fracture or osteotomy nonunion, infection, implant irritation.

Laboratory diagnosis

All labs were within normal limits.

Imaging diagnosis

Case 1: Radiographs showed anterolateral femoral bowing deformity. Case 2: Radiographs showed persistent radiolucent line on fracture site and progressive Rush pin bending. Case 3: Radiographs showed displaced subtrochanteric fracture below osteotomy plate with bilateral distal femur deformity.

Treatment

Case 1: Ender nails removal and multi-level corrective osteotomy with humeral nail. Case 2: Rush pin removal, and open reduction and internal fixation with humeral nail and local bone graft. Case 3: Bilateral staged femoral reconstructions; (1) osteotomy plate removal and humeral nail insertion; (2) corrective hinged osteotomy left distal femur with humeral nail; and (3) corrective osteotomy right distal femur with humeral nail.

Related reports

The recommended surgical treatment of long bone fracture in OI patients is load-sharing intramedullary fixation to avoid plate-related complications (implant failure, peri-implant fracture, etc.). However, the femoral reconstruction in these adolescent OI patients was difficult due to the abnormal femoral anatomy (short limb, abnormal alignment from previous fracture or bowing, and narrow medullary canal), and the unavailability of the specific IM implant.

Term explanation

OI is a rare genetic disorder of the synthesis of collagen that mainly affects the bone, and commonly presents as recurrent fracture and deformity.

Experiences and lessons

The humeral nail application for femoral fixation in adolescent OI patients should be performed with careful preoperative planning, gentle fracture manipulation, and strict postoperative rehabilitation protocol.

Peer-review

The authors demonstrated excellent results for treatment of femur deformity in OI adolescents with humeral nail. The paper is well written and instructive.

REFERENCES

- 1 **Roberts TT**, Cepela DJ, Uhl RL, Lozman J. Orthopaedic Considerations for the Adult With Osteogenesis Imperfecta. *J Am Acad Orthop Surg* 2016; **24**: 298-308 [PMID: 27100300 DOI: 10.5435/JAAOS-D-15-00275]
- 2 **Seikaly MG**, Kopanati S, Salhab N, Waber P, Patterson D, Browne R, Herring JA. Impact of alendronate on quality of life in children with osteogenesis imperfecta. *J Pediatr Orthop* 2005; **25**: 786-791 [PMID: 16294137 DOI: 10.1097/01.bpo.0000176162.78980.ed]
- 3 **Shapiro JR**, Thompson CB, Wu Y, Nunes M, Gillen C. Bone mineral density and fracture rate in response to intravenous and oral bisphosphonates in adult osteogenesis imperfecta. *Calcif Tissue Int* 2010; **87**: 120-129 [PMID: 20544187 DOI: 10.1007/s00223-010-9383-y]
- 4 **Burnei G**, Vlad C, Georgescu I, Gavrilu TS, Dan D. Osteogenesis imperfecta: diagnosis and treatment. *J Am Acad Orthop Surg* 2008; **16**: 356-366 [PMID: 18524987 DOI: 10.5435/00124635-200806000-00008]
- 5 **Enright WJ**, Noonan KJ. Bone plating in patients with type III osteogenesis imperfecta: results and complications. *Iowa Orthop J* 2006; **26**: 37-40 [PMID: 16789446]
- 6 **Esposito P**, Plotkin H. Surgical treatment of osteogenesis imperfecta: current concepts. *Curr Opin Pediatr* 2008; **20**: 52-57 [PMID: 18197039 DOI: 10.1097/MOP.0b013e3282f3f03]
- 7 **Gil JA**, DeFroda SF, Sindhu K, Cruz AI Jr, Daniels AH. Challenges of Fracture Management for Adults With Osteogenesis Imperfecta. *Orthopedics* 2017; **40**: e17-e22 [PMID: 27735980 DOI: 10.3928/0147-7447-20161006-04]
- 8 **Joseph B**, Rebello G, B CK. The choice of intramedullary devices for the femur and the tibia in osteogenesis imperfecta. *J Pediatr Orthop B* 2005; **14**: 311-319 [PMID: 16093940 DOI: 10.1097/01202412-200509000-00001]
- 9 **Gordon JE**, Khanna N, Luhmann SJ, Dobbs MB, Ortman MR, Schoenecker PL. Intramedullary nailing of femoral fractures in children through the lateral aspect of the greater trochanter using a modified rigid humeral intramedullary nail: preliminary results of a new technique in 15 children. *J Orthop Trauma* 2004; **18**: 416-422; discussion 423-424 [PMID: 15289686 DOI: 10.1097/00005131-200408000-00004]
- 10 **Park H**, Kim HW. Treatment of femoral shaft fracture with an interlocking humeral nail in older children and adolescents. *Yonsei Med J* 2012; **53**: 408-415 [PMID: 22318831 DOI: 10.3349/ymj.2012.53.2.408]
- 11 **Raney EM**, Ogden JA, Grogan DP. Premature greater trochanteric epiphysiodesis secondary to intramedullary femoral rodding. *J Pediatr Orthop* 1993; **13**: 516-520 [PMID: 8179649 DOI: 10.1097/01241398-199307000-00018]
- 12 **O'Malley DE**, Mazur JM, Cummings RJ. Femoral head avascular necrosis associated with intramedullary nailing in an adolescent. *J Pediatr Orthop* 1995; **15**: 21-23 [PMID: 7883920 DOI: 10.1097/01241398-199501000-00005]

P- Reviewer: Ohishi T S- Editor: Kong JX L- Editor: A
E- Editor: Lu YJ





Published by **Baishideng Publishing Group Inc**
7901 Stoneridge Drive, Suite 501, Pleasanton, CA 94588, USA
Telephone: +1-925-223-8242
Fax: +1-925-223-8243
E-mail: bpgoffice@wjgnet.com
Help Desk: <http://www.f6publishing.com/helpdesk>
<http://www.wjgnet.com>

