

World Journal of *Anesthesiology*

World J Anesthesiol 2020 September 27; 9(1): 1-11



EDITORIAL

- 1 Low dose corticosteroids in COVID-19 with refractory shock: We are not sure?
Omar AS

CASE REPORT

- 3 Unusual bronchoscopic value in percutaneous dilatational tracheostomy: A case report
Omar AS, Sudarsanan S, AlKhulaiji A
- 7 Cement-related embolism after lumbar vertebroplasty: A case report
Xu ZZ, Li HJ, Li X, Zhang H

ABOUT COVER

Editorial board member of *World Journal of Anesthesiology*, Dr. Amr Salah Omar, MBBch, Msc, PhD, MD, MBA, is Professor at Beni Suef University (Egypt). After completing his PhD in Critical Care Medicine from Cairo University in 2003, he undertook further graduate study at University of Liverpool (United Kingdom), being awarded an MBA in 2014. In 2016, he was granted the position of Assistant Professor at Weill Cornell Medicine-Qatar, which led to his current position as Senior Consultant Intensivist in the Cardiothoracic Surgery Department of Hamad Medical Corporation (HMC; Qatar). His career research efforts in hemodynamic monitoring, mechanical circulatory support and glycemic control have yielded over 40 peer-reviewed publications and been presented at more than 30 international conferences. Dr. Omar has received three innovation grants from HMC and the Qatar Science and Technology Park (member of the Qatar Foundation) over the last 4 years. (L-Editor: Filipodia)

AIMS AND SCOPE

The primary aim of *World Journal of Anesthesiology* (WJA, *World J Anesthesiol*) is to provide scholars and readers from various fields of anesthesiology with a platform to publish high-quality basic and clinical research articles and communicate their research findings online.

WJA mainly publishes articles reporting research results and findings obtained in the field of anesthesiology and covering a wide range of topics including critical medicine, orthopedic anesthesia, tumors and anesthesia, airway management, pediatric anesthesia, geriatric anesthesia, anesthesia for organ transplantation, regional anesthesia, anesthesia for neurosurgery, cardiothoracic anesthesia, obstetric anesthesia, pain diagnosis and treatment, and pharmacology in anesthesia.

INDEXING/ABSTRACTING

The WJA is now indexed in China National Knowledge Infrastructure (CNKI), China Science and Technology Journal Database (CSTJ), and Superstar Journals Database.

RESPONSIBLE EDITORS FOR THIS ISSUE

Production Editor: *Yu-Jie Ma*; Production Department Director: *Xiang Li*; Editorial Office Director: *Ya-Juan Ma*.

NAME OF JOURNAL

World Journal of Anesthesiology

ISSN

ISSN 2218-6182 (online)

LAUNCH DATE

December 27, 2011

FREQUENCY

Irregular

EDITORS-IN-CHIEF

Luis Tollinche

EDITORIAL BOARD MEMBERS

<https://www.wjgnet.com/2218-6182/editorialboard.htm>

PUBLICATION DATE

September 27, 2020

COPYRIGHT

© 2019 Baishideng Publishing Group Inc

INSTRUCTIONS TO AUTHORS

<https://www.wjgnet.com/bpg/gerinfo/204>

GUIDELINES FOR ETHICS DOCUMENTS

<https://www.wjgnet.com/bpg/GerInfo/287>

GUIDELINES FOR NON-NATIVE SPEAKERS OF ENGLISH

<https://www.wjgnet.com/bpg/gerinfo/240>

PUBLICATION ETHICS

<https://www.wjgnet.com/bpg/GerInfo/288>

PUBLICATION MISCONDUCT

<https://www.wjgnet.com/bpg/gerinfo/208>

ARTICLE PROCESSING CHARGE

<https://www.wjgnet.com/bpg/gerinfo/242>

STEPS FOR SUBMITTING MANUSCRIPTS

<https://www.wjgnet.com/bpg/GerInfo/239>

ONLINE SUBMISSION

<https://www.f6publishing.com>

Cement-related embolism after lumbar vertebroplasty: A case report

Zhen-Zhen Xu, Huai-Jin Li, Xue Li, Hong Zhang

ORCID number: Zhen-Zhen Xu 0000-0003-2387-1223; Huai-Jin Li 0000-0002-2862-9201; Xue Li 0000-0003-3437-0870; Hong Zhang 0000-0003-1690-033x.

Author contributions: Xu ZZ was responsible for obtaining the patient's informed consent, collecting patient data, and preparing the manuscript; Li HJ participated in the anesthesia management and revised the manuscript; Li X performed the follow-up for the patient and recorded the in-hospital and out-hospital treatment; Zhang H supervised the anesthesia management and was responsible for revision of the manuscript; all authors have read and approved the final manuscript.

Informed consent statement: Written informed consent was obtained from the patient's spouse for publication of this case report.

Conflict-of-interest statement: The authors declare that they have no conflict of interest to disclose.

CARE Checklist (2016) statement: The authors have read the CARE Checklist (2016), and the manuscript was prepared and revised according to the CARE Checklist (2016).

Open-Access: This article is an open-access article that was selected by an in-house editor and

Zhen-Zhen Xu, Huai-Jin Li, Xue Li, Hong Zhang, Department of Anesthesiology and Critical Medicine, Peking University First Hospital, Beijing 100034, China

Corresponding author: Hong Zhang, MD, Associate Professor, Doctor, Department of Anesthesiology and Critical Care Medicine, Peking University First Hospital, No. 8 Xishiku Street, Beijing 100034, China. zhanghong40@hotmail.com

Abstract

BACKGROUND

Cement-related embolism is a rare but potentially fatal complication in spinal surgery. Cardiac echocardiography can provide valuable information for the early identification.

CASE SUMMARY

A 66-year-old woman who underwent lumbar vertebroplasty and internal fixation under general anesthesia experienced an episode of supraventricular tachycardia and ventricular tachycardia at the end of surgery. Point-of-care echocardiogram revealed a foreign body in the right heart. After conservative treatment in the intensive care unit, her family decided on comfort care and she expired.

CONCLUSION

Transthoracic echocardiography may provide early valuable information in patients undergoing vertebroplasty, and mild-moderate pericardial effusion may be a significant sign of a poor outcome.

Key Words: Cement embolism; Vertebroplasty; Transthoracic echocardiography; Pericardial effusion; Perioperative management; Cardiovascular event; Case report

©The Author(s) 2020. Published by Baishideng Publishing Group Inc. All rights reserved.

Core Tip: With an aging population and increasing tumor occurrence, there is an ever-growing demand for vertebroplasty surgery. Cement related embolism subsequently increases. We recommend echocardiography in the early identification of cement embolism and foreign body with pericardial perfusion should be paid more attention.

Citation: Xu ZZ, Li HJ, Li X, Zhang H. Cement-related embolism after lumbar vertebroplasty: A case report. *World J Anesthesiol* 2020; 9(1): 7-11

URL: <https://www.wjgnet.com/2218-6182/full/v9/i1/7.htm>

fully peer-reviewed by external reviewers. It is distributed in accordance with the Creative Commons Attribution NonCommercial (CC BY-NC 4.0) license, which permits others to distribute, remix, adapt, build upon this work non-commercially, and license their derivative works on different terms, provided the original work is properly cited and the use is non-commercial. See: <http://creativecommons.org/licenses/by-nc/4.0/>

Manuscript source: Unsolicited manuscript

Received: April 29, 2020

Peer-review started: April 29, 2020

First decision: July 5, 2020

Revised: July 12, 2020

Accepted: August 16, 2020

Article in press: August 16, 2020

Published online: September 27, 2020

P-Reviewer: Quadros LGD, Surani S

S-Editor: Zhang L

L-Editor: Wang TQ

P-Editor: Ma YJ



DOI: <https://dx.doi.org/10.5313/wja.v9.i1.7>

INTRODUCTION

Cement augmented pedicle screw instrumentation of the thoracolumbar spine is indicated in spinal metastasis to release pain and stabilize the vertebral body. The incidence of cement leakage in multi-level vertebroplasty is more than 65%, and the incidence in single-level vertebroplasty is even higher^[1,2]. Cement-related embolism is a rare but potentially fatal complication, with an incidence of 4.6%-7.9%^[2,3]. Those with advanced age, metastatic bone disease, osteoporosis, underlying cardiovascular disease, and patent foramen ovale were reported to be at higher risk^[4]. Early screening and detection are crucial for these patients, and point-of-care echocardiography can provide valuable information in the clinical setting. Cardiac effusion revealed in echocardiogram examination may be a significant indicator of a poor outcome. Here, we report a case of cement-related pulmonary embolism following vertebroplasty for spinal metastasis.

CASE PRESENTATION

Chief complaints

A 66-year-old woman, complaining of back pain and lower limb weakness for about 2 mo, was referred from the orthopedics clinic to the inpatient department.

History of present illness

The patient underwent radical mastectomy 8 years ago for breast cancer, followed by chemotherapy and endocrine therapy. Six months ago, she was admitted to the emergency room, presenting with proximal femoral fracture. After surgical femoral head replacement, biopsy of the femur suggested metastatic breast adenocarcinoma. The patient had type 2 diabetes mellitus that was controlled by insulin injections for 10 years.

Laboratory and imaging examinations

Lumbar magnetic resonance imaging showed that there were occupying lesions at the level of T12 to S3 vertebrae and vertebral pedicle, suggestive of metastases. The patient was diagnosed with breast cancer and multiple bone metastases according to clinical evidence. Laboratory examination results were within normal limits, including hematological, coagulation, kidney, and liver functions as well as electrolytes. Electrocardiogram revealed tachycardia with a heart rate of 110 bpm. Preoperative transthoracic echocardiography (TTE) showed normal contraction function with an ejection fraction of 71% and normal diastolic function with a septal e' value of 12 cm/s. Chest X-ray did not show any abnormalities. Physical examination revealed normal cardiorespiratory findings, but low back tenderness and lower extremity weakness.

Intraoperative management

Invasive blood pressure, SpO_2 , lead II electrocardiogram, end-tidal concentrations of inhalational anesthetics and carbon dioxide, nasopharyngeal temperature, bispectral index, and urine output were monitored during surgery. Intravenous access was obtained using an 18G cannula before induction and a central venous catheter was inserted after the induction of general anesthesia. General anesthesia was induced with sufentanil (targeted controlled infusion at an effect-site concentration of 0.5 ng/mL), 60 mg propofol, 7 mg etomidate, and 50 mg rocuronium. After successful intubation, anesthesia was maintained with inhalation nitrous oxide, propofol (25-30 mL/h) infusion, and sufentanil (targeted controlled infusion at an effect-site concentration of 0.1-0.3 ng/mL) to achieve appropriate depth of anesthesia and pain control. Cis-atracurium was intermittently administered to ensure muscle relaxation. The patient was placed in the prone position and her eyes and nose were protected to avoid bruising. Hemodynamics management was guided by the stroke volume variation and cardiac index. When the surgery was finished, an episode of supraventricular tachycardia and ventricular tachycardia occurred without unstable hemodynamics. A 4-mL bolus of 2% lidocaine was administered intravenously to alleviate the arrhythmia. Arterial blood gas results were within normal limits (K^+ 4.8

mmol/L and lactate 1.0 mmol/L). The patient then recovered and was extubated with sinus tachycardia of 110 bpm, intra-arterial blood pressure of 140/90 mmHg, and SpO₂ of 95%.

FINAL DIAGNOSIS

After transferred to the post-anesthesia care unit, TTE was performed by a skillful anesthesiologist. A hyper-echogenic material signal was observed in the right heart, across the tricuspid valve area extending to the right ventricular apex. This sign might indicate a foreign body. Both foreign body and pericardial effusion could be detected on the apical four chamber view, parasternal long axis view, and subxiphoid four chamber view under TTE (Figure 1). With the exception of sinus tachycardia which already existed preoperatively, her general vital signs were within the normal range. We made a preliminary diagnosis of cement-related embolism. Subsequently, coronary angiography confirmed the presence of cement within the right heart and right pulmonary (Figure 2). She was finally diagnosed with cement-related embolism, and received non-invasive ventilation support afterwards.

TREATMENT

Due to advanced stage of the tumor and lung embolism and high risk of treatment, her family refused surgical embolectomy and percutaneous emboli removal and decided on comfort care.

OUTCOME AND FOLLOW-UP

The patient experienced dyspnea and progressive heart failure due to cement-related embolism. She eventually expired.

DISCUSSION

The incidence of vertebroplasty related symptomatic pulmonary cement embolism is reported to be approximately 3% to 23%, according to different imaging methods^[5]. Common complications in vertebroplasty include rib fracture, cement leakage, and anaphylactic reaction, with or without hemodynamic turbulence^[6]. Although this procedure was strictly monitored using good-quality fluoroscopy for vascular leakage, in our case, cement embolism caused by perivertebral venous migration was not identified early in the operating room. What's more, real-time detection of lateral-vertebral leakage was difficult due to overlap of the cement filling the vertebral body.

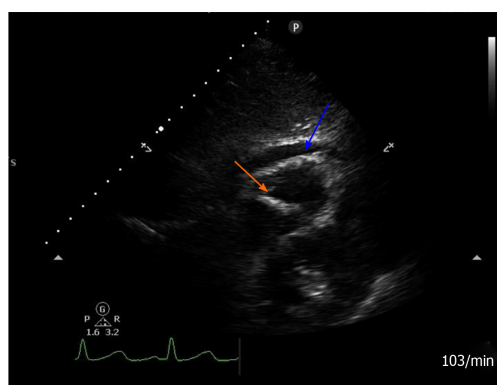
Lack of robust detection of the embolism was due to atypical vital signs in the early stage. The best management of cardiac and pulmonary cement-related embolism in this situation is worthy of debate^[7]. Surgical approaches, such as cardiovascular intervention or open cardiac surgery, the best timing for removal of the cement emboli, and patient preference need to be discussed on a multidiscipline basis.

The diagnosis of cardiac cement in our case was determined in the post-anesthesia care unit, and the patient was quickly transferred to the intensive care unit for further treatment. A review of the literatures revealed that conservative treatment may be recommended rather than surgical removal except for extensive obstruction^[8]. Moreover, quite a few patients were diagnosed ranging from 10 d to 6 years after surgery due to clinical symptoms^[9-12]. As shown in our case, mild-moderate pericardial effusion shortly after surgery may be a significant indicator of a poor outcome. Table 1 summarizes several reported cases with early detection of cement embolism by echocardiography during or shortly after surgery. Most cases requiring surgical treatment were associated with pericardial effusion.

Transthoracic echocardiogram is an inexpensive and non-invasive examination, and could probably provide valuable information in such patients. This case emphasizes the importance of early detection of cardiac and pulmonary embolism using polymethylmethacrylate during vertebroplasty, especially the identification of pericardial effusion. However, prospective clinical trials on this issue are still limited.

Table 1 Summary of case reports on the early detection of cement-related embolism patients during/after lumbar surgery by echocardiography

Ref.	Age/gender	Echocardiography finding/whether pericardial effusion present	Clinical features and occurrence time	Treatment	Outcome
Cohen ^[13] , 2012	65 yr/ female	Foreign body in the right ventricle/with little pericardial effusion	Ventricular tachycardia intraoperatively	Progression to right ventricle failure and surgical removal	Uneventful recovery
Tran <i>et al</i> ^[14] , 2013	68 yr/ female	Tamponade	Cardiac shock during coronary angiography after lumbar surgery	Percutaneous catheterization removal	Recovery
Elapavaluru <i>et al</i> ^[15] , 2015	61 yr/ female	Hyper-echo foreign body in the apex of the left ventricle/ pericardial effusion not clearly mentioned	Acute hypoxic respiratory failure within 24 h postoperatively	Mitral valve replacement under cardiopulmonary bypass	Discharged home
Puri ^[16] , 2016	75 yr/ female	Foreign body in right heart/ large pericardial effusion	Chest pain, tachycardia, and hypotension the following day	Surgical removal	Discharge with a normal sinus rhythm
Andrä <i>et al</i> ^[7] , 2017	62 yr/ female	Hyper-echo foreign body in the right atrium/ 8-mm wide pericardial effusion	Severe tachycardia and hypotonia intraoperatively	Surgical removal	Stable cardiorespiratory condition
Adu-Gyamfi <i>et al</i> ^[17] , 2019	86 yr/ female	Cement traversing the tricuspid valve into the right ventricle/ without pericardial effusion	Shortness of breath immediately after surgery	Medicine treatment	Discharged home


Figure 1 Postoperative transthoracic echocardiography view. Subxiphoid four chamber view modified for the right ventricle showing a hyperechogenic linear-shaped image attached to the apical portion of the right ventricle (orange arrow), and pericardial effusion (blue arrow).

CONCLUSION

Anesthesiologists should be aware of spinal metastasis and the anatomy of the vertebral venous system, and master the technique of transthoracic echocardiogram to minimize perioperative cardiovascular risks during vertebroplasty. Attention also should be paid to the early detection of pericardial effusion.

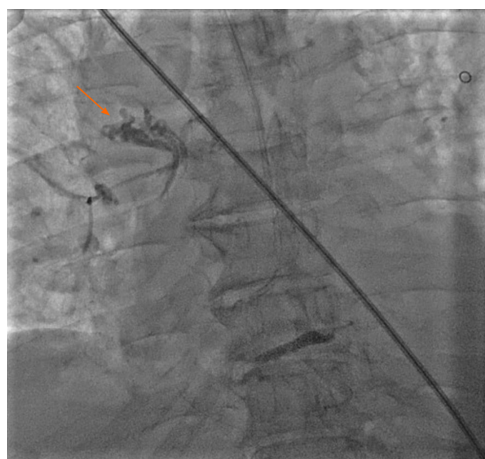


Figure 2 Postoperative coronary angiography examination. Coronary angiography showed an opaque lesion on the right pulmonary artery (orange arrow).

REFERENCES

- 1 **Bao L**, Jia P, Li J, Chen H, Dong Y, Feng F, Yang H, Chen M, Tang H. Percutaneous Vertebroplasty Relieves Pain in Cervical Spine Metastases. *Pain Res Manag* 2017; **2017**: 3926318 [PMID: [28239257](#) DOI: [10.1155/2017/3926318](#)]
- 2 **Janssen I**, Ryang YM, Gempt J, Bette S, Gerhard J, Kirschke JS, Meyer B. Risk of cement leakage and pulmonary embolism by bone cement-augmented pedicle screw fixation of the thoracolumbar spine. *Spine J* 2017; **17**: 837-844 [PMID: [28108403](#) DOI: [10.1016/j.spinee.2017.01.009](#)]
- 3 **Choe DH**, Marom EM, Ahrar K, Truong MT, Madewell JE. Pulmonary embolism of polymethyl methacrylate during percutaneous vertebroplasty and kyphoplasty. *AJR Am J Roentgenol* 2004; **183**: 1097-1102 [PMID: [15385313](#) DOI: [10.2214/ajr.183.4.1831097](#)]
- 4 **Osoba O**, Kosko B. Noise-enhanced clustering and competitive learning algorithms. *Neural Netw* 2013; **37**: 132-140 [PMID: [23137615](#) DOI: [10.1097/MJT.0b013e31820b3de3](#)]
- 5 **Krueger A**, Bliemel C, Zettl R, Ruchholtz S. Management of pulmonary cement embolism after percutaneous vertebroplasty and kyphoplasty: a systematic review of the literature. *Eur Spine J* 2009; **18**: 1257-1265 [PMID: [19575243](#) DOI: [10.1007/s00586-009-1073-y](#)]
- 6 **Habib N**, Maniatis T, Ahmed S, Kilkeny T, Alkaied H, Elsayegh D, Chalhoub M, Harris K. Cement pulmonary embolism after percutaneous vertebroplasty and kyphoplasty: an overview. *Heart Lung* 2012; **41**: 509-511 [PMID: [22425258](#) DOI: [10.1016/j.hrtlng.2012.02.008](#)]
- 7 **Andrä M**, Baumer H, Mittergradnegger F, Laschitz M, Petek T, Wandschneider W. Life-Threatening Cardiac Perforation After Posterior Spondylodesis. *Ann Thorac Surg* 2017; **104**: e355-e357 [PMID: [29054227](#) DOI: [10.1016/j.athoracsur.2017.06.021](#)]
- 8 **Rahimi B**, Boroofeh B, Dinparastisaleh R, Nazifi H. Cement pulmonary embolism after percutaneous vertebroplasty in a patient with cushing's syndrome: A case report. *Respir Med Case Rep* 2018; **25**: 78-85 [PMID: [30073141](#) DOI: [10.1016/j.rmcr.2018.06.009](#)]
- 9 **Bouchez S**, Mauermann E, Philipsen T, Wouters P. 3D Echocardiographic Diagnosis of Right Ventricular Perforation With Polymethylmethacrylate Particles After Vertebroplasty. *J Cardiothorac Vasc Anesth* 2017; **31**: 2123-2126 [PMID: [28526207](#) DOI: [10.1053/j.jvca.2017.02.053](#)]
- 10 **Schuerer S**, Misfeld M, Schuler G, Mangner N. Intracardiac cement embolization in a 65-year-old man four months after multilevel spine fusion. *Eur Heart J* 2015; **36**: 783 [PMID: [25157112](#) DOI: [10.1093/eurheartj/ehu300](#)]
- 11 **Cadeddu C**, Nocco S, Secci E, Deidda M, Pirisi R, Mercurio G. Echocardiographic accidental finding of asymptomatic cardiac and pulmonary embolism caused by cement leakage after percutaneous vertebroplasty. *Eur J Echocardiogr* 2009; **10**: 590-592 [PMID: [19329500](#) DOI: [10.1093/ejehocardi/jep030](#)]
- 12 **Lee JS**, Jeong YS, Ahn SG. Intracardiac bone cement embolism. *Heart* 2010; **96**: 387 [PMID: [20197363](#) DOI: [10.1136/hrt.2009.182162](#)]
- 13 **Cohen JB**. Bone cement embolism. *Anesthesiology* 2012; **117**: 407 [PMID: [22388069](#) DOI: [10.1097/ALN.0b013e31824de99a](#)]
- 14 **Tran I**, Gerckens U, Remig J, Zintl G, Textor J. First report of a life-threatening cardiac complication after percutaneous balloon kyphoplasty. *Spine (Phila Pa 1976)* 2013; **38**: E316-E318 [PMID: [23232213](#) DOI: [10.1097/BRS.0b013e318281507a](#)]
- 15 **Elapavaluru S**, Alhassan S, Khan F, Khalil R, Schuett A, Bailey S. Severe Acute Traumatic Mitral Regurgitation, Cardiogenic Shock Secondary to Embolized Polymethylmethacrylate Cement Foreign Body After a Percutaneous Vertebroplasty. *Ann Thorac Surg* 2016; **101**: 1169-1171 [PMID: [26897199](#) DOI: [10.1016/j.athoracsur.2015.04.115](#)]
- 16 **Puri V**. Invited Commentary. *Ann Thorac Surg* 2016; **101**: 1855 [PMID: [27106423](#) DOI: [10.1016/j.athoracsur.2015.06.117](#)]
- 17 **Adu-Gyamfi KO**, Patri S. Symptomatic cardiopulmonary cement embolism following vertebroplasty. *BMJ Case Rep* 2019; **12** [PMID: [31311789](#) DOI: [10.1136/bcr-2019-230603](#)]



Published by **Baishideng Publishing Group Inc**
7041 Koll Center Parkway, Suite 160, Pleasanton, CA 94566, USA

Telephone: +1-925-3991568

E-mail: bpgoffice@wjgnet.com

Help Desk: <https://www.f6publishing.com/helpdesk>

<https://www.wjgnet.com>

