

# World Journal of *Respirology*

*World J Respirol* 2021 August 8; 11(1): 1-17



## CASE REPORT

- 1 SARS-CoV-2 with concurrent coccidioidomycosis complicated by refractory pneumothorax in a Hispanic male: A case report and literature review

*Mathew J, Cherukuri SV, Dihowm F*

- 12 Like father, like son: Pulmonary thromboembolism due to inflammatory or hereditary condition? Two case reports

*Hannun P, Hannun W, Yoo HH, Resende L*

**ABOUT COVER**

Editorial Board Member of *World Journal of Respiriology*, Fizza Ghulam Nabi, PhD, Assistant Professor, Institute of Quality and Technology Management, Punjab University, Lahore, Lahore 54000, Punjab, Pakistan.  
 engr.fizza@yahoo.com

**AIMS AND SCOPE**

The primary aim of *World Journal of Respiriology* (WJR, *World J Respirol*) is to provide scholars and readers from various fields of respirology with a platform to publish high-quality basic and clinical research articles and communicate their research findings online. WJR mainly publishes articles reporting research results and findings obtained in the field of respirology and covering a wide range of topics including bronchial diseases, ciliary motility disorders, respiratory tract granuloma, laryngeal diseases, lung diseases, nose diseases, pleural diseases, respiration disorders, respiratory center abnormalities, neuromuscular disorders, respiratory hypersensitivity, respiratory system abnormalities, pulmonary vascular diseases, respiratory tract fistula, respiratory tract infections, respiratory tract neoplasms, thoracic diseases, and tracheal diseases.

**INDEXING/ABSTRACTING**

*World Journal of Respiriology* is now abstracted and indexed in China National Knowledge Infrastructure (CNKI), China Science and Technology Journal Database (CSTJ), and Superstar Journals Database.

**RESPONSIBLE EDITORS FOR THIS ISSUE**

Production Editor: Jia-Hui Li; Production Department Director: Xiang Li; Editorial Office Director: Ya-Juan Ma.

**NAME OF JOURNAL**

*World Journal of Respiriology*

**ISSN**

ISSN 2218-6255 (online)

**LAUNCH DATE**

December 30, 2011

**FREQUENCY**

Continuous Publication

**EDITORS-IN-CHIEF**

Kazuhiro Yamaguchi

**EDITORIAL BOARD MEMBERS**

<https://www.wjgnet.com/2218-6255/editorialboard.htm>

**PUBLICATION DATE**

August 8, 2021

**COPYRIGHT**

© 2021 Baishideng Publishing Group Inc

**INSTRUCTIONS TO AUTHORS**

<https://www.wjgnet.com/bpg/gerinfo/204>

**GUIDELINES FOR ETHICS DOCUMENTS**

<https://www.wjgnet.com/bpg/GerInfo/287>

**GUIDELINES FOR NON-NATIVE SPEAKERS OF ENGLISH**

<https://www.wjgnet.com/bpg/gerinfo/240>

**PUBLICATION ETHICS**

<https://www.wjgnet.com/bpg/GerInfo/288>

**PUBLICATION MISCONDUCT**

<https://www.wjgnet.com/bpg/gerinfo/208>

**ARTICLE PROCESSING CHARGE**

<https://www.wjgnet.com/bpg/gerinfo/242>

**STEPS FOR SUBMITTING MANUSCRIPTS**

<https://www.wjgnet.com/bpg/GerInfo/239>

**ONLINE SUBMISSION**

<https://www.f6publishing.com>

## Like father, like son: Pulmonary thromboembolism due to inflammatory or hereditary condition? Two case reports

Pedro Hannun, Walter Hannun, Hugo Hyung Yoo, Lucilene Resende

**ORCID number:** Pedro Hannun 0000-0003-1508-5361; Walter Hannun 0000-0002-7044-4905; Hugo Hyung Yoo 0000-0003-3226-2788; Lucilene Resende 0000-0002-7635-2016.

**Author contributions:** All authors were responsible for the study conception and design; Hannun P wrote the manuscript; all authors contributed to the manuscript revision and final version approval.

**Informed consent statement:** Informed written consent for publication of this report and use of any accompanying images was obtained from both patients.

**Conflict-of-interest statement:** The authors report no conflict of interest.

**CARE Checklist (2016) statement:** The authors have read the CARE Checklist (2016), and the manuscript was prepared and revised according to the CARE Checklist (2016).

**Open-Access:** This article is an open-access article that was selected by an in-house editor and fully peer-reviewed by external reviewers. It is distributed in accordance with the Creative Commons Attribution NonCommercial (CC BY-NC 4.0) license, which permits others to

**Pedro Hannun, Hugo Hyung Yoo, Lucilene Resende,** Department of Internal Medicine, Botucatu Medical School, São Paulo State University - UNESP, São Paulo 18618-687, Brazil

**Walter Hannun,** Department of Institutional Relations, Santa Catarina Hospital, São Paulo 01310-000, Brazil

**Corresponding author:** Pedro Hannun, MHS, Department of Internal Medicine, Botucatu Medical School, São Paulo State University - UNESP, Prof. Mário Rubens Guimarães Montenegro Avenue, s/n, São Paulo 18618-687, Brazil. [pgch2003@gmail.com](mailto:pgch2003@gmail.com)

### Abstract

#### BACKGROUND

Venous thromboembolism, which includes deep venous thrombosis and pulmonary embolism, is a well-known causal disorder with high morbidity and mortality rates. Inherited or acquired conditions affecting components of coagulation and fibrinolysis systems have been linked to venous thromboembolism pathogenesis as they may lead to a pro-inflammatory state in human bodies. Toxoplasmosis is a zoonosis that potentially leads to acute systemic cachectic-inflammatory effects in experimental animal models but is not yet proven in humans. It is known that venous thrombosis can occur during acute inflammatory/infectious diseases, although it is not well established with regard to toxoplasmosis alone.

#### CASE SUMMARY

A 70-year-old Caucasian man and his 32-year-old son developed general malaise, chills, fever, and myalgia, having established a diagnosis of toxoplasmosis. Twenty days later, they presented dry cough leading to further investigations that revealed an incidental deep venous thrombosis plus pulmonary embolism in them both. Thrombophilia screening showed both patients had a factor V Leiden mutation heterozygosis. Father and son completely recovered without any sequelae after anticoagulant treatment. They have not presented symptom recurrence of either medical disorder during 1 year of follow-up.

#### CONCLUSION

Toxoplasmosis may enhance the risk of venous thromboembolism in patients showing factor V Leiden mutation heterozygosis.

**Key Words:** Factor V Leiden mutation; Thrombophilia; Venous thromboembolism; Deep



distribute, remix, adapt, build upon this work non-commercially, and license their derivative works on different terms, provided the original work is properly cited and the use is non-commercial. See: <http://creativecommons.org/licenses/by-nc/4.0/>

**Manuscript source:** Unsolicited manuscript

**Specialty type:** Respiratory system

**Country/Territory of origin:** Brazil

**Peer-review report's scientific quality classification**

Grade A (Excellent): 0  
Grade B (Very good): B  
Grade C (Good): C  
Grade D (Fair): 0  
Grade E (Poor): 0

**Received:** March 7, 2021

**Peer-review started:** March 7, 2021

**First decision:** May 6, 2021

**Revised:** May 17, 2021

**Accepted:** July 14, 2021

**Article in press:** July 14, 2021

**Published online:** August 8, 2021

**P-Reviewer:** Protopapas AA

**S-Editor:** Zhang H

**L-Editor:** Filipodia

**P-Editor:** Li JH



venous thrombosis; Toxoplasmosis; Inflammation; Case report

©The Author(s) 2021. Published by Baishideng Publishing Group Inc. All rights reserved.

**Core Tip:** This paper describes two closely related patients simultaneously infected by *Toxoplasma gondii* who concurrently presented their first venous thromboembolism episode. Further investigation revealed a factor V Leiden mutation in them both. The association between these two morbid conditions suggests that systemic infection/inflammation may enhance the risk of venous thromboembolism in people carrying this kind of pro-thrombophilia mutation. As far as we know, this is the first report of that association. We believe that this paper provides an insight into this important issue bringing potential help for clinical decision-making processes by doctors around the world.

**Citation:** Hannun P, Hannun W, Yoo HH, Resende L. Like father, like son: Pulmonary thromboembolism due to inflammatory or hereditary condition? Two case reports. *World J Respir* 2021; 11(1): 12-17

**URL:** <https://www.wjgnet.com/2218-6255/full/v11/i1/12.htm>

**DOI:** <https://dx.doi.org/10.5320/wjr.v11.i1.12>

## INTRODUCTION

Inflammation and coagulation are intrinsically related processes that communicate at various levels; either can be the cause or consequence of the other[1,2]. The mechanism that links inflammation (originally infectious or not) and thrombosis is complex and not fully understood. The most commonly accepted hypothesis states that aseptic inflammations or infection-related inflammations promote the secretion of several cellular mediators, mostly related to the innate immune response. Inflammation activates endothelial cells, leukocytes, and platelets, resulting in cell dysfunction and/or injury and platelet aggregation[2]. Concomitantly, an infection can result in antiphospholipid antibodies that trigger the overproduction of tissue factor and thromboxane A<sub>2</sub>[3]. All together this could initiate the blood clotting cascade[1,2].

Toxoplasmosis, a common zoonosis caused by the *Toxoplasma gondii* protozoan, is a systemic infection that may cause cachectic-inflammatory effects in experimental animal models[4] and even the development of antiphospholipid syndrome in humans [3,5]. Hence, toxoplasmosis by itself might eventually provoke a venous thromboembolism (VTE) event in a given patient.

In addition to having toxoplasmosis, our studied patients carried factor V Leiden (FVL) mutation heterozygosis, a well-known cause of thrombophilia. The combination of these two morbid conditions might have increased the risk of VTE in both patients.

## CASE PRESENTATION

### Chief complaints

A 70-year-old Caucasian man and his 32-year-old son had developed general malaise, chills, fever, and myalgia. Dry cough appeared approximately 20 d after initial symptoms in both patients.

### History of present illness

At the beginning of 2019, a 70-year-old Caucasian man and his 32-year-old son had lunch together at a steakhouse in São Paulo City, Brazil. After 5 d, the older man developed general malaise, chills, fever, and myalgia; he also noticed enlarged cervical and occipital lymph nodes. One week later, he took a 10 h flight to the United States remaining abroad for 10 d without any clinical improvement. During this time, his son who had stayed in Brazil, started having similar symptoms. About 20 d later they both developed a persistent dry cough. One month after initial symptoms, they were hospitalized after being radiologically diagnosed with pulmonary thromboembolism.

### **History of past illness**

The older man had a prostatic carcinoma *in situ* operated 5 years earlier; he was also a former smoker.

The younger had only a right shoulder capsuloplasty 9 years earlier; he was a non-smoker.

### **Personal and family history**

The older man had current controlled hypertension and type II diabetes. There was no history of family disorders.

### **Physical examination**

The relevant findings were enlarged cervical and occipital lymph nodes in both patients and muscular stiffness in the right calf of the younger man.

There were no respiratory signs or low oxygen saturation levels on room air.

### **Laboratory examinations**

The following laboratory tests were normal in both patients: Blood cell count, prothrombin time, activated partial thromboplastin time, four hereditary alterations for thrombophilia (protein C, protein S, and antithrombin serum levels; G20210A prothrombin gene mutation search), and three acquired alterations for thrombophilia (anticardiolipin antibodies, anti-beta-2-glycoprotein I antibodies, and lupus anticoagulant).

Tests with abnormal results in both patients were (Table 1): Presence of high serum C-reactive protein, presence of positive IgM antibodies for *Toxoplasma gondii*, and presence of FVL mutation heterozygous status (gene F5, c.691G>A, p.R506Q).

D-dimers were only analyzed in the older patient with a high result.

### **Imaging examinations**

Imaging studies are shown in Table 1.

In the father, pulmonary computed tomography angiography showed bilateral pulmonary embolism (Figure 1A), and a further Doppler ultrasound (US) found deep venous thrombosis (DVT) in the left lower limb (anterior tibial, posterior tibial, and fibular veins). In the son, pulmonary computed tomography angiography and Doppler US respectively showed a bilateral pulmonary embolism (Figure 1B) and DVT in the right lower limb (anterior tibial, posterior tibial, fibular, and popliteal veins).

---

## **FINAL DIAGNOSIS**

The final diagnosis of both patients was identical, corresponding to pulmonary VTE associated with acute toxoplasmosis plus FVL heterozygous mutation status.

---

## **TREATMENT**

Although clinically stable, both patients were admitted to the hospital to start anticoagulant therapy with enoxaparin (60 mg, subcutaneously, twice a day for 4 d) followed by rivaroxaban (15 mg, orally, twice a day) according to local standards. They were discharged completely free of symptoms, under oral anticoagulation for 1 year.

Regarding toxoplasmosis, treatment of immunocompetent adults with lymphadenopathic toxoplasmosis is rarely indicated due to its usually self-limited evolution[6]. The only prescription being bed rest.

---

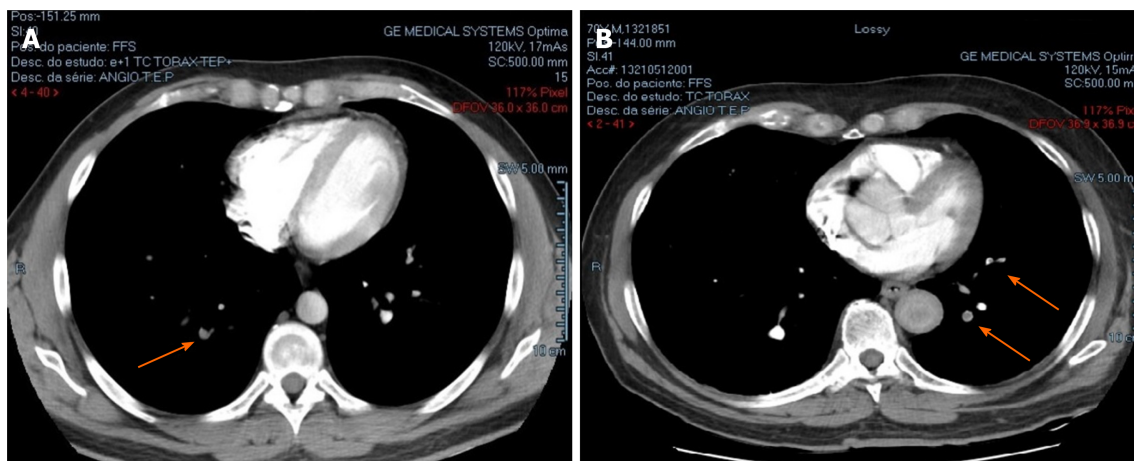
## **OUTCOME AND FOLLOW-UP**

Father and son have totally recovered without sequelae. After 1 year of follow-up, patients have not presented a recurrence of either morbid condition.

**Table 1 Laboratory tests and imaging studies for both patients showing altered findings**

| Laboratory tests and imaging studies             | Father (older patient)   | Son (younger patient)  | Normal values and conditions               |
|--|--|--|--|
| C-reactive protein (mg/L)                        | 4.6  | 44.8   | < 1.2                                      |
| <i>Toxoplasma gondii</i> IgM antibodies (UI/mL)  | 19.8   | 30.8   | < 0.5                                      |
| FVL mutation status (gene F5, c.691G>A, p.R506Q) | Heterozygosis  | Heterozygosis  | Unmutated                                  |
| D-dimer (ng/mL)                                  | 5.724  | Not performed  | < 500                                      |
| Lower limbs Doppler ultrasound                   | Absent blood flow in anterior tibial, posterior tibial, and fibular veins in the left leg                          | Absent blood flow in anterior tibial, posterior tibial, fibular, and popliteal veins in the right leg  | Presence of blood flow in the veins        |
| Chest CT scan                                    | Filling defects in segmental and subsegmental arterial branches in upper and lower lobes of both lungs (Figure 1A) | Filling defects in segmental and subsegmental arterial branches in lower lobes of both lungs and in apical subsegmental artery of right lung (Figure 1B) | Absence of filling defects in the arteries |

FVL: Factor V Leiden; CT: Computed tomography.



**Figure 1 Pulmonary computed tomography angiography.** A: Father's pulmonary computed tomography angiography transversal slice of lungs showed filling defects in subsegmental arterial branches characterizing left pulmonary embolism (arrows); B: Son's pulmonary computed tomography angiography transversal slice of lungs showed right pulmonary embolism (arrow).

## DISCUSSION

Toxoplasmosis is a usually asymptomatic zoonosis with wide geographical distribution. According to the São Paulo Sanitary Surveillance Agency, at the beginning of 2019 there was an increased number of acute toxoplasmosis cases in São Paulo City, including asymptomatic cases only detected by positive serological tests due to a foodborne disease outbreak. Of the 165 notified cases, only 9% had severe complications, none being DVT or pulmonary embolism[7].

The relationship between toxoplasmosis and venous thrombosis is uncertain. There is evidence of direct[8,9] and indirect[3,5] toxoplasmosis effects that may lead to thrombotic events. Toxoplasmosis was described as resulting in cerebral vein thrombosis in severe cases of its congenital form in humans[8]. Placental thrombosis was also seen in abortions during experimental *Toxoplasma gondii* infection in sheep [9]. However, indirect toxoplasmosis effects have been more consistently reported in literature, especially human Toxoplasma-induced antiphospholipid syndrome[3,5]. However, our studied cases did not show positivity for any antibodies related to antiphospholipid syndrome.

Being a systemic infectious disease, the potential for toxoplasmosis to trigger a venous thrombosis *via* an inflammatory pathway cannot be neglected[1,2], especially in patients with FVL mutation heterozygous status, the most common type of inherent thrombophilia[10]. In association with a pre-existing prothrombotic state, the inflam-

matory and pro-hemostatic environment caused by the infection may have caused endothelial dysfunction and changes in coagulation homeostasis resulting in VTE[2]. Considering a scenario without direct endothelial damage, it is also possible that the inflammation itself had increased the genetic expression of tissue factor (factor III), thus initiating the extrinsic coagulation pathway[2]. These two hypothetical situations would favor activation of mutated factor V, therefore amplifying thrombus formation given the mutated factor V resistance to activated protein C[2].

Some experimental and clinical studies corroborate the interaction between congenital thrombophilia and systemic infections/sepsis leading to exacerbation of thrombotic activity[11-13]. Although they differ regarding the impact of the thrombophilia gene mutation heterozygosis on survival of infected individuals, most agree that there is a significant increase in thrombin generation markers and in the conversion of fibrinogen to fibrin, both of which represent more frequent and severe episodes of thrombosis[11-13].

Regarding other predisposing factors for DVT, only the older of the two patients had a long period of immobility during a flight concurrently with toxoplasmosis. It is also important to highlight that both patients had undergone previous surgeries with no venous thrombosis.

Considering father and son had been living with the FVL heterozygous mutation throughout their lives without any thrombotic events, it does not seem a simple coincidence that they both simultaneously had VTE with concurrent toxoplasmosis.

## CONCLUSION

This paper reports the unusual clinical cases of two closely related patients carrying the hereditary thrombophilia FVL heterozygous mutation who have concomitantly experienced the so far only VTE episode during concurrent *Toxoplasma gondii* acute infection. Their sharing of these three events does not seem to be mere coincidence and suggests a potential synergistic effect between toxoplasmosis and heterozygous mutation state for FVL as triggers of the thromboembolic events.

## REFERENCES

- 1 **Perez-Pujol S**, Aras O, Escolar G. Factor v leiden and inflammation. *Thrombosis* 2012; **2012**: 594986 [PMID: 22666576 DOI: 10.1155/2012/594986]
- 2 **Aksu K**, Donmez A, Keser G. Inflammation-induced thrombosis: mechanisms, disease associations and management. *Curr Pharm Des* 2012; **18**: 1478-1493 [PMID: 22364132 DOI: 10.2174/138161212799504731]
- 3 **Sène D**, Piette JC, Cacoub P. Antiphospholipid antibodies, antiphospholipid syndrome and infections. *Autoimmun Rev* 2008; **7**: 272-277 [PMID: 18295729 DOI: 10.1016/j.autrev.2007.10.001]
- 4 **Hatter JA**, Kouche YM, Melchor SJ, Ng K, Bouley DM, Boothroyd JC, Ewald SE. *Toxoplasma gondii* infection triggers chronic cachexia and sustained commensal dysbiosis in mice. *PLoS One* 2018; **13**: e0204895 [PMID: 30379866 DOI: 10.1371/journal.pone.0204895]
- 5 **Shapira Y**, Agmon-Levin N, Selmi C, Petriková J, Barzilai O, Ram M, Bizzaro N, Valentini G, Matucci-Cerinic M, Anaya JM, Katz BS, Shoenfeld Y. Prevalence of anti-Toxoplasma antibodies in patients with autoimmune diseases. *J Autoimmun* 2012; **39**: 112-116 [PMID: 22297145 DOI: 10.1016/j.jaut.2012.01.001]
- 6 **Montoya J**, Boothroyd J, Kovacs J. *Toxoplasma gondii*. In: Mandell G, Bennett J, Dolin R, Eds. Mandell, Douglas, and Bennett's Principles and Practice of Infectious Diseases. 8th ed. Philadelphia: Churchill Livingstone Elsevier, 2017: 3122-3153
- 7 **Coordenadoria de Vigilância em Saúde de São Paulo**. Toxoplasmose: Boletim epidemiológico, São Paulo, n 1, 2019. [cited 2021 Mar 7]. Available from: [https://www.prefeitura.sp.gov.br/cidade/secretarias/upload/saude/boletim\\_toxoplasmose\\_2019.pdf](https://www.prefeitura.sp.gov.br/cidade/secretarias/upload/saude/boletim_toxoplasmose_2019.pdf)
- 8 **Wiebe B**, Fremerey C, Ehlen M. 539 Severe form of Congenital Toxoplasmosis with Extensive Cerebral findings. *Arch Dis Childhood* 2012; **97**: A156-A7 [DOI: 10.1136/archdischild-2012-302724.0539]
- 9 **Castaño P**, Fuertes M, Ferre I, Fernández M, Ferreras Mdel C, Moreno-Gonzalo J, González-Lanza C, Katzer F, Regidor-Cerrillo J, Ortega-Mora LM, Pérez V, Benavides J. Placental thrombosis in acute phase abortions during experimental *Toxoplasma gondii* infection in sheep. *Vet Res* 2014; **45**: 9 [PMID: 24475786 DOI: 10.1186/1297-9716-45-9]
- 10 **Campello E**, Spiezia L, Simioni P. Diagnosis and management of factor V Leiden. *Expert Rev Hematol* 2016; **9**: 1139-1149 [PMID: 27797270 DOI: 10.1080/17474086.2016.1249364]
- 11 **Kondaveeti S**, Hibberd ML, Booy R, Nadel S, Levin M. Effect of the Factor V Leiden mutation on the severity of meningococcal disease. *Pediatr Infect Dis J* 1999; **18**: 893-896 [PMID: 10530586]



DOI: [10.1097/00006454-199910000-00011](https://doi.org/10.1097/00006454-199910000-00011)]

- 12 **Kerlin BA**, Yan SB, Isermann BH, Brandt JT, Sood R, Basson BR, Joyce DE, Weiler H, Dhainaut JF. Survival advantage associated with heterozygous factor V Leiden mutation in patients with severe sepsis and in mouse endotoxemia. *Blood* 2003; **102**: 3085-3092 [PMID: [12869495](https://pubmed.ncbi.nlm.nih.gov/12869495/) DOI: [10.1182/blood-2003-06-1789](https://doi.org/10.1182/blood-2003-06-1789)]
- 13 **Elmas E**, Suvajac N, Jilma B, Weiler H, Borggrefe M, Dempfle CE. Factor V Leiden mutation enhances fibrin formation and dissolution in vivo in a human endotoxemia model. *Blood* 2010; **116**: 801-805 [PMID: [20410502](https://pubmed.ncbi.nlm.nih.gov/20410502/) DOI: [10.1182/blood-2009-03-213215](https://doi.org/10.1182/blood-2009-03-213215)]



Published by **Baishideng Publishing Group Inc**  
7041 Koll Center Parkway, Suite 160, Pleasanton, CA 94566, USA

**Telephone:** +1-925-3991568

**E-mail:** [bpgoffice@wjgnet.com](mailto:bpgoffice@wjgnet.com)

**Help Desk:** <https://www.f6publishing.com/helpdesk>

<https://www.wjgnet.com>

