

Hirschsprung's disease: Historical notes and pathological diagnosis on the occasion of the 100th anniversary of Dr. Harald Hirschsprung's death

Consolato Sergi

Consolato Sergi, Department of Pediatrics, Stollery Children's Hospital, Alberta T6G 2B7, Canada

Consolato Sergi, Department of Lab Medicine and Pathology, University of Alberta Hospital, Edmonton, Alberta T6G 2B7, Canada

Author contributions: Sergi C designed research, performed literature research, contributed to the analytic tools, analyzed data, and wrote the paper.

Conflict-of-interest statement: Dr. Sergi C is a "ad hoc" consultant of the World Health Organization (WHO)/International Agency for Research on Cancer (IARC) sitting in the panel as collaborator for the use of pesticides and cancer (IARC Monographs Volume 112: evaluation of five organophosphate insecticides and herbicides) and Carcinogenicity of perfluorooctanoic acid, tetrafluoroethylene, dichloromethane, 1,2-dichloropropane, and 1,3-propane sultone. Moreover, Dr. Sergi C. has received research funding from the Women and Children Research Institute, Saudi Cultural Bureau, and the Canada Foundation for Women's Health (CFWH) (Award 2009: CFWH General Research Grant Dr. L. Hornberger and Dr. C. Sergi), and has received fees for serving as grant reviewer for the Health and Medical Research Fund (HMRF), Hong Kong Special Administrative Region, and as consultant for Guidepoint.

Open-Access: This article is an open-access article which was selected by an in-house editor and fully peer-reviewed by external reviewers. It is distributed in accordance with the Creative Commons Attribution Non Commercial (CC BY-NC 4.0) license, which permits others to distribute, remix, adapt, build upon this work non-commercially, and license their derivative works on different terms, provided the original work is properly cited and the use is non-commercial. See: <http://creativecommons.org/licenses/by-nc/4.0/>

Correspondence to: Consolato Sergi, MD, MSc, FRCPC, PhD, Professor, Department of Lab Medicine and Pathology, University of Alberta Hospital, Edmonton, 8440 112 St, Alberta T6G 2B7, Canada. sergi@ualberta.ca
Telephone: +1-780-4077951
Fax: +1-780-4073009

Received: May 7, 2015

Peer-review started: May 8, 2015

First decision: June 9, 2015

Revised: August 21, 2015

Accepted: September 10, 2015

Article in press: September 16, 2015

Published online: November 8, 2015

Abstract

Hirschsprung's disease (HSCR) or congenital megacolon is one of the differential diagnoses of chronic constipation mostly in infancy and may indeed represent a challenge for pediatricians, pediatric surgeons, and pediatric pathologists. The diagnosis relies clearly on the identification of the absence of ganglion cells at the plexuses (submucosus and myentericus) of the bowel wall. HSCR is usually located at the terminal (distal) rectum with potential pre-terminal or proximal extension to the less distal large bowel (sigmoid colon). Astonishingly, there is some evidence that Hindu surgeons of prehistoric India may have been exposed and had considerable knowledge about HSCR, but this disease is notoriously and eponymously named to Dr. Harald Hirschsprung (1830-1916), who brilliantly presented two infants with fatal constipation at the Berlin conference of the German Society of Pediatrics more than one century ago. Historical milestones and diagnosis of HSCR (originally called "Die Hirschsprungsche Krankheit") are reviewed. More than 100 years following his meticulous and broad description, HSCR is still a puzzling disease for both diagnosis and treatment. HSCR remains a critical area of clinical pediatrics and pediatric surgery and an intense area of investigation for both molecular and developmental biologists.

Key words: Constipation; Analysis; Rectum; Medicine; Biopsy; History

© The Author(s) 2015. Published by Baishideng Publishing Group Inc. All rights reserved.

Core tip: Medical history is fascinating and, since its beginning, it was meant to enlighten scientific issues, booster the medical profession, and celebrate the traditions or tales of particular places. Harald Hirschsprung, who presented two infants with fatal constipation at the German Society of Pediatrics more than one century ago, is known in medicine for his eponym of intestinal aganglionosis. Events running before and after Dr. Hirschsprung's discovery may drive interest in medical students and doctors to review the diagnostic procedures of this intriguing disease and recognize the enormous input given from microscopy and pathology to this diagnosis.

Sergi C. Hirschsprung's disease: Historical notes and pathological diagnosis on the occasion of the 100th anniversary of Dr. Harald Hirschsprung's death. *World J Clin Pediatr* 2015; 4(4): 120-125 Available from: URL: <http://www.wjgnet.com/2219-2808/full/v4/i4/120.htm> DOI: <http://dx.doi.org/10.5409/wjcp.v4.i4.120>

HIRSCHSPRUNG'S ANNIVERSARY

In 2016, a particular and noteworthy anniversary recurs that will probably have enormous impact to clinical pediatrics, pediatric surgery, and pediatric pathology. Dr. Harald Hirschsprung (1830-1916), a Danish pediatrician, first described Hirschsprung's disease or congenital megacolon about one and half century ago. He is notoriously acknowledged as the writer of the first description of two children who died of intestinal obstruction called "congenital megacolon", which is now known as Hirschsprung's disease (HSCR)^[1]. Dr. Hirschsprung was working as pediatrician at Queen Louise Children's Hospital in Copenhagen, Denmark, when he came across this disease. He brilliantly reported two children in 1886 in occasion of the Berlin Conference of the German Society of Pediatrics.

WHEN THE SAGA BEGAN

Dr. Hirschsprung, who graduated with a degree in medicine in 1855, showed since his first steps into medical career a strong interest in pediatrics, becoming astoundingly the chief physician of the only children's hospital in Copenhagen just fifteen years later. The appointment as professor of pediatrics came in 1877 and Dr. Hirschsprung became director of a larger children's hospital in Copenhagen from 1879 until 1904, when he retired. The new children's hospital was magnificently named after Denmark's Queen Louise (The Queen Louise Hospital for Children). Dr. Hirschsprung was fond of anatomical variations, peculiar aspects of medicine, and intriguing diseases. He was a brilliant teacher with loyal and faithful students. Between 1880 and 1885, Hirschsprung came across two infants with

similar clinical presentation. The first child had bowel problems that persisted soon after birth with absence of spontaneous bowel movements. Daily enemas and laxatives were necessary. The second case had similar bowel distensions with terminal bouts of diarrhea variably alternating with impossibility to evacuate. Notwithstanding the scarcity of information continuous therapy was applied, but, unfortunately, both children eventually died and a postmortem examination was performed. At the autopsy, the rectum was narrowed, but there were striking dilation of the bowel loops with some ulceration of the mucosa associated with thickening of the bowel wall^[2,3]. In his publication, Dr. Hirschsprung summarized his findings and drew attention to the typical clinical presentation of both cases. In an opinion, which is worldwide shared, his meticulous and comprehensive description is not the first one to indicate details of this disease, but he provided a complete and excellent account of this entity in consideration of his clinical experience and practice in pediatrics^[4]. The name "Hirschsprung's disease" came into widespread use shortly before the end of the 20th century and, in 1916, Hirschsprung himself added an additional 10 more cases before his death^[5-8].

DIGGING INTO THE PRE-HIRSCHSPRUNG ERA

The examination of the scientific literature seems indicate that approximately 20 similar cases have been recorded between 1825 and 1888^[9]. However, there is evidence that Hindu surgeons of prehistoric India had considerable knowledge about HSCR^[10]. Sushruta's description of a disease called Baddha Gudodaram is extraordinarily analogous to that of HSCR. Semantically, it seems indicate "abdominal distension due to blocked rectum". According to Sushruta, Baddha Gudodaram is a type of disease caused by (functional) blockage of the ano-rectal canal. The affected child or, even, young adult may show rectum and distal colon stuffed with gas, "stones" (fecaliths), "hair" (undigested fibers), and, obviously, feces. In the child, there is an abdominal distension, which is characteristically seen between the heart and the umbilicus. Scanty stools are evacuated with greatest difficulty, and, eventually, it was reported that the patient might vomit feculent fluid. However, the pre-Hirschsprung era is not complete, if additional reports are not also mentioned. Indeed, Fredericus Ruysch, a Dutch anatomist in Amsterdam (Netherland) in 1691 described a 5-year-old girl with abdominal pain. It seems that the usual treatment to relieve pain was permanently inefficacious and the child continued to pass flatulence. No evacuation was practically possible and the child ultimately died^[11]. Remarkably, Domenico Battini, an Italian physician of the 19th century described a child that he followed up for 10 years with severe constipation. The child died and the autopsy demonstrated severe dilatation of the colon^[12]. The posthumously published

Italian contribution showed not only a very careful clinical evolution of the child, but also provided a detailed autopsy with examination of the abdominal viscera. Particular mention to the morphological alterations occurred in the large bowel were present in the original Italian publication. Through the examination of the reports, Fiori concludes that Dr. Battini, nearly one century before Hirschsprung, may have originally achieved its target in reporting an archetypal case of megacolon of congenital type. Distinctively, a number of characteristic features, including familiarity and the peculiar selective involvement of "neural layers" of the bowel, that later became characteristic of HSCR, were remarkably well postulated by Dr. Domenico Battini. To increase the controversy between Denmark and Italy as well as other countries, there may be a few more reports that need to be listed. In 1836, Ebers^[13] reported a 17-year-old boy with a history of constipation since birth or, perhaps, as toddler, while Jacobi^[14] had also described two neonates with intestinal obstruction in 1869. Fragmentary reports of children who died of severe constipation appeared also in the literature in the pre-Hirschsprung era^[15,16]. In fact, Gee^[17] reported the autopsy findings of a 4-year-old child with a "spasm" of the sigmoid colon without involving of the rectum in 1884, while Bristowe^[18] described the outcome of a 8-year-old girl who died of mechanic ileus after longstanding severe constipation of the bowel. Dr. Hirschsprung died on April 11, 1916, but his supreme legacy to clinical pediatrics, pediatric surgery, and pediatric pathology is unmatched with contributions that go further than severe constipation in children or the disease harboring his name ("Hirschsprungsche Krankheit"). The Danish pediatrician observed and described in detail several diseases, including pyloric stenosis and intussusception. Dr. Hirschsprung indicated guidelines for management of a broad spectrum of pediatric diseases, including contributions in the area of teratology and clinical dysmorphology^[4]. These contributions are now part of the didactic activity and scientific investigation of innumerable professors and researchers of Pediatrics, Pediatric Surgery, and Pediatric Pathology of the 21st century. His legacy to children is marvelous. He participated actively to the building of the children's hospital and his dedication to children was adamant and unbending. Queen Louise wanted the wall spaces above doors to harbor biblical quotations for the edification of the sick children, but Dr. Hirschsprung considered more appropriate to give the children an environment that could bring some quietness. In consideration of the sensibility of the children, he firmly refused the holy quotations and suggested colorful and beautiful wall decorations of animals and flowers, which in the end were well accepted by the Danish crown to be inserted in the wall spaces above doors.

BEYOND THE HIRSCHSPRUNG'S DISCOVERY

Recently, the interest has focused on the diagnosis

of HSCR mainly because of the jeopardy of methods used to make the diagnosis and their accuracy. Being a genetic disease quite diverse, main topics on HSCR involve, indeed, the investigation of the best diagnostic marker for HSCR and changes that may take place during ganglion cell maturation. In the setting of the diagnosis, we recently published a systematic review on HSCR trying to identify the value of single methods to ascertain currently this diagnosis^[19]. HSCR is now known as the most common cause of neonatal lower intestinal obstruction occurring in 1:5000 live birth newborns. HSCR involves in about three quarters of cases male children, and its incidence is variable according to ethnics. The caudal migration of the primordial neural crest cells starts at the upper end of the gut following progressively the vagal fibers distally. A delay or arrest in this migration induces failure of the neural crest cells to reach the distal bowel with consequent congenital abnormal nerve innervation of the bowel. There is a caudo-cranial severity, which means from the internal anal sphincter extending proximally for a variable length of gut. Pathophysiologically, there is a proximal intestine, which is dilated and progresses to an abrupt or, alternatively, gradual transition to a normal calibrated distal bowel. This distal intestinal segment shows typically a funnel like or cone shaped zone in between (the so-called "transition zone"). Moreover, there is a proximal muscle hypertrophy. This anatomic and prominent feature of the colon, located proximal to the aganglionic segment, represents undoubtedly an effort to overcome the partial obstruction. The bowel becomes distended with thickening of its wall, and the degree of dilatation and hypertrophy depends intricately upon both the time and degree of obstruction and obviously, indirectly, to the age of the patient. Clinical presentation settings include failure to pass meconium within the 24-h of life considering that 98% of newborns pass meconium in less than 24-h of age, neonatal intestinal obstruction syndrome (abdominal distension, refusal to feed, and vomiting of bilious type), and recurrent enterocolitis (mainly infants less than 3 mo of life), toxic megacolon, spontaneous perforation, and chronic constipation with persistent failure to thrive. Toxic megacolon includes fever, abdominal distension, bile stained vomiting, explosive diarrhea, dehydration, and shock. History includes failure to pass meconium, painless abdominal distension, and, obviously, constipation. Physical examinations of children with HSCR includes enlarged abdominal circumference with numerous fecal masses. Digital or post-evacuation examinations reveal hypertonic anal sphincter, typical empty rectum, and hard fecal mass. Radiology (plain abdominal X-ray both erect and supine as well as contrast enema) typically shows narrow distal segment, funnel-shaped dilatation characteristically localized at level of transition zone as well as marked dilatation of the proximal colon. Moreover, a poor emptying of barium throughout the colon in 24-h delayed films is also found. A differential diagnosis of "psychogenic" stool is requested and, in

Table 1 Differential diagnosis of chronic pseudo-obstruction of the child and young adult

Organic colorectal diseases	
Pseudotumors (<i>e.g.</i> , rectocele)	
Neoplasms (both benign and malignant epithelial and mesenchymal)	
Strictures (postinflammatory, posts ischemic, posttransplant, <i>etc.</i>)	
	Apostinflammatory (<i>e.g.</i> , Crohn's disease)
	Postischemic (<i>e.g.</i> , necrotizing enterocolitis)
	Graft <i>vs</i> host disease
	Others
Dysmetabolism	
Severe hypothyroidism	
Calcium imbalance (hypercalcemia)	
Potassium imbalance (hypokalemia)	
Diabetes mellitus (autonomic neuropathy)	
Autonomic Enteric Neuro-Myopathies	
Scleroderma or systemic sclerosis	
Amyloidosis or familial mediterranean Fever	
Sarcoidosis	
Central nervous system - pathologies	
Cerebral palsy	
Spinal cord injury	
Demyelinating disease in youth (<i>e.g.</i> , multiple sclerosis)	
Iatrogenic Chronic Pseudo-Obstruction (drugs-related)	
	Anticholinergics, antidepressants (especially tricyclic antidepressants), antipsychotics, calcium-channel blockers, aluminum (antacids), narcotics and narcotic-related drugs

Drugs-related chronic pseudo-obstruction may have different and multiple etiologies and accidental intoxication should also be taken into account.

this latter case, the barium generally collects in the distal recto-sigmoid colon. Electromanometry shows absence of the recto-anal inhibitory reflex (RAIR) when the rectum is distended. RAIR is defined as the reflex of relaxation of the internal anal sphincter following rectal distension (balloon). RAIR (+) means normal, while lack of RAIR, RAIR (-), means HSCR. Bedside or outpatient procedures seem to give no complications. The test is unreliable if the gestational age plus post-natal age is less than 39 wk and birth weight is less than 2.7 kg. However, if, at neonatal age, electromanometry is useless, it represents a good screening tool in infancy and childhood. Ultrasonography is important to rule out associated anomalies and a genetic counselling may be considered appropriate according to the familiarity and the phenotype of the patients affected with HSCR. Rectal biopsy is the definitive diagnostic test showing absence of ganglion cells, presence of nerve hypertrophy, and increased acetyl-cholinesterase activity. It may include either a suction mucosal biopsy (at different levels) or a full thickness biopsy. Suction, transmural, and jumbo biopsies are the usual biopsies taken in an infant with severe constipation. It is a general opinion that pediatricians play a major role in diagnosing HSCR and dysmorphic features remain important landmarks that need to be identified first by clinical pediatricians and, later discussed with clinical geneticists. Typically, HSCR is clinically identified as a solitary gastro-intestinal anomaly in a full term, otherwise healthy newborn or infant, but associated anomalies do occur in about 1/5 of cases, including uro-genital system (11%), cardio-vascular system (6%), gastro-intestinal system (6%), and other

systemic congenital defects (8%). In as many as 1/10 of children with HSCR, the condition of prematurity has been reported. Trisomy 21 syndrome (Down syndrome) occurs in approximately 1/20 of children with HSCR. Astoundingly, the work of the pathologists is impressive and their criteria for diagnosing HSCR are quite straightforward and easy to follow in classic cases as indicated above. Figure 1 shows mature and immature ganglion cells of the submucosa plexus of a rectal suction biopsy performed at 2 cm above the pectinate line in a 3-mo-old infant and a newborn with severe constipation. It is important to highlight that not all-severe constipation mean automatically HSCR. Table 1 indicates a differential diagnosis of chronic pseudo-obstruction of the child and young adult. Figures 2 and 3 show the absence of ganglion cells and the hypertrophy of nerve fibers in an infant with HSCR operated with pull-through procedure. Both the lack of ganglion cells and the hypertrophy of nerve fibers are pathologic landmarks of HSCR.

CONCLUSION

Several loci seem to be involved in HSCR. Nevertheless, the molecular-biologic basis of this intriguing gastro-intestinal disorder remains yet essentially unknown. In our working group at the Stollery Children's Hospital, we consider that the study of combined properties of modules linking functionally related genes may shed light on an efficient and effective platform of transcriptomics that can target rare diseases. A "Pathway-Based Analysis" may help to confirm a strong association bet-

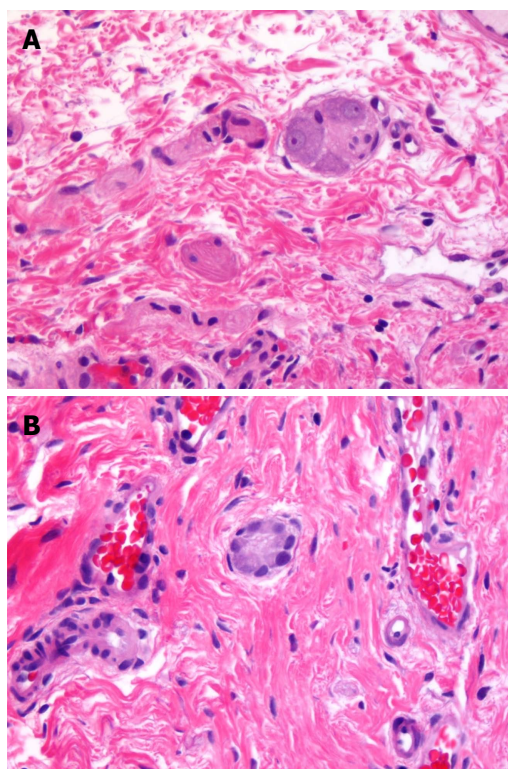


Figure 1 Mature ganglion cells (A) and immature ganglion cells (B). A: Mature ganglion cells; B: Immature ganglion cells (Hematoxylin and Eosin staining, magnification: 400 × for both photographs).

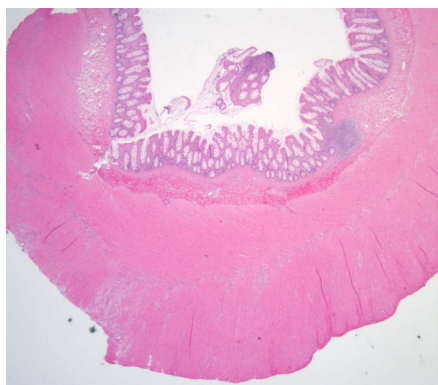


Figure 2 Hirschsprung's disease showing hypertrophy of nerve fibers.

ween genes and pathways related to signal transduction and its regulation of the enteric nervous system^[20,21]. Most recently, some potential molecular markers, *e.g.*, targeting variations of *PTCH1* gene, have been reported to be useful for early diagnosis of HSCR in the Han Chinese population^[22]. The *WNT8A* gene has also been involved in the susceptibility to HSCR and may play an important role in the occurrence and development of HSCR^[23].

In summary, HSCR is still a disease with many unclear aspects. HSCR is due to migration failure of neural crest cells. Definitive anatomic-pathologic finding that identifies HSCR is the absence of ganglion cells in both the submucosal and myenteric plexuses. Thus,

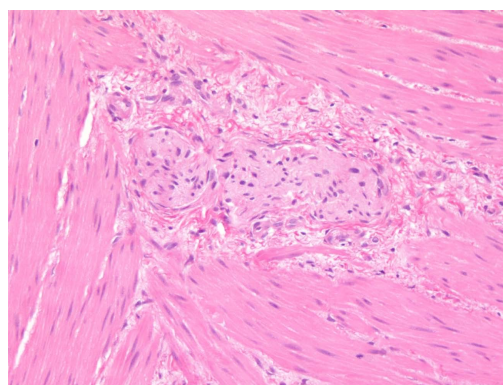


Figure 3 Hirschsprung's disease showing hypertrophy of nerve fibers and lack of ganglion cells.

rectal biopsy is definitive in most cases. In doubt, ancillary techniques may be applied, but a re-biopsy is the best choice^[19]. If research is supported, signaling pathways may be identified that may play a diagnostic other than a mechanistic role. Despite genes and pathways identified in patients at the beginning of the 21st century there is still a lot to do investigating etiology, pathogenesis, and treatment modalities of this frightful disease.

ACKNOWLEDGMENTS

We are very grateful to the patients and families affected with Hirschsprung disease that allow performing research on this difficult topic. We acknowledge the contribution of pathologists (pediatric pathologists and gastrointestinal pathologists) of the Department of Laboratory Medicine and Pathology at the University of Alberta, Edmonton, Canada, who offered second opinion on surgical biopsies. Moreover, we acknowledge the contribution of pediatricians and pediatric surgeons, who gave good comments and suggestions in the diagnosis and management of Hirschsprung disease (<http://lmp.med.ualberta.ca/Pages/default.aspx>).

REFERENCES

- 1 **Skaba R.** Historic milestones of Hirschsprung's disease (commemorating the 90th anniversary of Professor Harald Hirschsprung's death). *J Pediatr Surg* 2007; **42**: 249-251 [PMID: 17208575 DOI: 10.1016/j.jpedsurg.2006.09.024]
- 2 **Hirschsprung H.** Constipation of newborns as a result of dilatation and hypertrophy of the colon. *Jhrb f Kinderh* 1888; **27**: 1-7
- 3 **Roed-Petersen K, Erichsen G.** The Danish pediatrician Harald Hirschsprung. *Surg Gynecol Obstet* 1988; **166**: 181-185 [PMID: 3276016]
- 4 **Jay V.** Legacy of Harald Hirschsprung. *Pediatr Dev Pathol* 2001; **4**: 203-204 [PMID: 11178638 DOI: 10.1007/s100240010144]
- 5 **Walker TJ.** Congenital(?) Dilatation and Hypertrophy of the Colon Fatal at the Age of 11 Years. *Br Med J* 1893; **2**: 230-231 [PMID: 20754384 DOI: 10.1136/bmj.2.1700.230]
- 6 **Mya G.** Two observations of congenital dilatation and hypertrophy of the colon. *Sperimentale* 1894; **48**: 215-231
- 7 **Genersich G.** Concerning a congenital dilatation and hypertrophy of the colon. *Jb Kinderheilk* 1894; **37**: 91-100

- 8 **Concetti L.** About some innate colon malformation causing habitual constipation of children. *Arch Kinderheilk* 1899; **27**: 319-353
- 9 **Finney MT.** Congenital idiopathic dilatation of the colon. *Surg Gynecol Obstet* 1908; **6**: 624-643
- 10 **Raveenthiran V.** Knowledge of ancient Hindu surgeons on Hirschsprung disease: evidence from Sushruta Samhita of circa 1200-600 BC. *J Pediatr Surg* 2011; **46**: 2204-2208 [PMID: 22075360 DOI: 10.1016/j.jpedsurg.2011.07.007]
- 11 **Ruysch F.** Observationum anatomico-chirurgicarum centuria. Amstelodami, 1691
- 12 **Fiori MG.** Domenico Battini and his description of congenital megacolon: a detailed case report one century before Hirschsprung. *J Peripher Nerv Syst* 1998; **3**: 197-206 [PMID: 10959250]
- 13 **Ebers G.** History of a rare case of ileus. *Hufland's J* 83/2:62-89, 1836
- 14 **Jacobi A.** On some important causes of constipation in infants. *Am J Obstet* 2:96, 1869
- 15 **Ehrenpreis TH.** Megacolon in the newborn. A clinical and roentgenological study with special regard to the pathogenesis. *Acta Chir Scand* 1946; **94** Suppl: 112
- 16 **Cass D.** Hirschsprung's disease: an historical review. *Prog Pediatr Surg* 1986; **20**: 199-214 [PMID: 3095874 DOI: 10.1007/978-3-642-70825-1_15]
- 17 **Gee SJ.** Treatment of Intestinal Obstruction. A discussion at the Liverpool Medical Institution. *Lancet* 3197, 1019-1020, 1884
- 18 **Bristowe JS.** Clinical Lecture on the Consequences of Long Continued Constipation. *Br Med J* 1885; **1**: 1085-1088 [PMID: 20751277 DOI: 10.1136/bmj.1.1274.1085]
- 19 **Takawira C,** D'Agostini S, Shenouda S, Persad R, Sergi C. Laboratory procedures update on Hirschsprung disease. *J Pediatr Gastroenterol Nutr* 2015; **60**: 598-605 [PMID: 25564805 DOI: 10.1097/MPG.0000000000000679]
- 20 **Fernández RM,** Bleda M, Luzón-Toro B, García-Alonso L, Arnold S, Sribudiani Y, Besmond C, Lantieri F, Doan B, Ceccherini I, Lyonnet S, Hofstra RM, Chakravarti A, Antiñolo G, Dopazo J, Borrego S. Pathways systematically associated to Hirschsprung's disease. *Orphanet J Rare Dis* 2013; **8**: 187 [PMID: 24289864 DOI: 10.1186/1750-1172-8-187]
- 21 **Saeed A,** Barreto L, Neogii SG, Loos A, McFarlane I, Aslam A. Identification of novel genes in Hirschsprung disease pathway using whole genome expression study. *J Pediatr Surg* 2012; **47**: 303-307 [PMID: 22325380 DOI: 10.1016/j.jpedsurg.2011.11.017]
- 22 **Wang Y,** Wang J, Pan W, Zhou Y, Xiao Y, Zhou K, Wen J, Yu T, Cai W. Common genetic variations in Patched1 (PTCH1) gene and risk of hirschsprung disease in the Han Chinese population. *PLoS One* 2013; **8**: e75407 [PMID: 24073265 DOI: 10.1371/journal.pone.0075407]
- 23 **Gao H,** Chen D, Liu X, Wu M, Mi J, Wang W. Polymorphisms and expression of the WNT8A gene in Hirschsprung's disease. *Int J Mol Med* 2013; **32**: 647-652 [PMID: 23836442 DOI: 10.3892/ijmm.2013.1433]

P- Reviewer: Agilli M, Kolettis TM

S- Editor: Tian YL **L- Editor:** A **E- Editor:** Jiao XK





Published by **Baishideng Publishing Group Inc**

8226 Regency Drive, Pleasanton, CA 94588, USA

Telephone: +1-925-223-8242

Fax: +1-925-223-8243

E-mail: bpgoffice@wjgnet.com

Help Desk: <http://www.wjgnet.com/esps/helpdesk.aspx>

<http://www.wjgnet.com>

