

World Journal of *Clinical Urology*

World J Clin Urol 2020 September 12; 9(1): 1-15



ORIGINAL ARTICLE**Retrospective Study**

- 1 Estimation of successful capping with complete aspiration of bladder *via* nephroureterostomy tube
Maybody M, Shay WK, Fleischer DA, Hsu M, Moskowitz C
- 9 Evaluation of patient reported outcome measures post urethroplasty: Piloting a “Trifecta” approach
Ong M, Duncan C, McGrail M, Desai DJ

ABOUT COVER

Editorial Board Member of *World Journal of Clinical Urology*, Dr. YM Fazil Marickar is Dean of Mount Zion Medical College (Kerala, India). He was previously Principal, Azeezia Medical College and Professor and Head of Surgery Government Medical College and SUT College of Medicine. He was the first PhD in the medical faculty (Urology) of Kerala University (1991) and the first and only surgeon awarded FAMS in Surgery (1999) and the prestigious Pandalai Oration award of Association of Surgeons of India (2008), the highest national award. He has served as surgical teacher for the last 47 years and conducted extensive research on urinary stone disease, authoring 395 papers, 9 books and 3 textbooks. He is President of the Association of Genito Urinary Surgeons of India, Secretary of the National Academy of Medical Sciences Kerala Chapter, Chief Editor of the *Kerala Surgical Journal*, and Editorial Board Member of *Urological Research*. (L-Editor: Filipodia)

AIMS AND SCOPE

The primary aim of *World Journal of Clinical Urology* (WJCU, *World J Clin Urol*) is to provide scholars and readers from various fields of urology with a platform to publish high-quality basic and clinical research articles and communicate their research findings online.

WJCU mainly publishes articles reporting research results and findings obtained in the field of urology and covering a wide range of topics including andrology, benign prostatic hyperplasia, diagnostic imaging, endoscopy, genital diseases, incontinence, minimally invasive therapy, pharmacology, renal transplantation, urinary reconstruction, urinary tract stones, urodynamics and urinary dysfunction, urogenital abnormalities, urogenital neoplasms, urogenital surgical procedures, and urologic diseases.

INDEXING/ABSTRACTING

World Journal of Clinical Urology is now indexed in China National Knowledge Infrastructure (CNKI), China Science and Technology Journal Database (CSTJ), and Superstar Journals Database.

RESPONSIBLE EDITORS FOR THIS ISSUE

Production Editor: Yu-Jie Ma; Production Department Director: Xiang Li; Editorial Office Director: Ya-Juan Ma.

NAME OF JOURNAL

World Journal of Clinical Urology

ISSN

ISSN 2219-2816 (online)

LAUNCH DATE

December 28, 2011

FREQUENCY

Irregular

EDITORS-IN-CHIEF

Olivier Abbo, Jian Lu

EDITORIAL BOARD MEMBERS

<https://www.wjgnet.com/2219-2816/editorialboard.htm>

PUBLICATION DATE

September 12, 2020

COPYRIGHT

© 2019 Baishideng Publishing Group Inc

INSTRUCTIONS TO AUTHORS

<https://www.wjgnet.com/bpg/gerinfo/204>

GUIDELINES FOR ETHICS DOCUMENTS

<https://www.wjgnet.com/bpg/GerInfo/287>

GUIDELINES FOR NON-NATIVE SPEAKERS OF ENGLISH

<https://www.wjgnet.com/bpg/gerinfo/240>

PUBLICATION ETHICS

<https://www.wjgnet.com/bpg/GerInfo/288>

PUBLICATION MISCONDUCT

<https://www.wjgnet.com/bpg/gerinfo/208>

ARTICLE PROCESSING CHARGE

<https://www.wjgnet.com/bpg/gerinfo/242>

STEPS FOR SUBMITTING MANUSCRIPTS

<https://www.wjgnet.com/bpg/GerInfo/239>

ONLINE SUBMISSION

<https://www.f6publishing.com>



Retrospective Study

Estimation of successful capping with complete aspiration of bladder *via* nephroureterostomy tube

Majid Maybody, Wesley K Shay, Deborah A Fleischer, Meier Hsu, Chaya Moskowitz

ORCID number: Majid Maybody 0000-0003-4650-6640; Wesley K Shay 0000-0003-4076-9693; Deborah A Fleischer 0000-0002-5864-0989; Meier Hsu 0000-0002-9519-8560; Chaya Moskowitz 0000-0002-2850-8450.

Author contributions: Maybody M contributed to study conception and design, acquisition of data, analysis and interpretation of data, drafting of manuscript, and critical revision; Shay WK and Fleischer DA contributed to acquisition of data and critical revision; Hsu M and Moskowitz C contributed to analysis and interpretation of data, critical revision.

Supported by National Institute of Health (United States), No. P30 CA008748.

Institutional review board statement: This study was reviewed and approved by the Institutional Review Board/Privacy Board-B. The IRB determined that the protocol meets the requirements as set forth in the regulatory criteria for research approval and has been granted approval for 12 mo.

Informed consent statement: Your request to waive the requirement to obtain written informed consent and a research authorization has

Majid Maybody, Wesley K Shay, Deborah A Fleischer, Department of Radiology, Interventional Radiology Service, Memorial Sloan Kettering Cancer Center, New York, NY 10065, United States

Meier Hsu, Chaya Moskowitz, Department of Biostatistics and Epidemiology, Memorial Sloan Kettering Cancer Center, New York, NY 10065, United States

Corresponding author: Majid Maybody, MD, Associate Professor, Department of Radiology, Interventional Radiology Service, Memorial Sloan Kettering Cancer Center, No. 1275 York Avenue, M276C, New York, NY 10065, United States. maybodym@mskcc.org

Abstract

BACKGROUND

Ureteral stent and nephroureterostomy tube (NUT) are treatments of ureteral obstruction. Ureteral stent provides better quality of life. Internalization of NUT is desired whenever possible.

AIM

To assess outcomes of capping trial among cancer patients with complete aspiration of retained contrast from bladder *via* NUT.

METHODS

Our Institutional Review Board approved retrospective review of all NUT placement, NUT exchange and conversion of nephrostomy catheter into NUT performed during June 2013 to June 2015 ($n = 578$). Cases were excluded due to lack of imaging of bladder ($n = 37$), incomplete aspiration of bladder ($n = 324$), no attempt at capping NUT ($n = 166$), and patients with confounding factors interfering with results of capping trial including non-compliant bladder, bladder outlet obstruction and catheter malposition ($n = 14$). Study group consisted of 37 procedures in 34 patients (male 19, female 15, age 2-83 years, average 58, median 61) most with cancer (prostate 8, endometrial 5, bladder 4, colorectal 4, breast 2, gastric 2, neuroblastoma 2, cervical 1, ovarian 1, renal 1, sarcoma 1, urothelial 1 and testicular 1) and one with Crohn's disease. Medical records were reviewed to assess outcomes of capping trial. Exact 95% confidence intervals (95%CI) were calculated.

RESULTS

Among patients with complete aspiration of retained contrast, 30 (81%, 95%CI:

been granted.

Conflict-of-interest statement: We have no financial relationships to disclose.

Data sharing statement: No additional data are available.

Open-Access: This article is an open-access article that was selected by an in-house editor and fully peer-reviewed by external reviewers. It is distributed in accordance with the Creative Commons Attribution NonCommercial (CC BY-NC 4.0) license, which permits others to distribute, remix, adapt, build upon this work non-commercially, and license their derivative works on different terms, provided the original work is properly cited and the use is non-commercial. See: <http://creativecommons.org/licenses/by-nc/4.0/>

Manuscript source: Unsolicited manuscript

Received: April 9, 2020

Peer-review started: April 9, 2020

First decision: June 7, 2020

Revised: July 16, 2020

Accepted: August 15, 2020

Article in press: August 15, 2020

Published online: September 12, 2020

P-Reviewer: Cantiello F

S-Editor: Zhang L

L-Editor: A

P-Editor: Ma YJ



0.65-0.92) catheters were successfully capped (range 12-94 d, average 40, median 24.5) until planned conversion to internal stent (23), routine exchange (5), removal (1) or death unrelated to catheter (1). Seven capping trials (19%, 95%CI: 0.08-0.35) were unsuccessful (range 2-22 d, average 12, median 10) due to leakage (3), elevated creatinine (2), fever/hematuria (1) and nausea/vomiting (1).

CONCLUSION

Capping trial success among patients with complete aspiration of retained contrast/urine from bladder *via* NUT appears high.

Key Words: Nephroureterostomy tube; Ureteral stent; Capping trial; Internalization; Conversion; Percutaneous nephrostomy

©The Author(s) 2020. Published by Baishideng Publishing Group Inc. All rights reserved.

Core Tip: Patients with ureteral obstruction are best treated with cystoscopic placement of ureteral stent because of a better quality of life. When ureteral stent placement is not possible, a nephroureterostomy tube (NUT) is placed. Once the acute clinical problem is resolved, internalization is sought in order to improve patient's quality of life. Currently all patients undergo NUT capping trial which is needed before internalization. This work helps urologists and interventional radiologists to estimate success of capping trial. It helps define the endpoint of NUT placement or exchange interventions with potential benefits to patients and health care systems.

Citation: Maybody M, Shay WK, Fleischer DA, Hsu M, Moskowitz C. Estimation of successful capping with complete aspiration of bladder *via* nephroureterostomy tube. *World J Clin Urol* 2020; 9(1): 1-8

URL: <https://www.wjgnet.com/2219-2816/full/v9/i1/1.htm>

DOI: <https://dx.doi.org/10.5410/wjcu.v9.i1.1>

INTRODUCTION

Patients with ureteral obstruction are commonly treated with cystoscopic placement of ureteral stent. Compared to percutaneous approach with externalized catheter, cystoscopic approach is less invasive and the ureteral stent provides a better quality of life to patients. When ureteral stent placement is not possible or when it fails to alleviate hydronephrosis, percutaneous approach is indicated. This is achieved by placing percutaneous nephrostomy (PCN) catheter or nephroureterostomy tube (NUT). Once the acute clinical problem is resolved, internalization is sought in order to improve patient's quality of life. In case of PCN it is converted to NUT first. The NUT is capped for a few days (capping trial) simulating the presence of ureteral stent without the exteriorized catheter. If capping trial is successful, then NUT is converted to ureteral stent (internalization). A successful capping trial is defined when all of the below criteria are met: Lack of fever, lack of rise in serum creatinine level, lack of peri catheter leakage, lack of ipsilateral flank pain and lack of pelvic symptoms such as urgency, incontinence and pain.

After a failed capping trial, patients usually undergo catheter exchange with upsizing and/or change of catheter length in order to improve the outcome of the next trial. In some patients this process is repeated a few times. Currently all patients undergo capping trial(s) as a diagnostic intervention because there is no way of estimating the result. Estimating success of capping trial is helpful. It can help define the endpoint of a catheter exchange intervention with potential benefits to patients and health care systems. Some cancer patients with successful capping trial prefer to carry a capped NUT that can be uncapped if needed over an internal stent. The management algorithm for ureteral obstruction is shown in [Figure 1](#).

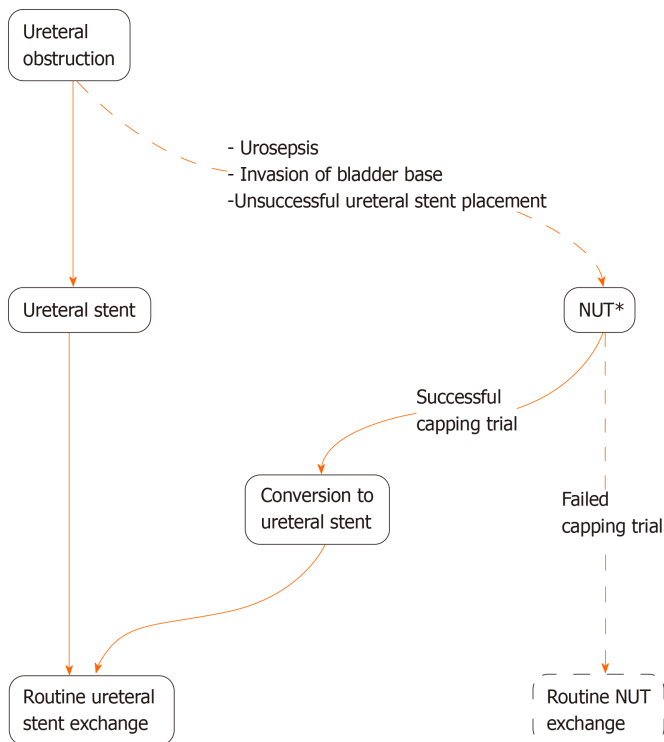


Figure 1 Algorithm of management of ureteral obstruction. The ideal objectives are highlighted with solid lines. Study's observation occurs when a nephroureterostomy tube is in place (asterisk). If originally a percutaneous nephrostomy catheter is placed, it will be converted to a nephroureterostomy tube before capping trial. NUT: Nephroureterostomy tube.

MATERIALS AND METHODS

Our Institutional Review Board approved retrospective review of all patients who underwent NUT placement, NUT exchange and conversion of PCN into NUT performed from June 2013 to June 2015. This included 578 procedures. Patients in whom complete aspiration of retained contrast/urine in bladder was evident followed by a capping trial were selected. The inclusion criteria were presence of NUT at the end of procedure, visualization of bladder on final procedural image, presence of discernible amount of contrast/urine in bladder during procedure, resolution of contrast from bladder on final procedural images, initiation of capping trial at least one d after the procedure and lack of confounding factors that interfere with capping trial (Figure 2).

The confounding factors were bladder outlet obstruction, noncompliant bladder, presence of Foley catheter in bladder (may mask pelvic symptoms), undrained obstructed contralateral kidney (interferes with interpretation of serum creatinine level), capping on the same d of procedure (not standard practice, higher risk for failure due to acute inflammation or bleeding from a fresh procedure) and malpositioning of NUT during capping trial that required catheter exchange (mimics capping failure by peri catheter leakage).

Cases were excluded due to lack of imaging of bladder on final procedural images ($n = 37$), uncertainty about complete aspiration of bladder ($n = 324$), no attempt at capping NUT ($n = 166$), confounding factors interfering with interpretation of capping trial ($n = 14$) (Figure 3).

Because some patients may become uroseptic with forceful injection of contrast antegradely into the renal pelvis, it is our standard practice to avoid forceful injection into NUT and to not pursue contrast flow into the bladder. The study was designed to only capture patients in whom procedural images were conclusive of aspiration of contrast from the bladder through NUT. Study cohort consisted of 37 procedures in 34 patients (male 19, female 15, age 2-83 years, average 58, median 61) (Table 1) mostly with cancer (prostate 8, endometrial 5, bladder 4, colorectal 4, breast 2, gastric 2, neuroblastoma 2, cervical 1, ovarian 1, renal 1, sarcoma 1, urothelial 1 and testicular 1) and one with Crohn's disease. Medical records including imaging studies, lab results, outpatient clinic visits, inpatient progress notes and interventional radiology records were reviewed to assess outcomes of capping trial. Successful capping trial was defined by lack of symptoms of failure until the goal of capping was achieved. The

Table 1 Patient demographics and capping trial outcomes

	Total	Successful capping	Unsuccessful capping
NUT procedures	37	30 (81%), 95%CI: 0.65-0.92	7 (19%), 95%CI: 0.80-0.35
Patients	34		
Gender			
Male	19	17	2
Female	15	10	5
Age (yr)			
Average (range)	58 (2-83)	59 (2-83)	56 (24-73)
Underlying cancer (procedures)			
	Prostate: 9	Prostate: 7	Prostate: 2
	Bladder: 5	Bladder: 5	
	Colorectal: 5	Colorectal: 5	
	Endometrial: 5	Endometrial: 3	Endometrial: 2
	Breast: 2	Breast: 1	Breast: 1
	Cervical: 2	Cervical: 2	
	Gastric: 2	Gastric: 1	Gastric: 1
	Neuroblastoma: 2	Neuroblastoma: 2	
	Ovarian: 1	Ovarian: 1	
	Renal: 1	Renal: 1	
	Sarcoma: 1	Sarcoma: 1	
	Testicular: 1	Testicular: 1	
	Crohn's: 1		Crohn's: 1
Catheter size (French)			
8.5	14	11	3
10	23	19	4
Catheter length (cm)			
22	10	8	2
24	16	13	3
26	8	6	2
28	2	2	0
32	1	1	0
Side			
Right	18	16	2
Left	10	6	4
Bilateral	4	3	1
Capping length (d)			
Average, Median, Range		40, 24.5, 12-94	12, 10, 2-22
Outcomes		Conversion to internal stent (<i>n</i> = 23); Routine exchange (<i>n</i> = 5); Removal (<i>n</i> = 1); Unrelated death (<i>n</i> = 1)	Peri catheter leakage (<i>n</i> = 3); Elevated creatinine (<i>n</i> = 2); Fever/hematuria (<i>n</i> = 1); Nausea/vomiting (<i>n</i> = 1)

NUT: Nephroureterostomy tube.

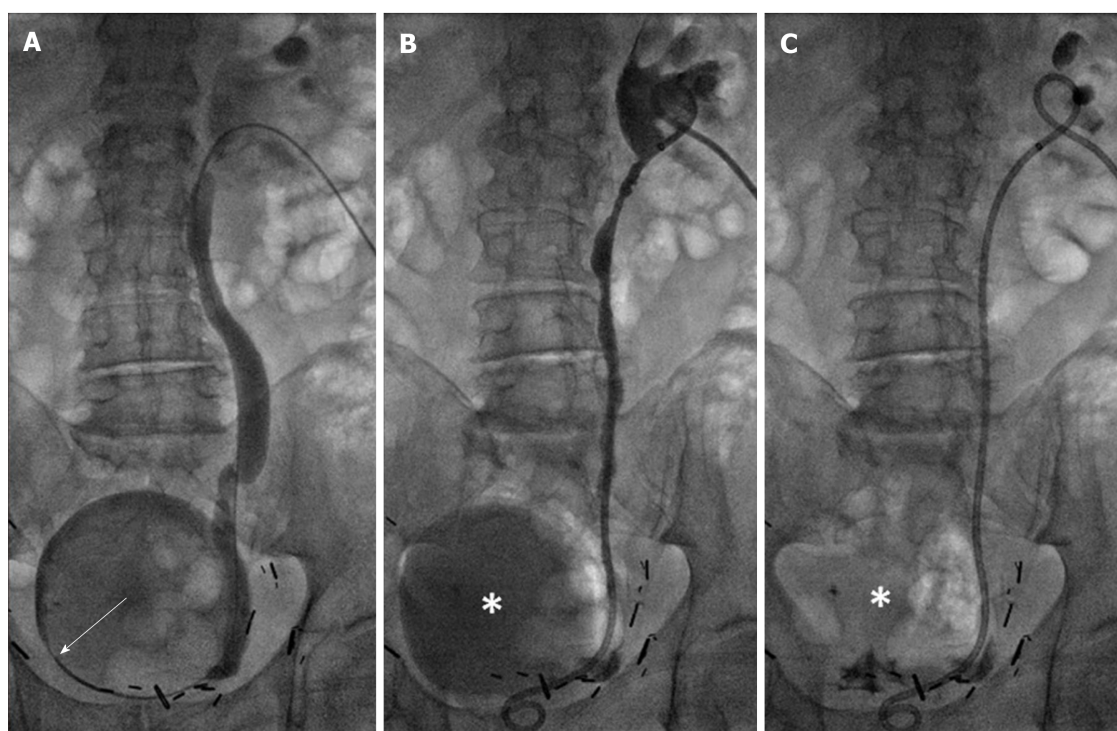


Figure 2 An 83 years old male with prostate cancer presented with right hydronephrosis from a tumor involving the right bladder base. Cystoscopic attempt at placing ureteral stent failed. The indication for drainage of kidney is to preserve renal function for chemotherapy. Prone position. A: Distal right ureteral obstruction is crossed and contrast is injected into the bladder by a 5 French directional catheter (arrow); B: A 10 F × 26 cm nephroureterostomy tube (NUT) is placed, and small amount of contrast is injected through the NUT to confirm proper positioning of the proximal loop. Retained contrast/urine in bladder (asterisk) is evident; and C: Retained contrast in bladder (asterisk) is completely aspirated via NUT. B and C are the final images of this intervention. The NUT was capped a few days later. It remained capped with no clinical issues for 42 d before it was converted to a ureteral stent.

goals are conversion of NUT to ureteral stent, removal of NUT and routine exchange of capped NUT.

The proportion of procedures that were successfully capped was estimated among patients with complete aspiration of retained contrast. Exact 95% confidence intervals (95% CI) were calculated.

RESULTS

Among the study cohort, 30 (81%, 95%CI: 0.65-0.92) had successful capping with a median length of capping of 24.5 d (range 12-94 d) until planned goal of conversion to internal stent ($n = 23$), routine exchange ($n = 5$) or removal ($n = 1$) and one patient who expired for reasons unrelated to catheter ($n = 1$). Substantially fewer patients had unsuccessful capping result ($n = 7$, 19%, 95%CI: 0.08-0.35) had median length of capping of 10 d (range 2-22 d) due to leakage ($n = 3$), elevated creatinine ($n = 2$), fever/hematuria ($n = 1$) and nausea/vomiting ($n = 1$).

DISCUSSION

Mechanical obstruction to the flow of urine from kidney to bladder can be due to a variety of etiologies. Among these include primary tumors involving the ureters or bladder, tumors or other space occupying lesions within abdomen and pelvis that compress ureters externally, nephrolithiasis and iatrogenic causes such as surgery. Acute obstruction is symptomatic and may result in urosepsis in some patients. Chronic obstruction mainly interferes with renal function. The first line of

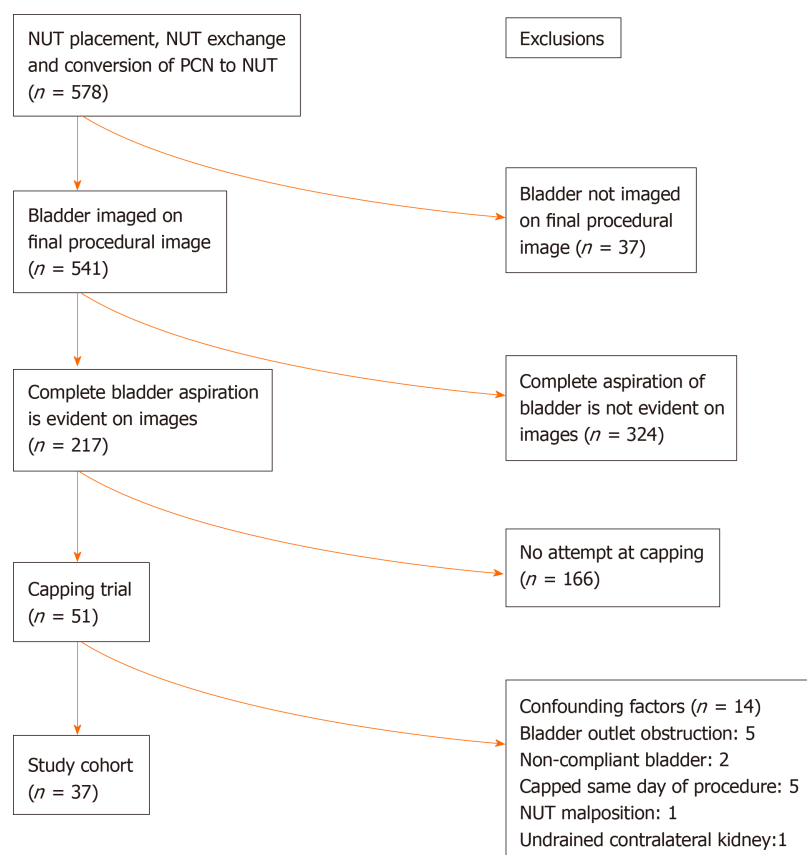


Figure 3 Flowchart of study. NUT: Nephroureterostomy tube; PCN: Percutaneous nephrostomy tube.

management for ureteral obstruction is cystoscopic placement a ureteral stent. This approach provides patients with better quality of life due to lack of external catheter and drainage bag. Cystoscopy may not be possible when tumors involve the base of bladder. If hydronephrosis does not resolve, the stent is considered failed. Patients with hemodynamic instability and urosepsis are not favorable candidates for cystoscopic approach. These scenarios account for 36%-53% of malignant ureteral obstructions and percutaneous approach is advised^[1,2]. Once the obstructing etiology is resolved the ureteral stent, PCN or NUT are removed. However, this is not always possible, and many patients remain dependent on these catheters. The external catheter puts limitations on patient's quality of life. For example, they cannot bathe or swim. Maintaining the gravity drainage bag is cumbersome and the catheter may get dislodged by incidental traction. It has been shown that both ureteral stent and external catheters have comparable complication rates^[2,3]. Since ureteral stent provides better quality of life, unless there is need for permanent urinary diversion which is achieved only by PCN, the optimal long-term plan is to convert external catheter into ureteral stent whenever possible. In case of PCN and in the absence of need for permanent urinary diversion, it needs to be converted to NUT first. NUT is capped for a few days to simulate lack of external component. If the capping trial is successful, the NUT is converted to ureteral stent. Predictors of ureteral stent outcomes including invasion of bladder base by tumor and degree of hydronephrosis have been published^[4-7]. There is no data in the literature about predictors of success for internalization in patients who receive external catheters and the percentage of patients who can ultimately be internalized. Having an indicator of favorable capping trial outcome is helpful in clinical decision-making and defining the endpoint of a catheter exchange intervention. We observed that at the conclusion of an intervention where a NUT is present if the retained contrast/urine in bladder can be aspirated through the NUT there is a high proportion of a successful capping trial. If bladder contrast/urine cannot be aspirated through the newly placed/exchanged NUT, the interventionalist may exchange the catheter with larger caliber or another length at the same sitting. This may save time and resources obviating the results of the next capping trial.

This study has several limitations including its retrospective design, small size of

study cohort and lack of control group. Our results are based on cancer patients with malignant ureteral obstruction and applicability of the results to non-cancer patients is not known. Since aspiration of retained contrast/urine from the bladder through the NUT is not standard practice and this description is not included in official dictations, we could only rely on cases where retained contrast/urine was completely aspirated on final procedural images. This created many exclusions which potentially skew the results.

ARTICLE HIGHLIGHTS

Research background

Ureteral stent and nephroureterostomy tube (NUT) are treatments of ureteral obstruction. Ureteral stent provides better quality of life. Internalization of NUT is desired whenever possible.

Research motivation

Before internalization of NUT patients should pass a capping trial. Currently there are no indicators of capping trial results.

Research objectives

To help urologists and interventional radiologists estimate successful capping trial during a NUT placement or exchange intervention. By preventing unsuccessful trials, patients and healthcare systems benefit.

Research methods

578 NUT placement, NUT exchange and conversion of nephrostomy catheter into NUT performed between 2013 and 2015 were reviewed. Exclusions were due to lack of imaging of bladder ($n = 37$), incomplete aspiration of bladder ($n = 324$), no attempt at capping NUT ($n = 166$), and patients with confounding factors interfering with results of capping trial ($n = 14$). Study group consisted of 37 procedures in 34 patients (male 19, female 15, age 2-83 years, average 58, median 61) most with cancer (prostate 8, endometrial 5, bladder 4, colorectal 4, breast 2, gastric 2, neuroblastoma 2, cervical 1, ovarian 1, renal 1, sarcoma 1, urothelial 1 and testicular 1) and one with Crohn's disease. Medical records were reviewed to assess outcomes of capping trial. Exact 95% confidence intervals were calculated.

Research results

In 81% of study group (95% confidence intervals: 0.65-0.92) NUTs were successfully capped (range 12-94 d, average 40, median 24.5) until planned conversion to internal stent (23), routine exchange (5), removal (1) or death unrelated to catheter (1).

Research conclusions

The ability to aspirate retained contrast from bladder through NUT is an indicator for successful capping trial. If contrast cannot be aspirated from bladder through NUT, same session tube exchange (upsized or different length) should be considered.

Research perspectives

Prospective studies are required to further assess the findings of this study.

REFERENCES

- 1 **Ganatra AM**, Loughlin KR. The management of malignant ureteral obstruction treated with ureteral stents. *J Urol* 2005; **174**: 2125-2128 [PMID: 16280741 DOI: 10.1097/01.ju.0000181807.56114.b7]
- 2 **Ku JH**, Lee SW, Jeon HG, Kim HH, Oh SJ. Percutaneous nephrostomy versus indwelling ureteral stents in the management of extrinsic ureteral obstruction in advanced malignancies: are there differences? *Urology* 2004; **64**: 895-899 [PMID: 15533473 DOI: 10.1016/j.urology.2004.06.029]
- 3 **Alawneh A**, Tuqan W, Innabi A, Al-Nimer Y, Azzouqah O, Rimawi D, Taqash A, Elkhatib M, Klepstad P. Clinical Factors Associated With a Short Survival Time After Percutaneous Nephrostomy for Ureteric Obstruction in Cancer Patients: An Updated Model. *J Pain Symptom Manage* 2016; **51**: 255-261 [PMID: 26497918 DOI: 10.1016/j.jpainsymman.2015.09.009]
- 4 **Yossepowitch O**, Lifshitz DA, Dekel Y, Gross M, Keidar DM, Neuman M, Livne PM, Baniel J. Predicting the success of retrograde stenting for managing ureteral obstruction. *J Urol* 2001; **166**: 1746-1749 [PMID: 11511111 DOI: 10.1097/01.ju.0000018180.75611.b7]

- 11586215 DOI: [10.1016/S0022-5347\(05\)65666-2](https://doi.org/10.1016/S0022-5347(05)65666-2)]
- 5 **Matsuura H**, Arase S, Hori Y. Ureteral stents for malignant extrinsic ureteral obstruction: outcomes and factors predicting stent failure. *Int J Clin Oncol* 2019; **24**: 306-312 [PMID: [30298199](https://pubmed.ncbi.nlm.nih.gov/30298199/) DOI: [10.1007/s10147-018-1348-6](https://doi.org/10.1007/s10147-018-1348-6)]
 - 6 **Wang JY**, Zhang HL, Zhu Y, Qin XJ, Dai BO, Ye DW. Predicting the failure of retrograde ureteral stent insertion for managing malignant ureteral obstruction in outpatients. *Oncol Lett* 2016; **11**: 879-883 [PMID: [26870299](https://pubmed.ncbi.nlm.nih.gov/26870299/) DOI: [10.3892/ol.2015.3961](https://doi.org/10.3892/ol.2015.3961)]
 - 7 **Fiuk J**, Bao Y, Calleary JG, Schwartz BF, Denstedt JD. The use of internal stents in chronic ureteral obstruction. *J Urol* 2015; **193**: 1092-1100 [PMID: [25463984](https://pubmed.ncbi.nlm.nih.gov/25463984/) DOI: [10.1016/j.juro.2014.10.123](https://doi.org/10.1016/j.juro.2014.10.123)]



Published by **Baishideng Publishing Group Inc**
7041 Koll Center Parkway, Suite 160, Pleasanton, CA 94566, USA

Telephone: +1-925-3991568

E-mail: bpgoffice@wjgnet.com

Help Desk: <https://www.f6publishing.com/helpdesk>

<https://www.wjgnet.com>

