

# World Journal of *Surgical Procedures*

*World J Surg Proced* 2022 July 15; 12(1): 1-12



**ORIGINAL ARTICLE****Observational Study**

- 1 Freehand-robot-assisted laparoscopic colorectal surgery: Initial experience in the Trinidad and Tobago  
*Cawich SO, Singh Y, Naraynsingh V, Senasi R, Arulampalam T*

**CASE REPORT**

- 8 Rare case of perforated giant gastric ulcer with concurrent thyroid storm: A case report  
*Wang JX, Soh LS, Mahendran DCJ, Woon CY, Chia CLK*

**ABOUT COVER**

Editorial Board Member of *World Journal of Surgical Procedures*, Meer M Chisthi, MS, PhD, Professor, Department of General Surgery, Government Medical College, Trivandrum, Kerala 695011, India.  
meerchisthi.m@tmc.kerala.gov.in

**AIMS AND SCOPE**

The primary aim of *World Journal of Surgical Procedures* (WJSP, *World J Surg Proced*) is to provide scholars and readers from various fields of surgical procedures with a platform to publish high-quality basic and clinical research articles and communicate their research findings online.

WJSP mainly publishes articles reporting research results and findings obtained in the field of surgical procedures and covering a wide range of topics including ablation techniques, ambulatory surgical procedures, surgical anastomosis, assisted circulation, bariatric surgery, biopsy, bloodless medical and surgical procedures, non-therapeutic body modification, cardiovascular surgical procedures, curettage, debridement, surgical decompression, deep brain stimulation, device removal, digestive system surgical procedures, dissection, etc.

**INDEXING/ABSTRACTING**

The WJSP is now abstracted and indexed in Reference Citation Analysis, China National Knowledge Infrastructure, China Science and Technology Journal Database, and Superstar Journals Database.

**RESPONSIBLE EDITORS FOR THIS ISSUE**

Production Editor: *Yu-Xi Chen*; Production Department Director: *Xu Guo*; Editorial Office Director: *Yun-Xiaoqiao Wu*.

**NAME OF JOURNAL**

*World Journal of Surgical Procedures*

**ISSN**

ISSN 2219-2832 (online)

**LAUNCH DATE**

December 29, 2011

**FREQUENCY**

Continuous Publication

**EDITORS-IN-CHIEF**

Dinesh Vyas, Pankaj Kumar Garg

**EDITORIAL BOARD MEMBERS**

<https://www.wjgnet.com/2219-2832/editorialboard.htm>

**PUBLICATION DATE**

July 15, 2022

**COPYRIGHT**

© 2022 Baishideng Publishing Group Inc

**INSTRUCTIONS TO AUTHORS**

<https://www.wjgnet.com/bpg/gerinfo/204>

**GUIDELINES FOR ETHICS DOCUMENTS**

<https://www.wjgnet.com/bpg/gerinfo/287>

**GUIDELINES FOR NON-NATIVE SPEAKERS OF ENGLISH**

<https://www.wjgnet.com/bpg/gerinfo/240>

**PUBLICATION ETHICS**

<https://www.wjgnet.com/bpg/gerinfo/288>

**PUBLICATION MISCONDUCT**

<https://www.wjgnet.com/bpg/gerinfo/208>

**ARTICLE PROCESSING CHARGE**

<https://www.wjgnet.com/bpg/gerinfo/242>

**STEPS FOR SUBMITTING MANUSCRIPTS**

<https://www.wjgnet.com/bpg/gerinfo/239>

**ONLINE SUBMISSION**

<https://www.f6publishing.com>

## Observational Study

## Freehand-robot-assisted laparoscopic colorectal surgery: Initial experience in the Trinidad and Tobago

Shamir O Cawich, Yardesh Singh, Vijay Naraynsingh, Ramdas Senasi, Tan Arulampalam

## Specialty type: Surgery

## Provenance and peer review:

Unsolicited article; Externally peer reviewed.

## Peer-review model: Single blind

## Peer-review report's scientific quality classification

Grade A (Excellent): 0

Grade B (Very good): 0

Grade C (Good): C, C

Grade D (Fair): 0

Grade E (Poor): 0

P-Reviewer: Badessi G, Italy; Lei Y, China

A-Editor: Zhu JQ, China

Received: January 30, 2022

Peer-review started: January 30, 2022

First decision: March 25, 2022

Revised: May 11, 2022

Accepted: June 16, 2022

Article in press: June 16, 2022

Published online: July 15, 2022



Shamir O Cawich, Vijay Naraynsingh, Department of Surgery, University of the West Indies, St Augustine, Trinidad and Tobago

Yardesh Singh, Department of Clinical Surgical Sciences, University of the West Indies, St. Augustine, Trinidad and Tobago

Ramdas Senasi, Department of Surgery, South Tyneside and Sunderland NHS Trust, South Shields NE34 0PL, United Kingdom

Tan Arulampalam, Department of General Surgery, Colchester Hospital University National Health Services Foundation Trust, Colchester, Essex, England, Colchester CO4 5JL, United Kingdom

Corresponding author: Shamir O Cawich, FRCS, Full Professor, Department of Surgery, University of the West Indies, St. Augustine Campus St. Augustine, St Augustine, Trinidad and Tobago. [socawich@hotmail.com](mailto:socawich@hotmail.com)

## Abstract

## BACKGROUND

Laparoscopic colorectal surgery is still developing in the Anglophone Caribbean, having been first performed in the region in the year 2011. We report the initial outcomes using a robot camera holder to assist in laparoscopic colorectal operations.

## AIM

To report our initial experience using the FreeHand® robotic camera holder (Freehand 2010 Ltd., Guildford, Surrey, United Kingdom) for laparoscopic colorectal surgery in Trinidad & Tobago.

## METHODS

We retrospectively collected data from all patients who underwent laparoscopic colorectal resections using the Freehand® (Freehand 2010 Ltd., Guildford, Surrey, United Kingdom) robotic camera holder between September 30, 2021 and April 30, 2022. The following data were recorded: patient demographics, robotic arm setup time, operating time, conversions to open surgery, conversions to a human camera operator, number and duration of intra-operative lens cleaning. At the termination of the operation, before operating notes were completed, the surgeons were administered a questionnaire recording information on ergonomics, user-

difficulty, requirement to convert to a human camera operator and their ability to carry out effective movements to control the robot while operating.

## RESULTS

Nine patients at a mean age of  $58.9 \pm 7.1$  years underwent colorectal operations using the FreeHand robot: Right hemicolectomies (5), left hemicolectomy (1), sigmoid colectomies (2) and anterior resection (1). The mean robot docking time was 6.33 minutes (Median 6; Range 4-10; SD  $\pm 1.8$ ). The mean duration of operation was  $122.33 \pm 78.5$  min and estimated blood loss was  $113.33 \pm 151.08$  mL. There were no conversions to a human camera holder. The laparoscope was detached from the robot for lens cleaning/defogging an average of  $2.6 \pm 0.88$  times per case, with cumulative mean interruption time of  $4.2 \pm 2.15$  minutes per case. The mean duration of hospitalization was  $3.2 \pm 1.30$  days and there were no complications recorded. When the surgeons were interviewed after operation, the surgeons reported that there were good ergonomics (100%), with no limitation on instrument movement (100%), stable image (100%) and better control of surgical field (100%).

## CONCLUSION

Robot-assisted laparoscopic colorectal surgery is feasible and safe in the resource-poor Caribbean setting, once there is appropriate training.

**Key Words:** Laparoscopic; Robotic; Minimally invasive; Colorectal

©The Author(s) 2022. Published by Baishideng Publishing Group Inc. All rights reserved.

**Core Tip:** This study demonstrates that robot-assisted laparoscopic colorectal surgery is feasible in the resource poor Caribbean setting, but requires appropriate user training to ensure safe introduction of the technology.

**Citation:** Cawich SO, Singh Y, Naraynsingh V, Senasi R, Arulampalam T. Freehand-robot-assisted laparoscopic colorectal surgery: Initial experience in the Trinidad and Tobago. *World J Surg Proced* 2022; 12(1): 1-7

**URL:** <https://www.wjgnet.com/2219-2832/full/v12/i1/1.htm>

**DOI:** <https://dx.doi.org/10.5412/wjsp.v12.i1.1>

## INTRODUCTION

Cooperman *et al*[1] were first to report laparoscopic colectomy for neoplastic disease in 1991. After this success, multiple reports of laparoscopic colectomies appeared in the surgical literature and the technique became widely accepted as the preferred approach for colorectal resections[2-9]. The benefits of laparoscopic colectomy are supported by level I data from the Barcelona trial[2], Clinical Outcomes of Surgical Therapy trial[3], Colon Cancer Laparoscopic or Open Resection trial[4] and the Conventional *vs* Laparoscopic assisted Surgery in Patients with Colorectal Cancer (MRC CLASICC) trial[5]. These trials and subsequent meta-analyses demonstrated laparoscopic colectomy's superiority over open colectomy in post-operative pain, return of bowel function and hospitalization[2-9].

In the Anglophone Caribbean, Plummer *et al*[10] first reported a series of laparoscopic colectomies in the year 2011, approximately 20 years after the first report by Cooperman *et al*[1]. We report our initial experience using the FreeHand® robotic camera holder (Freehand 2010 Ltd., Guildford, Surrey, United Kingdom) for laparoscopic colorectal surgery in Trinidad & Tobago.

## MATERIALS AND METHODS

In this study we retrospectively collected data from hospital records of all patients who underwent laparoscopic colorectal resections using the Freehand® (Freehand 2010 Ltd., Guildford, Surrey, United Kingdom) robotic camera holder over a four-month period from September 30, 2021 to April 30, 2022. We excluded patients who were below 18 years of age, who underwent emergency operations, who had colectomies associated with other major procedures performed at the same sitting and those who did not consent to data collection.

For all patients who underwent colectomies, we recorded the following data: patient demographics, robotic arm setup time (time for draping, lens fixation and positioning), operating time, conversions to

open surgery, conversions to a human camera operator, number and duration of intra-operative lens cleaning. All data were entered into an excel database and the data were analyzed using Statistical Product and Service Solutions version 20.0.

In this series, the decision on operating room setup was taken at the pre-operative time out. In all cases, a 12 mmHg pneumoperitoneum was created using Hasson's technique *via* a port placed at the umbilicus. For a right hemicolectomy, the patient was placed supine and the left hand was tucked in. The laparoscopic monitors were placed on the right side of the patient and the Freehand robot was fixated to the right-side bed rail (Figure 1A). For a left hemicolectomy, the patient was placed supine and the right hand was tucked in. The laparoscopic monitors were placed on the left side of the patient and the robot was fixated to the left-side bed rail (Figure 1B). For an anterior resection, the patient was placed in reversed trendelenburg position and the both hands were tucked in. The laparoscopic monitors were placed at the patient's feet and the Freehand robot was fixated to the left-side bed rail (Figure 1C). A three-port technique was used in these cases and the 5 mm port sites were chosen by the operating surgeon based on his ergonomics. Once ports were placed, the robot was positioned and the operation commenced.

The operations were performed using the medial-to-lateral approach. The ureters were identified and preserved prior to mesenteric vascular control. Once sufficiently mobilized the colon was transected and an anastomosis completed. The specimen was exteriorized through a site chosen by the surgeon using a wound protector. Following local fast-track protocols, all patients were offered normal diet once awake. Urethral catheters were removed and the patients mobilized on post-operative day 1. The patients were discharged once they remained well and tolerated diet.

At the termination of the operation, before operating notes were completed, the surgeons were administered a questionnaire to solicit their subjective impression of the Freehand system. The questionnaire sought information on ergonomics, user-difficulty, requirement to convert to a human camera operator and their ability to carry out effective movements to control the robot while operating.

## RESULTS

Over the study period, nine patients underwent colorectal operations using the FreeHand robot (Freehand 2010 Ltd., Guildford, Surrey, United Kingdom). There were three females and six males at an average age of 58.9 years (Median 60; Range 49-70; SD  $\pm$  7.1). These patients underwent right hemicolectomies (3), extended right colectomies (2), left hemicolectomy (1), sigmoid colectomies (2) and anterior resection (1). The mean robot docking time was 6.33 min (Median 6; Range 4-10; SD  $\pm$  1.8).

Intra-operatively, there were no conversions recorded and no adverse events encountered. The mean duration of operation was 122.33 min (Median 100; Range 84-330; SD  $\pm$  78.5) and mean estimated blood loss was 113.33 mL (Median 50; Range 10-500; SD  $\pm$  151.08). Specifically related to the intra-operative handling of the robot, there were no instances of conversion to a human camera holder. The laparoscope was detached from the robot for lens cleaning/defogging an average of 2.6 times per case (Median 3; Range 1-4; SD  $\pm$  0.88), with cumulative mean interruption time of 4.2 min per case (Median 4; Range 1-8; SD  $\pm$  2.15).

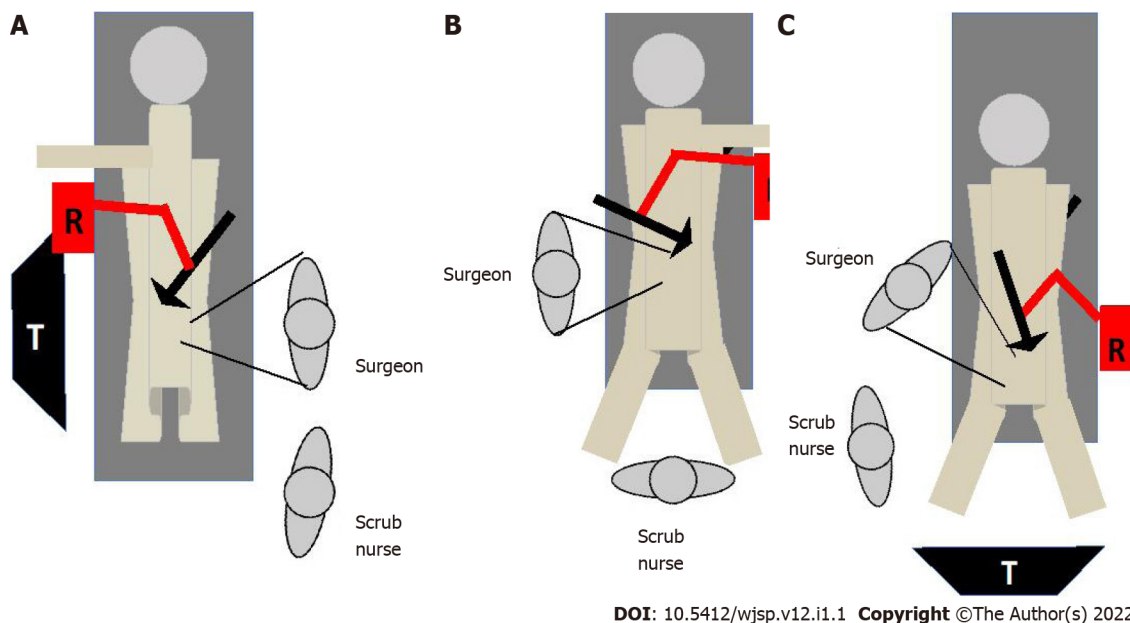
Post-operation, there were no complications or deaths. The mean duration of hospitalization was 3.2 d (Median 3; Range 2-6; SD  $\pm$  1.30). Histologic assessment revealed adequate oncologic targets: 19.8 cm mean proximal margin distance (median 20, range 12-35, SD  $\pm$  7.19), 17.22 cm mean distal margin distance (median 18, range 10-20, SD  $\pm$  3.42), and 13 mean node harvest (median 12, range 10-18, SD  $\pm$  2.55). All patients were alive and disease free after a mean follow-up of 5.1 mo. However, this duration of follow-up was not sufficient to meaningfully assess overall survival or disease-free survival. Three advanced laparoscopic surgeons performed these operations. When the surgeons were interviewed after operation, the surgeons reported that there were good ergonomics (100%), with no limitation on instrument movement (100%), stable image (100%) and better control of surgical field (100%).

## DISCUSSION

Generally, the Anglophone Caribbean lagged behind the developed world in terms of adopting advanced operative techniques due to a combination of resource unavailability, financial limitations and leadership deficiencies[11]. To illustrate this, consider the fact that the initial report on laparoscopic colectomies from the Caribbean[10] came 20 years after it was first reported by Cooperman *et al*[1].

Similarly, the first report of robotic colectomy was published by Weber *et al*[12] in March, 2001. They reported two cases in which they used the DaVinci robotic platform (Intuitive Surgical Inc, Sunnyvale, California, United States) to perform a sigmoid colectomy for diverticulitis and a right hemicolectomy for diverticulitis. In the next few years, several reports of robotic colectomies began to appear in the surgical literature for benign and malignant disease[13,14]. However, robotic surgery remained dormant in the Anglophone Caribbean[15]. To the best of our knowledge, there has been no report of colorectal resections using the DaVinci or any other full robotic platform from the Caribbean. The first step toward





**Figure 1** Operating room setup using the FreeHand (R) surgical robot. A: The operating room is setup for a right hemicolectomy, with the patient supine and the left hand tucked in. The laparoscopic stack (T) and the robot (R) are placed at the right side of the bed, while the surgeon and scrub nurse stand at the patient's left side; B: The operating room is setup for a left colectomy, with the right hand tucked in and the robot (R) and laparoscopic stack (T) at the patient's left; C: For an anterior resection, the patient is in a reversed trendelenburg position with both hands tucked in. The robot (R) is fixated to the left bed rail and the stack at the patient's feet.

robotics in the Caribbean was a FreeHand robot-assisted laparoscopic right hemicolectomy performed on November 29, 2021. To illustrate our point once more, this was two decades after robotic hemicolectomy was first described by Weber *et al*[12].

In the report by Weber *et al*[12] the DaVinci robot (Intuitive Surgical Inc, Sunnyvale, California, United States) was utilized. However, there are no da Vinci platforms in any nation in the Anglophone Caribbean. It is a resource-poor region with some of the poorest nations in the Western hemisphere. The cases in this report were performed by advanced laparoscopic surgeons with the assistance of the FreeHand robot (Freehand 2010 Ltd., Guildford, Surrey, United Kingdom). This was a single robotic arm that controlled the laparoscope and was under the direct control of the surgeon *via* an infrared communicator. The resource poor nations in the Caribbean could not afford more advanced robotic platforms that are available on the commercial market, but we found this system to be a good intermediary that brought advantages over conventional laparoscopy while balancing cost.

In our small series, these operations were performed by advanced laparoscopic surgeons who were already facile with laparoscopic colectomies. Therefore, it was not surprising that the mean operating time was comparable to those in published reports on laparoscopic colectomies from the Caribbean[10, 11,16] that ranged from 150 min[10] to 175 min[16], as well as reports from international literature[17-20]. Similarly, our other outcomes were comparable to those in reports on laparoscopic colectomies from the region, where the median length of hospitalization ranged from 4[11] to 5[10] days, overall morbidity from 10%[10] to 35.3%[16] and no reported mortality[10,11,16].

Ballantyne *et al*[21] wrote during their early experience with robotic colectomies in 2001 that the DaVinci system overcame the pitfalls of conventional laparoscopy that included: an unstable video camera platform, limited motion (degrees of freedom) of straight laparoscopic instruments, two-dimensional imaging and poor surgeon ergonomics. Ballantyne *et al*[21] also wrote that “*inexperienced or bored camera-holders move the camera frequently and rotate it away from the horizon.*” We agree with Ballantyne *et al*[21] and we found that the surgeon being in full control of the visual field was a distinct advantage of the FreeHand robot. The operators also unanimously found the stability of the vision advantageous. In our cases, the robot was assigned a conventional 30-degree laparoscope with a single lens. Therefore, unlike the advanced multi-lens cameras in advanced robotic systems that allow depth perception, the FreeHand robot could not overcome the two-dimensional views that is a recognized limitation of conventional laparoscopy.

Surgeon ergonomics has been one criticism of the FreeHand platform. More sophisticated robotic systems such as the DaVinci platform would allow intra-corporeal articulation with specialized instruments, but the Freehand robot had only one arm to operate the camera. Therefore, conventional laparoscopic instruments had to be used in these cases. The straight, long instruments would still be limited in their motion by the fixation enforced by the abdominal wall trocars[21]. Providing more degrees of freedom of movement would require a more sophisticated robot with additional operating arms, but the point was already made that these come at a significant increase in cost. On the other

hand, all surgeons in our series unanimously reported that the robotic arm was not intrusive and did not negatively impact surgeon ergonomics, although it did not improve ergonomics either.

We have shown that the use of the FreeHand robot for laparoscopic colorectal resections is feasible, provides some advantages over conventional laparoscopy and has similar short-term outcomes to conventional laparoscopy. From this study, we cannot comment on the long-term outcomes, although we expect it to be similar conventional laparoscopy. It has already been proven and accepted from randomized controlled trials[2-7] and large metanalyses[7,8,22] that conventional laparoscopic colorectal resections have equivalent oncologic outcomes to open surgery.

## LIMITATIONS

We acknowledge that these colorectal operations were performed by experienced surgeons who were already facile with laparoscopic colectomies and beyond the learning curves. Therefore, this does introduce some bias in outcomes, but it was equally important to show that this technique was feasible in this setting.

We also acknowledge that the sample size is small. This is a low resource nation with a population of 1.3 million persons so few persons qualified for use of the robotic arm during the study period.

## CONCLUSION

We have shown that robot assisted colorectal surgery is feasible and safe in the resource-poor Caribbean setting.

## ARTICLE HIGHLIGHTS

### **Research background**

Laparoscopic colorectal surgery is still developing in the Anglophone Caribbean and there has been no report of robot assisted colorectal surgery in the region. This paper reports our initial experience with advanced colorectal surgery using the Freehand robot.

### **Research motivation**

Robot-assisted colorectal surgery using the FreeHand® robotic camera holder (Freehand 2010 Ltd., Guildford, Surrey, United Kingdom) was introduced to the Caribbean in 2021. We report our initial experience with this technology.

### **Research objectives**

This paper reports the initial experience with the FreeHand(R) robotic camera holder to complete colorectal operations in a resource-poor setting.

### **Research methods**

A retrospective study was performed, collecting data from all consecutive patients who underwent colorectal operations using the FreeHand robot from September 2020 to April 2022. The data collected included: demographics, docking time, operating time, conversions, number and duration of intra-operative lens cleaning. All operating surgeons completed a survey that sought information on robot use.

### **Research results**

There were 9 patients in this study who underwent: Right hemicolectomies (5), left hemicolectomy (1), sigmoid colectomies (2) and anterior resection (1). These operations were completed with a mean robot docking time of 6.33 min, mean duration of surgery of 122.33 min and mean estimated blood loss of 113.33 mL. The laparoscope was detached from the robot an average of 2.6 times per case, with cumulative mean interruption time of 4.2 min per case. The mean duration of hospitalization was 3.2 d and there were no complications recorded. Surgeons reported that there were good ergonomics, with no limitation on instrument movement, stable image and better control of surgical field.

### **Research conclusions**

Robot-assisted laparoscopic colorectal surgery is feasible and safe in the resource-poor Caribbean setting, once there is appropriate training.



### Research perspectives

Future research should incorporate large numbers of patients and a comparison of outcomes between robot-assisted and laparoscopic cases.

## FOOTNOTES

**Author contributions:** Cawich SO wrote the paper and reviewed the paper for scientific accuracy; Naraynsingh V and Singh Y collected data and reviewed the manuscript for accuracy; Sensai R and Arulampalam T analyzed data and reviewed the manuscript for scientific accuracy.

**Institutional review board statement:** The study was reviewed and approved by the University of the West Indies' Institutional Review Board [(Approval No. CREC-SA.1615/06/2022)].

**Informed consent statement:** This was an observational study of anonymized patient records. Consequently, the Institutional Review Board reviewed the protocols and exempted the participants from individual consent.

**Conflict-of-interest statement:** There are no conflicts of interest declared by any of the authors.

**Data sharing statement:** Data are available from the corresponding author upon request.

**CONSORT 2010 statement:** The authors have read the CONSORT 2010 statement, and the manuscript was prepared and revised according to the CONSORT 2010 statement.

**Open-Access:** This article is an open-access article that was selected by an in-house editor and fully peer-reviewed by external reviewers. It is distributed in accordance with the Creative Commons Attribution NonCommercial (CC BY-NC 4.0) license, which permits others to distribute, remix, adapt, build upon this work non-commercially, and license their derivative works on different terms, provided the original work is properly cited and the use is non-commercial. See: <https://creativecommons.org/licenses/by-nc/4.0/>

**Country/Territory of origin:** Trinidad and Tobago

**ORCID number:** Shamir O Cawich 0000-0003-3377-0303; Yardesh Singh 0000-0001-6058-6267; Vijay Naraynsingh 0000-0002-5445-3385; Ramdas Senasi 0000-0001-9894-877X; Tan Arulampalam 0000-0002-1784-7713.

**S-Editor:** Liu JH

**L-Editor:** A

**P-Editor:** Liu JH

## REFERENCES

- Cooperman AM, Katz V, Zimmon D, Botero G. Laparoscopic colon resection: a case report. *J Laparoendosc Surg* 1991; **1**: 221-224 [PMID: 1834273 DOI: 10.1089/Lps.1991.1.221]
- Lacy AM, Garcia-Valdecasas JC, Delgado S. Laparoscopic-assisted colectomy vs open colectomy for treatment of non-metastatic colon cancer: a randomised trial. *Lancet* 2002; **359**: 2224e9 [DOI: 10.1016/S0140-6736(02)09290-5]
- Clinical Outcomes of Surgical Therapy Study Group, Nelson H, Sargent DJ, Wieand HS, Fleshman J, Anvari M, Stryker SJ, Beart RW Jr, Hellinger M, Flanagan R Jr, Peters W, Ota D. A comparison of laparoscopically assisted and open colectomy for colon cancer. *N Engl J Med* 2004; **350**: 2050-2059 [PMID: 15141043 DOI: 10.1056/NEJMoa032651]
- Veldkamp R, Kuhry E, Hop WC, Jeekel J, Kazemier G, Bonjer HJ, Haglind E, Pahlman L, Cuesta MA, Msika S, Morino M, Lacy AM; Colon cancer Laparoscopic or Open Resection Study Group (COLOR). Laparoscopic surgery versus open surgery for colon cancer: short-term outcomes of a randomised trial. *Lancet Oncol* 2005; **6**: 477-484 [PMID: 15992696 DOI: 10.1016/S1470-2045(05)70221-7]
- Guillou PJ, Quirke P, Thorpe H, Walker J, Jayne DG, Smith AM, Heath RM, Brown JM; MRC CLASICC trial group. Short-term endpoints of conventional versus laparoscopic-assisted surgery in patients with colorectal cancer (MRC CLASICC trial): multicentre, randomised controlled trial. *Lancet* 2005; **365**: 1718-1726 [PMID: 15894098 DOI: 10.1016/S0140-6736(05)66545-2]
- Weeks JC, Nelson H, Gelber S, Sargent D, Schroeder G; Clinical Outcomes of Surgical Therapy (COST) Study Group. Short-term quality-of-life outcomes following laparoscopic-assisted colectomy vs open colectomy for colon cancer: a randomized trial. *JAMA* 2002; **287**: 321-328 [PMID: 11790211 DOI: 10.1001/jama.287.3.321]
- Janson M, Lindholm E, Anderberg B, Haglind E. Randomized trial of health-related quality of life after open and laparoscopic surgery for colon cancer. *Surg Endosc* 2007; **21**: 747-753 [PMID: 17342556 DOI: 10.1007/s00464-007-9217-9]
- Jackson TD, Kaplan GG, Arena G, Page JH, Rogers SO Jr. Laparoscopic versus open resection for colorectal cancer: a metaanalysis of oncologic outcomes. *J Am Coll Surg* 2007; **204**: 439-446 [PMID: 17324779 DOI: 10.1016/j.jamcollsurg.2006.12.008]

- 9 **Jayne DG**, Guillou PJ, Thorpe H, Quirke P, Copeland J, Smith AM, Heath RM, Brown JM; UK MRC CLASICC Trial Group. Randomized trial of laparoscopic-assisted resection of colorectal carcinoma: 3-year results of the UK MRC CLASICC Trial Group. *J Clin Oncol* 2007; **25**: 3061-3068 [PMID: [17634484](#) DOI: [10.1200/JCO.2006.09.7758](#)]
- 10 **Plummer JM**, Mitchell DI, Arthurs M, Leake PA, Deans-Minott J, Cawich SO, Martin A. Laparoscopic colectomy for colonic neoplasms in a developing country. *Int J Surg* 2011; **9**: 382-385 [PMID: [21419240](#) DOI: [10.1016/j.ijsu.2011.03.002](#)]
- 11 **Cawich SO**, Pooran S, Amow B, Ali E, Mohammed F, Mencia M, Ramsewak S, Hariharan S, Naraynsingh V. Impact of a medical university on laparoscopic surgery in a service-oriented public hospital in the Caribbean. *Risk Manag Healthc Policy* 2016; **9**: 253-260 [PMID: [27895521](#) DOI: [10.2147/RMHP.S89724](#)]
- 12 **Weber PA**, Merola S, Wasielewski A, Ballantyne GH. Telerobotic-assisted laparoscopic right and sigmoid colectomies for benign disease. *Dis Colon Rectum* 2002; **45**: 1689-94; discussion 1695 [PMID: [12473897](#) DOI: [10.1007/s10350-004-7261-2](#)]
- 13 **D'Annibale A**, Morpurgo E, Fiscon V, Trevisan P, Sovernigo G, Orsini C, Guidolin D. Robotic and laparoscopic surgery for treatment of colorectal diseases. *Dis Colon Rectum* 2004; **47**: 2162-2168 [PMID: [15657669](#) DOI: [10.1007/s10350-004-0711-z](#)]
- 14 **Braumann C**, Jacobi CA, Menenakos C, Borchert U, Rueckert JC, Mueller JM. Computer-assisted laparoscopic colon resection with the Da Vinci system: our first experiences. *Dis Colon Rectum* 2005; **48**: 1820-1827 [PMID: [16142433](#) DOI: [10.1007/s10350-005-0121-x](#)]
- 15 **Cawich SO**, Arulampalam T, Senasi R, Naraynsingh V. Robot-Assisted Minimally Invasive Surgery: First Report from the Caribbean. *Cureus* 2021; **13**: e18739 [PMID: [34790488](#) DOI: [10.7759/cureus.18739](#)]
- 16 **Leake PA**, Pitzul K, Roberts PO, Plummer JM. Comparative analysis of open and laparoscopic colectomy for malignancy in a developing country. *World J Gastrointest Surg* 2013; **5**: 294-299 [PMID: [24520427](#) DOI: [10.4240/wjgs.v5.i11.294](#)]
- 17 **Trastulli S**, Coratti A, Guarino S, Piagnerelli R, Annecchiarico M, Coratti F, Di Marino M, Ricci F, Desiderio J, Ciocchi R, Parisi A. Robotic right colectomy with intracorporeal anastomosis compared with laparoscopic right colectomy with extracorporeal and intracorporeal anastomosis: a retrospective multicentre study. *Surg Endosc* 2015; **29**: 1512-1521 [PMID: [25303905](#) DOI: [10.1007/s00464-014-3835-9](#)]
- 18 **Morpurgo E**, Contardo T, Molano R, Zerbinati A, Orsini C, D'Annibale A. Robotic-assisted intracorporeal anastomosis versus extracorporeal anastomosis in laparoscopic right hemicolectomy for cancer: a case control study. *J Laparoendosc Adv Surg Tech A* 2013; **23**: 414-417 [PMID: [23627922](#) DOI: [10.1089/lap.2012.0404](#)]
- 19 **Petruciani N**, Sirimarco D, Nigri GR, Magistri P, La Torre M, Aurello P, D'Angelo F, Ramacciato G. Robotic right colectomy: A worthwhile procedure? *J Minim Access Surg* 2015; **11**: 22-28 [PMID: [25598595](#) DOI: [10.4103/0972-9941.147678](#)]
- 20 **Lujan HJ**, Plasencia G, Rivera BX, Molano A, Fagenson A, Jane LA, Holguin D. Advantages of Robotic Right Colectomy With Intracorporeal Anastomosis. *Surg Laparosc Endosc Percutan Tech* 2018; **28**: 36-41 [PMID: [28319493](#) DOI: [10.1097/SLE.0000000000000384](#)]
- 21 **Ballantyne GH**, Merola P, Weber A, Wasielewski A. Robotic solutions to the pitfalls of laparoscopic colectomy. *Osp Ital Chir* 2001; **7**: 405-412 [DOI: [10.1097/00129689-200202000-00008](#)]
- 22 **Bonjer HJ**, Hop WC, Nelson H, Sargent DJ, Lacy AM, Castells A, Guillou PJ, Thorpe H, Brown J, Delgado S, Kuhrij E, Haglind E, Pahlman L; Transatlantic Laparoscopically Assisted vs Open Colectomy Trials Study Group. Laparoscopically assisted vs open colectomy for colon cancer: a meta-analysis. *Arch Surg* 2007; **142**: 298-303 [PMID: [17372057](#) DOI: [10.1001/archsurg.142.3.298](#)]



Published by **Baishideng Publishing Group Inc**  
7041 Koll Center Parkway, Suite 160, Pleasanton, CA 94566, USA

**Telephone:** +1-925-3991568

**E-mail:** [bpgoffice@wjgnet.com](mailto:bpgoffice@wjgnet.com)

**Help Desk:** <https://www.f6publishing.com/helpdesk>

<https://www.wjgnet.com>

