

World Journal of *Critical Care Medicine*

World J Crit Care Med 2020 August 7; 9(3): 43-62



ORIGINAL ARTICLE**Retrospective Study**

- 43 Ventilator-associated pneumonia in patients with cancer: Impact of multidrug resistant bacteria
Cornejo-Juárez P, González-Oros I, Mota-Castañeda P, Vilar-Compte D, Volkow-Fernández P

CASE REPORT

- 54 Lessons from a methanol poisoning outbreak in Egypt: Six case reports
Gouda AS, Khattab AM, Mégarbane B

ABOUT COVER

Editorial board member of *World Journal of Critical Care Medicine*, Dr. Cascella works in the Department of Anesthesia Pain Medicine and Supportive Care at the National Cancer Institute, Fondazione "G. Pascale" – IRCCS in Naples, Italy. He is also Professor of Physiology in the Degree Course of Biomedical Laboratory Techniques at the Faculty of Medicine, University "Federico II", Naples, Italy. After Dr. Cascella graduated in Medicine and Surgery with honors from the University "Vanvitelli" of Naples in 1997, he undertook postgraduate studies in anesthesia and intensive care, obtaining his doctorate in 2001. He acts as research editor for the Italian Ministry of Health and is an editorial board member of several medical journals. He has been a speaker at numerous conferences and conventions and is the author of about 200 scientific publications, books, book chapters, etc. in the fields of anesthesia, pathophysiology, treatment of pain, oncology, and palliative care. (L-Editor: Filipodia)

AIMS AND SCOPE

The primary aim of the *World Journal of Critical Care Medicine* (*WJCCM*, *World J Crit Care Med*) is to provide scholars and readers from various fields of critical care medicine with a platform to publish high-quality basic and clinical research articles and communicate their research findings online.

WJCCM mainly publishes articles reporting research results and findings obtained in the field of critical care medicine and covering a wide range of topics including acute kidney failure, acute respiratory distress syndrome and mechanical ventilation, application of bronchofiberscopy in critically ill patients, cardiopulmonary cerebral resuscitation, coagulant dysfunction, continuous renal replacement therapy, fluid resuscitation and tissue perfusion, hemodynamic monitoring and circulatory support, ICU management and treatment control, sedation and analgesia, severe infection, etc.

INDEXING/ABSTRACTING

The *WJCCM* is now indexed in PubMed, PubMed Central, China National Knowledge Infrastructure (CNKI), China Science and Technology Journal Database (CSTJ), and Superstar Journals Database.

RESPONSIBLE EDITORS FOR THIS ISSUE

Electronic Editor: Jia-Hui Li; Production Department Director: Xiang Li; Editorial Office Director: Jia-Ping Yan.

NAME OF JOURNAL

World Journal of Critical Care Medicine

ISSN

ISSN 2220-3141 (online)

LAUNCH DATE

February 4, 2012

FREQUENCY

Irregular

EDITORS-IN-CHIEF

KLE Hon

EDITORIAL BOARD MEMBERS

<https://www.wjnet.com/2220-3141/editorialboard.htm>

PUBLICATION DATE

August 7, 2020

COPYRIGHT

© 2020 Baishideng Publishing Group Inc

INSTRUCTIONS TO AUTHORS

<https://www.wjnet.com/bpg/gerinfo/204>

GUIDELINES FOR ETHICS DOCUMENTS

<https://www.wjnet.com/bpg/GerInfo/287>

GUIDELINES FOR NON-NATIVE SPEAKERS OF ENGLISH

<https://www.wjnet.com/bpg/gerinfo/240>

PUBLICATION ETHICS

<https://www.wjnet.com/bpg/GerInfo/288>

PUBLICATION MISCONDUCT

<https://www.wjnet.com/bpg/gerinfo/208>

ARTICLE PROCESSING CHARGE

<https://www.wjnet.com/bpg/gerinfo/242>

STEPS FOR SUBMITTING MANUSCRIPTS

<https://www.wjnet.com/bpg/GerInfo/239>

ONLINE SUBMISSION

<https://www.f6publishing.com>



Lessons from a methanol poisoning outbreak in Egypt: Six case reports

Ahmed S Gouda, Amr M Khattab, Bruno Mégarbane

ORCID number: Ahmed S Gouda 0000-0003-2470-0792; Amr M Khattab 0000-0001-8560-2745; Bruno Mégarbane 0000-0002-2522-2764.

Author contributions: Gouda AS and Khattab AM managed the patients; Gouda AS and Mégarbane B developed the framework of the paper; Gouda AS wrote the first draft; Mégarbane B worked on subsequent drafts; all authors confirmed the last version before submission, and read and approved the final manuscript.

Informed consent statement: The patients gave their written informed consents.

Conflict-of-interest statement: The authors have no conflicts of interest.

CARE Checklist (2016) statement: The authors have read the CARE Checklist (2016), and the manuscript was prepared and revised according to the CARE Checklist (2016).

Open-Access: This article is an open-access article that was selected by an in-house editor and fully peer-reviewed by external reviewers. It is distributed in accordance with the Creative Commons Attribution NonCommercial (CC BY-NC 4.0) license, which permits others to

Ahmed S Gouda, National Egyptian Center of Environmental and Toxicological Research, Faculty of Medicine, Cairo University, Cairo 11562, Egypt

Amr M Khattab, Department of Forensic Medicine and clinical Toxicology, Faculty of Medicine, Cairo University, Cairo 11562, Egypt

Bruno Mégarbane, Department of Medical and Toxicological Critical Care, Lariboisière Hospital, Paris 75010, France

Corresponding author: Bruno Mégarbane, MD, PhD, Professor, Department of Medical and Toxicological Critical Care, Lariboisière Hospital, 2 Rue Ambroise Paré, Paris 75010, France. bruno.megarbane@lrb.aphp.fr

Abstract

BACKGROUND

Mass methanol poisonings are challenging, especially in regions with no preparedness, management guidelines and available antidotes.

CASE SUMMARY

Six Ukrainian patients were referred to our emergency department in Cairo, Egypt several hours after drinking an alcoholic beverage made of 70%-ethanol disinfectant bought from a local pharmacy. All patients presented with severe metabolic acidosis and visual impairments. Two were comatose. Management was based on the clinical features and chemistry tests due to deficient resources for methanol leveling. No antidote was administered due to fomepizole unavailability and the difficulties expected to obtain ethanol and safely administer it without concentration monitoring. One patient died from multiorgan failure, another developed blindness and the four other patients rapidly improved.

CONCLUSION

This methanol poisoning outbreak strongly highlights the lack of safety from hazardous pharmaceuticals sold in pharmacies and limitations due to the lack of diagnostic testing, antidote availability and staff training in countries with limited-resources such as Egypt.

Key words: Hemodialysis; Limited resources; Methanol; Metabolic acidosis; Outbreak; Poisoning; Case report

distribute, remix, adapt, build upon this work non-commercially, and license their derivative works on different terms, provided the original work is properly cited and the use is non-commercial. See: <http://creativecommons.org/licenses/by-nc/4.0/>

Manuscript source: Invited manuscript

Received: April 6, 2020

Peer-review started: April 6, 2020

First decision: June 8, 2020

Revised: June 8, 2020

Accepted: July 19, 2020

Article in press: July 19, 2020

Published online: August 7, 2020

P-Reviewer: Tabaran F

S-Editor: Ma YJ

L-Editor: Filipodia

E-Editor: Li JH



©The Author(s) 2020. Published by Baishideng Publishing Group Inc. All rights reserved.

Core tip: Mass methanol poisoning with unpredictable risk assessment represents a major threat in developing countries. This work reports a clinical series with patients' features and outcome, describes the investigations to identify rapidly the involved causative agent (here, a homemade beverage made with alcoholic disinfectant) and discusses the observed insufficiencies to improve hospital preparedness in case of methanol poisoning outbreak.

Citation: Gouda AS, Khattab AM, Mégarbane B. Lessons from a methanol poisoning outbreak in Egypt: Six case reports. *World J Crit Care Med* 2020; 9(3): 54-62

URL: <https://www.wjgnet.com/2220-3141/full/v9/i3/54.htm>

DOI: <https://dx.doi.org/10.5492/wjccm.v9.i3.54>

INTRODUCTION

Methanol is included in many home chemicals, fluids, varnishes, stains and dyes. Toxicity results from its metabolism by alcohol dehydrogenase (ADH) to formic acid, which accumulates and results in metabolic acidosis and organ injuries (Figure 1)^[1]. Small ingested amounts as little as 10 mL of pure methanol may be sufficient to cause life-threatening toxicity and permanent blindness^[2].

Acute single-patient methanol poisonings are commonly reported while outbreaks occur sporadically, especially in countries with limited accessibility to ethanol due to unavailability or religious, cultural and economic reasons. Methanol is consumed accidentally as ethanol substitute in underground homemade alcoholic beverages^[3-6]. Methanol poisoning outbreaks have also been reported in occidental countries resulting in hundreds of victims and deaths^[7-10]. In such epidemics, providing effective therapy on time may be challenging, especially if the number of patients exceeds the availability of resources and in the absence of national guidelines to help physicians in charge. As dramatic illustration, a recent methanol poisoning outbreak in the northeast state of Assam in India has killed at least 154 people and left more than 200 people hospitalized after drinking an unregulated moonshine, known locally as "country-made liquor"^[11]. Here, we report the outcome of a collective methanol intoxication that occurred in Cairo, Egypt in 2018 and discuss the different challenging issues from a public health perspective.

CASE PRESENTATION

Five Ukrainian males were referred to our emergency department in Cairo, Egypt on May 28, 2018. The patients were transferred by ambulance and accompanied by an Arabic translator. Two patients were comatose, and three others drowsy with vomiting and headaches. Detailed history was taken from the conscious persons. All five patients were recently assigned to a local multinational factory in a neighboring area and lived there together in the same building. The day before, they tried to buy alcoholic beverages but did not know any local store. So, they prepared and ingested a homemade alcoholic beverage using bottles containing 70% ethanol disinfectant bought from a local pharmacy and fresh orange juice. They drank several glasses of this beverage during the day prior. Another sixth patient drank with them but refused to come to the hospital as he felt well. We requested from the translator to convince him to come as soon as possible. He came on the next day while presenting severe impairment in visual acuity, with perception limited to hand motion for the right eye and light for the left eye. All patients were promptly admitted to the intensive care unit (ICU). Vital signs, physical and biological parameters on admission as well as management and outcome data are presented in Table 1.

FINAL DIAGNOSIS

Based on history and presence of metabolic acidosis and visual impairment in all patients, methanol poisoning was suspected.

Table 1 Clinical, biological, management and outcome data in six methanol-poisoned patients during an outbreak in Egypt

	Patient 1	Patient 2	Patient 3	Patient 4	Patient 5	Patient 6
Clinical parameters on admission						
Age in yr	41	47	41	46	42	42
Glasgow coma score	3	3	15	15	15	15
Respiratory rate as /min	32	30	26	29	23	18
Systolic/diastolic blood pressure in mmHg	80/60	60/40	110/70	110/80	100/80	150/100
Pupils	Dilated	Dilated	Dilated	Dilated	Dilated	Dilated
Repeated seizures	+	+	-	-	-	-
Ophthalmological examination	-	Diminished visual acuity bilaterally with diminished visual field for follow-up	Diminished visual acuity bilaterally for follow-up	Diminished visual acuity bilaterally for follow-up	Diminished visual acuity bilaterally for follow-up	Hand motion by the right eye and light perception by the left eye
Ophthalmoscopy	Bilateral hyperemic swollen optic discs with flame-shaped shadow along superior arcade	Bilateral hyperemic optic discs with pale vassal rim	Bilateral hyperemic optic discs with peripapillary nerve fiber layer edema	Bilateral mild disc pallor and retinal edema	Bilateral pale swollen optic discs with superior and inferior retinal nerve fiber layer swelling	Bilateral disc pallor with normal retina
Biological parameters on admission						
Arterial pH	6.80	6.80	7.18	7.03	7.07	7.36
HCO ₃ ⁻ concentration in mmol/L	4.2	4.5	9.7	8.2	4.3	20.9
PaCO ₂ in mmHg	27	22	26	31	15	37
Serum creatinine in mg/dL	1.1	1.6	4.1	1.0	0.9	1.1
Blood urea nitrogen in mg/dL	26	44	26	26	31	36
AST/ALT	80/60	31/15	36/38	43/57	28/20	28/24
Hemoglobin in g/dL	15.0	15.0	13.2	15.0	15.6	14.0
Platelets in G/L	150	250	226	202	314	150
White blood cells in G/L	8.1	22.7	13.6	8.3	14.3	6.1
Management						
Sodium bicarbonates	+	+	+	+	+	+
Thiamin at 400 mg/d, IV	+	+	+	+	+	+

Leucovorin at 200 mg/d, IV	+	+	+	+	+	+
Methylprednisolone at 400 mg/d, IV	+	+	-	-	+	+
Diazepam at 30 mg/d, IV	+	+	-	-	-	-
Hemodialysis 2-h session	One session	One session / d during 4 d	One session / d during 2 d	One session	One session	One session / d during 2 d
Mechanical ventilation	+	+	-	-	-	-
Vasopressor, norepinephrine	+	-	-	-	-	-
Outcome						
Outcome	Multiorgan failure and death	Disorientation, abnormal behavior, Diminished visual acuity	Full orientation, Pneumonia, Diminished visual acuity	Full orientation, Diminished visual acuity	Full orientation, Diminished visual acuity	Full orientation, Blindness
ICU discharge	Day 1	Day 7	Day 3	Day 3	Day 3	Day 5
Risk score, predicted risk of death ¹	Risk E, 83%	Risk D, 50%	Risk A, 5%	Risk A, 5%	Risk A, 5%	Risk A, 5%

¹Based on the risk assessment chart for the evaluation of outcome using admission parameters including coma onset, arterial pH and PaCO₂, according to Paasma *et al*^[29].

TREATMENT

Due to the lack of readily available antidote and blood ethanol measurement in our laboratory, patients were treated with supportive care, vitamins (thiamin and leucovorin) and intermittent dialysis. Two hemodialysis devices were available in the ICU. Thus, 2-h sessions were successively provided to all patients starting with the most severely injured ones (Patient 1 to 5 then Patient 6 when admitted) and secondarily repeated on a daily basis if required by the metabolic disturbances.

OUTCOME AND FOLLOW-UP

One patient rapidly died from multiorgan failure a few hours after ICU admission. Due to persistent disorientation, brain magnetic resonance imaging was performed in Patient 2 showing bilateral, symmetrical sizable patchy areas of abnormal signals at cerebellar hemispheres and basal ganglia as well as bilateral and mainly subcortical frontal, parietal and occipital regions. Brain injuries elicited faintly bright to intermediate T2 and more bright fluid attenuation inversion recovery signals with restricted diffusion in diffusion-weighted imaging. The five survivors were discharged upon their request when possible to continue treatment and follow-up in their

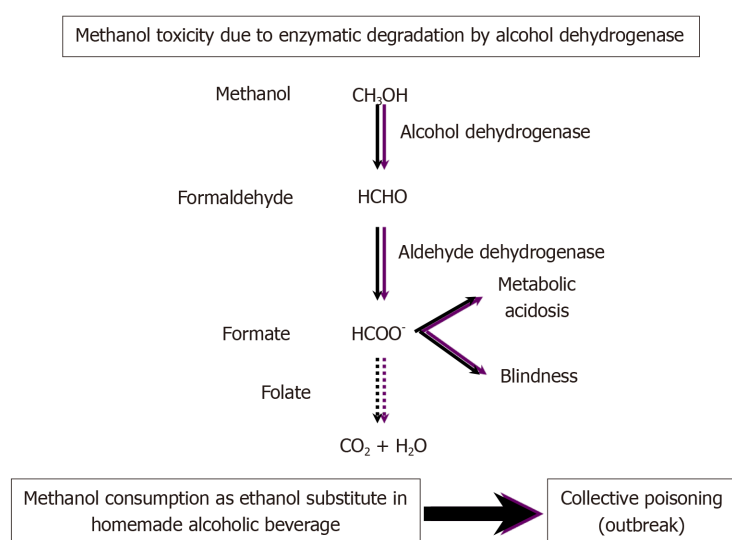


Figure 1 Metabolism pathway of methanol and its resulting toxicity in humans.

country. Before living our ICU, they gave their consent for the anonymous use of their data for research purposes.

DISCUSSION

Outbreaks of methanol poisoning occur frequently on a global basis and affect vulnerable populations^[5]. The situation in Egypt is poorly known, likely with many cases and even outbreaks going unnoticed. Here, we described the features and outcome of six methanol-poisoned patients managed in Cairo, allowing us to acknowledge the limitations that influenced our therapeutic strategy and to review the main underlying public health issues that remain unsolved to date.

All six patients presented with severe metabolic acidosis, which is the most common disturbance in methanol intoxication due to the accumulation of formic acid^[1,12]. All patients presented with visual disturbances, which is the only specific symptom of methanol poisoning. Visual disturbances are frequently reported in methanol poisoning, with approximately 30%-60% prevalence on hospital admission^[9,13-17]. Ocular changes consist in bilateral retinal edema, hyperemia of the discs and blurring of the disc margins. Usually, optic atrophy is a late complication of methanol poisoning^[12,13]. In our series, 1 patient developed almost complete blindness, probably due to his delayed admission and treatment in comparison to the others.

When methanol poisoning is suspected based on medical history, osmolal gap or anion gap metabolic acidosis, confirmation should be rapidly obtained with the measurement of blood methanol concentration^[18,19]. However, if not readily available, osmolal gap has been reported to be a useful indicator for the presence of toxic alcohol to guide the treatment^[19]. In our hospital, due to deficient regional resources, neither osmolality testing, anion gap measurement nor methanol leveling was readily available. Therefore, empirical therapy was immediately started based on the typical features attributed to methanol toxicity.

The full correction of metabolic acidosis and the rapid formate formation blockage and elimination are the cornerstones of management^[2,12,20]. Ethanol, a competitive ADH substrate and fomepizole, a potent ADH inhibitor, are the two recommended antidotes with established effectiveness to reverse methanol toxicity^[1,12,14,15,21]. Hemodialysis is effective to reverse rapidly metabolic acidosis and enhance methanol and formate elimination^[2,12,20]. Leucovorin (folinic acid) is commonly administered due to its attributed effects to enhance formate metabolism in the monkey^[22]. Our patients did not receive any antidote and were only treated with hemodialysis, folinic acid and supportive care. Fomepizole is not marketed in Egypt. Ethanol is not readily available at the bedside in our region; additionally, due to the non-availability of blood ethanol concentration measurement, its administration was estimated to be unsafe by the physicians in charge.

The recommended indications for extracorporeal treatment of methanol poisoning

were revisited by the international Extracorporeal Treatment in Poisoning Work Group^[20]. Recommendations included any of the following criteria being attributed to methanol: Coma, seizures, new vision deficits, metabolic acidosis with blood pH ≤ 7.15 , persistent metabolic acidosis despite adequate supportive measures and antidotes and serum anion gap ≥ 24 mmol/L. Intermittent hemodialysis was recognized as the modality of choice, while continuous modalities were considered as acceptable alternatives. In our series, all patients presented at least one of these criteria and were therefore dialyzed. If available, serum methanol concentration should also be considered to indicate hemodialysis if ≥ 700 mg/L (21.8 mmol/L) in the context of fomepizole therapy; if ≥ 600 mg/L (18.7 mmol/L) in the context of ethanol treatment; and if ≥ 500 mg/L (15.6 mmol/L) in the absence of an ADH blocker^[20]. In the absence of methanol concentration, the osmolal gap was estimated to inform the decision. In our situation, none of these biological parameters was available, and hemodialysis decision was undertaken based on the severity of acidosis and the presence of visual impairments on admission.

Although hemodialysis should be done in severely methanol-intoxicated patients, it may be readily unavailable in case of outbreak due to limited resources^[23,24]. Selection of patients to perform hemodialysis should thus be prioritized on clinical indications (respiratory, neurological or visual symptoms or reduced kidney function) rather than on absolute methanol levels^[12,20]. Contrary to conventional teaching, acidosis may occur only a few hours after ingestion, but this delay is prolonged in case of ethanol co-ingestion^[23]. Here, the exact starting time and duration of drinking as well as the beverage composition remained unknown. Published data are insufficient to apply 200 mg/L (6.2 mmol/L) as treatment threshold in a non-acidotic patient arriving early for care. It is possible to offer prolonged ADH inhibition with fomepizole until hemodialysis can be performed, if necessary. Nevertheless, this approach should be balanced against the longer (approximately 52 h) methanol half-life with the antidote and need for extended hospitalization^[14,21,25]. In patients without significant acidosis or ocular symptoms, treatment with ADH inhibition alone has been shown to be safe and is therefore a viable option if hemodialysis is not possible or methanol concentrations are not markedly elevated.

These international recommendations should reduce the allocation of resources to patients with less severe poisoning, so that extracorporeal treatments can be prioritized to those with greater need. Guidance on risk stratification of patients with severe methanol poisoning may be useful to help physicians in charge of mass casualty care^[24]. Very recently, consensus statements were established on the approach to patients in a methanol poisoning outbreak, setting up international recommendations and a triage system that identifies patients most likely to benefit, so that they are prioritized in favor of those in whom treatment is futile or those with low toxicity exposures at that time^[23]. A risk assessment score utilizing simple readily available parameters on patient admission exists, and it is based on a multicenter study that included observational data from several methanol poisoning outbreaks to help identify the patients associated with poor outcome (Table 2)^[26]. Low pH (pH < 7.00), coma (Glasgow coma score < 8) and inadequate hyperventilation [$\text{PaCO}_2 \geq 3.1$ kPa (or 23 mmHg) in spite of arterial pH < 7.00] on admission were shown to be the strongest predictors of poor outcome after methanol poisoning. Interestingly, improved clinical outcome was more recently shown to be positively associated with out-of-hospital ethanol administration^[27,28]. Therefore, conscious adults with suspected poisoning should be considered for administration of out-of-hospital ethanol to reduce morbidity and mortality. However, we acknowledge that such a recommendation has serious limitations in a Muslim country like Egypt.

Outcome of methanol-induced blindness appears less predictable. However, improvement of optic nerve conductivity has been reported in more than 80% of the patients during the first years of follow-up^[28]. Visual disturbances on admission and coma are significantly more prevalent in the patients with visual sequelae^[16]. Although depth of acidosis at presentation is the strongest determinant of the final visual acuity, no other parameter at presentation including demographics, elapsed time to presentation, symptoms, neurological examination, arterial blood gas and brain computed tomography-scan findings was found able to identify transient *versus* permanent visual injuries in the initial disturbances^[17,29]. In the recent Czech mass methanol outbreak, no association was found between visual sequelae and type of antidote administered, mode of hemodialysis or folate substitution, while only pre-hospital administration of ethanol seemed beneficial, if based on the follow-up evaluating the retinal nerve fibers layer by optical coherence tomography^[16]. Intravenous high-dose methylprednisolone, alone^[13] or in combination with intravenous erythropoietin^[30], has been suggested to reverse methanol-induced ocular

Table 2 Risk assessment for the rapid evaluation of outcome based on admission parameters, adapted from Paasma *et al*^[29]

Risk group	Coma	Arterial pH	PaCO ₂	Death risk
A	No	≥ 7.00	-	5%
B	No	6.74-6.99	-	10%
C	No	< 6.74	-	25%
D	Yes	6.74-6.99	< 3.07	50%
E	Yes	6.74-6.99	≥ 3.07	83%
F	Yes	< 6.74	-	89%

Determination of the risk group of 1 patient on admission requires the combination of all conditions for the three parameters.

injuries provided the interval between methanol consumption and starting treatment is short like in our patients; but its definitive effectiveness remains to be proved.

One major issue in mass methanol poisoning is the rapid identification of the involved causative agent. Here, our investigations concluded that the suspected beverage was homemade with alcoholic disinfectant used for medicinal purposes and sold in most of local pharmacies, in bottles lacking pamphlet and use instructions. Data on the bottles written in Arabic only showed that they contained 70% ethanol and have to be kept away from children (Figure 2). It is probable that the absence of adequate information on the disinfectant bottles was misleading and confusing.

Prevention is also a major critical issue from a public health perspective and includes public education, constraining the public purchase of methanol-containing items and storing these items securely^[7]. According to the Classification, Labeling and Packaging article 17 of the European Chemical Agency's guidance of labeling and packaging, a substance and mixture classified as hazardous must bear a label including the following elements: (1) Name, address and telephone number of the supplier(s); (2) The nominal quantity of the substance or mixture in the package made available to the general public, unless this quantity is specified elsewhere on the package; and (3) Product identifiers; hazard pictograms, where applicable; the relevant signal word, where applicable; hazard statements, where applicable; and appropriate precautionary statements where applicable^[31]. In addition, according to the Egyptian New Consumer Law 181/2018, the producer or supplier of any commodity must inform the consumer of all essential data about the product, including particularly its source, price, characteristics and all basic components in accordance with the Egyptian or international specifications standards. Clearly, the basic laws have not been respected in this situation.

This experience has alarmed us about the terrible consequences of shortages in staff, testing and treatment availability (antidote and extracorporeal treatments) in Egypt that may become challenging in a larger methanol poisoning outbreak. Poor knowledge of management of methanol poisoning among health workers and late diagnosis of the suspected cases may result in high case fatality. Increasing local competencies is crucial since mobilization of international teams in case of major outbreaks takes time^[5]. A strategic plan should be in place in the rare event of an outbreak. Government health authorities should search for poisoned individuals who have not yet presented to hospitals. Joint effort between local health authorities and non-governmental organizations with the necessary infrastructure and emergency experience combined with provision of detailed and locally adapted treatment protocols and training is life-saving. Guidelines have to be rapidly disseminated by email alert systems or other internet-based services or hand-delivered when required in resource-limited regions.

CONCLUSION

Mass methanol poisoning with unpredictable risk assessment represents a major threat in developing countries with resource limitations like Egypt. In this local outbreak, immediate supply of supportive care and hemodialysis overcame the deficit in diagnostic testing and antidotes. This study brings attention to the risks due to sold products with no warnings or ingredients notice. Like the ongoing extended methanol

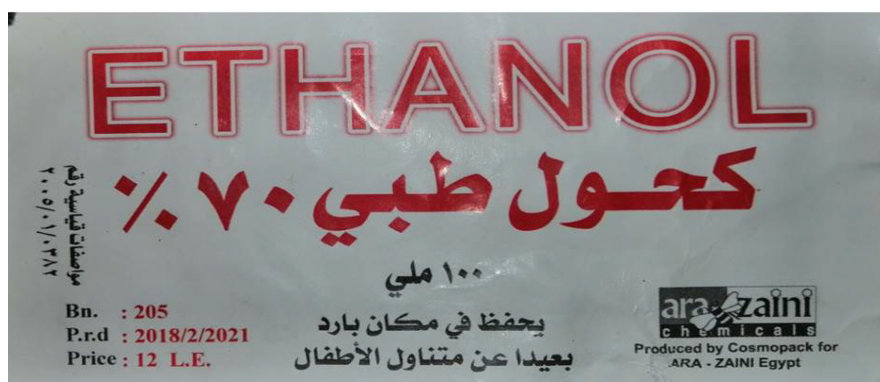

Figure 2 Label of the locally produced disinfectant sold in the Egyptian pharmacies.

poisoning outbreak in India, dramatic consequences are not impossible to exclude.

ACKNOWLEDGMENTS

The authors would like to acknowledge Alison Good, Scotland, United Kingdom, for her helpful review of this manuscript.

REFERENCES

- Kraut JA, Mullins ME. Toxic Alcohols. *N Engl J Med* 2018; **378**: 270-280 [PMID: 29342392 DOI: 10.1056/NEJMr1615295]
- Mégarbane B, Borron SW, Baud FJ. Current recommendations for treatment of severe toxic alcohol poisonings. *Intensive Care Med* 2005; **31**: 189-195 [PMID: 15627163 DOI: 10.1007/s00134-004-2521-0]
- Aghababacian H, Araghi Ahvazi L, Ostadtaghizadeh A. The Methanol Poisoning Outbreaks in Iran 2018. *Alcohol Alcohol* 2019; **54**: 128-130 [PMID: 30715164 DOI: 10.1093/alcalc/agz005]
- Onyekwere N, Nwadiuto I, Maleghemi S, Maduka O, Numbere TW, Akpuh N, Kanu E, Katchy I, Okefor I. Methanol poisoning in South- South Nigeria: Reflections on the outbreak response. *J Public Health Afr* 2018; **9**: 748 [PMID: 30079165 DOI: 10.4081/jphia.2018.748]
- Rostrup M, Edwards JK, Abukalish M, Ezzabi M, Some D, Ritter H, Menge T, Abdelrahman A, Rootwelt R, Janssens B, Lind K, Paasma R, Hovda KE. The Methanol Poisoning Outbreaks in Libya 2013 and Kenya 2014. *PLoS One* 2016; **11**: e0152676 [PMID: 27030969 DOI: 10.1371/journal.pone.0152676]
- Hassanian-Moghaddam H, Nikfarjam A, Mirafzal A, Saberinia A, Nasehi AA, Masoumi Asl H, Memaryan N. Methanol mass poisoning in Iran: role of case finding in outbreak management. *J Public Health (Oxf)* 2015; **37**: 354-359 [PMID: 24944254 DOI: 10.1093/pubmed/dfu038]
- Collister D, Duff G, Palatnick W, Komenda P, Tangri N, Hingwala J. A Methanol Intoxication Outbreak From Recreational Ingestion of Fracking Fluid. *Am J Kidney Dis* 2017; **69**: 696-700 [PMID: 28111025 DOI: 10.1053/j.ajkd.2016.10.029]
- Zakharov S, Pelclova D, Urban P, Navratil T, Diblik P, Kuthan P, Hubacek JA, Miovsky M, Klempir J, Vaneckova M, Seidl Z, Pilin A, Fenclova Z, Petrik V, Kotikova K, Nurieva O, Ridzon P, Rulisek J, Komarc M, Hovda KE. Czech mass methanol outbreak 2012: epidemiology, challenges and clinical features. *Clin Toxicol (Phila)* 2014; **52**: 1013-1024 [PMID: 25345388 DOI: 10.3109/15563650.2014.974106]
- Paasma R, Hovda KE, Tikkerberi A, Jacobsen D. Methanol mass poisoning in Estonia: outbreak in 154 patients. *Clin Toxicol (Phila)* 2007; **45**: 152-157 [PMID: 17364632 DOI: 10.1080/15563650600956329]
- Hovda KE, Hunderi OH, Tafjord AB, Dunlop O, Rudberg N, Jacobsen D. Methanol outbreak in Norway 2002-2004: epidemiology, clinical features and prognostic signs. *J Intern Med* 2005; **258**: 181-190 [PMID: 16018795 DOI: 10.1111/j.1365-2796.2005.01521.x]
- Gupta S, Guy J, Humayun H, CNN. Toxic moonshine kills 154 people and leaves hundreds hospitalized in India. [published 25 February 2019]. Available from: <https://edition.cnn.com/2019/02/24/asia/india-alcohol-poisoning/index.html>
- Barceloux DG, Bond GR, Krenzelok EP, Cooper H, Vale JA; American Academy of Clinical Toxicology Ad Hoc Committee on the Treatment Guidelines for Methanol Poisoning. American Academy of Clinical Toxicology practice guidelines on the treatment of methanol poisoning. *J Toxicol Clin Toxicol* 2002; **40**: 415-446 [PMID: 12216995 DOI: 10.1081/clt-120006745]
- Sodhi PK, Goyal JL, Mehta DK. Methanol-induced optic neuropathy: treatment with intravenous high dose steroids. *Int J Clin Pract* 2001; **55**: 599-602 [PMID: 11770356 DOI: 10.2169/internalmedicine.40.1162]
- Mégarbane B, Borron SW, Trout H, Hantson P, Jaeger A, Krencker E, Bismuth C, Baud FJ. Treatment of acute methanol poisoning with fomepizole. *Intensive Care Med* 2001; **27**: 1370-1378 [PMID: 11511951 DOI: 10.1007/s001340101011]
- Brent J, McMartin K, Phillips S, Aaron C, Kulig K; Methylpyrazole for Toxic Alcohols Study Group. Fomepizole for the treatment of methanol poisoning. *N Engl J Med* 2001; **344**: 424-429 [PMID: 11172179]

- DOI: [10.1056/NEJM200102083440605](https://doi.org/10.1056/NEJM200102083440605)]
- 16 **Zakharov S**, Pelclova D, Diblik P, Urban P, Kuthan P, Nurieva O, Kotikova K, Navratil T, Komarc M, Belacek J, Seidl Z, Vaneckova M, Hubacek JA, Bezdicek O, Klempir J, Yurchenko M, Ruzicka E, Miovsky M, Janikova B, Hovda KE. Long-term visual damage after acute methanol poisonings: Longitudinal cross-sectional study in 50 patients. *Clin Toxicol (Phila)* 2015; **53**: 884-892 [PMID: [26364866](https://pubmed.ncbi.nlm.nih.gov/26364866/) DOI: [10.3109/15563650.2015.1086488](https://doi.org/10.3109/15563650.2015.1086488)]
 - 17 **Desai T**, Sudhalkar A, Vyas U, Khamar B. Methanol poisoning: predictors of visual outcomes. *JAMA Ophthalmol* 2013; **131**: 358-364 [PMID: [23303293](https://pubmed.ncbi.nlm.nih.gov/23303293/) DOI: [10.1001/jamaophthalmol.2013.1463](https://doi.org/10.1001/jamaophthalmol.2013.1463)]
 - 18 **Kraut JA**. Diagnosis of toxic alcohols: limitations of present methods. *Clin Toxicol (Phila)* 2015; **53**: 589-595 [PMID: [26114345](https://pubmed.ncbi.nlm.nih.gov/26114345/) DOI: [10.3109/15563650.2015.1056880](https://doi.org/10.3109/15563650.2015.1056880)]
 - 19 **Hovda KE**, Hunderi OH, Rudberg N, Froyshov S, Jacobsen D. Anion and osmolal gaps in the diagnosis of methanol poisoning: clinical study in 28 patients. *Intensive Care Med* 2004; **30**: 1842-1846 [PMID: [15241587](https://pubmed.ncbi.nlm.nih.gov/15241587/) DOI: [10.1007/s00134-004-2373-7](https://doi.org/10.1007/s00134-004-2373-7)]
 - 20 **Roberts DM**, Yates C, Megarbane B, Winchester JF, Maclaren R, Gosselin S, Nolin TD, Laverigne V, Hoffman RS, Ghannoum M; EXTRIP Work Group. Recommendations for the role of extracorporeal treatments in the management of acute methanol poisoning: a systematic review and consensus statement. *Crit Care Med* 2015; **43**: 461-472 [PMID: [25493973](https://pubmed.ncbi.nlm.nih.gov/25493973/) DOI: [10.1097/CCM.0000000000000708](https://doi.org/10.1097/CCM.0000000000000708)]
 - 21 **Brent J**. Fomepizole for ethylene glycol and methanol poisoning. *N Engl J Med* 2009; **360**: 2216-2223 [PMID: [19458366](https://pubmed.ncbi.nlm.nih.gov/19458366/) DOI: [10.1056/NEJMc0806112](https://doi.org/10.1056/NEJMc0806112)]
 - 22 **McMartin KE**, Martin-Amat G, Makar AB, Tephly TR. Methanol poisoning. V. Role of formate metabolism in the monkey. *J Pharmacol Exp Ther* 1977; **201**: 564-572 [PMID: [405471](https://pubmed.ncbi.nlm.nih.gov/405471/) DOI: [10.1111/j.1749-6632.1986.tb23619.x](https://doi.org/10.1111/j.1749-6632.1986.tb23619.x)]
 - 23 **Hassanian-Moghaddam H**, Zamani N, Roberts DM, Brent J, McMartin K, Aaron C, Eddleston M, Dargan PI, Olson K, Nelson L, Bhalla A, Hantson P, Jacobsen D, Megarbane B, Balali-Mood M, Buckley NA, Zakharov S, Paasma R, Jarwani B, Mirafzal A, Salek T, Hovda KE. Consensus statements on the approach to patients in a methanol poisoning outbreak. *Clin Toxicol (Phila)* 2019; **57**: 1129-1136 [PMID: [31328583](https://pubmed.ncbi.nlm.nih.gov/31328583/) DOI: [10.1080/15563650.2019.1636992](https://doi.org/10.1080/15563650.2019.1636992)]
 - 24 **Roberts DM**, Hoffman RS, Gosselin S, Megarbane B, Yates C, Ghannoum M. The authors reply. *Crit Care Med* 2015; **43**: e211-e212 [PMID: [25978175](https://pubmed.ncbi.nlm.nih.gov/25978175/) DOI: [10.1097/CCM.0000000000001006](https://doi.org/10.1097/CCM.0000000000001006)]
 - 25 **Hovda KE**, Jacobsen D. Expert opinion: fomepizole may ameliorate the need for hemodialysis in methanol poisoning. *Hum Exp Toxicol* 2008; **27**: 539-546 [PMID: [18829729](https://pubmed.ncbi.nlm.nih.gov/18829729/) DOI: [10.1177/0960327108095992](https://doi.org/10.1177/0960327108095992)]
 - 26 **Sanaei-Zadeh H**, Zamani N, Shadnia S. Outcomes of visual disturbances after methanol poisoning. *Clin Toxicol (Phila)* 2011; **49**: 102-107 [PMID: [21370946](https://pubmed.ncbi.nlm.nih.gov/21370946/) DOI: [10.3109/15563650.2011.556642](https://doi.org/10.3109/15563650.2011.556642)]
 - 27 **Zakharov S**, Pelclova D, Urban P, Navratil T, Nurieva O, Kotikova K, Diblik P, Kurcova I, Belacek J, Komarc M, Eddleston M, Hovda KE. Use of Out-of-Hospital Ethanol Administration to Improve Outcome in Mass Methanol Outbreaks. *Ann Emerg Med* 2016; **68**: 52-61 [PMID: [26875060](https://pubmed.ncbi.nlm.nih.gov/26875060/) DOI: [10.1016/j.annemergmed.2016.01.010](https://doi.org/10.1016/j.annemergmed.2016.01.010)]
 - 28 **Nurieva O**, Hubacek JA, Urban P, Hlusicka J, Diblik P, Kuthan P, Sklenka P, Meliska M, Bydzovsky J, Heissigerova J, Kotikova K, Navratil T, Komarc M, Seidl Z, Vaneckova M, Vojtova L, Zakharov S. Clinical and genetic determinants of chronic visual pathway changes after methanol - induced optic neuropathy: four-year follow-up study. *Clin Toxicol (Phila)* 2019; **57**: 387-397 [PMID: [30451020](https://pubmed.ncbi.nlm.nih.gov/30451020/) DOI: [10.1080/15563650.2018.1532083](https://doi.org/10.1080/15563650.2018.1532083)]
 - 29 **Paasma R**, Hovda KE, Hassanian-Moghaddam H, Brahmi N, Afshari R, Sandvik L, Jacobsen D. Risk factors related to poor outcome after methanol poisoning and the relation between outcome and antidotes--a multicenter study. *Clin Toxicol (Phila)* 2012; **50**: 823-831 [PMID: [22992104](https://pubmed.ncbi.nlm.nih.gov/22992104/) DOI: [10.3109/15563650.2012.728224](https://doi.org/10.3109/15563650.2012.728224)]
 - 30 **Pakdel F**, Sanjari MS, Naderi A, Pirmarzashti N, Haghighi A, Kashkouli MB. Erythropoietin in Treatment of Methanol Optic Neuropathy. *J Neuroophthalmol* 2018; **38**: 167-171 [PMID: [29300238](https://pubmed.ncbi.nlm.nih.gov/29300238/) DOI: [10.1097/WNO.0000000000000614](https://doi.org/10.1097/WNO.0000000000000614)]
 - 31 European Chemical Agency's guidance of labeling and packaging. [cited 6 April 2020]. Available from: https://echa.europa.eu/documents/10162/23036412/clp_labelling_en.pdf/89628d94-573a-4024-86cc-0b4052a74d65



Published by **Baishideng Publishing Group Inc**
7041 Koll Center Parkway, Suite 160, Pleasanton, CA 94566, USA

Telephone: +1-925-3991568

E-mail: bpgoffice@wjgnet.com

Help Desk: <https://www.f6publishing.com/helpdesk>

<https://www.wjgnet.com>

