

World Journal of *Transplantation*

World J Transplant 2020 December 28; 10(12): 372-421



MINIREVIEWS

- 372 Donor risk factors in pancreas transplantation
Muñoz-Bellví L, López-Sánchez J
- 381 Complications during multiorgan retrieval and pancreas preservation
Casanova D, Gutierrez G, Gonzalez Noriega M, Castillo F
- 392 Exocrine drainage in pancreas transplantation: Complications and management
Ferrer-Fàbrega J, Fernández-Cruz L
- 404 Late complications of pancreas transplant
Maupoey Ibáñez J, Boscà Robledo A, López-Andujar R
- 415 Immediate post-operative complications (I): Post-operative bleeding; vascular origin: Thrombosis pancreatitis
Perez Daga JA, Perez Rodriguez R, Santoyo J

ABOUT COVER

Associate editor of *World Journal of Transplantation*, Daniel Casanova, MD, PhD, FACS, FEBT, is a Professor at University Hospital Valdecilla, University of Cantabria in Santander, Spain. He obtained his MD degree from University Zaragoza. In 1978, he became Assistant Professor of Surgery at the University Hospital Valdecilla in Santander, where he completed his PhD on islet transplantation. He was promoted to Professor of Surgery in 1992 and to Full Professor of Surgery in 2002 at University of Cantabria. His career research interests include abdominal transplants, and hepato-pancreato-biliary surgery and endocrine surgery. In 2013, he was appointed Honorary Professor of the Department of Surgery and Cancer at Hammersmith Hospital, Imperial College, London. He is member of the editorial board and reviewer of several journals, and has published more than 250 articles. (L-Editor: Filipodia)

AIMS AND SCOPE

The primary aim of *World Journal of Transplantation* (WJT, *World J Transplant*) is to provide scholars and readers from various fields of transplantation with a platform to publish high-quality basic and clinical research articles and communicate their research findings online.

WJT mainly publishes articles reporting research results obtained in the field of transplantation and covering a wide range of topics including bone transplantation, brain tissue transplantation, corneal transplantation, descemet stripping endothelial keratoplasty, fetal tissue transplantation, heart transplantation, kidney transplantation, liver transplantation, lung transplantation, pancreas transplantation, skin transplantation, etc..

INDEXING/ABSTRACTING

The WJT is now abstracted and indexed in PubMed, PubMed Central, China National Knowledge Infrastructure (CNKI), and Superstar Journals Database.

RESPONSIBLE EDITORS FOR THIS ISSUE

Production Editor: Li-Li Wang; Production Department Director: Yun-Xiaojian Wu; Editorial Office Director: Jia-Ping Yan.

NAME OF JOURNAL

World Journal of Transplantation

ISSN

ISSN 2220-3230 (online)

LAUNCH DATE

December 24, 2011

FREQUENCY

Monthly

EDITORS-IN-CHIEF

maurizio salvadori, Sami Akbulut, Vassilios Papalois

EDITORIAL BOARD MEMBERS

<https://www.wjgnet.com/2220-3230/editorialboard.htm>

PUBLICATION DATE

December 28, 2020

COPYRIGHT

© 2020 Baishideng Publishing Group Inc

INSTRUCTIONS TO AUTHORS

<https://www.wjgnet.com/bpg/gerinfo/204>

GUIDELINES FOR ETHICS DOCUMENTS

<https://www.wjgnet.com/bpg/GerInfo/287>

GUIDELINES FOR NON-NATIVE SPEAKERS OF ENGLISH

<https://www.wjgnet.com/bpg/gerinfo/240>

PUBLICATION ETHICS

<https://www.wjgnet.com/bpg/GerInfo/288>

PUBLICATION MISCONDUCT

<https://www.wjgnet.com/bpg/gerinfo/208>

ARTICLE PROCESSING CHARGE

<https://www.wjgnet.com/bpg/gerinfo/242>

STEPS FOR SUBMITTING MANUSCRIPTS

<https://www.wjgnet.com/bpg/GerInfo/239>

ONLINE SUBMISSION

<https://www.f6publishing.com>



Complications during multiorgan retrieval and pancreas preservation

Daniel Casanova, Gonzalo Gutierrez, Monica Gonzalez Noriega, Federico Castillo

ORCID number: Daniel Casanova 0000-0003-3863-5039; Gonzalo Gutierrez 0000-0002-1878-3985; Monica Gonzalez Noriega 0000-0002-9494-0903; Federico Castillo 0000-0002-5092-8830.

Author contributions: Casanova D designed the review and serves as guarantor; Gutierrez G, Gonzalez Noriega M and Castillo F contributed important intellectual content to the document.

Conflict-of-interest statement: The authors declare no conflicts of interest.

Open-Access: This article is an open-access article that was selected by an in-house editor and fully peer-reviewed by external reviewers. It is distributed in accordance with the Creative Commons Attribution NonCommercial (CC BY-NC 4.0) license, which permits others to distribute, remix, adapt, build upon this work non-commercially, and license their derivative works on different terms, provided the original work is properly cited and the use is non-commercial. See: <http://creativecommons.org/licenses/by-nc/4.0/>

Manuscript source: Invited manuscript

Specialty type: Transplantation

Daniel Casanova, Department of Surgery, University Hospital Marques de Valdecilla, University Cantabria, Santander 39008, Cantabria, Spain

Gonzalo Gutierrez, Monica Gonzalez Noriega, Federico Castillo, Department of Surgery, University Hospital Marques de Valdecilla, Santander 39008, Cantabria, Spain

Corresponding author: Daniel Casanova, FACS, FRCS (Ed), MD, PhD, Full Professor, Surgeon, Department of Surgery, University Hospital Marques de Valdecilla, University Cantabria, Chairman Board Europeo de Trasplante, Servicio de Cirugía General y Digestiva Hospital Universitario Marqués de Valdecilla, Santander 39008, Cantabria, Spain. daniel.casanova@unican.es

Abstract

In pancreas transplantation, complications can arise at each step of the process, from the initial selection of donors and recipients through the surgical technique itself and the post-operative period, when lifelong immunosuppression is required. In the early steps, careful retrieval and preservation of the pancreas are crucial for the viability of the organ and ultimate success of the transplant. The pancreas is a low-flow gland, making it highly sensitive to transplantation conditions and presenting risk of pancreatitis due to periods of ischemia. The two groups of donors - after brain death (DBD) or after cardiac arrest (DCD) - require different strategies of retrieval and preservation to avoid or reduce the risk of complications developing during and after the transplantation. For DBD donor transplantation, multiorgan retrieval and cold preservation is the conventional technique. Asystole donor (DCD) transplantation, in contrast, can benefit from the newest technologies, such as hypothermic and especially normothermic preservation machines (referred to as NECMO), to optimize organ preservation. The latter has led to an increase in the pool of donors by facilitating recuperation of organs for transplantation that would have been discarded otherwise.

Key Words: Pancreas transplantation; Diabetes mellitus; Graft thrombosis; Compartmental syndrome; Pancreas retrieval; Pancreas preservation

©The Author(s) 2020. Published by Baishideng Publishing Group Inc. All rights reserved.

Country/Territory of origin: Spain**Peer-review report's scientific quality classification**

Grade A (Excellent): A

Grade B (Very good): 0

Grade C (Good): 0

Grade D (Fair): D

Grade E (Poor): 0

Received: June 20, 2020**Peer-review started:** June 18, 2020**First decision:** July 25, 2020**Revised:** August 4, 2020**Accepted:** October 5, 2020**Article in press:** October 5, 2020**Published online:** December 28, 2020**P-Reviewer:** Novita BD, Pranata R**S-Editor:** Huang P**L-Editor:** A**P-Editor:** Wang LL

Core Tip: The retrieval and preservation steps of pancreas transplantation are critical factors for graft and patient survival. The most frequent complications of these steps are pancreatitis, graft thrombosis, fistula, and infectious collections. Therefore, it is very important to design and carry out a careful surgical technique for retrieval and a rigorous method of preservation for optimal organ integrity.

Citation: Casanova D, Gutierrez G, Gonzalez Noriega M, Castillo F. Complications during multiorgan retrieval and pancreas preservation. *World J Transplant* 2020; 10(12): 381-391

URL: <https://www.wjgnet.com/2220-3230/full/v10/i12/381.htm>

DOI: <https://dx.doi.org/10.5500/wjt.v10.i12.381>

INTRODUCTION

The selection requirements for accepting a pancreatic graft are very strict, with the transplant and patient outcomes depending largely on such^[1-3]. The most important risk criteria for recipients are age over 55 years, body mass index over 30%, creatinine level over 1.5, preservation period over 20 h, prolonged periods of cardiac arrest and hypotension, and donor factors of atherosclerosis as cause of brain death, presence of arteriosclerosis of the celiac axis, presence of thrombophilia, and history of cardiac arrest^[4,5]. The complications that occur during the earliest steps (retrieval and preservation) are determinant factors of the transplant outcome. Early recognition of complications and initiation of preventive measures, therefore, guide the decision-making process for moving forward with any transplantation.

The potential complications are numerous but the most common are postoperative bleeding, graft thrombosis, peripancreatic collections and abscesses, duodenal fistulas, pancreatitis, pseudocyst formation, compartment syndrome, and long-term formation of fungal aneurysms^[6-8]. These recipient complications present equal risk with regard to donor status at time of harvesting: Brain dead donor (DBD) or asystole (DCD). These two forms of donor status are determined by the circumstances of the donation situation. DBD, which uses cold-temperature preservation, occurs under the following three scenarios: A1, with unidentified vascular anomalies during the retrieval; A2, with iatrogenic lesions during the retrieval; and A3, with anomalous factors related to the perfusion and preservation. DCD, on the other hand, is classified as either B1, with super-fast retrieval and cold preservation, or B2, with preservation with normothermic preservation machines (NECMOs).

A-DBD (A1-A3) WITH RETRIEVAL AND COLD PRESERVATION

In these scenarios, the pancreatic retrieval technique can be performed by classic dissection, obtaining the pancreas in combination with the liver, or by a technique of removal of the entire abdominal block (liver, pancreas, and kidneys). In most pancreas transplant programs, the type of graft used is the pancreatic-duodenal form obtained from DBDs; although, in some centers, DCDs are used. Moreover, at the end of the century (1980s and 1990s), some centers used segmental grafts, including those obtained from living donors.

Since pancreas donors are often also liver donors, it is mandatory to share both arterial and venous vascularization^[9-11]. As such, there are a number of specific factors that determine the viability of a pancreatic graft, such as vascular abnormalities, especially of the hepatic artery, edema or fat infiltration of the pancreas, injuries during harvesting, injuries to the surface of the pancreas, hematomas, etc^[12-14].

A1 (unidentified vascular anomalies during the retrieval)

The fundamental axis of the arterial circulation is the celiac axis, and the system consists of three main arteries: The splenic artery, the gastroduodenal artery, and the superior mesenteric artery. One of the most frequent vascular anomalies encountered is a right hepatic artery from the upper mesenteric artery (Figures 1 and 2). This anomaly must be detected at the beginning of the retrieval operation, since injury or inadvertent section of this artery compromises the use of one of the associated

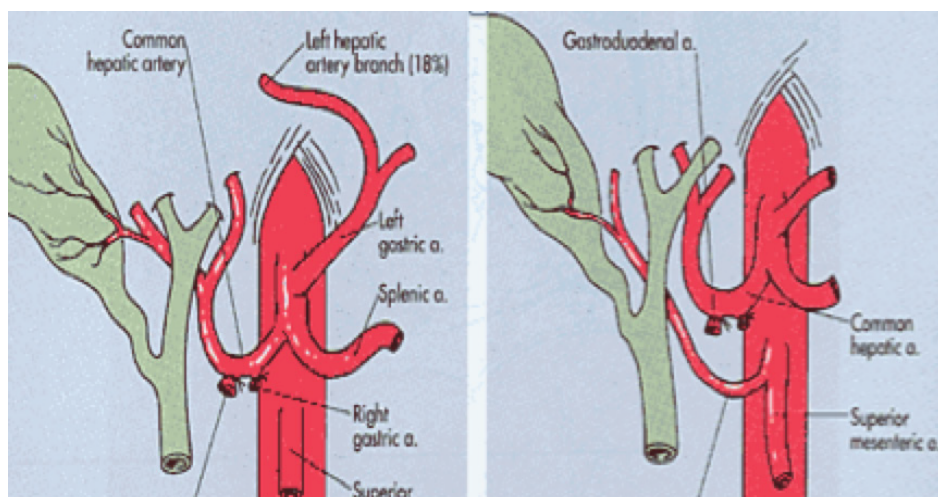


Figure 1 Right hepatic artery from mesenteric superior artery.

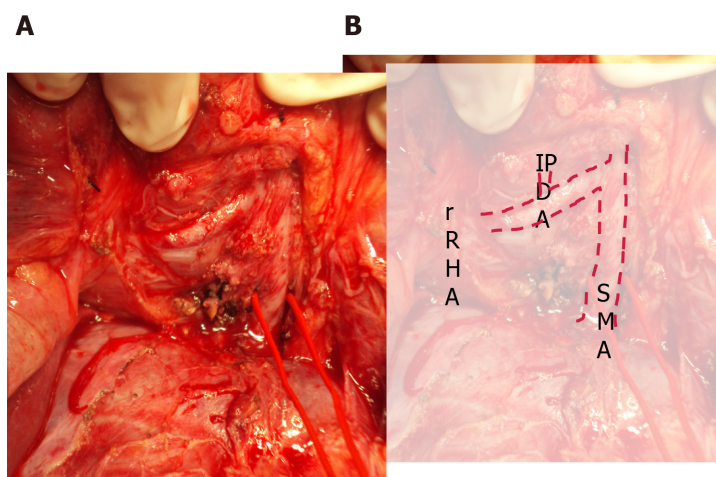


Figure 2 Right hepatic artery from mesenteric superior artery. A: Intraoperative view; B: Overlaid with identifiers. SMA: Superior mesenteric artery; IPDA: Inferior pancreaticoduodenal artery; rRHA: Replaced right hepatic artery.

organs^[15,16]. Another frequently encountered anomaly is a dorsal pancreatic artery exiting directly into the celiac trunk or just before the splenic artery (Figure 3); injury of this artery during surgical maneuvers results in graft thrombosis^[17].

A2 (iatrogenic lesions during retrieval)

This situation can only be avoided (or risk minimized) by careful performance of the pancreas retrieval technique^[18]. In most cases, the situation can be readily recognized by the surgeon during the harvesting procedure and repaired immediately; if it goes undetected until the inspection of the graft during the bench surgery, or even until the time of implantation and revascularization, the consequences can be dire (hematoma and postoperative pancreatitis)^[19,20]. From a technical point of view, it is recommended to mobilize the pancreas without touching the gland (as much as possible), holding it through the spleen in order to avoid traction, hematomas and capsule tears (Figure 4).

The most critical injuries are those that involve the vessels of the gland at the pancreas head and duodenum; although, those involving the pancreatic body and tail are not trifling. One of the complications that can occur is related to the anatomical vascular anomalies already mentioned, such as the existence of a right hepatic artery as the first branch of the superior mesenteric artery or the section or injury of a segment of the splenic artery or the dorsal pancreatic artery. If this has occurred and tail perfusion is compromised, at most centers the graft is usually discarded for vascularized transplantation, leaving open the option of use for islet isolation. However, in some emergent situations, such as a rescue surgery, a distal resection could be performed in order to use the graft for vascularized transplant.

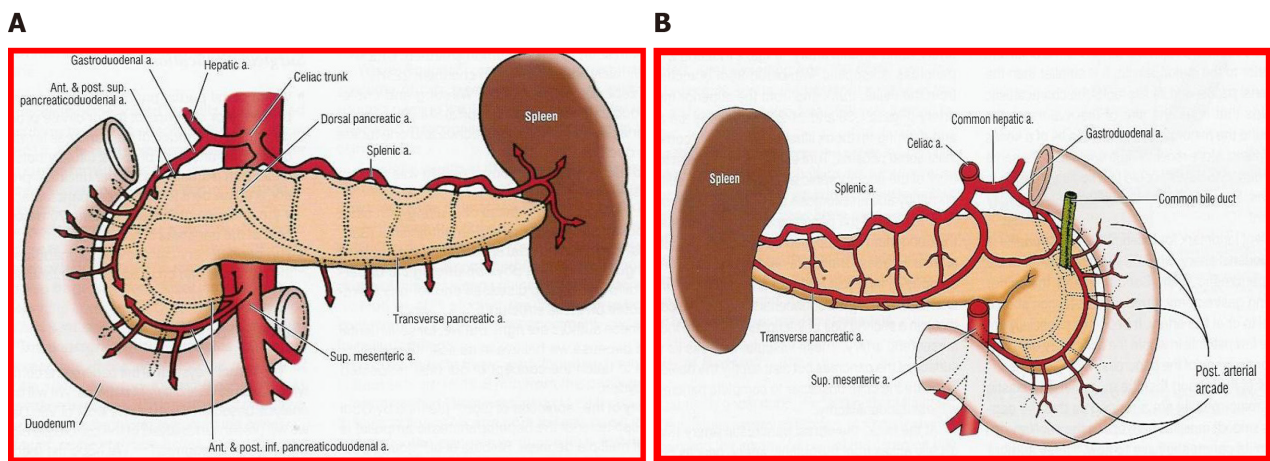


Figure 3 Arterial vasculature of the pancreas. Illustrated from the view of contemporary surgery. A: Anterior; B: Posterior.

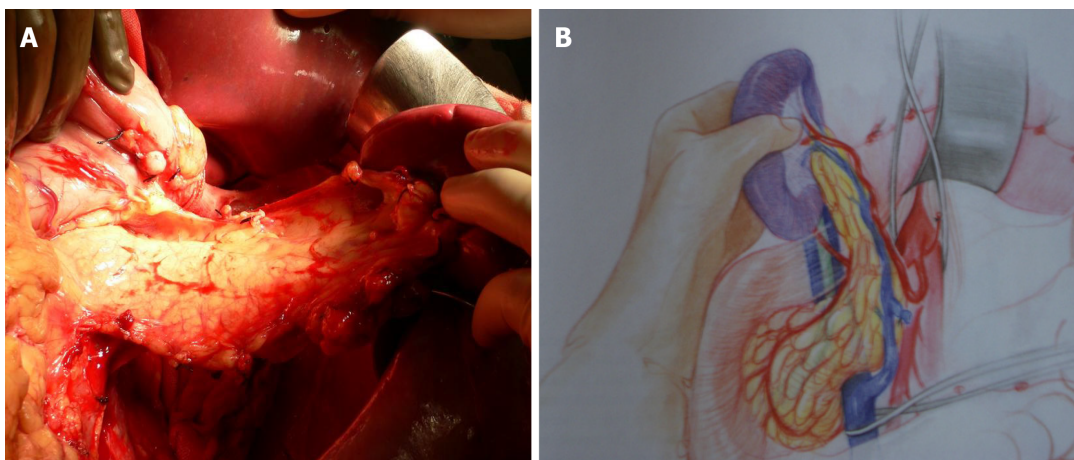


Figure 4 Pancreas graft mobilization. A: Photo; B: Drawing from Martin Finch.

It is convenient to place some sutures that identify the edge of the splenic artery, since it can retract, and also to identify the section edge of the portal vein, given its small size. It is important to check that the lower pancreaticoduodenal artery is located on the pancreatic side entirely; this is especially important during preparation of the duodenal segment of the graft, and during distal section of the mesenteric vessels.

A3 (factors related to the perfusion and preservation of the pancreas)

Static cold storage is the preservation technique used in most programs of pancreas transplants. It is based on the principle of reducing cell metabolism by lowering the temperature. This decreases the consumption of adenosine triphosphate and inhibits the activity of intracellular enzymes, with consequent reduction in cell degradation by hydrolysis of phospholipids. Under the hypothermic condition, metabolism activity drops to 10% but, over time, it produces ischemic lesions. This is particularly detrimental to graft survival, and preservative solutions are designed to minimize the detrimental effects of cold ischemic injury^[21,22]. This remains an essential aspect for the surgeon's attention, however, since the pancreas is a gland that is very sensitive to edema.

The perfusion technique must be carried out with any preservation solution [*e.g.*, electrolyte mimicking intracellular, *i.e.*, UW, or extracellular, *i.e.*, IGL, solutions, and mannitol-containing solutions, *i.e.*, Celsior and histidine-tryptophan-ketoglutarate (commonly referred to as HTK), *etc.*] through arterial cannulas at low pressure (< 60 cm) in order to minimize edema^[23-27]. In general, it is recommended to perform perfusion through the aorta^[9], sectioning the portal vein above the pancreas after having perfused the 1st L of solution, in order to facilitate drainage of the pancreas and avoid edema.

In order to maintain arterial and venous perfusion for the liver, the portal vein

proximal to the liver may be cannulated and perfusion continued. Arterial perfusion should also be continued to maintain the perfusion of the liver and kidneys. A maximum of 4 L of perfusion solution is recommended for a 70 kg donor. Once the pancreas has cooled through the perfusion and *via* contact with ice, it can be retrieved separately or together with the liver (Figures 5 and 6). There is good evidence that both liver and pancreas function better when retrieved en bloc and separated on the back table^[10].

In bench surgery, the integrity of the gland and its vessels must be checked. In addition to confirming that the capsule is intact, it is important to infuse preservation solution at low pressure through the cut ends of the splenic and superior mesenteric arteries, to verify that the effluent flows properly through the end of the graft's portal vein. It can also be left without ligating the stump of the gastroduodenal artery to check the permeability of the arterial tree at that level. The venous drainage of the pancreas is made up of vessels that connect to the splenic vein and the superior mesenteric vein, giving way to the portal vein (Figures 7 and 8).

If the perfusion is not satisfactory or the portal effluent remains bloody with small clots, the perfusion is deemed inadequate and a risk for venous thrombosis of the graft^[28].

B-DONOR IN ASYSTOLE (DCD) (B1 AND B2)

Shortage of conventional pancreas donors has led to a significant increase in DCD donations. Indeed, asystole donors have constituted a very important group in recent years. The largest studies comparing the outcomes of pancreas transplantation from DCDs with those from DBDs have shown comparable results. However, it is important to remember that the selection of DCDs is often more rigorous and DCDs tend to be younger, with a lower body mass index; and, recipients of such are also at lower-risk immunological level, further favoring the results from DCD transplants^[29-32]. Given that the use of these donors implies an increase in resources, we must be extreme in the selection criteria, in order to identify the risk factors and therefore the complications that these donors may present (Table 1). Although there are some differences in the screening and control criteria of these donors in different occidental countries, in general, the 5-min non-touch period is accepted. The technique chosen for organ retrieval depends on whether NECMO technology is available; alternatively, a super-fast cold technique must be used.

B1 (super-fast retrieval and cold preservation)

Super-fast retrieval and cold dissection technique was introduced as a means of rapid procurement of all abdominal organs. This approach was initially used with unstable donors but has since been applied successfully to multiorgan retrievals. In such cases, extreme care must be taken when performing the surgery to avoid iatrogenic injuries. It is very important to check for anatomical anomalies and carry out the surgical technique in conjunction with an early abdominal perfusion through the aorta. After the non-touch period, wide-access laparotomy and rapid access to the aorta should be performed to insert the perfusion cannula^[33-35] (Figure 9).

Warm ischemic time has two components - the time from when the patient is hypotensive after the start of life-support limitation, and the time from asystole to cannulation of the abdominal aorta and the start of organ-preserving perfusion. Once the entire abdominal block has been perfused, it should be explanted *en bloc*. Subsequently, the dissection and identification of the different anatomical structures can be performed in the bench surgery. It is convenient to reperfuse the pancreas through the splenic and upper mesenteric arteries, until the effluent becomes clear.

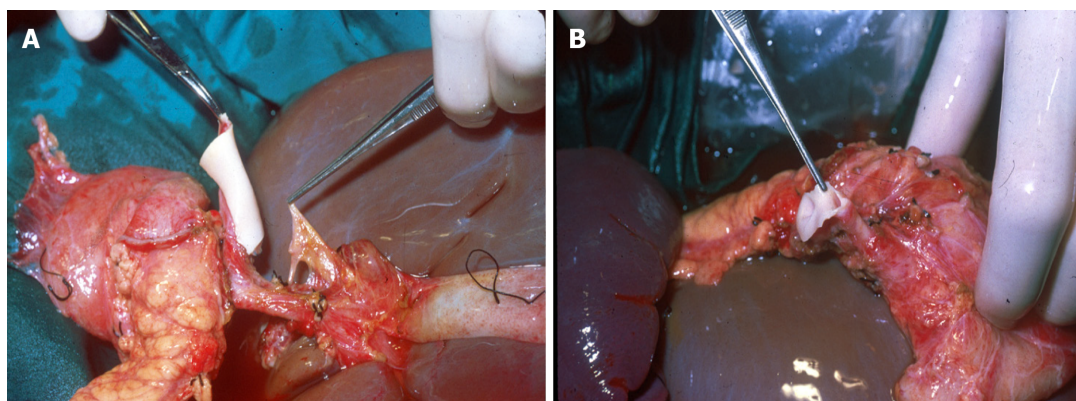
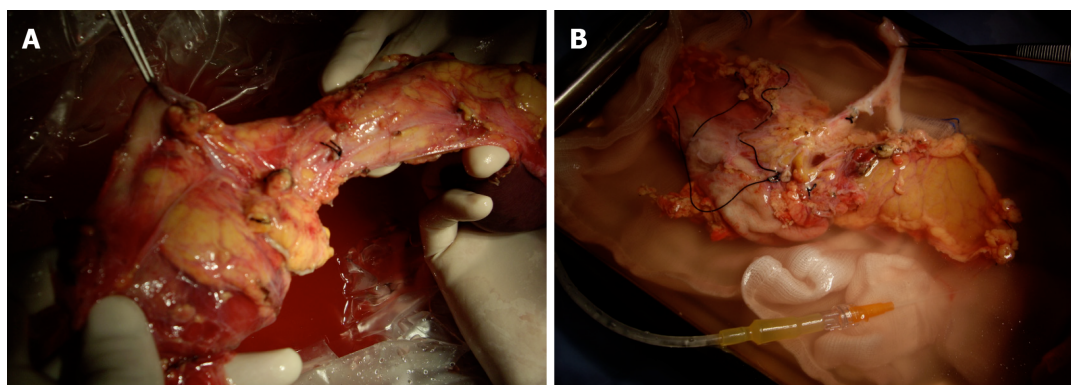
The asystole donor is considered to be at higher thrombotic risk. Pre-transplant anticoagulation with low molecular weight heparin (40 mg at 6 h before surgery) should be performed, followed by heparinization with 2500 U of unfractionated heparin before vascular clamping in the recipient.

B2-donor in asystole (DCD) (with NECMO preservation)

NECMO technology is relatively new but has emerged as a successful approach for the retrieval and preservation of organs from controlled asystole Maastricht type III donors^[36-40]. Normothermic perfusion has the potential to decrease or ameliorate ischemic injury and also facilitates the testing of graft viability, reducing the percentage of organs discarded prior to transplantation. Its use in DCDs has been proposed as superior to super-fast extraction, as it overcomes the risk of ischemia

Table 1 Risk factors

| No. of risk factors | Technical failure (%) | Graft survival (%) |
|---------------------|-----------------------|--------------------|
| 0 | 7.5 | 100 |
| 1 | 12.8 | 92.5 |
| 2 | 26.7 | 75.9 |
| 3 | 42.9 | 57.1 |

**Figure 5 Retrieval of pancreas and liver.** A and B: Intraoperative views of the retrieval procedure, showing different aspects.**Figure 6 Pancreatico-duodenal graft.** A and B: Intraoperative views of the bench preparation procedure, showing different aspects.

effects and improves the graft outcome in recipients. The demonstrated advantages are better immediate graft function, fewer post-transplant complications, shorter hospital stay, and better graft survival. These differences are especially significant in the case of liver and pancreas transplants^[41].

One of the important advantages in Spain, in particular, is that it is legally authorized to start anticoagulation maneuvers and placement of cannulas after consent for donation. This process consists of the administration of heparin (600 U/kg) and the cannulation of the femoral vessels before the withdrawal of life-sustaining therapies. The femoral artery and vein are percutaneously cannulated in the intensive care unit, using the Seldinger technique. An aortic occlusion balloon is placed through the femoral vessels in the contralateral groin to prevent cerebral and coronary perfusion during the normothermic recirculation. It is also essential to maintain a pump flow of 2-2.4 L/min^[42,43] (Figure 10).

The functional warm ischemic time (commonly known as f-WIT) for abdominal grafts is defined as the time from systolic blood pressure < 60 mmHg to the start of normothermic recirculation, including the 5-min non-touch period. A continuous pressure of 60-65 mmHg should be maintained at the femoral artery cannula, along with a temperature of 37 °C. Bicarbonate is administered immediately after the start of recirculation, to maintain pH of 7.35-7.45. Hematocrit is maintained > 25%. To avoid

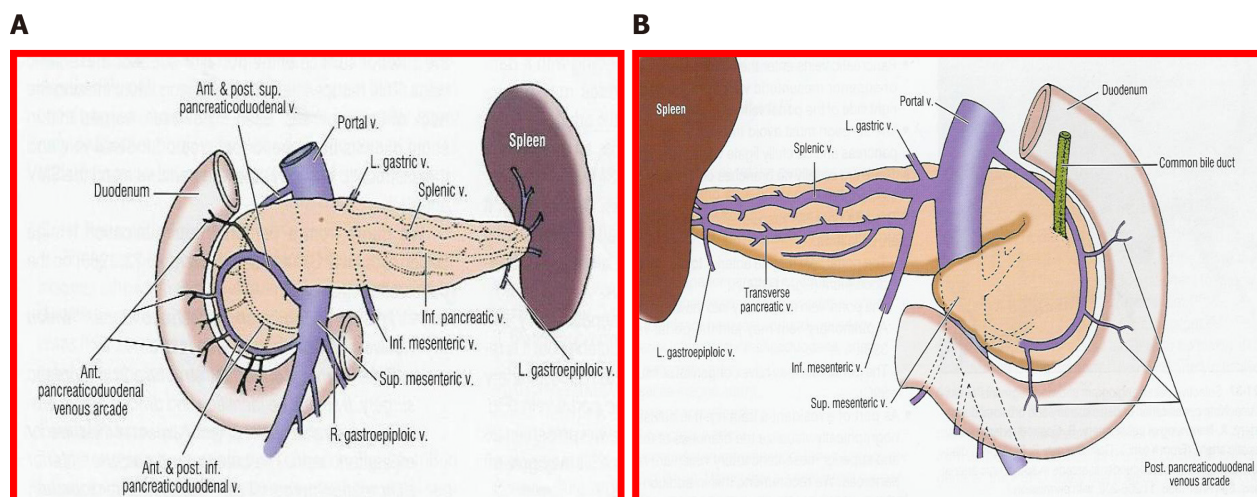


Figure 7 Venous vessels. Illustrated from the view of contemporary surgery. A: Anterior view; B: Posterior view.

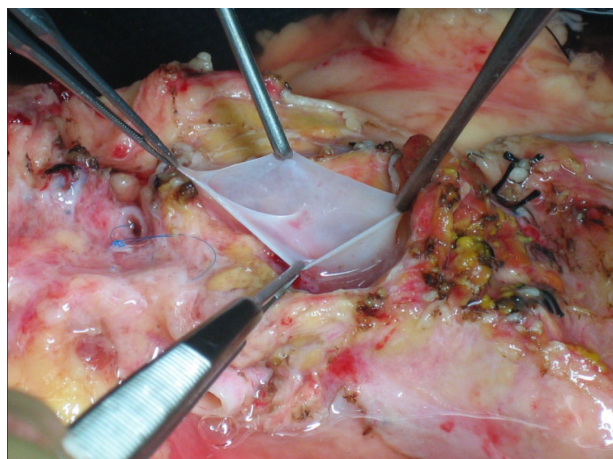


Figure 8 Portal vein.

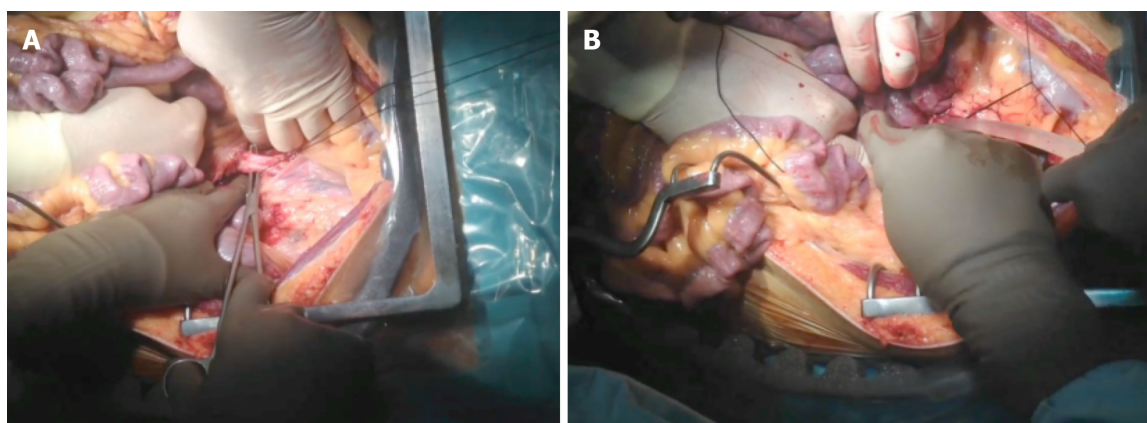


Figure 9 Aortic canula in super-fast retrieval. A and B: Intraoperative views of the procedure, showing different aspects. Photos provided by Dr Perez Daga, pancreas transplant surgeon (Malaga, Spain).

low blood flow in the pump due to the absence of venous return from the chest and head, 1-1.5 L of saline is perfused to the DCD just prior to vena cava ligation. The potential advantage is that it provides a continuous circulation that is able to improve the metabolic support during perfusion, preserving the microcirculation of the organs and thereby improving preservation. Another important aspect is that it allows the

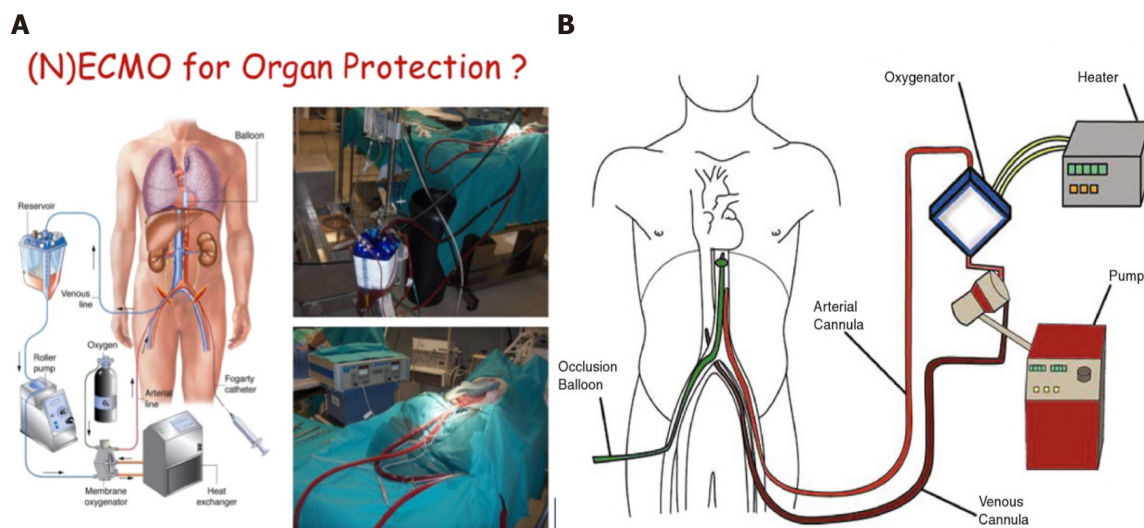


Figure 10 Normothermic circulation. A: Picture of normothermic preservation machines (NECMO); B: Diagram of NECMO. NECMO: Normothermic preservation machines.

quality of the organs to be evaluated before transplantation, especially in those organs coming from donors with expanded criteria. Finally, it reduces the risk of delayed graft function and improves the survival of the graft.

One of the complications related to the severe anticoagulation, to which these donors are subjected, is the risk of postoperative bleeding, along with the consequently required reoperation. Other complications observed include the existence of peripancreatic hematomas with risk of abdominal compartmental syndrome, especially with the use of a retroperitoneal graft technique. A compartment syndrome exists when increased pressure in a closed anatomic space threatens the viability of the tissue within the compartment^[44-47]. In these cases, the entire wound must be opened to drain the hematoma and liberate the graft from the existing pressure, since otherwise the ischemia and thrombosis of the graft is the rule. Subsequently, a negative pressure closure technique is recommended (Figure 11).

Negative-pressure wound therapy is a frequently applied open abdomen treatment. There are only few experimental data published in support of this method and describing the optimal settings and pressure distribution in the abdominal cavity during this procedure^[48-51]. The retrieval and preservation of the pancreas for transplantation is a surgical procedure that requires very high level anatomical and technical knowledge. It is necessary to remember that the pancreas is the most frequently discarded organ during donation.

CONCLUSION

Pancreas transplant is a milestone in the treatment of diabetes mellitus, for selected patients. Despite the improvement of its results in terms of patient and graft survival (similar to the transplantation of other solid organs), its complications are important and numerous, often compromising the viability of the transplant. For this reason, we must be very careful with the selection of donors and recipients, as well as with the technical aspects related to the retrieval, preservation and transplantation of the pancreas. The new techniques of retrieval and preservation of the pancreas in asystole donors have allowed us to increase the pool of donors while maintaining safety guidelines for patients.

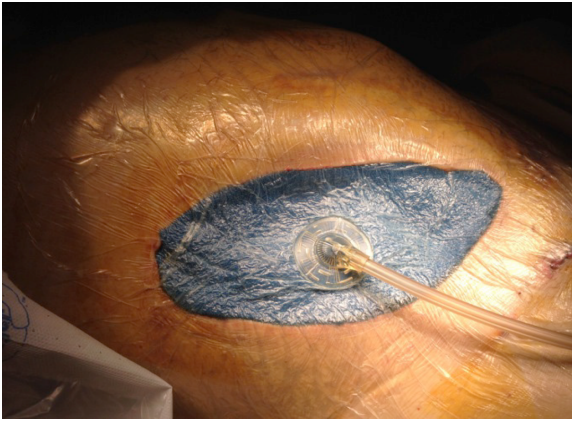


Figure 11 Negative-pressure wound therapy.

REFERENCES

- 1 **Krieger NR**, Odorico JS, Heisey DM, D'Alessandro AM, Knechtle SJ, Pirsch JD, Sollinger HW. Underutilization of pancreas donors. *Transplantation* 2003; **75**: 1271-1276 [PMID: [12717215](#) DOI: [10.1097/01.TP.0000061603.95572.BF](#)]
- 2 **Lam HD**, Schaapherder AF, Kopp WH, Putter H, Braat AE, Baranski AG. Professionalization of surgical abdominal organ recovery leading to an increase in pancreatic allografts accepted for transplantation in the Netherlands: a serial analysis. *Transpl Int* 2017; **30**: 117-123 [PMID: [27874968](#) DOI: [10.1111/tri.12893](#)]
- 3 **Wullstein C**, Woeste G, de Vries E, Persijn GG, Bechstein WO. Acceptance criteria of pancreas grafts: how do surgeons decide in Europe? *Transplant Proc* 2005; **37**: 1259-1261 [PMID: [15848688](#) DOI: [10.1016/j.transproceed.2004.12.146](#)]
- 4 **Maglione M**, Ploeg RJ, Friend PJ. Donor risk factors, retrieval technique, preservation and ischemia/reperfusion injury in pancreas transplantation. *Curr Opin Organ Transplant* 2013; **18**: 83-88 [PMID: [23254698](#) DOI: [10.1097/MOT.0b013e32835c29ef](#)]
- 5 **Gruessner AC**, Sutherland DE, Gruessner RW. Pancreas transplantation in the United States: a review. *Curr Opin Organ Transplant* 2010; **15**: 93-101 [PMID: [20009932](#) DOI: [10.1097/MOT.0b013e32833552d2](#)]
- 6 **Troppmann C**. Complications after pancreas transplantation. *Curr Opin Organ Transplant* 2010; **15**: 112-118 [PMID: [20009931](#) DOI: [10.1097/MOT.0b013e3283355349](#)]
- 7 **Goodman J**, Becker YT. Pancreas surgical complications. *Curr Opin Organ Transplant* 2009; **14**: 85-89 [PMID: [19337152](#) DOI: [10.1097/MOT.0b013e328320a8ec](#)]
- 8 **Humar A**, Ramcharan T, Kandaswamy R, Gruessner RW, Gruessner AC, Sutherland DE. Technical failures after pancreas transplants: why grafts fail and the risk factors--a multivariate analysis. *Transplantation* 2004; **78**: 1188-1192 [PMID: [15502718](#) DOI: [10.1097/01.tp.0000137198.09182.a2](#)]
- 9 **Brockmann JG**, Vaidya A, Reddy S, Friend PJ. Retrieval of abdominal organs for transplantation. *Br J Surg* 2006; **93**: 133-146 [PMID: [16432811](#) DOI: [10.1002/bjs.5228](#)]
- 10 **Marsh CL**, Perkins JD, Sutherland DE, Corry RJ, Sterioff S. Combined hepatic and pancreaticoduodenal procurement for transplantation. *Surg Gynecol Obstet* 1989; **168**: 254-258 [PMID: [2645667](#)]
- 11 **Dunn DL**, Morel P, Schlumpf R, Mayoral JL, Gillingham KJ, Moudry-Munns KC, Krom RA, Gruessner RW, Payne WD, Sutherland DE. Evidence that combined procurement of pancreas and liver grafts does not affect transplant outcome. *Transplantation* 1991; **51**: 150-157 [PMID: [1987684](#) DOI: [10.1097/00007890-199101000-00023](#)]
- 12 **Sanseverino R**, Martin X, Caldara R, Faure JL, Lefrancois N, Dubernard JM. Technique of pancreas revascularization after combined liver and pancreas harvesting in the same cadaveric donor. *Clin Transplant* 1991; **5**: 55-59 [PMID: [10147635](#)]
- 13 **Fridell JA**, Powelson JA, Kubal CA, Burke GW, Sageshima J, Rogers J, Stratta RJ. Retrieval of the pancreas allograft for whole-organ transplantation. *Clin Transplant* 2014; **28**: 1313-1330 [PMID: [25203627](#) DOI: [10.1111/ctr.12459](#)]
- 14 **Fernández ED**, Schmid M, Schlosser K, Mauer D; Working Group of the Organ Procurement Central Region of the German Foundation for Organ Transplantation (DSO). Technical complications in organ procurement. *Transplant Proc* 2007; **39**: 2975-2976 [PMID: [18089303](#) DOI: [10.1016/j.transproceed.2007.07.092](#)]
- 15 **Molmenti EP**, Klein AS, Henry ML. Procurement of liver and pancreas allografts in donors with replaced/accessory right hepatic arteries. *Transplantation* 2004; **78**: 770-771 [PMID: [15371686](#) DOI: [10.1097/01.tp.0000132785.96091.d9](#)]
- 16 **Ames SA**, Kisthard JK, Smith JL, Piper JB, Corry RJ. Successful combined hepatic and pancreatic allograft retrieval in donors with a replaced right hepatic artery. *Surg Gynecol Obstet* 1991; **173**: 216-

- 222 [PMID: [1925883](#)]
- 17 **Baranski AG**, Lam HD, Braat AE, Schaapherder AF. The dorsal pancreatic artery in pancreas procurement and transplantation: anatomical considerations and potential implications. *Clin Transplant* 2016; **30**: 1360-1364 [PMID: [27555344](#) DOI: [10.1111/ctr.12814](#)]
 - 18 **Marang-van de Mheen PJ**, Hilling DE, Dirkes MC, Baranski AG. Surgical injuries of pancreatic allografts during procurement. *Clin Transplant* 2011; **25**: 737-743 [PMID: [20973826](#) DOI: [10.1111/j.1399-0012.2010.01335.x](#)]
 - 19 **Fridell JA**, Powelson JA, Sanders CE, Ciancio G, Burke GW 3rd, Stratta RJ. Preparation of the pancreas allograft for transplantation. *Clin Transplant* 2011; **25**: E103-E112 [PMID: [21362047](#) DOI: [10.1111/j.1399-0012.2011.01414.x](#)]
 - 20 **Wright FH**, Wright C, Ames SA, Smith JL, Corry RJ. Pancreatic allograft thrombosis: donor and retrieval factors and early postperfusion graft function. *Transplant Proc* 1990; **22**: 439-441 [PMID: [1691538](#)]
 - 21 **Humar A**, Kandaswamy R, Drangstveit MB, Parr E, Gruessner AG, Sutherland DE. Prolonged preservation increases surgical complications after pancreas transplants. *Surgery* 2000; **127**: 545-551 [PMID: [10819063](#) DOI: [10.1067/msy.2000.104742](#)]
 - 22 **Sollinger HW**, Vernon WB, D'Alessandro AM, Kalayoglu M, Stratta RJ, Belzer FO. Combined liver and pancreas procurement with Belzer-UW solution. *Surgery* 1989; **106**: 685-690; discussion 690 [PMID: [2799643](#)]
 - 23 **Boggi U**, Vistoli F, Del Chiaro M, Signori S, Croce C, Pietrabissa A, Berchiolli R, Marchetti P, Del Prato S, Mosca F. Pancreas preservation with University of Wisconsin and Celsior solutions: a single-center, prospective, randomized pilot study. *Transplantation* 2004; **77**: 1186-1190 [PMID: [15114082](#) DOI: [10.1097/01.tp.0000120535.89925.ca](#)]
 - 24 **Parsons RF**, Guarrera JV. Preservation solutions for static cold storage of abdominal allografts: which is best? *Curr Opin Organ Transplant* 2014; **19**: 100-107 [PMID: [24553501](#) DOI: [10.1097/MOT.0000000000000063](#)]
 - 25 **Voigt MR**, DeLario GT. Perspectives on abdominal organ preservation solutions: a comparative literature review. *Prog Transplant* 2013; **23**: 383-391 [PMID: [24311404](#) DOI: [10.7182/pit2013100](#)]
 - 26 **Potdar S**, Malek S, Eghtesad B, Shapiro R, Basu A, Patel K, Broznick B, Fung J. Initial experience using histidine-tryptophan-ketoglutarate solution in clinical pancreas transplantation. *Clin Transplant* 2004; **18**: 661-665 [PMID: [15516240](#) DOI: [10.1111/j.1399-0012.2004.00262.x](#)]
 - 27 **Agarwal A**, Powelson JA, Goggins WC, Milgrom ML, Fridell JA. Organ preservation with histidine-tryptophan ketoglutarate solution in clinical pancreas transplantation: an update of the indiana university experience. *Transplant Proc* 2008; **40**: 498-501 [PMID: [18374113](#) DOI: [10.1016/j.transproceed.2008.01.011](#)]
 - 28 **Baertschiger RM**, Berney T, Morel P. Organ preservation in pancreas and islet transplantation. *Curr Opin Organ Transplant* 2008; **13**: 59-66 [PMID: [18660708](#) DOI: [10.1097/MOT.0b013e3282f44a63](#)]
 - 29 **Muthusamy AS**, Mumford L, Hudson A, Fuggle SV, Friend PJ. Pancreas transplantation from donors after circulatory death from the United Kingdom. *Am J Transplant* 2012; **12**: 2150-2156 [PMID: [22845910](#) DOI: [10.1111/j.1600-6143.2012.04075.x](#)]
 - 30 **Qureshi MS**, Callaghan CJ, Bradley JA, Watson CJ, Pettigrew GJ. Outcomes of simultaneous pancreas-kidney transplantation from brain-dead and controlled circulatory death donors. *Br J Surg* 2012; **99**: 831-838 [PMID: [22437616](#) DOI: [10.1002/bjs.8733](#)]
 - 31 **Salvalaggio PR**, Davies DB, Fernandez LA, Kaufman DB. Outcomes of pancreas transplantation in the United States using cardiac-death donors. *Am J Transplant* 2006; **6**: 1059-1065 [PMID: [16611344](#) DOI: [10.1111/j.1600-6143.2006.01310.x](#)]
 - 32 **Fernandez LA**, Di Carlo A, Odorico JS, Levenson GE, Shames BD, Becker YT, Chin LT, Pirsch JD, Knechtle SJ, Foley DP, Sollinger HW, D'Alessandro AM. Simultaneous pancreas-kidney transplantation from donation after cardiac death: successful long-term outcomes. *Ann Surg* 2005; **242**: 716-723 [PMID: [16244546](#) DOI: [10.1097/01.sla.0000186175.84788.50](#)]
 - 33 **Boggi U**, Vistoli F, Del Chiaro M, Signori S, Pietrabissa A, Costa A, Bartolo TV, Catalano G, Marchetti P, Del Prato S, Rizzo G, Jovine E, Pinna AD, Filipponi F, Mosca F. A simplified technique for the en bloc procurement of abdominal organs that is suitable for pancreas and small-bowel transplantation. *Surgery* 2004; **135**: 629-641 [PMID: [15179369](#) DOI: [10.1016/j.surg.2003.10.011](#)]
 - 34 **Jeon H**, Ortiz JA, Manzarbeitia CY, Alvarez SC, Sutherland DE, Reich DJ. Combined liver and pancreas procurement from a controlled non-heart-beating donor with aberrant hepatic arterial anatomy. *Transplantation* 2002; **74**: 1636-1639 [PMID: [12490801](#) DOI: [10.1097/00007890-200212150-00025](#)]
 - 35 **de Boer JD**, Kopp WH, Ooms K, Haase-Kromwijk BJ, Krikke C, de Jonge J, van Heurn LW, Baranski AG, van der Vliet JA, Braat AE. Abdominal organ procurement in the Netherlands - an analysis of quality and clinical impact. *Transpl Int* 2017; **30**: 288-294 [PMID: [27992973](#) DOI: [10.1111/tri.12906](#)]
 - 36 **Reich DJ**, Mulligan DC, Abt PL, Pruett TL, Abecassis MM, D'Alessandro A, Pomfret EA, Freeman RB, Markmann JF, Hanto DW, Matas AJ, Roberts JP, Merion RM, Klintmalm GB; ASTS Standards on Organ Transplantation Committee. ASTS recommended practice guidelines for controlled donation after cardiac death organ procurement and transplantation. *Am J Transplant* 2009; **9**: 2004-2011 [PMID: [19624569](#) DOI: [10.1111/j.1600-6143.2009.02739.x](#)]
 - 37 **Hessheimer AJ**, Billault C, Barrou B, Fondevila C. Hypothermic or normothermic abdominal regional perfusion in high-risk donors with extended warm ischemia times: impact on outcomes?

- Transpl Int* 2015; **28**: 700-707 [PMID: 24797796 DOI: 10.1111/tri.12344]
- 38 **Miñambres E**, Rubio JJ, Coll E, Domínguez-Gil B. Donation after circulatory death and its expansion in Spain. *Curr Opin Organ Transplant* 2018; **23**: 120-129 [PMID: 29120882 DOI: 10.1097/MOT.0000000000000480]
 - 39 **Brogi E**, Circelli A, Gamberini E, Russo E, Benni M, Pizzilli G, Agnoletti V. Normothermic Regional Perfusion for Controlled Donation After Circulatory Death: A Technical Complication During Normothermic Regional Perfusion. *ASAIO J* 2020; **66**: e19-e21 [PMID: 31085950 DOI: 10.1097/MAT.0000000000000963]
 - 40 **Oniscu GC**, Randle LV, Muiesan P, Butler AJ, Currie IS, Perera MT, Forsythe JL, Watson CJ. In situ normothermic regional perfusion for controlled donation after circulatory death--the United Kingdom experience. *Am J Transplant* 2014; **14**: 2846-2854 [PMID: 25283987 DOI: 10.1111/ajt.12927]
 - 41 **Barlow AD**, Hosgood SA, Nicholson ML. Current state of pancreas preservation and implications for DCD pancreas transplantation. *Transplantation* 2013; **95**: 1419-1424 [PMID: 23579769 DOI: 10.1097/TP.0b013e318285558f]
 - 42 **Miñambres E**, Suberviola B, Domínguez-Gil B, Rodrigo E, Ruiz-San Millan JC, Rodríguez-San Juan JC, Ballesteros MA. Improving the Outcomes of Organs Obtained From Controlled Donation After Circulatory Death Donors Using Abdominal Normothermic Regional Perfusion. *Am J Transplant* 2017; **17**: 2165-2172 [PMID: 28141909 DOI: 10.1111/ajt.14214]
 - 43 **Butler AJ**, Randle LV, Watson CJ. Normothermic regional perfusion for donation after circulatory death without prior heparinization. *Transplantation* 2014; **97**: 1272-1278 [PMID: 24646774 DOI: 10.1097/TP.0000000000000082]
 - 44 **Pineda-Solís K**, Xie WY, McAlister V, Sener A, Luke PP. Retroperitoneal Compartment Syndrome in Renal Transplantation: How to Salvage the Graft? *Urology* 2017; **107**: 268 [PMID: 28982622 DOI: 10.1016/j.urology.2017.05.015]
 - 45 **Ortiz J**, Parsikia A, Horrow MM, Khanmoradi K, Campos S, Zaki R. Risk factors for renal allograft compartment syndrome. *Int Surg* 2014; **99**: 851-856 [PMID: 25437599 DOI: 10.9738/INTSURG-D-13-00214.1]
 - 46 **Handschin AE**, Weber M, Renner E, Clavien PA. Abdominal compartment syndrome after liver transplantation. *Liver Transpl* 2005; **11**: 98-100 [PMID: 15690542 DOI: 10.1002/Lt.20295]
 - 47 **Michalska M**, Wen K, Pauly RP. Acute Kidney Injury in Pregnant Patient With Pancreas-Kidney Transplant Caused by Abdominal Compartment Syndrome: A Case Presentation, Review of Literature, and Proposal of Diagnostic Approach. *Can J Kidney Health Dis* 2019; **6**: 2054358119861942 [PMID: 31384476 DOI: 10.1177/2054358119861942]
 - 48 **Wang TY**, Elliott R, Low DW. Damage control abdomen: single-stage reconstruction using a vicryl mesh buttress. *Ann Plast Surg* 2013; **70**: 324-330 [PMID: 22791067 DOI: 10.1097/SAP.0b013e3182361af9]
 - 49 **Ghazi B**, Deigni O, Yezhelyev M, Losken A. Current options in the management of complex abdominal wall defects. *Ann Plast Surg* 2011; **66**: 488-492 [PMID: 21372667 DOI: 10.1097/SAP.0b013e31820d18db]
 - 50 **Smith CT**, Katz MG, Foley D, Welch B, Levenson GE, Funk LM, Greenberg JA. Incidence and risk factors of incisional hernia formation following abdominal organ transplantation. *Surg Endosc* 2015; **29**: 398-404 [PMID: 25125093 DOI: 10.1007/s00464-014-3682-8]
 - 51 **Huang C**, Leavitt T, Bayer LR, Orgill DP. Effect of negative pressure wound therapy on wound healing. *Curr Probl Surg* 2014; **51**: 301-331 [PMID: 24935079 DOI: 10.1067/j.cpsurg.2014.04.001]



Published by **Baishideng Publishing Group Inc**
7041 Koll Center Parkway, Suite 160, Pleasanton, CA 94566, USA

Telephone: +1-925-3991568

E-mail: bpgoffice@wjgnet.com

Help Desk: <https://www.f6publishing.com/helpdesk>

<https://www.wjgnet.com>

