

68886\_Auto\_Edited -check.docx

## Crouzon syndrome in a fraternal twin: A case report and review of the literature

Li XJ *et al.* CS of a fraternal twin

Xiao-Jing Li, Ji-Mei Su, Xiao-Wei Ye

### Abstract

#### BACKGROUND

Crouzon syndrome (CS, OMIM 123500) is an autosomal dominant inherited craniofacial disorder caused by mutations in *fibroblast growth factor receptor 2* (FGFR2) gene. CS is characterized by craniofacial dysostosis, exophthalmos, and facial anomalies with hypoplastic maxilla and relative mandibular prognathism.

#### CASE SUMMARY

Our report involves a 6-year-old fraternal twin boy with many caries in the oral cavity who presented with characteristic features of CS based on clinical and radiographic examinations along with Sanger sequencing. The fraternal girl did not show any abnormalities indicating CS. Carious teeth and poor oral hygiene were managed promptly through administering appropriate behavior guidance, orthodontic treatment was planned, and preventive procedures were described.

#### CONCLUSION

CS could occur in a fraternal twin caused by a de novo mutation of the FGFR2 gene. For the treatment, oral hygiene instruction, preventive programs on oral hygiene, orthodontic treatment, and maxillary osteotomy were required.

**Key Words:** Crouzon syndrome; Craniosynostosis; *Fibroblast growth factor receptor 2*; Mutation; Fraternal twin; Case report

Li XJ, Su JM, Ye XW. Crouzon syndrome in a fraternal twin: A case report and review of the literature. *World J Clin Cases* 2022; In press

**Core Tip:** Crouzon syndrome (CS) is an autosomal dominant inherited craniofacial disorder caused by mutations in *fibroblast growth factor receptor 2*, but approximately 50% of cases result from de novo mutations. Rarely has this syndrome been seen and evaluated in fraternal twins, only one of whom has CS. We presented a 6-year-old fraternal twin boy diagnosed as CS who had many caries and enamel hypomineralization in the oral cavity. The boy's parents and his fraternal twin sister did not show any abnormalities indicating CS, so we speculate that the fraternal twin boy's gene mutation arose from a de novo mutation.

## INTRODUCTION

Crouzon syndrome (CS) is an autosomal dominant inherited disorder and characterized by calvarial deformities with craniofacial dysostosis, exophthalmos, and facial anomalies<sup>[1,2]</sup>. In 1912, the French physician Louis Edouard Octave Crouzon firstly reported this syndrome, who identified a mother and her son with craniosynostosis that resulted in skull and facial deformities<sup>[3]</sup>. This syndrome is described as the mildest type of many craniosynostosis syndromes<sup>[3,4]</sup>. The birth incidence of CS is approximately 1:25000<sup>[4]</sup>. It is proved to be the most common craniosynostosis syndrome, as it accounts for nearly 4.8% of all craniosynostosis cases at birth<sup>[1,5]</sup>. It is more common in males than females (3:1)<sup>[6]</sup>. Mutations in the *fibroblast growth factor receptor 2* (FGFR2) gene on chromosome locus 10q25.3-q26 are related to CS<sup>[7]</sup>. Families with CS commonly suggest an autosomal dominant inheritance pattern<sup>[8,9]</sup>. The syndrome presents incomplete penetrance and variable expressivity leading to phenotypical characteristics varying from mild to severe<sup>[7,10]</sup>. About 50% of cases are resulting from de novo mutations of FGFR2 gene<sup>[11]</sup>.

CS is commonly observed at birth owing to characteristic facial and cranial deformities and a positive family history. The prominent manifestations of these

patients can be detected upon physical examination. Brachycephaly, hypertelorism, proptosis, flattened forehead, beaked noses, and maxillary/midface hypoplasia are the most common features<sup>[3,12-14]</sup>. Hearing loss, strabismus (misaligned eyes), a cleft lip and palate, and dental problems can be also seen from these patients<sup>[12,15,16]</sup>. However, Crouzon patients have normal hands and feet, in contrast to Apert syndrome patients and other craniosynostosis syndromes<sup>[17,18]</sup>. The different characteristics of the more common syndromic craniosynostosis syndromes are shown in Table 1<sup>[17,19-22]</sup>.

The most common dental problems in craniosynostosis are supernumerary teeth, hypodontia, delayed eruption, and macrodontia<sup>[23,24]</sup>. We report a 6-year-old fraternal twin boy with CS who had many caries and enamel hypomineralization in the oral cavity. The boy's parents and his fraternal twin sister did not show any abnormalities indicating CS, so we think that the twin boy's gene mutation arose from a de novo mutation.

## **CASE PRESENTATION**

### ***Chief complaints***

A 6-year-old Chinese boy was referred to the stomatology department of the Children's Hospital, Zhejiang University School of Medicine, with a chief complaint of dental caries.

### ***History of present illness***

Dental caries were observed since the patient was 4 years old, and gradually became progressively larger.

### ***History of past illness***

The patient underwent intracranial decompression surgery at the age of one due to hydrocephalus. Posterior cranial vault distraction was performed when he was 2 years old. The patient underwent a ventriculoperitoneal shunt operation for hydrocephalus at

the age of 3. One year later, the patient had cranial vault remodeling as a result of craniofacial dysostosis.

### *Personal and family history*

His medical and developmental history showed that he was born at full-term by cesarean delivery after an uneventful pregnancy with a 48 cm height and 2.35 kg weight, along with his fraternal twin sister with a 48 cm height and 1.8 kg weight. The family history of going back for three generations was negative for similar conditions, and his fraternal twin sister had no medical issues.

### *Physical examination*

Physical examination showed normal height (108 cm) and weight (20.4 kg) compared with that of children of the same age. Clinically normal hands and feet were found. Extraoral examination revealed a prominent forehead, eyelid ptosis, ocular proptosis, shallow eye sockets, hypertelorism, midface hypoplasia, and a retrusive upper lip and protrusive lower lip (Figure 1).

Intraoral examination showed that the patient was in early mixed dentition, with all deciduous canines and molar teeth present in the maxillary and mandibular arch. The chronology of eruption and eruption status was in accordance with the child's age (Figure 1). The oral hygiene of the child was poor with scattered pigmentation on the teeth, and permanent teeth 36, 46 and deciduous teeth 54, 55, 65, 74, 75, and 85 were mostly decayed. The eruptive permanent teeth, including 11, 21, 36, and 46, showed enamel hypomineralization. The maxillary arch was constricted, and the anterior cross bite and open bite are shown.

### *Laboratory examinations*

Sanger sequencing showed that the pathogenic variant c.1026C > G (p.Cys342Trp) was present on the *FGFR2* for the patient. The mutation was not present in any of the family members.

### *Imaging examinations*

The panoramic radiograph showed that there were no supernumerary teeth or normal permanent tooth germ development. Deciduous carious teeth 55, 64, 65, 75 and 85 had once been restored, and displayed further second caries at the time of the study. Permanent teeth 36 and 46 and deciduous teeth 54 and 74 were decayed (Figure 2A).

Based on the lateral cephalometric analysis, a severe skeletal Class III relationship was diagnosed with Sella-Nasion-A point angle:  $63.8^{\circ}$ , Sella-Nasion-B point angle:  $71.6^{\circ}$ , A point-Nasion-B point angle:  $-7.8^{\circ}$  (Figure 2B). A hypodivergent facial pattern was showed with Sella-Nasion/Gonion-Gnathion:  $35.1^{\circ}$ . The cephalometric analysis also revealed the maxillary skeletal size (condylion to point A) was diminished. The upper central incisors leaned toward the lip (U1/Sella-Nasion:  $112.8^{\circ}$ ).

### **FINAL DIAGNOSIS**

The final diagnosis of the presented case is CS, caries, and enamel hypomineralization.

### **TREATMENT**

A comprehensive treatment plan was made. The initial treatment involved improving the patient's oral hygiene and restoring his carious teeth. The dental caries in teeth 54, 55, 64, 65, 74, 75, 85, 36, and 46 were treated with resin-based restorations. Topical fluoride was regularly applied to enamel hypomineralization in teeth 11, 21, 36, 46 to promote enamel remineralization. The Skeletal Class III malocclusion was treated by orthodontic treatment and orthognathic surgery. Multidisciplinary approaches involving pediatric dentists, dental surgeons, oral and maxillofacial surgeons, and orthodontists were indispensable for this treatment.

At the first dental visit, the patient was nervous and fearful, and was unwilling to open his mouth. Appropriately administered behavior management and guidance<sup>[25,26]</sup>, including show-and-tell tactics, positive reinforcement, sound communication and modeling, was used to manage the patient's anxieties. Oral examination, radiographic



assessment, oral prophylaxis, and polishing of the teeth with the rubber cup were performed during the first dental appointment. For the latter dental appointments, carious restoration was successfully completed utilizing show-and-tell tactics, positive reinforcement, and distraction the patient by showing movies during the procedure. After the procedure, the patient was praised and given a post-visit sticker, and he was agreeable for a future visit.

## OUTCOME AND FOLLOW-UP

Three months later, the oral hygiene of the patient was good, and topical fluoride was applied in teeth 11, 21, 36, 46 to promote enamel remineralization.

## DISCUSSION

<sup>11</sup>Craniostygnosis results from the premature fusion of one or multiple cranial sutures, resulting in <sup>2</sup>restricted growth of the skull, brain, face, and central nervous system development<sup>[4]</sup>. CS <sup>14</sup>is the most common syndromic craniostygnosis, caused by the mutation of *FGFR2*<sup>[17]</sup>. *FGFR2* belongs to a family of four *FGFRs*. <sup>2</sup>*FGFRs* play a primary role in the growth and differentiation of mesenchymal and neuroectodermal cells by binding to FGF and initiating signal transduction. Additionally, *FGFRs* regulate cranial suture fusion on a macroscopic level<sup>[7]</sup>.

For our patient the c.1026 C>G (p.Cys342Trp) mutation on the *FGFR2* gene caused a cysteine-to-tryptophan substitution at amino acid 342. Mutations at amino acid 342 can cause CS and Pfeiffer syndrome. Normal hands and feet can be observed with CS, which differentiates it from Pfeiffer syndrome. The loss of this cysteine residue is one of the most common mutations in CS patients and has previously been reported in a Chinese family, a Japanese sporadic case, and four Caucasian cases<sup>[9,27-29]</sup>. The Chinese family and one Caucasian family with CS have a dominant inherited amino acid 342 mutation<sup>[9,27]</sup>. The Japanese case and the German patients with CS were sporadic<sup>[28,29]</sup>. Since the fraternal twin sister and the parents did not present gene mutations and similar presentations, our patient's mutation was considered to be a de novo mutation.

In 11 of the 21 families with CS who underwent tracing to determine the origin of the mutation by analyzing parents and the other family members, *FGFR2* mutations arose de novo, representing a high mutation rate for *FGFR2*<sup>[29]</sup>.

<sup>13</sup> This case report describes a patient with CS, who presented with a high forehead, ocular proptosis, shallow eye sockets, hypertelorism, palpebral ptosis and a skeletal Class III relationship. The carious teeth were fully restored, and oral hygiene instruction was performed in the clinic under behavior management and guidance. The child was advised to follow-up regularly with preventive care for teeth. The boy was satisfied with his good oral hygiene. Interceptive orthodontics was contemplated. <sup>4</sup> Midfacial advancement with a Le Fort III, Le Fort II plus zygomatic repositioning, monobloc, or facial bipartition is required for midface retrusion<sup>[30]</sup>. The appropriate time of surgery is deemed at 8 years of age<sup>[31]</sup>. <sup>1</sup> He has been referred to the Department of Oral and Maxillofacial Surgery for orthognathic surgical procedures in the next few years. He has also been referred to the Departments of Neurosurgery, Ophthalmology, E.N.T. and psychology to prevent complications.

## CONCLUSION

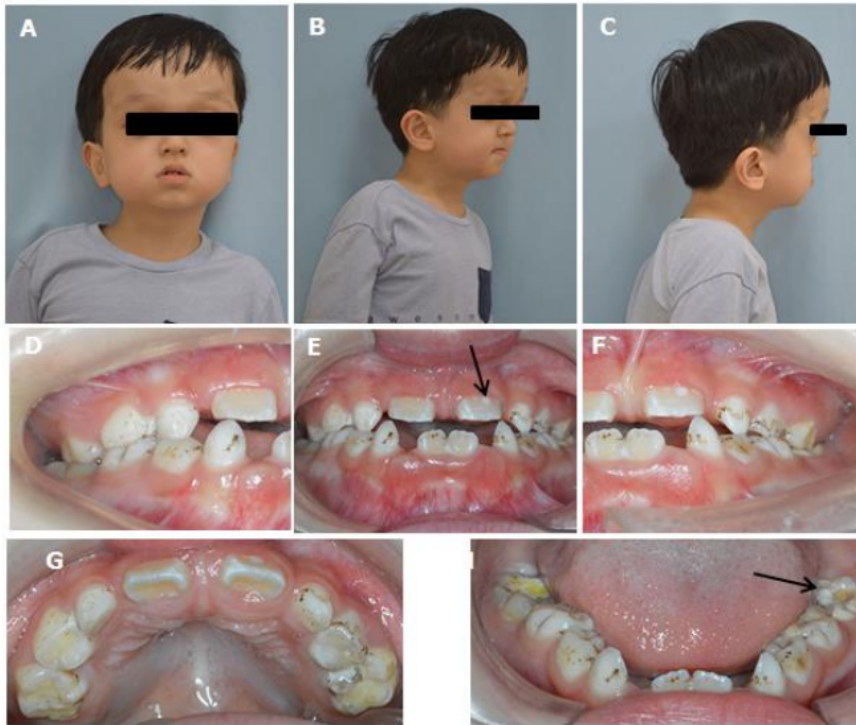
In summary, CS could occur in a fraternal twin <sup>7</sup> caused by a de novo mutation of the *FGFR2* gene, characterized by craniosynostosis, a prominent forehead, midface hypoplasia, and prortosis. Oral hygiene instruction and preventive programs on oral hygiene should be performed regularly. A multidisciplinary approach involving oral and maxillofacial surgeons, and orthodontists was necessary for the treatment of midface hypoplasia.

## ACKNOWLEDGEMENTS

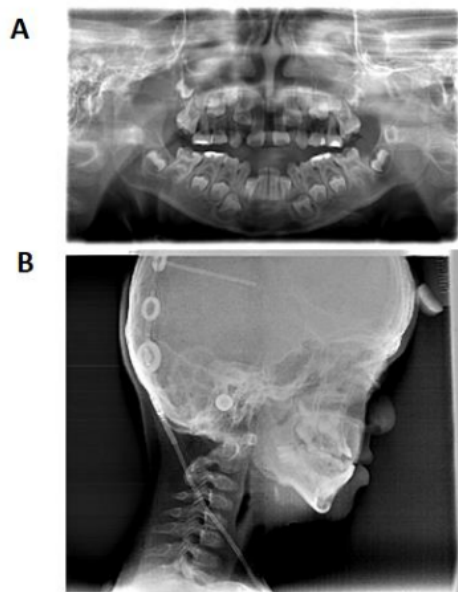
We sincerely thank the patient and his parents for their participation and permission to publish this paper.

## Figure Legends





**Figure 1 Extroral and Introral presentations of the patient.** A-C: Extraoral photos showed a prominent forehead, ocular proptosis, midface hypoplasia, retrusive upper lip and protrusive lower lip; D-H: The intraoral photos showed that oral hygiene was poor with scattered pigmentation on the teeth, 36, 46, 54, 55, 65, 74, 75, 85 were decayed and 11, 21, 36, 46 showed hypomineralization (black arrows).



**Figure 2** The panoramic and lateral cephalometric radiograph of the patient. A: The panoramic radiograph showed normal permanent tooth germ development; B: The lateral cephalometric radiograph showed a skeletal Class III relationship.

**Table 1 Clinical characteristics of the most common syndromic craniosynostosis syndromes**

	Crouzon	Apert	Pfeiffer	Muenke	Saethre-Chotzen
Gene	FGFR2	FGFR2	FGFR1/FGFR2	FGFR3	TWIST1
Craniofacial Phenotype	Brachycephaly; shallow orbits; ocular proptosis; midface hypoplasia	Turribrachycephaly; large anterior fontanelle bitemporal widening and occipital flattening; shallow orbits with ocular proptosis and horizontal grooves above supraorbital ridges; mild hypertelorism and down-slanting palpebral fissures; "parrot beak" nasal deformity	Turribrachycephaly; midface hypoplasia; proptosis; hypertelorism; strabismus; down- slanting palpebral fissures; beaked nasal deformity	Craniosynostosis of coronal sutures; uncommon to have midface hypoplasia	Brachycephaly or acrocephaly anterior plagiocephaly; low frontal hairline; eyelid ptosis; facial asymmetry; deviated nasal septum; ear deformities; parietal foramina
Oral dental Phenotype	Constricted, high-arched anterior open bite; Missing teeth; supernumerary; delayed tooth fusion;	High arched or cleft palate; severe midface hypoplasia; open bite; tooth agenesis; supernumerary teeth; dental fusion; delayed	Anterior open bit and bilateral posterior cross- bites; hypodontia; microdontia; dilacerations; radicular dentin dysplasia	High arched palate; the lowest incidence of cleft palate	Cleft palate

	eruption	tooth eruption	
Limb	Normal hands and feet	Severe 20 syndactyly(mitten hand); poor joint mobility	10 Broad thumbs; broad great toes; variable feature, partial soft-tissue syndactyly of the hands; ankylozed elbows; hydrocephalus
Phenotype			Thimble-like middle phalanges
			Brachydactyly; syndactyly; radioulnar synostosis; Hallux valgus
Other			
Phenotype		Low-set ears	Hearing loss; congenital heart malformation; short stature
			Hearing anomalies
Cognition	Normal	Intellectual disability	Normal
			Normal or nearly normal

FGFR: *Fibroblast growth factor receptor*.

# 15%

SIMILARITY INDEX

### PRIMARY SOURCES

- 1

[www.ncbi.nlm.nih.gov](http://www.ncbi.nlm.nih.gov)  
Internet

61 words — 3%
- 2

N.M. Al-Namnam, F. Hariri, M.K. Thong, Z.A. Rahman. "Crouzon syndrome: Genetic and intervention review", Journal of Oral Biology and Craniofacial Research, 2019  
Crossref

49 words — 2%
- 3

[dokumen.pub](http://dokumen.pub)  
Internet

29 words — 1%
- 4

[pubmed.ncbi.nlm.nih.gov](http://pubmed.ncbi.nlm.nih.gov)  
Internet

25 words — 1%
- 5

[www.wjgnet.com](http://www.wjgnet.com)  
Internet

23 words — 1%
- 6

Abhiyanth S Shetty. "Benefits of Fixed Orthodontic Appliances on Growth and Development in Pediatric Patients with Class III Malocclusion", Journal of Dental Health, Oral Disorders & Therapy, 2017  
Crossref

22 words — 1%
- 7

Peter De Coster, Guy De Pauw, Luc Martens, Anne De Paepe. "Craniofacial structure in Marfan syndrome: A cephalometric study", American Journal of Medical Genetics, 2004  
Crossref

16 words — 1%

8

dc.uthsc.edu

Internet

16 words — 1%

9

gradesfixer.com

Internet

13 words — 1%

10

J. I. Harper. "Genetics and Genodermatoses", Rook's Textbook of Dermatology, 01/01/2004

Crossref

12 words — 1%

11

Anna Kutkowska-Kaźmierczak, Monika Gos, Ewa Obersztyn. "Craniosynostosis as a clinical and diagnostic problem: molecular pathology and genetic counseling", Journal of Applied Genetics, 2018

Crossref

11 words — &lt; 1%

12

Mathijssen, Irene M.J.. "Guideline for Care of Patients With the Diagnoses of Craniosynostosis : Working Group on Craniosynostosis", Journal of Craniofacial Surgery, 2015.

Crossref

9 words — &lt; 1%

13

M. J. Papagrigorakis, M. Karamolegou, G. Vilos, C. Apostolidis, K. Karamesinis, P. N. Synodinos. "Auriculo-condylar syndrome", The Angle Orthodontist, 2012

Crossref

8 words — &lt; 1%

14

Nneamaka Barbara Agochukwu, Benjamin D. Solomon, Emily S. Doherty, Maximilian Muenke. "Palatal and Oral Manifestations of Muenke Syndrome (FGFR3-Related Craniosynostosis)", Journal of Craniofacial Surgery, 2012

Crossref

8 words — &lt; 1%

15

Steven L. Singer. "Dentofacial features of a family with Crouzon syndrome. Case reports", Australian Dental Journal, 2/1997

8 words — &lt; 1%



- 
- 16 doku.pub  
Internet 8 words — < 1%
- 
- 17 Bowling, E.L.. "Crouzon syndrome", Optometry - Journal of the American Optometric Association, 200605  
Crossref 6 words — < 1%
- 
- 18 Clair A. Francomano. "Skeletal Dysplasias: Craniosynostosis Syndromes and Skeletal Dysplasias Caused by Mutations in Fibroblast Growth Factor Receptor Genes", Connective Tissue and Its Heritable Disorders, 05/10/2002  
Crossref 6 words — < 1%
- 
- 19 Jesse A. Taylor, Scott P. Bartlett. "What's New in Syndromic Craniosynostosis Surgery?", Plastic and Reconstructive Surgery, 2017  
Crossref 6 words — < 1%
- 
- 20 Yazan Hassona, Abeer Al-Hadidi, Thaer Abu Ghlassi, Hanin El Dali, Crispian Scully. "Pfeiffer syndrome: oral healthcare management and description of new dental findings in a craniosynostosis", Special Care in Dentistry, 2017  
Crossref 6 words — < 1%
-