



All

Images

Videos

翻译成中文

开启取词

12,100 Results

Any time ▾

## Hepatoid adenocarcinoma of the lung without production of ...

[www.ncbi.nlm.nih.gov](http://www.ncbi.nlm.nih.gov) › [Journal List](#) › [Oncol Lett](#)

Hepatoid adenocarcinoma of the lung without production of  $\alpha$ -fetoprotein: A case report and review of the literature JI NING SUN , 1 BAO LONG ZHANG , 2 LIN KUN LI , 1 HAI YAN YU , 1 and BIN WANG 3 1 Department of Radiology, Weifang People's Hospital, Weifang, Shandong 261041, P.R. China

Cited by: 1

Author: Ji Ning Sun, Bao Long Zhang, Lin Kun Li,...

Publish Year: 2016

## [PDF] Case Report Hepatoid adenocarcinoma of the lung: a ...

[www.ijcep.com/files/ijcep0022208.pdf](http://www.ijcep.com/files/ijcep0022208.pdf)

Case Report Hepatoid adenocarcinoma of the lung: a case report Yi Shao 1, Dian-Sheng Zhong , ... HAL is a relatively rare tumor of the lung, with 19 cases in English literature being reported (Table 1 ). Clinically, the cases of HAL share sev - ... Adenocarcinoma of the Lung: A Case Report ...

## Hepatoid adenocarcinoma of the lung: report of five cases ...

[www.nature.com](http://www.nature.com) › [modern pathology](#)

Hepatoid adenocarcinoma of the lung: report of five cases and review of the literature. ... A case report of two patients with primary lung cancer secreting AFP.

Cited by: 22

Author: Diana M Haninger, Goetz Haus Kloecker, ...

Publish Year: 2014

## [PDF] Hepatoid adenocarcinoma of the stomach: A case report ...

<https://www.spandidos-publications.com/10.3892/etm.2015.2393/download>

The present case report describes a patient who was referred to the No.461 Hospital of PLA (Changchun, China) due to nausea and occasional ... Hepatoid adenocarcinoma of the stomach: A case report and literature review XIAO-MEI LIU1, GUI-QIU CHEN2, ...

## Hepatoid adenocarcinoma of the lung without production of ...

[europepmc.org/articles/PMC4906620](http://europepmc.org/articles/PMC4906620)

Hepatoid adenocarcinoma of the lung without production of  $\alpha$ -fetoprotein: A case report and review of the literature JI NING SUN , 1 BAO LONG ZHANG , 2 LIN KUN LI , ...

Cited by: 1

Author: Ji Ning Sun, Bao Long Zhang, Lin Kun Li,...

Publish Year: 2016

## Hepatoid adenocarcinoma of the stomach: A case report and ...

[https://www.researchgate.net/publication/273508078\\_Hepatoid...](https://www.researchgate.net/publication/273508078_Hepatoid...)

Hepatoid adenocarcinoma of the stomach: A case report and review of the literature Article in

**Name of Journal:** *World Journal of Clinical Cases*

**Manuscript NO:** 46325

**Manuscript Type:** CASE REPORT

**Primary hepatoid adenocarcinoma of the lung in Yungui Plateau, China: A case report**

Shi YF *et al.* Primary hepatoid adenocarcinoma of the lung

Yun-Fei Shi, Jia-Gui Lu, Qing-Mei Yang, Jin Duan, You-Ming Lei, Wei Zhao,  
Yin-Qiang Liu

**Abstract**

### Match Overview

1	<b>Crossref</b> 33 words Kate Grossman, Mary Beth Beasley, Sidney S. Braman. "H... patoid adenocarcinoma of the lung: Review of a rare form o	2%
2	<b>Internet</b> 21 words crawled on 05-May-2016 <a href="http://www.ijcep.com">www.ijcep.com</a>	1%





国内版 国际版

Chat with Bing

Primary hepatoid adenocarcinoma of the lung in Yungui Plateau, China: A case report



Sign in



All

Images

Videos

翻译成中文

关闭取词

Make Bing your search engine >

12,300 Results

Any time ▾

## [PDF] Case Report Hepatoid adenocarcinoma of the lung: a ...

[www.ijcep.com/files/ijcep0022208.pdf](http://www.ijcep.com/files/ijcep0022208.pdf)

Case Report Hepatoid adenocarcinoma of the lung: a case report Yi Shao 1, Dian-Sheng Zhong , ...

The patient was a 42-year old man with a **primary** complaint of dry cough. The chest computed tomography revealed a mass of the right **lung** with the diameter of the largest ... **Adenocarcinoma** of the Lung: A Case Report ...

## Hepatoid adenocarcinoma of the lung: Presenting ...

[www.ncbi.nlm.nih.gov](http://www.ncbi.nlm.nih.gov) › [Journal List](#) › [Oncol Lett](#)

Apr 15, 2014 · Hepatoid adenocarcinoma of the lung (HAL) is a rare type of **lung** cancer. Its diagnosis and treatment may be difficult due to the varied presentation; however, immunohistochemical analysis facilitates the diagnosis. The present study presents a **case** of HAL. The patient was a 48-year-old male who presented with a **primary** complaint of back pain.

Cited by: 5

Author: Yi-Qun Che, Shuang Wang, Yang Luo, Jin...

Publish Year: 2014

## Hepatoid adenocarcinoma of the lung: report of five cases ...

[www.nature.com](http://www.nature.com) › [modern pathology](#)

Sep 13, 2013 · We **report** four male patients and one female patient with **hepatoid adenocarcinoma** of **lung**, modify the diagnostic criteria of Ishikura et al 2 and ...

Cited by: 24

Author: Diana M Haninger, Goetz Haus Kloecker,...

Publish Year: 2014

Author: Diana M Haninger

## (PDF) Hepatoid Adenocarcinoma of the Lung - ResearchGate

[https://www.researchgate.net/publication/305418694\\_Hepatoid...](https://www.researchgate.net/publication/305418694_Hepatoid...)

Hepatoid adenocarcinoma of the lung: report of five cases and review of the literature. ... We **report** a **case** of **primary lung** cancer in a 16-year-old boy. ... suggest that the course of **hepatoid** ...

## Hepatoid adenocarcinoma of the lung | QJM: An ...

<https://academic.oup.com/qjmed/article/109/9/619/1753070> ▾

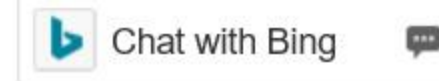
Hepatoid adenocarcinoma of lung (HAL) is a rare tumour type and the clinical and pathological features of this type of **lung** cancer are still poorly described. In 1990, Ishikura defined **hepatoid adenocarcinoma** as an AFP producing **adenocarcinoma** with a mixture of tubular or papillary components and a sheet like or trabecular proliferation pattern.

Cited by: 1

Author: G.-Q. Qian, F.-Y. Yin, G.-X. Li, J.-G. Chu

Publish Year: 2016

## Henatoid adenocarcinoma in stomach: a case report

[国内版](#)[国际版](#)

Primary hepatoid adenocarcinoma of the lung in Yungui Plateau, China: A case rep

[All](#)[Images](#)[Videos](#)[翻译成中文](#)[开启取词](#)

12,300 Results

Any time ▾

### [PDF] [Case Report Hepatoid adenocarcinoma of the lung: a ...](#)

[www.ijcep.com/files/ijcep0022208.pdf](http://www.ijcep.com/files/ijcep0022208.pdf)

**Case Report Hepatoid adenocarcinoma of the lung: a case report** Yi Shao 1, Dian-Sheng Zhong , ...

The patient was a 42-year old man with a **primary** complaint of dry cough. The chest computed tomography revealed a mass of the right **lung** with the diameter of the largest ... **Adenocarcinoma of the Lung: A Case Report** ...

### [Hepatoid adenocarcinoma of the lung: Presenting ...](#)

[www.ncbi.nlm.nih.gov](http://www.ncbi.nlm.nih.gov) › [Journal List](#) › [Oncol Lett](#)

Apr 15, 2014 · **Hepatoid adenocarcinoma of the lung** (HAL) is a rare type of **lung** cancer. Its diagnosis and treatment may be difficult due to the varied presentation; however, immunohistochemical analysis facilitates the diagnosis. The present study presents **a case** of HAL. The patient was a 48-year-old male who presented with a **primary** complaint of back pain.

**Cited by:** 5

**Author:** Yi-Qun Che, Shuang Wang, Yang Luo, Ji...

**Publish Year:** 2014

### [Hepatoid adenocarcinoma of the lung: report of five cases ...](#)

[www.nature.com](http://www.nature.com) › [modern pathology](#)

Sep 13, 2013 · We **report** four male patients and one female patient with **hepatoid adenocarcinoma of lung**, modify the diagnostic criteria of Ishikura et al 2 and ...

**Cited by:** 24

**Author:** Diana M Haninger, Goetz Haus Kloecker,...

**Publish Year:** 2014

**Author:** Diana M Haninger

### [Hepatoid adenocarcinoma of the lung | QJM: An ...](#)

<https://academic.oup.com/qjmed/article/109/9/619/1753070> ▾

**Hepatoid adenocarcinoma of lung** (HAL) is a rare tumour type and the clinical and pathological features of this type of **lung** cancer are still poorly described. In 1990, Ishikura defined **hepatoid adenocarcinoma** as an AFP producing **adenocarcinoma** with a mixture of tubular or papillary components and a sheet like or trabecular proliferation pattern.