

Match Overview

1

Internet 12 words
crawled on 05-Mar-2020
worldwidescience.org

1%

Name of Journal: *World Journal of Clinical Cases***Manuscript NO:** 54792**Manuscript Type:** CASE REPORT

Diffuse alveolar hemorrhage with histopathologic manifestations of pulmonary capillaritis: Report of three cases

Xie J *et al.* Diffuse alveolar hemorrhage with pulmonary capillaritis

Jun Xie, Ying-Yue Zhao, Jing Liu, Guang-Min Nong

INTRODUCTION

Diffuse alveolar hemorrhage (DAH) is a rare, and life-threatening disease in children. It is reported that DAH in children is associated with common causes such as oligoimmunity, immune complex deposition, and others (mainly due to medication)^[1]. DAH is divided into DAH in the presence or absence of pulmonary capillaritis (PC), and DAH of cardiac origin^[2]. PC is characterized by the presence of cough, shortness of breath, dyspnea, with

Diffuse Alveolar Hemorrhage - PubMed Central (PMC)

<https://www.ncbi.nlm.nih.gov/pmc/articles/PMC3651925>

Apr 30, 2013 · **Diffuse alveolar hemorrhage** (DAH) is a life-threatening condition caused by a variety of disorders associated with **hemoptysis**, anemia, **diffuse lung infiltration**, and **acute respiratory failure**. DAH originates from the **pulmonary microcirculation**, including the **alveolar capillaries**, **arterioles**, and **venules** and is usually **diffuse**, but may also be focal.

Cited by: 63 **Author:** Moo Suk Park

Publish Year: 2013

Diffuse Alveolar Hemorrhage - CHEST

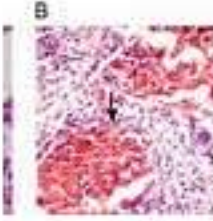
[https://journal.chestnet.org/article/S0012-3692\(10\)60245-0/fulltext](https://journal.chestnet.org/article/S0012-3692(10)60245-0/fulltext)

Epidemiology

Clinical significance

Diagnosis

Pathophysiology



IPH is a rare syndrome in which repeated episodes of DAH occur resulting in chronic anemia and pulmonary fibrosis.¹² The incidence in the adult population is unknown but is reported to occur most commonly before the age of 30 years. In the pediatric population the incidence is reported to be 0.24 in 1 million.¹³ The histology lacks evidence of capillaritis and the alveolar basement membranes are thickened but remain intact. Recu...

[See more on journal.chestnet.org](#)

Cited by: 356 **Author:** Abigail R. Lara, Marvin I. Schwarz

Publish Year: 2010

The diffuse alveolar hemorrhage syndromes - UpToDate

<https://www.uptodate.com/contents/the-diffuse-alveolar-hemorrhage-syndromes>

A variety of diseases are associated with the development of the **diffuse alveolar hemorrhage (DAH) syndrome** . The underlying cause of DAH is generally reflected in the **histopathologic pattern**. One of three different **histopathologic patterns** may be seen: **pulmonary capillaritis**, **bland pulmonary hemorrhage**, and **diffuse alveolar damage**.

Diffuse Alveolar Hemorrhage and Pulmonary Capillaritis Due ...

<https://www.sciencedirect.com/science/article/pii/S0012369215516310>

Selected Reports. Diffuse Alveolar Hemorrhage and Pulmonary Capillaritis Due to **Propylthiouracil**. **Propylthiouracil (PTU)** has recently been observed to be associated with **antineutrophil cytoplasmic antibody (ANCA)–positive small vessel vasculitis**, resulting in **crescentic glomerulonephritis** and, infrequently, diffuse alveolar hemorrhage (DAH).

Cited by: 104 **Author:** Samjot Singh Dhillon, Digvijay Singh, Natha...

Publish Year: 1999

Diffuse Alveolar Hemorrhage in Isolated Pulmonary ...

<https://www.researchgate.net/publication/262539357...>

Download Citation | **Diffuse Alveolar Hemorrhage in Isolated Pulmonary Capillaritis - Case Report** | Introduction: **Pulmonary capillaritis** is a small-diameter vessel vasculitis of the **lung**, which may ...

Pulmonary Capillaritis and Alveolar Hemorrhage - CHEST

[https://journal.chestnet.org/article/S0012-3692\(15\)46542-0/fulltext](https://journal.chestnet.org/article/S0012-3692(15)46542-0/fulltext)

Patients with **pulmonary capillaritis** often present with **diffuse alveolar** (also termed **pulmonary hemorrhage**, although **pulmonary capillaritis** is not a universal feature of this striking phenomenon. 7 x 7 Travis, WD, Carpenter, HA, and Lie, JT. **Diffuse pulmonary hemorrhage**.

Cited by: 294 **Author:** Ronald J. Green, Stephen J. Ruoss, Sally A....

Publish Year: 1996

Alveolar Hemorrhage Syndromes (Diffuse Alveolar Hemorrhage ...

<https://www.pulmonologyadvisor.com/home/decision...>

Bland hemorrhage: Hemorrhage without alveolar destruction or **inflammation**. Diffuse alveolar damage: **Edematous septa** but no **inflammation**. The most common histopathologic pattern found to cause DAH is pulmonary capillaritis, typically in the setting of a **rheumatologic disease** or **systemic vasculitis**.

[PDF] Diffuse Alveolar Hemorrhage

<https://e-trd.org/Synapse/Data/PDFData/0003TRD/trd-74-151.pdf>

pneumonia, or **diffuse alveolar damage** can also be seen². DAH is associated with **pulmonary capillaritis**, **bland pulmonary hemorrhage**, **diffuse alveolar damage**, and miscellaneous **histology**. **Pulmonary capillaritis** is the most common finding³. **Pulmonary capillaritis** has a unique **histopathologic appearance**, consisting of an in-

Isolated Pulmonary Capillaritis and Diffuse Alveolar ...

<https://www.sciencedirect.com/science/article/pii/S0012369216315069>

Study objectives. To demonstrate that **pulmonary capillaritis** and **diffuse alveolar hemorrhage** (DAH) occur and are isolated to the lung and therefore not part of systemic vasculitis at the time of the DAH episode in rheumatoid arthritis (RA) and mixed connective tissue disease (MCTD).

Cited by: 99 **Author:** Marvin I. Schwarz, Martin R. Zamora, Tony ...

Publish Year: 1998

Diffuse Alveolar Hemorrhage in Systemic Lupus ...

<https://www.hindawi.com/journals/cripa/2017/1936282>

Diffuse alveolar hemorrhage occurs in three distinct but sometimes overlapping **histologic patterns**: **pulmonary capillaritis**, **bland pulmonary hemorrhage**, and **diffuse alveolar damage** . **Pulmonary capillaritis** is defined by neutrophil infiltration of the **alveolar septa**, loss of **capillary structural integrity**, and spilling of **red blood cells** into the **alveolar spaces** and interstitium [11].

Cited by: 5 **Author:** Robert Ta, Romulo Celli, A. Brian West

Publish Year: 2017



Diffuse alveolar hemorrhage with histopathologic manife



ALL

IMAGES

VIDEOS

MAPS

NEWS

SHOPPING

27,800 Results

Any time ▾

[Diffuse Alveolar Hemorrhage - PubMed Central \(PMC\)](#)

<https://www.ncbi.nlm.nih.gov/pmc/articles/PMC3651925>

Apr 30, 2013 · **Diffuse alveolar hemorrhage** (DAH) is a life-threatening condition caused by a variety of **disorders** associated with **hemoptysis**, anemia, **diffuse lung infiltration**, and **acute respiratory failure**. DAH originates from the **pulmonary microcirculation**, including the **alveolar capillaries**, **arterioles**, and venules and is usually **diffuse**, but may also be focal.

Cited by: 63

Author: Moo Suk Park

Publish Year: 2013

[Case Report: Rheumatoid arthritis causing diffuse alveolar ...](#)

<https://www.ncbi.nlm.nih.gov/pmc/articles/PMC5535102>

Jun 14, 2017 · There are three main **histological patterns** associated with DAH: **diffuse alveolar damage**, **bland pulmonary haemorrhage** and **capillaritis**. 7 Of these, **capillaritis** represents **destruction of pulmonary microcirculation** by processes such as vasculitides, especially those associated with connective tissue diseases (CTD).

Cited by: 1

Author: Afaf Osman, Panagis Galiatsatos, Sonali ...

Publish Year: 2017

[The diffuse alveolar hemorrhage syndromes - UpToDate](#)

<https://www.uptodate.com/contents/the-diffuse...>

The underlying cause of DAH is generally reflected in the **histopathologic** pattern. One **of three** different **histopathologic** patterns may be seen: **pulmonary capillaritis**, bland **pulmonary hemorrhage**, and **diffuse alveolar** damage. ... Travis WD, Colby TV, Lombard C, Carpenter HA. A clinicopathologic study of 34 **cases** of **diffuse pulmonary hemorrhage** ...

[Diffuse Alveolar Hemorrhage - CHEST](#)

[https://journal.chestnet.org/article/S0012-3692\(10\)60245-0/fulltext](https://journal.chestnet.org/article/S0012-3692(10)60245-0/fulltext)



Epidemiology

Clinical significance

Diagnosis

Pathophysiology

