



ALL

IMAGES

VIDEOS

19,000 Results

Any time ▾

Basaloid Squamous Cell Carcinoma of the Sigmoid Colon

<https://www.ncbi.nlm.nih.gov/pmc/articles/PMC4435408>

Apr 10, 2015 · Basaloid squamous cell carcinoma (BSCC) of the colon is rarely found proximal to the anal canal. We report a case of an 81-year-old woman who was diagnosed with squamous cell carcinoma (SCC) of the lung without metastasis and BSCC of the sigmoid with differing histologic findings suggesting that these tumors were separate primary neoplasms.

Cited by: 1

Author: Salih Samo, Muhammed Sherid, Kevin Li...

Publish Year: 2015

Basaloid (Cloacogenic) Carcinoma Mimicking Intraabdominal ...

<https://www.ncbi.nlm.nih.gov/pmc/articles/PMC2988965>

Basaloid (Cloacogenic) Carcinoma Mimicking Intraabdominal Abscess: Report of a Case and Review of the Literature Sami Akbulut , a, * Bahri Cakabay , a Arsenal Sezgin , b and Cihan Akgul Ozmen c a Department of Surgery, Diyarbakir Education and Research Hospital, Diyarbakir, Turkey

Squamous cell cancer of the rectum - PubMed Central (PMC)

<https://www.ncbi.nlm.nih.gov/pmc/articles/PMC2747057>

Sep 21, 2009 · Squamous cell carcinoma of the rectum is a rare malignancy. It appears to be associated with chronic inflammatory conditions and infections. The clear association seen between Human Papilloma Virus and various squamous cancers has not been firmly established for the squamous cell cancer of the rectum.

Cited by: 80

Author: Tara Dyson, Peter V Draganov

Publish Year: 2009

Primary squamous cell carcinoma of the rectum: a case ...

<https://www.ncbi.nlm.nih.gov/pmc/articles/PMC4942521>

Jul 06, 2016 · Squamous cell carcinoma (SCC) of the rectum is a rare occurrence with an incidence rate of 0.1–0.25% per 1,000 cases. Herein, we report a case of a 52-year-old female who presented with a 2-month history of diffuse lower abdominal pain and hematochezia.

A Case Report of Basal Cell Carcinoma in a Non-Sun ...

<https://www.ncbi.nlm.nih.gov/pmc/articles/PMC6280225>

Nov 21, 2018 · Two case reports also reported successful treatment with radiotherapy for patients

Name of Journal: *World Journal of Clinical Cases*

Manuscript NO: 55756

Manuscript Type: CASE REPORT

Successful treatment of ⁶basaloid squamous cell carcinoma in the rectosigmoid colon: A case report and review of literature

Lee TG *et al.* Long-term survival in BSCC of the rectosigmoid

Taek-Gu Lee, Soon Man Yoon, Myung Jo Kim

Abstract

BACKGROUND

Compared with colorectal adenocarcinoma, basaloid squamous cell carcinomas (BSCCs) arising in the colorectum are rare and have very poor prognosis. To date, only nine cases have been reported. Most BSCCs are extensively involved in metastasis to the lymph node, liver, and lung at

Match Overview

1	Internet 15 words crawled on 09-Jun-2020 www.researchsquare.com	1%
2	Internet 14 words crawled on 18-Mar-2020 surgicalcasereports.springeropen.com	1%
3	Internet 12 words crawled on 29-Nov-2016 www.ijcasereportsandimages.com	1%
4	Crossref 12 words Katsuhiko Hiromura , Madoka Furuhashi , Kojiro Minami , Ken Miyazaki , Kana Yoshida , Naohiko Kuno , Kaoru Ishikawa . "L ...	1%
5	Internet 12 words www.pubmedcentral.nih.gov	1%
6	Internet 12 words crawled on 20-Jun-2020 tessera.spandidos-publications.com	1%



Successful treatment of basaloid squamous cell carcinon



ALL IMAGES VIDEOS MAPS NEWS SHOPPING

25,800 Results Any time ▾

Basaloid Squamous Cell Carcinoma of the Sigmoid Colon

<https://www.ncbi.nlm.nih.gov/pmc/articles/PMC4435408>

Apr 10, 2015 · **Basaloid squamous cell carcinoma** (BSCC) of the **colon** is rarely found proximal to the anal canal. We **report a case** of an 81-year-old woman who was diagnosed with **squamous cell carcinoma** (SCC) of the lung without metastasis and BSCC of the sigmoid with differing histologic findings suggesting that these tumors were separate primary neoplasms.

Cited by: 1 **Author:** Salih Samo, Muhammed Sherid, Kevin Li...

Publish Year: 2015

(PDF) Basaloid Squamous Cell Carcinoma of the Rectum: A ...

<https://www.researchgate.net/publication/255717262...>

Primary **squamous cell carcinoma** (SCC) of the **colon** and rectum is a rare malignancy. Overall there are less than 150 cases which have been reported and the first was **case** was reported in 1919.

Primary squamous cell carcinoma of the rectum: a case ...

<https://www.ncbi.nlm.nih.gov/pmc/articles/PMC4942521>

Jul 06, 2016 · **Squamous cell carcinoma** (SCC) of the rectum is a rare occurrence with an incidence rate of 0.1–0.25% per 1,000 cases. Herein, we **report a case** of a 52-year-old female who presented with a 2-month history of diffuse lower abdominal pain and hematochezia. Abdominal CT scan revealed a 7-cm irregular **rectal** mass, and the biopsy showed SCC.

Cited by: 3 **Author:** Neil Vyas, Sumair Ahmad, Khaled Bhuiya...

Publish Year: 2016

(PDF) Basaloid Squamous Cell Carcinoma of the Sigmoid Colon

<https://www.researchgate.net/publication/276166813...>

A **retrospective review of medical records** was undertaken in all 52 cases with respect to predisposing factors, clinicopathologic behavior, prognostic features, and **treatment** with **adjuvant therapy**...

Squamous Cell Skin Cancer

Medical Condition

A type of skin cancer, which forms in the middle and outer layer of the skin.

 Common (More than 200,000 cases per year in US)

 Often requires lab test or imaging

 Treatment from medical professional advised

 Can last several months or years

It is caused due to over production of skin cells. Over exposure to ultraviolet radiation (UV) of sun rays could also be a factor. Symptoms include scaly, red patches, open sores, or warts on sun exposed areas like face, neck and ears. Treatment includes topical medication and minor surgery.

Symptoms



Successful treatment of basaloid squamous cell carcinon



Sign in



ALL

IMAGES

VIDEOS

26,100 Results

Any time ▾

Basaloid Squamous Cell Carcinoma of the Sigmoid Colon

<https://www.ncbi.nlm.nih.gov/pmc/articles/PMC4435408>

Apr 10, 2015 · **Basaloid squamous cell carcinoma** (BSCC) of the **colon** is rarely found proximal to the anal canal. We **report a case** of an 81-year-old woman who was diagnosed with **squamous cell carcinoma** (SCC) of the lung without metastasis and BSCC of the sigmoid with differing histologic findings suggesting that these tumors were separate primary neoplasms.

Cited by: 1

Author: Salih Samo, Muhammed Sherid, Kevin Li...

Publish Year: 2015

Primary squamous cell carcinoma of the rectum: a case ...

<https://www.ncbi.nlm.nih.gov/pmc/articles/PMC4942521>

Jul 06, 2016 · **Squamous cell carcinoma** (SCC) of the rectum is a rare occurrence with an incidence rate of 0.1–0.25% per 1,000 cases. Herein, we **report a case** of a 52-year-old female who presented with a 2-month history of diffuse lower abdominal pain and hematochezia. Abdominal CT scan revealed a 7-cm irregular **rectal** mass, and the biopsy showed SCC.

Cited by: 3

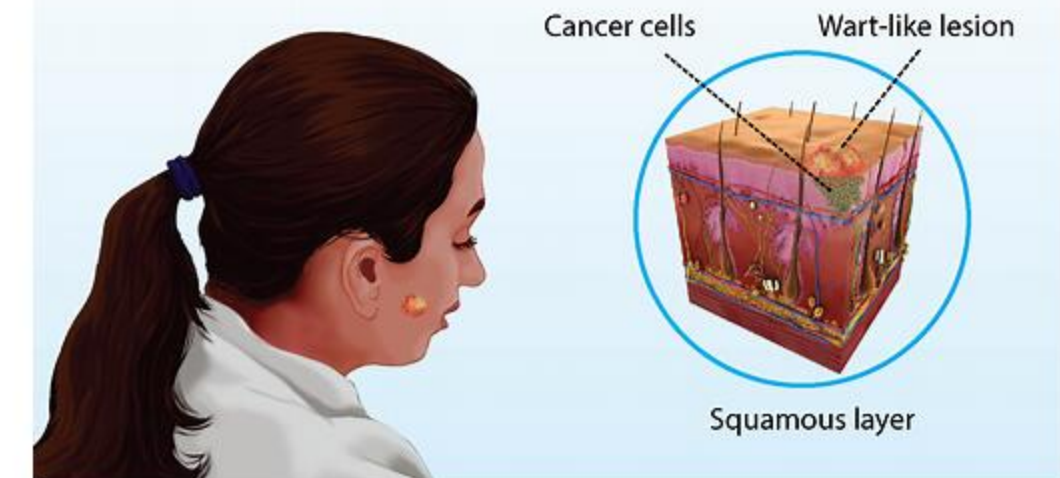
Author: Neil Vyas, Sumair Ahmad, Khaled Bhuiya...

Publish Year: 2016

Squamous Cell Skin Cancer

Medical Condition

Scaly, red patches, open sores, or wart like lesion on the skin



A type of skin cancer, which forms in the middle and outer layer of the skin.

Common (More than 200,000 cases per year in US)

Often requires lab test or imaging