

**1**  
Name of Journal: *World Journal of Clinical Cases*

Manuscript NO: 55781

Manuscript Type: CASE REPORT

Adult duodenal intussusception with horizontal adenoma: A rare case report

Kun-Peng Wang, Hao Jiang, Can Kong, Lie-zhi Wang, Guo-yu Wang,  
Jing-Gang Mo, Chong Jin

Abstract

BACKGROUND

## Match Overview

1	Internet 79 words crawled on 28-Aug-2019 <a href="http://f6publishing.blob.core.windows.net">f6publishing.blob.core.windows.net</a>	4%
2	Internet 21 words crawled on 17-Apr-2020 <a href="http://www.wjgnet.com">www.wjgnet.com</a>	1%
3	Crossref 12 words Ozaki, K.. "Focal chronic pancreatitis mimicking intraductal papillary mucinous neoplasm of the pancreas", <i>European Journal of Gastroenterology and Hepatology</i>	1%
4	Crossref 10 words Laila Menon, Jonathan M. Buscaglia. "Endoscopic approach to subepithelial lesions", <i>Therapeutic Advances in Gastroenterology</i>	1%
5	Crossref 10 words Amer M. Johri, Katherine A. Kovacs, Henryk Kafka. "An unusual case of infective endocarditis: Extension of a tricuspid valve vegetation into the right atrium", <i>Journal of Intensive Care Medicine</i>	1%



A rare case report of adult duodenal intussusception with



ALL

IMAGES

VIDEOS

42,900 Results

Any time ▾

### Adult duodenal intussusception ... - PubMed Central (PMC)

<https://www.ncbi.nlm.nih.gov/pmc/articles/PMC4611227>

Jul 28, 2007 · Duodeno-duodenal intussusception is exceptionally rare because the retroperitoneal situation fixes the duodenal wall. The aim of this report is to describe the first published case of this condition. A patient with duodeno-duodenal intussusception secondary to an ampullary lesion is reported.

Cited by: 10

Author: J Gardner-Thorpe, RH Hardwick, NR Carr...

Publish Year: 2007

### Acute Pancreatitis Secondary to ... - PubMed Central (PMC)

<https://www.ncbi.nlm.nih.gov/pmc/articles/PMC3364087>

In conclusion, acute pancreatitis secondary to duodenoduodenal intussusception in adult is very rare. Duodenoduodenal intussusception is always associated with a lead point, which in our patient was a tubulovillous adenoma.

### Taking the Lead: A Case Report of a Leiomyoma Causing ...

<https://www.liebertpub.com/doi/full/10.1089/crpc.2016.0001>

Apr 01, 2016 · Background: Duodenal masses are rare entities and symptomatic presentation generally is due to abdominal pain or the presence of gastrointestinal bleeding. A number of published case reports in the literature have detailed various neoplasms that have caused an intussusception isolated to the duodenum.

Cited by: 1

Author: F ChaiLouis, M BatistaPhilip, LavuHarish

Publish Year: 2016

### A rare case of adult colocolonic intussusception of the ...

<https://casereports.bmj.com/content/12/11/e231590> ▾

Left hemicolectomy with primary anastomosis was performed. The final pathology revealed a tubulovillous adenoma with multiple foci of high-grade dysplasia. Intussusception is a rare cause for colonic obstruction, and ~90% of cases in adults are secondary to an anatomical or pathological condition.

### Brunner's gland adenoma of duodenum: A case report and ...

<https://www.ncbi.nlm.nih.gov/pmc/articles/PMC4572179>

Sep 01, 2004 · METHODS: A rare case of Brunner's gland adenoma of the duodenum was described





国内版

国际版

Adult duodenal intussusception with horizontal adenom



Sign in



ALL

IMAGES

VIDEOS

277,000 Results

Any time ▾

## Adult duodenal intussusception associated with congenital ...

<https://www.ncbi.nlm.nih.gov/pmc/articles/PMC4611227>

Jul 28, 2007 · In **adults**, there is usually an **abnormality** acting as a lead point, usually a Meckels' diverticulum, a hamartoma or a **tumour**. **Duodeno-duodenal intussusception** is exceptionally **rare** because the **retroperitoneal** situation fixes the **duodenal wall**. The aim of this **report** is to describe the first published **case** of this condition.

Cited by: 11

Author: J Gardner-Thorpe, RH Hardwick, NR Car...

Publish Year: 2007

## Case Report: Intussusception: a rare complication in a ...

<https://www.ncbi.nlm.nih.gov/pmc/articles/PMC5337644>

Feb 28, 2017 · Discussion. **Intussusception** is a process in which there is prolapse of a proximal bowel segment into a distal one. 8 **Adult intussusception** is a **rare** occurrence since ~95% of the cases occur in children. 9 10 Among all cases of bowel obstruction occurring in **adults**, **intussusception** is responsible for 1–5% of all cases. 8 10 11 The pathogenesis that leads to invagination is poorly ...

Cited by: 1

Author: Qasrawi A, Abu Ghanimeh M, Abughani...

Publish Year: 2017

## Search Tools

Turn off Hover Translation (关闭取词)





ALL IMAGES VIDEOS MAPS NEWS SHOPPING

276,000 Results Any time ▾

## Adult duodenal intussusception associated with congenital ...

<https://www.ncbi.nlm.nih.gov/pmc/articles/PMC4611227>

Jul 28, 2007 · In **adults**, there is usually an **abnormality** acting as a lead point, usually a Meckels' diverticulum, a hamartoma or a **tumour**. **Duodeno-duodenal intussusception** is exceptionally **rare** because the **retroperitoneal** situation fixes the **duodenal wall**. The aim of this **report** is to describe the first published **case** of this condition.

**Cited by:** 11 **Author:** J Gardner-Thorpe, RH Hardwick, NR Car...

**Publish Year:** 2007

## Case report and literature review: patient with ...

<https://bmcsurg.biomedcentral.com/articles/10.1186/s12893-019-0608-3>

Oct 29, 2019 · Background. **Intussusception** rarely occurs among the **adult** patients. It accounts for 5% of all **intussusception** cases and in only 1% **causes intestinal obstruction** [ 1 ]. **Gastroduodenal intussusception** is the most infrequent form of **intussusception** in **adults**, ...

**Author:** Mihajlo Đokić, Jerica Novak, Miha Pet... **Publish Year:** 2019

## Case Report: Intussusception: a rare complication in a ...

<https://www.ncbi.nlm.nih.gov/pmc/articles/PMC5337644>

Feb 28, 2017 · Discussion. **Intussusception** is a process in which there is prolapse of a proximal bowel segment into a distal one. 8 **Adult intussusception** is a **rare** occurrence since ~95% of the cases occur in children. 9 10 Among all cases of bowel obstruction occurring in **adults**, **intussusception** is responsible for 1–5% of all cases. 8 10 11 The pathogenesis that leads to invagination is poorly ...

**Cited by:** 1 **Author:** Qasrawi A, Abu Ghanimeh M, Abughanim...

**Publish Year:** 2017

## Adult colocolic intussusception diagnosed by ...

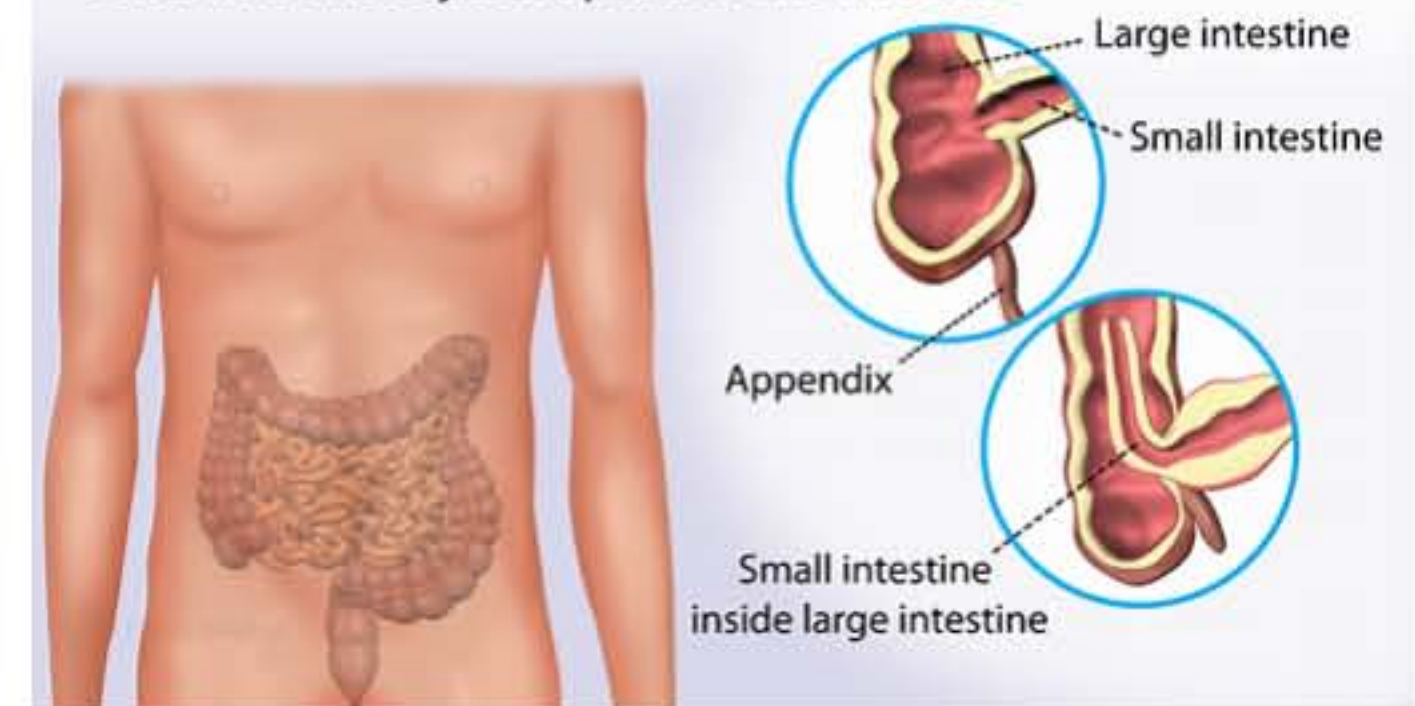
<https://www.ncbi.nlm.nih.gov/pmc/articles/PMC3155120>

**Intussusception** is highly uncommon in **adults** and accounts for only 5% of all **reported cases**. It is

## Intussusception

Medical Condition

Intestinal obstruction in which one segment of intestine folds into the adjacent portion the intestine



Intestinal obstruction that results when a part of the intestine folds into a section next to it.

📊 Rare (Fewer than 200,000 cases per year in US)

🧪 Requires lab test or imaging

👨🏻‍⚕️ Treatment from medical professional advised

🕒 Can last several weeks or months

More common in children, the cause is unknown. Sometimes, it could be a result of an abnormal growth in the intestines, e.g. a tumor. The symptoms include stool mixed with mucus, vomiting, diarrhea, fever, a lump in the abdomen. If diagnosed early, it can be treated through a minor procedure. In adults, surgery may be necessary.