

Portal gas in neonates; is it always surgical?: A case report

Altokhais TI *et al.* Portal gas in neonates

Tariq Ibrahim Altokhais

Abstract**BACKGROUND**

Hepatic portal venous gas in infants is frequently due to late presentation of necrotizing enterocolitis which is considered a relative indicator for surgical intervention.

CASE SUMMARY

A preterm baby underwent an umbilical catheter placement and discovered in abdominal radiograph to have air in the portal venous system due to malpositioning of the umbilical catheter.

CONCLUSION

Hepatic portal venous gas in infants without signs of necrotizing enterocolitis could result from malposition of umbilical venous catheter, and in that case, should be managed medically, with no need for surgical intervention.

Key words: Portal gas; Neonate; Necrotizing; Enterocolitis; Umbilical; Catheter

Match Overview

1 match

1

Crossref 13 words

Hans W. Bodewes, Julien B. C. M. Puylaert. "Ultrasound in detection of portal venous gas in adults", *Gastrointestinal Radiol*

1%



Portal gas in neonates; is it always surgical? A case report and review



ALL

IMAGES

VIDEOS

284,000 Results

Any time ▾

Hepatic portal venous gas: A case report and review of ...

<https://www.ncbi.nlm.nih.gov/pmc/articles/PMC2772243>

The occurrence of gas in portal veins has been described in literature as pneumoportogram, gas embolisation of the portal vein or portal venous gas. It was first described as hepatic portal venous gas (HPVG) in 1978 by Libman, et al. Until 1968, HPVG was viewed as an inevitable harbinger of death with a mortality rate of over 90%.

Cited by: 13

Author: Vikas Kesarwani, Dhaval R Ghelani, Grah...

Publish Year: 2009

Neonatal group A streptococcal meningitis: a case report ...

<https://www.ncbi.nlm.nih.gov/pmc/articles/PMC2531175>

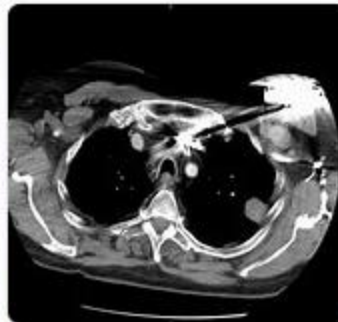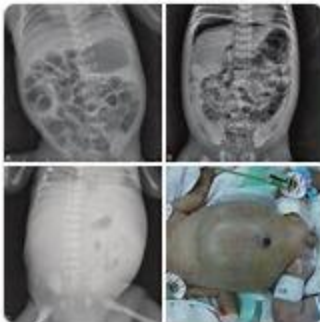
Aug 18, 2008 · Background. Since the introduction of antibiotics, group A streptococcal infection has been an uncommon disease in neonates. Thirty-nine patients with severe neonatal disease caused by group A streptococcus (GAS) have been described since 1966 [1]. Meningitis caused by GAS is reported in only 15 neonates during same period [2-13]. This case report describes a neonate with GAS ...

Cited by: 12

Author: Amer A Lardhi

Publish Year: 2008

Images of Portal Gas In Neonates; Is It Always Surgical? A Cas...

<bing.com/images>[See all images >](#)



ALL IMAGES VIDEOS

339,000 Results Any time ▼

Hepatic portal venous gas: A case report and review of ...

<https://www.ncbi.nlm.nih.gov/pmc/articles/PMC2772243>

The occurrence of **gas** in **portal** veins has been described in **literature** as pneumoportogram, **gas** embolisation of the **portal** vein or **portal** venous **gas**. It was first described as hepatic **portal** venous **gas** (HPVG) in 1978 by Libman, et al. Until 1968, HPVG was viewed as an inevitable harbinger of death with a mortality rate of over 90%.

Cited by: 14 **Author:** Vikas Kesarwani, Dhaval R Ghelani, Graha...

Publish Year: 2009

Search Tools

Turn off Hover Translation (关闭取词)

Hepatic portal venous gas: A case report and analysis of ...

<https://www.sciencedirect.com/science/article/pii/S0735675720305891>

Jul 14, 2020 · 1. Background. Hepatic **portal** vein **gas** was first introduced by Wolff and Evans in 1955 in **neonatal** necrotizing enterocolitis []. In 1978, Liebman et al. reported that **gas** in the **portal** vein was associated with a mortality rate of 75% []. With the advancement of imaging technology, it is gradually recognized that HPVG is not a disease and cannot be used as a predictor of death alone, but may be a ...

Author: Chun Liu, Chang-Wei Wu, Xiang-De Zhe... **Publish Year:** 2020

Hepatic Portal Venous Gas: The ABCs of Management ...

<https://jamanetwork.com/journals/jamasurgery/fullarticle/405097> ▼

Jun 01, 2009 · Hepatic **portal** venous **gas** (HPVG) was first described in abdominal plain radiographs in 1955 by Wolfe and Evans 1 in 6 **neonates** who died secondary to necrotic bowels, followed by reports of HPVG in 5 adults who died 2,3 and the first reported survivor in 1965. 4 Liebman and colleagues 5 analyzed all cases of HPVG reported in the **literature** by 1978 and found an oft-cited mortality rate of ...

Cited by: 202 **Author:** Aaron L. Nelson, Timothy M. Millington, Du...

Publish Year: 2009



Portal gas in neonates; is it always surgical? A case report



ALL

IMAGES

VIDEOS

MAPS

NEWS

SHOPPING

7,310,000 Results

Any time ▼

[Hepatic portal venous gas: A case report and review of ...](#)

<https://www.ncbi.nlm.nih.gov/pmc/articles/PMC2772243>

Portal venous **gas** has a high carbon dioxide content,[] which is expected to exist only briefly in the vascular system before being absorbed or removed by bulk flow, unless the **gas** production persists. The **portal** venous **gas** may also be related to an increase in intra-luminal pressure, which forces intra-luminal **gas** through a damaged or undamaged bowel wall where it is absorbed into the **portal** ...

Cited by: 14

Author: Vikas Kesarwani, Dhaval R Ghelani, Gra...

Publish Year: 2009

[Neonatal group A streptococcal meningitis: a case report ...](#)

<https://www.ncbi.nlm.nih.gov/pmc/articles/PMC2531175>

Aug 18, 2008 - Background. Since the introduction of antibiotics, **group A streptococcal** infection has been an uncommon disease **in neonates**. Thirty-nine patients with severe **neonatal** disease caused by group A streptococcus (**GAS**) have been described since 1966 [].Meningitis caused by **GAS** is reported in only 15 **neonates** during same period [2-13].This **case report** describes a neonate with **GAS** ...

Cited by: 12

Author: Amer A Lardhi

Publish Year: 2008

[Neonatal group A streptococcal meningitis: a case report ...](#)

<https://casesjournal.biomedcentral.com/articles/10.1186/1757-1626-1-108> ▼

Aug 18, 2008 - Since the introduction of antibiotics, **group A streptococcal** infection has been an uncommon disease **in neonates**. Thirty-nine patients with severe **neonatal** disease caused by group A streptococcus (**GAS**) have been described since 1966 [].Meningitis caused by **GAS** is reported in only 15 **neonates** during same period [2–13].This **case report** describes a neonate with **GAS** meningitis seen ...

Cited by: 12

Author: Amer A Lardhi

Publish Year: 2008

[\[PDF\] Gastric Perforation in Two Neonates: Spontaneous ...](#)

https://www.jsmcentral.org/sm-pediatric-surgery/fulltext_smjps-v2-1009.pdf

Secondary to Feeding Tube: **A Case Report**. SM J Pediatr Surg. 2016; 2(1): 1009. OPEN ACCESS