

国内版

国际版



Diffusion-Weighted Imaging Might Be Useful for Reactive Lymphoi



ALL

IMAGES

VIDEOS

15,800 Results

Any time ▾

Reactive lymphoid hyperplasia of the liver: Perinodular ...

<https://www.ncbi.nlm.nih.gov/pmc/articles/PMC4458787>

Jun 07, 2015 · We report the case of a **69-year-old** woman with reactive lymphoid hyperplasia (RLH) of the liver. She underwent partial hepatectomy under a preoperative diagnosis of **hepatocellular carcinoma**; however, histopathological analysis revealed RLH.

Cited by: 5

Author: Tetsuo Sonomura, Shinpei Anami, Taizo...

Publish Year: 2015

Reactive lymphoid hyperplasia of the liver mimicking ...

<https://www.ncbi.nlm.nih.gov/pmc/articles/PMC4503181>

Reactive lymphoid hyperplasia of liver is an extremely rare disease which **may** show similar radiological features to hepatocellular carcinoma by various **imaging** modalities. The definite **diagnosis** of this disease depends upon a combination of morphologic findings, immunohistochemical analysis and molecular studies.

Cited by: 7

Author: Ang Lv, Wendy Liu, Hong-Gang Qian, Ji...

Publish Year: 2015

Reactive Lymphoid Hyperplasia of the liver in a patient ...

<https://www.ncbi.nlm.nih.gov/pmc/articles/PMC1579220>

Reactive lymphoid hyperplasia (RLH) of the liver is very rarely reported, and we encountered **two cases of RLH of the liver in a patient with colon cancer**. Case presentation In the first case, a 77-year-old woman was admitted for the surgical removal of a ascending colon cancer.

Cited by: 56

Author: Hiroki Takahashi, Hirozumi Sawai, Yoich...

Publish Year: 2006


Reactive lymphoid hyperplasia of the liver requires ...

<https://www.ncbi.nlm.nih.gov/pmc/articles/PMC4747959>



Reactive lymphoid hyperplasia of the liver is an extremely rare condition, and only 47 cases of

国内版

国际版



Diffusion-weighted imaging might be useful for reactive lymphoid hyper



ALL

IMAGES

VIDEOS

30,600 Results

Any time

Reactive lymphoid hyperplasia of the liver. A case report

<https://pubmed.ncbi.nlm.nih.gov/31530408>

Reactive lymphoid hyperplasia of the liver is an unusual benign lesion of unknown pathogenesis. The largest reported series to date includes only 7 cases. Reactive lymphoid hyperplasia can be radiologically confused with malignant tumors such as hepatocellular carcinoma ...

Author: María Luisa Suárez-Solís, Sofía de la ... Publish Year: 2019

Reactive lymphoid hyperplasia of the liver requires ...

<https://www.ncbi.nlm.nih.gov/pmc/articles/PMC4747959>

Reactive lymphoid hyperplasia (RLH) of the liver is a rare and benign nodular lesion. It remains difficult to distinguish RLH from hepatocellular carcinoma (HCC) despite recent advances in imaging modalities. We report five cases of RLH that required differential diagnosis of HCC preoperatively.

Cited by: 6 Author: Takaaki Higashi, Daisuke Hashimoto, Hir... Publish Year: 2015

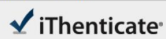
Search Tools

Turn off Hover Translation (关闭取词)

Chat with Bing

Sign in

Microsoft Bing



Match Overview

- | | | |
|---|--|----|
| 1 | Internet 47 words
crawled on 17-May-2020
www.wjgnet.com | 3% |
| 2 | Crossref 25 words
Tetsuo Sonomura. "Reactive lymphoid hyperplasia of the liver
r: Perinodular enhancement on contrast-enhanced compute ... | 2% |

Name of Journal: *World Journal of Clinical Cases*

Manuscript NO: 58036

Manuscript Type: CASE REPORT

Diffusion-weighted imaging might be useful for reactive lymphoid hyperplasia diagnosis of the liver: A case report

Taro Tanaka, Kazuhiro Saito, Daisuke Yunaiyama, Jun Matsubayashi, Yuichi Nagakawa, Maki Tanigawa, Toshitaka Nagao

Abstract

BACKGROUND

Reactive lymphoid hyperplasia (RLH) of the liver is a rare liver lesion. It is considered

国内版

国际版

Diffusion-weighted imaging might be useful for reactive lymphoid



ALL

IMAGES

VIDEOS

30,700 Results

Any time ▾

Reactive lymphoid hyperplasia of the liver. A case report

<https://pubmed.ncbi.nlm.nih.gov/31530408>

Reactive lymphoid hyperplasia of the liver is an unusual benign lesion of unknown pathogenesis. The largest reported series to date includes only 7 cases. **Reactive lymphoid hyperplasia** can be radiologically confused with malignant tumors such as hepatocellular carcinoma or metastases. Histological d ...

Author: María Luisa Suárez-Solís, Sofía de la... **Publish Year:** 2019

Intrahepatic Reactive Lymphoid Hyperplasia: A Case Report ...

<https://www.ncbi.nlm.nih.gov/pmc/articles/PMC6146636>

Sep 06, 2018 · Reactive lymphoid hyperplasia of the liver is a very rare disease of the liver, often found incidentally and often incorrectly diagnosed as **hepatocellular carcinoma** on preoperative workup. It has a **predilection to middle-aged females**, often associated with **autoimmune diseases, specifically primary biliary cholangitis**, or other **malignancies**.

Cited by: 1 **Author:** Samantha Seitter, Zachary D. Goodman...

Publish Year: 2018

Reactive lymphoid hyperplasia of the liver: Perinodular ...

<https://www.ncbi.nlm.nih.gov/pmc/articles/PMC4458787>

Jun 07, 2015 · INTRODUCTION. **Reactive lymphoid hyperplasia** (RLH) is a benign condition of unknown etiology and pathogenesis[].It is common in the gastrointestinal tract, orbit, lung, and skin, but rare in the **liver**, where it is difficult to differentiate from malignant **liver** tumors such as hepatocellular carcinoma (HCC) and **liver** metastases.

Cited by: 5 **Author:** Tetsuo Sonomura, Shinpei Anami, Taizo...

Publish Year: 2015

(PDF) A case of reactive lymphoid hyperplasia of the liver ...

https://www.researchgate.net/publication/341132803_A_case_of_reactive_lymphoid