



国内版 国际版

Malignant Acanthosis Nigricans with Leser-Trélat sign and Tripe



ALL IMAGES VIDEOS

7,470 Results Any time ▼

Including results for **malignant acanthosis nigricans with leser-trelat sign and tripe palms a case report**.

Do you want results only for **Malignant Acanthosis Nigricans with Leser-Trélat sign and Tripe Palms: A Case Report** ?

### Malignant Acanthosis Nigricans Associated with Ovarian ...

<https://www.ncbi.nlm.nih.gov/pmc/articles/PMC2914370>

Jul 02, 2010 · Malignant acanthosis nigricans is a cutaneous eruption characterized by **symmetric hyperpigmented hyperkeratosis**, **dermal papillomatosis**, and mucosal involvement associated with **internal malignancies**. **Tripe palms** refers to a characteristic velvety thickening of the palms, with exaggeration of normal skin markings.

Cited by: 5

Author: Chee Won Oh, Jimi Yoon, Chi Yeon Kim

Publish Year: 2010

### [PDF] Case Report Malignant acanthosis nigricans, tripe palms ...

[https://www.gynecologiconcology-online.net/article/S0090-8258\(05\)01129-7/pdf](https://www.gynecologiconcology-online.net/article/S0090-8258(05)01129-7/pdf)

The presence of **acanthosis nigricans** in conjunction with **tripe palms** and the sign of **Leser-Tre'lat** are highly suggestive of an internal malignancy and necessitate an extensive investigation in order to discover the **underlying malignancy**. © 2005 Elsevier Inc.

### Malignant acanthosis nigricans, tripe palms and the sign ...

<https://www.sciencedirect.com/science/article/pii/S0090825805011297>

May 01, 2006 · Malignant acanthosis nigricans is a mucocutaneous eruption associated with internal malignancies. **Tripe palms** refers to a characteristic velvety thickening of the **palms**, with exaggeration of normal skin markings. The sign of **Leser-Tre'lat** is the presence of multiple **seborrheic keratoses** and scattered skin tags caused by a malignancy.

Cited by: 55

Author: Mehdi M. Kebria, Jerome L. Belinson, Ro...

Publish Year: 2006

### Malignant Acanthosis Nigricans, Florid Cutaneous ...

<https://content.sciendo.com/view/journals/sjdv/7/1/article-p5.xml?language=en> ▼

Mar 01, 2015 · Acanthosis nigricans is usually associated with one of the three or all three forms of paraneoplastic lesions: **florid cutaneous papillomatosis**, **acanthosis palmaris** (tripe palms, **pachydermatoglyphia**) involving the palms and soles, as well as **multiple seborrheic keratosis** (sign

Malignant acanthosis nigricans is a form of extensive and rapidly progressive AN, always associated with malignancy. As was reported in our case, malignant acanthosis nigricans can occur in conjunction with the sign of Leser-Tre'lat and **hyperkeratosis of the palms** (tripe palms) [ 8, 9, 10

Author: Mehdi M. Kebria, Jerome L. Belinson, Robert Kim, Tarek M. Mekhail

Cited by: 57

Publish Year: 2006

[Malignant acanthosis nigricans, tripe palms and the sign ...](#)

[www.gynecologiconcology-online.net/article/S0090-8258\(05\)01129-7/fulltext](http://www.gynecologiconcology-online.net/article/S0090-8258(05)01129-7/fulltext)

Was this helpful?

#### PEOPLE ALSO ASK

Can acanthosis nigricans cause cancer? ▾

Is tripe palm a sign of cancer? ▾

What is acanthosis nigricans eruption? ▾

Feedback

[PDF] [Case Report Malignant acanthosis nigricans, tripe palms ...](#)

[https://www.gynecologiconcology-online.net/article/S0090-8258\(05\)01129-7/pdf](https://www.gynecologiconcology-online.net/article/S0090-8258(05)01129-7/pdf)

The presence of acanthosis nigricans in conjunction with tripe palms and the sign of Leser-Tre'lat are highly suggestive of an internal malignancy and necessitate an extensive investigation in order to discover the underlying malignancy. © 2005 Elsevier Inc.

[Malignant acanthosis nigricans, tripe palms and the sign ...](#)

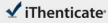
<https://www.sciencedirect.com/science/article/pii/S0090825805011297>

May 01, 2006 - Malignant acanthosis nigricans is a mucocutaneous eruption associated with internal malignancies. Tripe palms refers to a characteristic velvety thickening of the palms, with exaggeration of normal skin markings. The sign of Leser-Tre'lat is the presence of multiple seborrheic keratoses and

19-Oct-2020 11:05AM

3050 words • 4 matches • 2 sources

FAQ

 iThenticate

56859\_Auto\_Edited.docx

Quoted Included  
(Bibliography Included)

2%

1

Internet 45 words  
crawled on 07-May-2020  
[www.sigm.com](#)

2%

2

Internet 17 words  
crawled on 25-Jul-2020  
[www.spellman-publications.com](#)

1%

**Name of Journal:** *World Journal of Clinical Cases*

**Manuscript NO:** 56859

**Manuscript Type:** CASE REPORT

**Malignant acanthosis nigricans with Leser-Trélat sign and tripe palms: A case report**

Wang N *et al.* Malignant AN with Leser-Trélat sign and tripe palms

Ning Wang, Peng-Jie Yu, Zhi-Lin Liu, Sheng-Mao Zhu, Cheng-Wu Zhang

**Abstract**

BACKGROUND

Acanthosis nigricans (AN), Leser-Trélat sign, and tripe palm are all skin diseases. So far, reports of these appearing as a paraneoplastic syndrome in a gastric cancer patient

PDF 1 OF 11



Two-Only Report

国内版 国际版

Malignant acanthosis nigricans with Leser-Trélat sign and tripe pa



ALL

IMAGES

VIDEOS

12,800 Results

Any time ▾

Malignant acanthosis nigricans is a form of extensive and rapidly progressive AN, always associated with malignancy. As was reported in our case, malignant acanthosis nigricans can occur in conjunction with the sign of Leser-Tre'lat and **hyperkeratosis of the palms** (tripe palms) [ 8, 9, 10

**Author:** Mehdi M. Kebria, Jerome L. Belinson, Robert Kim, Tarek M. Mekhail

**Cited by:** 57

**Publish Year:** 2006

[Malignant acanthosis nigricans, tripe palms and the sign ...](#)

[www.gynecologiconcology-online.net/article/S0090-8258\(05\)01129-7/fulltext](http://www.gynecologiconcology-online.net/article/S0090-8258(05)01129-7/fulltext)

Was this helpful?

#### PEOPLE ALSO ASK

Can acanthosis nigricans cause cancer? ▾

What is acanthosis nigricans? ▾

Is tripe palm a sign of cancer? ▾

Feedback

[PDF] [Case Report Malignant acanthosis nigricans, tripe palms ...](#)

[https://www.gynecologiconcology-online.net/article/S0090-8258\(05\)01129-7/pdf](https://www.gynecologiconcology-online.net/article/S0090-8258(05)01129-7/pdf)

**Malignant acanthosis nigricans** is a mucocutaneous eruption associated with **internal malignancies**. **Tripe palms** refers to a. characteristic velvety thickening of the **palms**, with exaggeration of normal skin markings. The **sign of Leser-Tre'lat** is the presence of multiple.

[Malignant acanthosis nigricans, tripe palms and the sign](#)