

国内版

国际版



Endoscopic fenestration in the diagnosis and treatment of delayed :



ALL

IMAGES

VIDEOS

27,600 Results

Any time ▾

### Endoscopic Treatment of Various Gastrointestinal Tract ...

<https://www.ncbi.nlm.nih.gov/pmc/articles/PMC3994261>

Endoscopic submucosal dissection and enucleation are more frequently being used for the **diagnosis** and **treatment** of SETs. 12 Complications of such interventions include perforation, especially for deep-seated SETs of the fourth hypoechoic endosonographic layer. As in our final case, the OTSC system may be used for the management of perforation ...

Cited by: 5

Author: Woong Cheul Lee, Weon Jin Ko, Jun-Hyu...

Publish Year: 2014

### Review: Sealing the hole: endoscopic management of acute ...

<https://www.ncbi.nlm.nih.gov/pmc/articles/PMC6914298>

A systematic review by van Boeckel et al on using stents for benign rupture or **anastomotic** leakage of the oesophagus concluded the effectiveness and safety of placing stents for 6–8 weeks as a **treatment** option. 23 The systematic review did not show any superiority of any type of stent. Limitations of stents include migration, which seems to ...

Author: Ahmed Gabr

Publish Year: 2020

### Stricture Occurring after Endoscopic Submucosal Dissection ...

<https://www.ncbi.nlm.nih.gov/pmc/articles/PMC4260099>

Endoscopic submucosal dissection (ESD) is a widely accepted **treatment** for early gastric and esophageal cancer. Compared to **endoscopic** mucosal resection, ESD has the advantage of enabling en bloc removal of tumors regardless of their size. However, ESD can result in a large artificial ulcer, which may lead to a considerable deformity.

Cited by: 9

Author: Gwang Ha Kim, Sam Ryong Jee, Jae You...

Publish Year: 2014

### Delayed perforation: A hazardous complication of ...

<https://onlinelibrary.wiley.com/doi/abs/10.1111/den.12104>

Apr 29, 2013 · A total of 63 patients (41 with adenomas and 22 with carcinomas) underwent **endoscopic** mucosal resection (EMR) or **endoscopic** submucosal dissection (ESD) from January 1993 to December 2011. Incidence, outcome, and factors associated with occurrence of **delayed** ...

Cited by: 98

Author: Takuya Inoue, Noriya Uedo, Takeshi Yam...

Publish Year: 2014

Microsoft Bing

国内版

国际版

Endoscopic fenestration in the diagnosis and treatment of delayed :

Sign in

ALL

IMAGES

VIDEOS

Add the GIVE with Bing extension

27,600 Results

Any time

Review: Sealing the hole: endoscopic management of acute ...

<https://www.ncbi.nlm.nih.gov/pmc/articles/PMC6914298>

A systematic review by van Boeckel et al on using stents for benign rupture or anastomotic leakage of the oesophagus concluded the effectiveness and safety of placing stents for 6-8 weeks as a treatment option. 23 The systematic review did not show any superiority of any type of stent. Limitations of stents include migration, which seems to ...

Author: Ahmed Gabr    Publish Year: 2020

Endoscopic Treatment of Various Gastrointestinal Tract ...

<https://www.ncbi.nlm.nih.gov/pmc/articles/PMC3994261>

Endoscopic submucosal dissection and enucleation are more frequently being used for the diagnosis and treatment of SETs.12 Complications of such interventions include perforation, especially for deep-seated SETs of the fourth hypoechoic endosonographic layer. As in our final case, the OTSC system may be used for the management of perforation ...

Cited by: 5    Author: Woong Cheul Lee, Weon Jin Ko, Jun-Hyung...

Publish Year: 2014

Role of endoscopic clipping in the treatment of ...

Search Tools

[Turn on Hover Translation \(开启取词\)](#)

激活 Windows

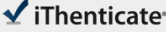
转到“设置”以激活 Windows

Feedback

20-Oct-2020 06:38PM

2143 words • 10 matches • 4 sources

FAQ

 iThenticate®

57240\_Auto\_Edited.docx

Quotes Included  
Bibliography Included

4%  
SIMILAR

**Name of Journal:** *World Journal of Clinical Cases*

**Manuscript NO:** 57240

**Manuscript Type:** CASE REPORT

Endoscopic fenestration in the diagnosis and treatment of delayed anastomotic submucosal abscess: **A case report and review of the literature**

Endoscopic fenestration for delayed submucosal abscess diagnosis

Bao-Zhen Zhang, Yi-Dan Wang, Ye Liao, Jing-Jing Zhang, Yu-Fan Wu, Xiao-Lin Sun, Si-Yu Sun, Jin-Tao Guo

Match Overview

1

Internet 55 words  
crawled on 26-Jan-2020  
[www.wjgnet.com](http://www.wjgnet.com)

2%

2

Crossref 28 words  
Nan Ge, Si-Yu Sun, "Endoscopic ultrasonography elastogr...  
phy in the diagnosis of intrapancreatic ectopic spleen: A cas

1%

3

Internet 9 words  
crawled on 01-Oct-2020  
[jmedicalcasereports.biomedcentral.com](http://jmedicalcasereports.biomedcentral.com)

<1%

4

Crossref 8 words  
H. Imazu, Y. Kawahara, S. Koyama, H. Tajiri, "Endoscopic ul  
trasound-guided transgastric drainage for omental bursa a ...

<1%

1

2

PAGE: 1 OF 10

激活 Windows  
转到“设置”以激活 Windows。 转到“设置”以激活 Windows。

Text-Only Report



### Review: Sealing the hole: endoscopic management of acute ...

<https://www.ncbi.nlm.nih.gov/pmc/articles/PMC6914298>

A systematic **review** by van Boeckel et al on using stents for benign rupture or **anastomotic** leakage of the oesophagus concluded the effectiveness and safety of placing stents for 6–8 weeks as a **treatment** option. 23 The systematic **review** did not show any superiority of any type of stent. Limitations of stents include migration, which seems to ...

**Author:** Ahmed Gabr **Publish Year:** 2020

### Delayed perforation: A hazardous complication of ...

<https://onlinelibrary.wiley.com/doi/abs/10.1111/den.12104>

Apr 29, 2013 · Yi Wei Fu, Mao Song Lin, Bing Yang, Hong Yu, Xia Jiao, Jun Xing Huang, An early superficial non-ampullary duodenal tumor cured with **endoscopic submucosal** dissection: **A case report**, Oncology Letters, 10.3892/ol.2017.6576, 14, 3, (3755–3759), (2017).

**Cited by:** 103

**Author:** Takuya Inoue, Noriya Uedo, Takeshi Ya...

**Publish Year:** 2014

### Endoscopic unroofing drainage with a needle-knife for ...

<https://www.ncbi.nlm.nih.gov/pmc/articles/PMC6835030>

A previous **report** described a **case** of severe phlegmonous gastritis arising as an adverse event of EUS-FNA.3 Risk factors for the development of GWA include **delayed** recovery of gastric mucosal injury (eg, due to diabetes mellitus, alcohol, or gastric ulcer), immune deficiency, and gastric secretion inhibitors.4 In our **case**, the patient had ...

**Author:** Gen Kimura, Yusuke Hashimoto, Ma... **Publish Year:** 2019

### Endoscopic tissue shielding with polyglycolic acid sheets ...

<https://onlinelibrary.wiley.com/doi/10.1111/den.12253>

Apr 20, 2014 · The incidence **of delayed** perforation after **endoscopic** resection for superficial non-ampullary duodenal epithelial tumors is extremely high. **Endoscopic** tissue shielding with polyglycolic acid (PGA ) sheets and fibrin glue is a promising method to prevent **delayed** perforation