



国内版

国际版

Hepatoid adenocarcinoma of the stomach: A report of 13 case



ALL

IMAGES

VIDEOS

关闭取词

1,050,000 Results

Any time ▼

Hepatoid adenocarcinoma of the stomach: A case report and ...

<https://www.ncbi.nlm.nih.gov/pmc/articles/PMC4473375>

Hepatoid adenocarcinoma (HAC) is a rare form of **gastric cancer** that has unique clinicopathological features and an extremely poor prognosis. The present **case report** describes a patient who was referred to the No. **461 Hospital of PLA** (Changchun, China) due ...

Author: Xiao-Mei Liu, Gui-Qiu Chen, Shun-Li ... **Publish Year:** 2015

Hepatoid adenocarcinoma of the stomach: A report of three ...

<https://www.ncbi.nlm.nih.gov/pmc/articles/PMC3718917>

Jul 21, 2013 · A recent analysis by Kumashiro et al compared the cellular phenotypes of **23 cases of hepatoid adenocarcinoma of the stomach** and showed **tubular adenocarcinomatous** components with **69 cases of non-hepatoid adenocarcinoma of the stomach**. The results suggested that **hepatoid adenocarcinoma** was derived from an **adenocarcinoma** with an intestinal phenotype and that its hepatoid ...

Cited by: 21 **Author:** Min-Feng Ye, Feng Tao, Fang Liu, Ai-Jing...

Publish Year: 2013

Hepatoid adenocarcinoma of the stomach: A case report and ...

https://www.researchgate.net/publication/277655747_Hepatoid_adenocarcinoma_of_the...

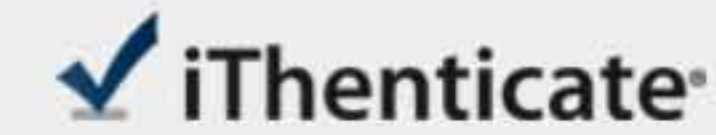
Download Citation | **Hepatoid adenocarcinoma of the stomach: A case report and literature review** |

Hepatoid adenocarcinoma (HAC) is a rare form of **gastric cancer** that has unique clinicopathological ...

Hepatoid adenocarcinoma of the stomach: A case report and ...

https://www.researchgate.net/publication/273508078_Hepatoid_adenocarcinoma_of_the...

Hepatoid adenocarcinoma of the stomach (HAS) is an extremely rare and unique **gastric**



Name of Journal: *World Journal of Clinical Cases*

Manuscript NO: 53217

Manuscript Type: CASE REPORT

Hepatoid adenocarcinoma of the stomach: Thirteen case reports and review of literature

Zhang ZR, *et al.* Thirteen cases of Hepatoid adenocarcinoma of the stomach

Abstract

BACKGROUND

The aim of the present study was to examine the clinical characteristics of

Match Overview

1	Crossref 26 words Sun Kyung Baek, Sae-Won Han, Do-Youn Oh, Seock-Ah Im, Tae-You Kim, Yung-Jue Bang. "Clinicopathologic characteristic	1%
2	Crossref 17 words Tanaka, S.. "Surgical outcome of patients with hepatocellular carcinoma originating in the caudate lobe", The American Journ	1%
3	Crossref 14 words Tetsuya Tsurumachi, Hiroshi Yamamoto, Kazuo Watanabe, Ichirou Honda et al. "Resection of liver metastasis from alpha-	<1%
4	Crossref 13 words Xiaowen Liu. "An analysis of clinicopathological features and prognosis by comparing hepatoid adenocarcinoma of the stom	<1%

[国内版](#)[国际版](#)[Chat with Bing](#)[Sign in](#)[ALL](#)[IMAGES](#)[VIDEOS](#)[Add Bing Firefox extension](#)

25,600 Results

Any time ▾

Hepatoid adenocarcinoma of the stomach: A case report and ...

<https://www.ncbi.nlm.nih.gov/pmc/articles/PMC4467275>

Hepatoid adenocarcinoma is a rare tumor, associated with an extremely poor prognosis. In the present report, a 72-year-old female presented to **Huashan Hospital** (Shanghai, China) with **upper abdominal discomfort** and, following endoscopy, an ulcerated lesion was observed in the stomach.

Cited by: 2**Author:** Ru Zhou, Yantao Cai, Yi Yang, Jianbin Xi...**Publish Year:** 2015

Hepatoid adenocarcinoma of the stomach: A case report and ...

<https://www.ncbi.nlm.nih.gov/pmc/articles/PMC4473375>

Hepatoid adenocarcinoma (HAC) is a rare form of **gastric cancer** that has unique clinicopathological features and an extremely poor prognosis. The present **case report** describes a patient who was referred to the No. 461 Hospital of PLA (Changchun, China) due to nausea and occasional vomiting of acid/water.

Author: Xiao-Mei Liu, Gui-Qiu Chen, Shun-Li ...**Publish Year:** 2015

Hepatoid Adenocarcinoma of the Stomach: A Challenging ...

<https://www.ncbi.nlm.nih.gov/pmc/articles/PMC5627014>

Sep 28, 2017 · **Hepatoid adenocarcinoma of the stomach** is a rare aggressive tumor with **hepatocellular** differentiation that often produces AFP. It occurs usually in elderly people with unclear pathogenesis. This entity was coined by Ishikura et al. in 1985 (3), and several **reports and reviews** were published thereafter (4 , 5).

Author: Najla Fakhruddin, Hisham Hf Bahmad...**Publish Year:** 2017

Hepatoid adenocarcinoma of the stomach: A case report and ...



国内版

国际版

Hepatoid adenocarcinoma of the stomach: Thirteen case repc



YJ



ALL

IMAGES

VIDEOS

25,500 Results

Any time ▾

Hepatoid adenocarcinoma of the stomach: A case report and ...

<https://www.ncbi.nlm.nih.gov/pmc/articles/PMC4467275>

Hepatoid adenocarcinoma is a rare tumor, associated with an extremely poor prognosis. In the present report, a 72-year-old female presented to **Huashan Hospital** (Shanghai, China) with **upper abdominal discomfort** and, following endoscopy, an ulcerated lesion was observed in the stomach.

Cited by: 2

Author: Ru Zhou, Yantao Cai, Yi Yang, Jianbin Xi...

Publish Year: 2015

Hepatoid adenocarcinoma of the stomach: A case report and ...

<https://www.ncbi.nlm.nih.gov/pmc/articles/PMC4473375>

Hepatoid adenocarcinoma (HAC) is a rare form of **gastric cancer** that has unique clinicopathological features and an extremely poor prognosis. The present **case report** describes a patient who was referred to the No. 461 Hospital of PLA (Changchun, China) due to nausea and occasional vomiting of acid/water.

Author: Xiao-Mei Liu, Gui-Qiu Chen, Shun-Li ...

Publish Year: 2015

Hepatoid Adenocarcinoma of the Stomach: A Challenging ...

<https://www.ncbi.nlm.nih.gov/pmc/articles/PMC5627014>

Sep 28, 2017 · **Hepatoid adenocarcinoma of the stomach** is a rare aggressive tumor with

hepatocellular differentiation that often produces AFP. It occurs usually in elderly people with unclear