

Name of Journal: *World Journal of Clinical Cases*

Manuscript NO: 53799

Manuscript Type: CASE REPORT

Curved ablation of liver cancer: A case report

Cao N *et al.* Curved ablation of liver cancer

Nan Cao, Huai-Jie Cai, Xi-Xi Sun, De-Lin Liu, Bin Huang

Abstract

BACKGROUND

1 Liver cancer is one of the most common malignant tumors with a high incidence and mortality. Hepatitis-liver cirrhosis-liver cancer is known as the trilogy of liver cancers. At present, due to significant development of imaging

Match Overview

1	Internet 16 words crawled on 08-Jan-2020 www.mdpi.com	1%
2	Internet 12 words crawled on 12-Jul-2019 www.wjgnet.com	1%



ALL

IMAGES

VIDEOS

关闭取词

239,000 Results

Any time ▼

Case report - PubMed Central (PMC)

<https://www.ncbi.nlm.nih.gov/pmc/articles/PMC3789050>

Primary Budd-Chiari syndrome (BCS) is a rare clinical entity characterized by a blocked **hepatic** venous outflow tract at various levels from the small **hepatic** veins to the inferior vena cava (IVC) (1,2). **Hepatocellular carcinoma (HCC)** is **one** of the major complications of BCS (3,4).

Cited by: 3**Author:** Qing-Qiao Zhang, Mao-Heng Zu, Hao ...**Publish Year:** 2013

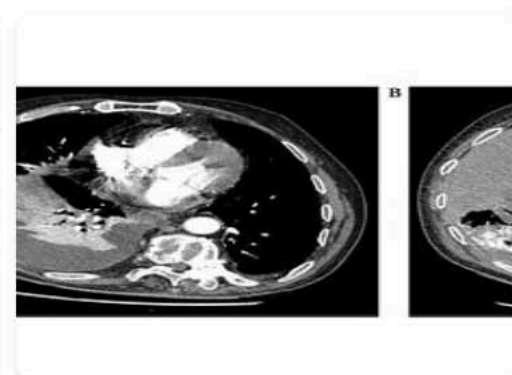
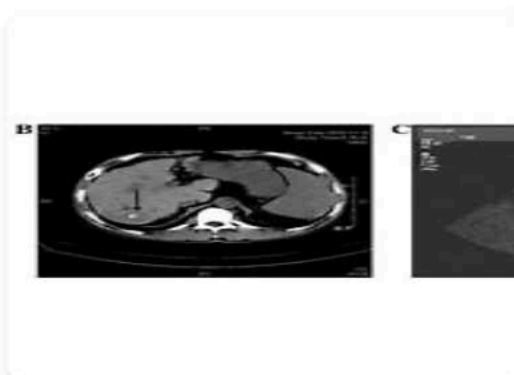
A Unique Case of Hepatocellular Carcinoma Treated with ...

<https://www.hindawi.com/journals/crim/2010/151846> ▼

A Unique **Case** of **Hepatocellular Carcinoma** Treated with **Radiofrequency Ablation** with More than **12** Years Overall Survival: A **Case Report** Loukas Thanos , **1** Nikolaos Ptohis , **2** Anastasia Pomoni , **2** Evangelia Sotiropoulou , **1** Mary Pomoni , **2** and Dimitrios Kelekis **2**

Author: Loukas Thanos, Nikolaos Ptohis, A...**Publish Year:** 2010

Images of Curved ablation of hepatocellular carcinoma Report of Tw...

<bing.com/images>[See more images of Curved ablation of hepatocellular carcinoma Report of Two Cases](#)



国内版

国际版

Curved ablation of liver cancer: A case report



登录



网页

图片

视频

学术

词典

地图

检测到您输入了英文，试试切换到国际版？搜英文结果更丰富更准确



768,000 条结果

时间不限

Liver Ablation: Best Practice [翻译此页](#)

Cited by: 55

Author: Shane A. Wells, J. Louis Hinshaw, Megha...

Publish Year: 2015

位置: 8600 Rockville Pike, Bethesda, MD

2020-4-9 · Tumor ablation in the liver has evolved to become a well-accepted tool in the management of increasingly complex oncologic patients. Ablative therapies can be used alone, in conjunction with other ablative therapies, or in combination with other oncologic treatment strategies, such as surgery ...

<https://www.ncbi.nlm.nih.gov/pmc/articles/PMC6419975>

Radiofrequency ablation of liver metastasis from ... [翻译此页](#)

Cited by: 17

Author: Michael O Bojalian, Gustavo R Machado, ...

Publish Year: 2004

Radiofrequency ablation of liver metastasis from ovarian adenocarcinoma: case report and literature review. ... Thus, liver resection is safe and may provide a survival advantage for patients with metastatic ovarian cancer to the liver.

<https://www.sciencedirect.com/science/article/pii/S0090825804000691>

Liver radiofrequency ablation as emergency treatment ... [翻译此页](#)

Cited by: 1

Author: Alessandra Bertacco, Alessandra Bertacc...

Publish Year: 2017



ALL IMAGES VIDEOS MAPS NEWS SHOPPING

Also try: [ablation therapy for liver cancer](#) · [radiofrequency ablation for liver cancer](#)

69,300 Results Any time ▾

Nan Cao Bin Huang, Huai-Jie Cai, Xi-Xi Sun, De-Lin Liu

[https://apcio2019.com/ePoster/EPosters/\(EP 005\).pdf](https://apcio2019.com/ePoster/EPosters/(EP 005).pdf)

case report. Nan Cao, Bin Huang, Huai-Jie Cai, Xi-Xi Sun, De-Lin Liu ... **Curved ablation** plays a positive role in the **ablation of liver cancer** with special parts, which expands the adaptive range ... +

Irreversible electroporation for liver metastasis from ...

<https://www.ncbi.nlm.nih.gov/pmc/articles/PMC7000941>

Jan 26, 2020 · We **report** the **case** of a 66-year-old female patient with **liver metastasis** from **pancreatic cancer** who underwent **synchronous IRE ablation of liver** and ... +

Author: Yang-Yang Ma, Juan-Juan Shi, Ji-Bin... **Publish Year:** 2020

Case Study: 33-Year-Old With Liver-Metastatic Colorectal ...

[https://www.onclive.com/insights/liver-metastases/...](https://www.onclive.com/insights/liver-metastases/)

In this segment, David Liu, MD, shares a **case** study based on a 33-year-old woman with stage IV colorectal **cancer** that had metastasized to the **liver**.

[PDF] CASE REPORT Transarterial radioembolization for liver ...

www.scielo.br/pdf/eins/v18/2317-6385-eins-18-eRC4990.pdf

To **report** 3 cases of **liver** tumors in which transarterial radioembolization of the **liver** was used as a neoadjuvant therapy. **CASE REPORT Case 1** A 68-year-old man with multinodular hepatocellular ... +

Author: Vithor de Oliveira Carvalho, Francisco... **Publish Year:** 2020

Systematic review and meta-analysis of local ablative ...

<https://www.sciencedirect.com/science/article/pii/S0748798319314969>

Introduction. Colorectal **liver** metastases (CRLM) is the most common type of **liver** malignancy; about 20% of patients affected by colorectal **cancer** will be diagnosed with synchronous **liver** ... +

Author: Marcello Di Martino, Gianluca Rompia... **Publish Year:** 2019

Hepatopulmonary syndrome after radiofrequency ablation of ...

<https://www.ncbi.nlm.nih.gov/pubmed/31040688>

Related searches

ablation **therapy for** liver cancer

radiofrequency ablation **for** liver cancer

liver cancer ablation **surgical method**

chemo ablation liver cancer

microwave ablation liver cancer

liver **tumor** ablation **side effects**