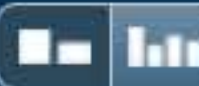


Match Overview



Name of Journal: *World Journal of Clinical Cases*

Manuscript NO: 55064

Manuscript type: LETTER TO THE EDITOR

Rare primary lymphoepithelioma-like carcinoma of the renal pelvis

Lai SC *et al.* Lymphoepithelioma-like carcinoma of the renal pelvis

Shi-Cong Lai, Samuel Seery, Tong-Xiang Diao, Jian-Ye Wang, Ming Liu

There are no matching sources for this report.



国内版

国际版

A rare primary lymphoepithelioma-like carcinoma of the



ALL

IMAGES

VIDEOS

33,700 Results

Any time ▾

Lymphoepithelioma is a malignant tumour found in the nasopharynx. When this tumour is found in other sites of the body, it is referred to as lymphoepithelioma-like carcinoma (LELC). LELC of the renal pelvis is extremely rare and, to our knowledge, this is the seventh reported case.

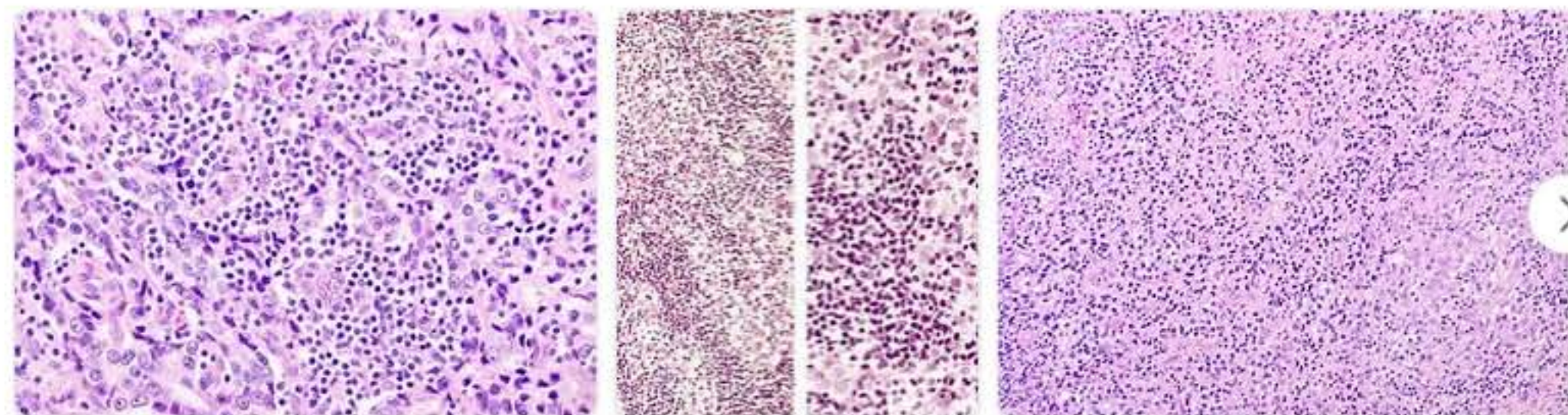
[Lymphoepithelioma-like carcinoma of the renal pelvis ...](#)

www.ncbi.nlm.nih.gov/pmc/articles/PMC3776035/

Was this helpful?

[Images of A rare primary Lymphoepithelioma-like carcinoma ...](#)

bing.com/images



[See more images of A rare primary Lymphoepithelioma-like carcinoma of the Renal Pelvis](#)

[Lymphoepithelioma-like Carcinoma of the Renal Pelvis: A ...](#)

Lymphoepithelioma

Lymphoepithelioma is a type of poorly differentiated nasopharyngeal carcinoma characterized by prominent infiltration of lymphocytes into the area involved by tumor. Lymphoepithelioma is also known as "class III nasopharyngeal carcinoma" in the WHO classification system. It has a high tendency to metastasize and is responsive to radiotherapy. Most cases are associated with Epstein-Barr virus infection.



Wikipedia

People also search for

[Adenocarcinoma](#)

[Carcinoma](#)

[Basal Cell Carcinoma](#)

[Adenoma](#)

[Papilloma](#)

[See more ▾](#)

Data from: Wikipedia

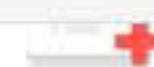[Suggest an edit](#)

Chat with Bing



Can chat with a search engine, you're not an ordinary human.

Say something...



extension

MAYBE LATER

YES

Rare primary lymphoepithelioma-like carcinoma of the re



ALL

IMAGES

VIDEOS

37,400 Results

Any time ▼

Lymphoepithelioma is a malignant tumour found in the nasopharynx. When this tumour is found in other sites of the body, it is referred to as lymphoepithelioma-like carcinoma (LELC). LELC of the renal pelvis is extremely rare and, to our knowledge, this is the seventh reported case.

[Lymphoepithelioma-like carcinoma of the renal pelvis ...](#)

www.ncbi.nlm.nih.gov/pmc/articles/PMC3776035/

Was this helpful?  

[Lymphoepithelioma-like carcinoma of the renal pelvis ...](#)

<https://www.ncbi.nlm.nih.gov/pmc/articles/PMC3776035>

Sep 10, 2013 · **Lymphoepithelioma** is a malignant tumour found in the nasopharynx. When this tumour is found in other sites of the body, it is referred to as **lymphoepithelioma-like carcinoma (LELC)**. **LELC of the renal pelvis** is extremely **rare** and, to our knowledge, this is the seventh reported case.

[Lymphoepithelioma-like Carcinoma of the Renal Pelvis: A ...](#)



Rare primary lymphoepithelioma-like carcinoma of the r



ALL IMAGES VIDEOS MAPS NEWS SHOPPING

39,200 Results

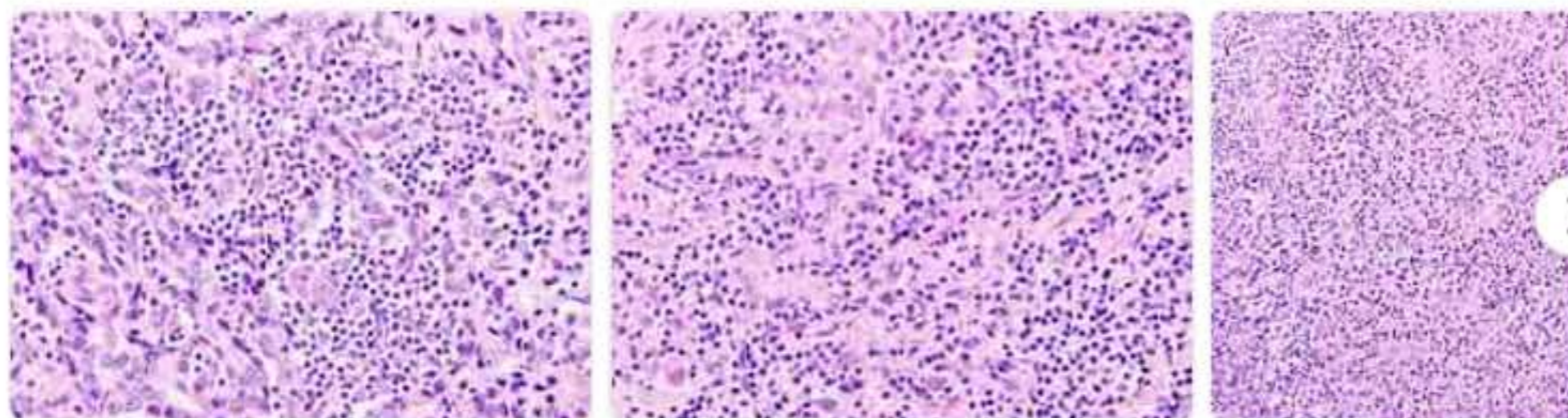
Any time ▾

Lymphoepithelioma is a malignant tumour found in the nasopharynx. When this tumour is found in other sites of the body, it is referred to as lymphoepithelioma-like carcinoma (LELC). LELC of the renal pelvis is extremely rare and, to our knowledge, this is the seventh reported case.

[Lymphoepithelioma-like carcinoma of the renal pelvis ...](#)
www.ncbi.nlm.nih.gov/pmc/articles/PMC3776035/

Was this helpful?

[Images of rare primary Lymphoepithelioma-like carcinoma of the R...](#)
bing.com/images



[See more images of rare primary Lymphoepithelioma-like carcinoma of the Renal pelvis](#)

[Lymphoepithelioma-like carcinoma of the renal pelvis ...](#)
<https://www.ncbi.nlm.nih.gov/pmc/articles/PMC3776035>

Sep 10, 2013 - **Lymphoepithelioma** is a malignant tumour found in the nasopharynx. When this tumour is found in other sites of the body, it is referred to as **lymphoepithelioma-like carcinoma (LELC)**. **LELC of the renal pelvis** is extremely **rare** and, to our knowledge, this is the seventh reported case.

Lymphoepithelioma

Lymphoepithelioma is a type of poorly differentiated nasopharyngeal carcinoma characterized by prominent infiltration of lymphocytes in the area involved by tumor. Lymphoepithelioma is also known as "class III nasopharyngeal carcinoma" in the WHO classification system. It has a high tendency to metastasize and is responsive to radiotherapy. Most cases are associated with Epstein-Barr virus infection.

Wikipedia

People also search for

[Adenocarcinoma](#)
[Adenoma](#)
[Basal Cell Carcinoma](#)
[Carcinoma](#)
[Papilloma](#)
[See more ▾](#)

Data from: Wikipedia

[Suggest an edit](#)