

国内版国际版

Microsoft Bing

Robotically assisted removal of pelvic splenosis fifty-six years after

Sign in

Chat with Bing

ALLIMAGESVIDEOS

4,610 ResultsAny time

Robotically assisted laparoscopic management of pelvic ...

<https://www.researchgate.net/publication/251197198...>

Robotically assisted laparoscopy is a superior technique for the management of abdominopelvic splenosis, which is an often unsuspected cause of pelvic pain.

(PDF) Laparoscopic Management of Pelvic Splenosis

<https://www.researchgate.net/publication/270616837...>

Case: A 45-year-old multiparous woman who had a splenectomy in childhood after trauma presented complaining of a long history of chronic pelvic pain and postcoital bleeding.

Robot-assisted partial and total splenectomy | Request PDF

<https://www.researchgate.net/publication/51668805...>

We report, to our knowledge, the first case of robot-assisted splenectomy following embolization of the splenic artery in a 15-year-old patient with chronic immune thrombocytopenia, worsened by a ...

Abdominal splenosis and its differential diagnoses: What ...

<https://www.sciencedirect.com/science/article/pii/S036301882030102X>

May 19, 2020 · Introduction. Splenosis is a benign acquired condition characterized by heterotopic auto-




Search Tools

Turn off Hover Translation (关闭取词)

Microsoft Bing

国内版 国际版

Robotically assisted removal of pelvic splenosis fifty-six years after



ALL IMAGES VIDEOS

4,810 Results Any time


Robotically assisted laparoscopic management of pelvic ...
<https://www.researchgate.net/publication/251197198...>
Robotically assisted laparoscopy is a superior technique for the management of abdominopelvic splenosis, which is an often unsuspected cause of pelvic pain.

Robot-assisted partial and total splenectomy | Request PDF
<https://www.researchgate.net/publication/51668805...>
We report, to our knowledge, the first case of robot-assisted splenectomy following embolization of the splenic artery in a 15-year-old patient with chronic immune thrombocytopenia, worsened by a ...

(PDF) Laparoscopic Management of Pelvic Splenosis
<https://www.researchgate.net/publication/270616837...>
Case: A 45-year-old multiparous woman who had a splenectomy in childhood after trauma presented complaining of a long history of chronic pelvic pain and postcoital bleeding.

Splenosis presenting with adnexal mass: A case report ...
<https://www.researchgate.net/publication/8266346...>
A case of a 35-year-old woman with acute traumatic splenectomy reconstruction with four splenectomy nodes and

Chat with Bing

 Am I the most talkative search engine you have ever used?

Say something...

SEARCH TOOLS

Turn on Hover Translation (开始翻译)

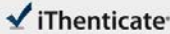
激活 Windows

转到“设置”以激活 Windows。

08-Jan-2021 01:46PM

1703 words • 4 matches • 4 sources

FAQ

 iThenticate

61016_Auto_Edited.docx

Quotes Excluded
Bibliography Excluded

3%
Matched

Name of Journal: *World Journal of Clinical Cases*

Manuscript NO: 61016

Manuscript Type: CASE REPORT

Robotically assisted removal of pelvic splenosis fifty-six years after splenectomy: a case report

Tognarelli A et al. Pelvic splenosis after splenectomy

Alessio Tognarelli, Lorenzo Faggioni, Anna Paola Erba, Pinuccia Faviana, Jacopo Durante, Francesca Manassero, Cesare Selli

Match Overview

1

Internet 20 words
crawled on 13-Apr-2019
asianamale.ctsnetjournals.org

1%

2

Crossref 16 words
[Bariatric Surgery, 2012](#)

1%

3

Internet 13 words
crawled on 05-Jul-2020
www.vjgnet.com

1%

4

Crossref 12 words
[Surgery for Cancers of the Gastrointestinal Tract, 2015](#)

1%

PAGE: 1 OF 8

激活 Windows
转到“设置”以激活 Windows。 如果没有密钥，请转到“设置”以激活 Windows。

Test-Only Report

Robotically assisted laparoscopic management of pelvic ...

<https://www.researchgate.net/publication/251197198...>

Robotically assisted laparoscopy is a superior technique for the management of abdominopelvic splenosis, which is an often unsuspected cause of pelvic pain.

(PDF) Laparoscopic Management of Pelvic Splenosis

<https://www.researchgate.net/publication/270616837...>

Case: A 45-year-old multiparous woman who had a splenectomy in childhood after trauma presented complaining of a long history of chronic pelvic pain and postcoital bleeding.

Splenosis presenting with adnexal mass: A case report ...

<https://www.researchgate.net/publication/8266346...>

A case of a 35 year old woman, with post-traumatic splenectomy presenting with low abdominal pain and pelvic mass is reported. Laparoscopic removal of the pelvic splenic implants dispelled all ...

Abdominal splenosis and its differential diagnoses: What ...

<https://www.sciencedirect.com/science/article/pii/S036301882030102X>

May 19, 2020 · Introduction. Splenosis is a benign acquired condition characterized by heterotopic auto-transplantation of splenic tissue. 1 The true incidence of this condition is unknown because splenosis is usually an incidental finding at surgery, autopsy, or imaging. However, splenosis has been reported in up to 67% of patients with history of splenic trauma. 2, 3 ...

Author: Federica Vernuccio, Federica Vernucc... Publish Year: 2020

(PDF) Abdominal splenosis - ResearchGate

https://www.researchgate.net/publication/51595595_Abdominal_splenosis

purpura due to splenosis 12 years after splenectomy (30) ... Fifty-six articles with 59 reported cases were included. The majority of the patients were male (n = 49, 83.1%). ... This is the case ...