

ALL

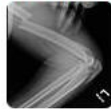IMAGES

VIDEOS

58,600 Results

Any time ▾

Floating Elbow: Background, Anatomy, Etiology

<https://emedicine.medscape.com/article/1231103-overview> ▾


Jul 05, 2018 · Floating elbow is an injury pattern involving a fracture of the humerus and a fracture of the radius and/or the ulna in the same extremity. This injury may be associated with an elbow dislocation...

Floating Elbow Treatment & Management: Approach ...

<https://emedicine.medscape.com/article/1231103-treatment> ▾


Jul 05, 2018 · The term floating elbow was first introduced by Stanitski and Micheli to describe an injury pattern in children involving concomitant fractures of the forearm axis and supracondylar humerus in the...

An unusual pattern of segmental forearm fracture in the ...

<https://www.researchgate.net/publication/227998363>...

Simultaneous ipsilateral fracture of the elbow and forearm--floating elbow--is an uncommon injury. ... We would like to report a case of treating a segmental fracture of ulnar shaft, with a ...

Concomitant Olecranon Fracture, Ipsilateral Segmental ...

<https://www.ncbi.nlm.nih.gov/pmc/articles/PMC3876514>

1. Introduction. T-condylar fracture of distal humerus in young children is very rare (1-4). Pure physeal fractures of the olecranon are also rare (). We report a rare case of concomitant olecranon fracture, ipsilateral segmental humerus and intercondylar humerus fracture (type III) in ...

Cited by: 1

Author: Mohammad Hossein Ebrahimzadeh, Ali ...

Publish Year: 2013

Bipolar clavicular fracture on ipsilateral reverse ...

<https://www.ncbi.nlm.nih.gov/pmc/articles/PMC6849076>

Case presentation. We report a case of a 78y.o female patient with left bipolar clavicular fracture on ipsilateral reverse shoulder prosthesis, associated with multiple ribs fracture, that was treated with open reduction and internal fixation using k-wires and endobutton for the lateral part, while as the medial part was fixed with plate and screws.

ALL IMAGES VIDEOS

55,400 Results Any time ▾

[Floating Elbow: Background, Anatomy, Etiology](#)

<https://emedicine.medscape.com/article/1231103-overview> ▾



Jul 05, 2018 - Floating elbow is an injury pattern involving a fracture of the humerus and a fracture of the radius and/or the ulna in the same extremity. This injury may be associated with an elbow dislocation...

[Floating Elbow Treatment & Management: Approach ...](#)

<https://emedicine.medscape.com/article/1231103-treatment> ▾



Jul 05, 2018 - The term **floating elbow** was first introduced by Stanitski and Micheli to describe an injury pattern in children involving concomitant fractures of the forearm axis and supracondylar humerus in the...

PEOPLE ALSO ASK

What is floating elbow fracture? ▾

How is supracondylar humerus fracture treated? ▾

Search Tools

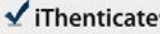
Turn off Hover Translation (关闭翻译)

激活 Windows
转到“设置”以激活 Windows。

23-Feb-2021 12:51PM

1788 words • 7 matches • 6 sources

FAQ

 iThenticate®

60690_Auto_Edited.docx

Quotes Excluded
Bibliography Excluded

11%
similarity

4

Name of Journal: *World Journal of Clinical Cases*

Manuscript NO: 60690

Manuscript Type: CASE REPORT

Floating elbow combining ipsilateral distal multiple segmental forearm fractures: a case report

a case of special Floating elbow

GUO-HUA HUANG, JIANG-AN TANG, TIE-YI YANG, YUE LIU

Match Overview

1

Internet 72 words
crawled on 09-Aug-2020
journals.haw.com

4%

2

Internet 41 words
crawled on 31-Dec-2020
juniperpublishers.com

2%

3

Crossref 35 words
Vijay Coni, Prateek Behera, Umesh Kumar Meena, Nirmal r
aj Gopinathan, Narendranadh Akkina, R.H.H. Arjun "Elbow

2%

4

Internet 19 words
crawled on 26-Aug-2020
www.wjgnet.com

1%

5

Crossref Posted Content 14 words
Alvin Chao-Yu Chen, Chun-Jui Weng, Chih-Hao Chiu, Shih-
Sheng Chang, Chun-Ying Cheng, Yi-Sheng Chan, "Retros

1%

6

Internet 14 words
crawled on 20-Aug-2020
ifpublishing.blob.core.windows.net

1%

PDF icon

FILE

PAGE 1 OF 8

Search icon

Zoom slider

Print icon

Fullscreen icon

Test Only Report

Run Windows
转到设置以启用 Windows

国内版 国际版

Floating elbow combining ipsilateral distal multiple segmental forea

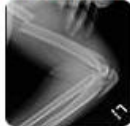

ALL IMAGES VIDEOS

55,100 Results Any time ▾

Floating Elbow: Background, Anatomy, Etiology

<https://emedicine.medscape.com/article/1231103-overview> ▾



Jul 05, 2018 · Floating elbow is an injury pattern involving a fracture of the humerus and a fracture of the radius and/or the ulna in the same extremity. This injury may be associated with an elbow dislocation...

Floating Elbow Treatment & Management: Approach ...

<https://emedicine.medscape.com/article/1231103-treatment> ▾



Jul 05, 2018 · The term **floating elbow** was first introduced by Stanitski and Micheli to describe an injury pattern in children involving **concomitant fractures of the forearm axis and supracondylar humerus** in the...

PEOPLE ALSO ASK

What is floating elbow fracture? ▾

How is supracondylar humerus fracture treated? ▾

What is internal fixation of bone forearm? ▾

How to treat Monteggia fracture? ▾

Feedback

An unusual pattern of segmental forearm fracture in the ...

<https://www.researchgate.net/publication/227998363...>

Simultaneous ipsilateral fracture of the elbow and forearm--floating elbow--is an uncommon injury. ... We would like to report a case of treating a segmental fracture of ulnar shaft, with a ...

Concomitant Ulecranon Fracture, Ipsilateral Segmental ...

<https://www.ncbi.nlm.nih.gov/pmc/articles/PMC3876514>

1. Introduction. T-condylar fracture of distal humerus in young children is very rare (1-4).Pure physeal fracture of the elbow...
... of the elbow...
... of the elbow...