

Match Overview

- 1** **Crossref** 14 words
Yoshihisa Takahashi. "Sarcomatoid carcinoma with compon ...
nts of small cell carcinoma and undifferentiated carcinoma of t 1%
- 2** **Internet** 13 words
crawled on 23-Apr-2021
apm.amegroups.com 1%

Name of Journal: *World Journal of Clinical Cases*

Manuscript NO: 65537

Manuscript Type: CASE REPORT

Primary hepatic neuroendocrine tumor: a case report with 18F-FDG PET/CT findings

A case report of PHNET

Abstract

BACKGROUND

Primary hepatic neuroendocrine tumors (PHNETs) are rare hepatic tumors. Their diagnosis based on radiological findings is difficult.

CASE SUMMARY

We present a case of PHNET in a 79-year-old man with no clinical symptoms. Computed tomography (CT) and 2-Deoxy-2-[fluorine-18] fluorodeoxyglucose positron emission tomography/CT (¹⁸F-FDG PET/CT) were performed for further evaluation. A

Primary hepatic neuroendocrine tumor: a case report with 18F-FDG



ALL

IMAGES

VIDEOS

66,000 Results

Any time ▾

Open links in new tab



18F-FDG-PET/CT Findings of a Primary Hepatic ...

<https://www.sciforschenonline.org/journals/clinical-case-studies/JCCS194.php> ▾

18 F-FDG-PET/CT Findings of a Primary Hepatic Neuroendocrine Tumor: A Case Report and Literature Review. Bo Pan 1* Shi-Cun Wang 1 Zong-Ke Chen 1 Gui-Chang Zou 2* . 1 PET/CT Center, T...

(PDF) 18F-FDG-PET/CT Findings of a Primary Hepatic ...

<https://www.researchgate.net/publication/339307808...>

PDF | On Jan 1, 2020, Pan B and others published 18F-FDG-PET/CT Findings of a Primary Hepatic Neuroendocrine Tumor: A Case Report and Literature Review | Find, read and cite all the research y...

Primary hepatic neuroendocrine tumors: A case report ...

<https://journals.lww.com/md-journal/Fulltext/2019/...>

1 Introduction. Neuroendocrine tumors (NET) account for about 1% to 2% of all gastrointestinal tumor cases. However, PHNET is extremely rare. Edmonson et al reported PHNET for the first time. So far, th...

Primary hepatic neuroendocrine tumor: A case report and ...

<https://www.sciencedirect.com/science/article/pii/S2210261220303588>

Jan 01, 2020 · Primary hepatic neuroendocrine tumors are rare neoplasms, with less than 200 cases reported. The clinical presentation of PHNETs is non-specific and its radiologic features are intensely...

Author: Adriano C. Costa, Fernando Santa-Cr... Publish Year: 2020

(18)F-FDG PET/CT Imaging of Primary Hepatic ...

<https://europepmc.org/articles/PMC4937691> ▾

Jan 01, 2015 · F-18 fluorodeoxyglucose (18 F-FDG) positron emission tomography (PET) and fused PET/CT images showed increased uptake in the hepatic mass. Whole-body 18 F-FDG PET images...

Cited by: 2 Author: Katsuya Mitamura, Yuka Yamamoto, Ken...

Publish Year: 2015

(18)F-FDG PET/CT Imaging of Primary Hepatic ...

<https://www.researchgate.net/publication/305498539...>

F-18 fluorodeoxyglucose ((18)F-FDG) positron emission tomography (PET) and fused PET/CT images

ALL

IMAGES

VIDEOS

73,500 Results

Any time ▼

18F-FDG-PET/CT Findings of a Primary Hepatic ...

<https://www.sciforschenonline.org/journals/clinical-case-studies/JCCS194.php> ▼

18 F-FDG-PET/CT Findings of a Primary Hepatic Neuroendocrine Tumor: A Case Report and Literature Review. Bo Pan 1* Shi-Cun Wang 1 Zong-Ke Chen 1 Gui-Chang Zou 2* . 1 **PET/CT** Center, The First...

(PDF) 18F-FDG-PET/CT Findings of a Primary Hepatic ...

<https://www.researchgate.net/publication/339307808...>

PDF | On Jan 1, 2020, Pan B and others published **18F-FDG-PET/CT Findings of a Primary Hepatic Neuroendocrine Tumor: A Case Report** and Literature Review | Find, read and cite all the research you ...

Primary hepatic neuroendocrine tumors: A case report ...

<https://journals.lww.com/md-journal/Fulltext/2019/...>

1 Introduction. **Neuroendocrine tumors** (NET) account for about 1% to 2% of all gastrointestinal **tumor** cases. However, PHNET is extremely rare. Edmonson et al reported PHNET for the first time. So far, the...

(18)F-FDG PET/CT Imaging of Primary Hepatic Neuroendocrine ...

<https://europepmc.org/articles/PMC4937691> ▼

Jan 01, 2015 · **F-18 fluorodeoxyglucose (18 F-FDG)** positron emission tomography (PET) and fused **PET/CT** images showed increased uptake in the **hepatic** mass. Whole-body **18 F-FDG PET** images...

Cited by: 3

Author: Katsuya Mitamura, Yuka Yamamoto, Kenic...

Publish Year: 2015

(18)F-FDG PET/CT Imaging of Primary Hepatic Neuroendocrine ...

<https://www.researchgate.net/publication/305498539...>

ALL IMAGES VIDEOS MAPS NEWS SHOPPING

64,400 Results

Any time ▾

18F-Fluorodeoxyglucose positron emission tomography ...

<https://www.ncbi.nlm.nih.gov/pubmed/29381956>

18F-Fluorodeoxyglucose positron emission tomography computed tomography detection threshold in follicular lymphoma: **A case report**. Péricart S(1), Martin-Blondel G(2), Franchet C(1), Hitzel A(3), Brouss...

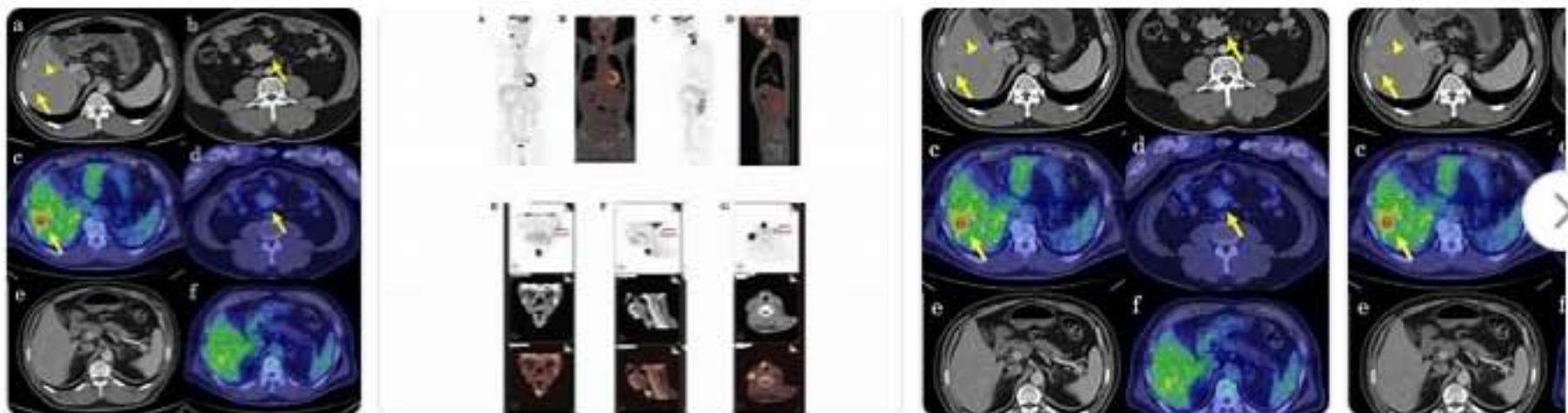
Cited by: 1

Author: Sarah Péricart, Guillaume Martin-Blondel, C...

Publish Year: 2017

Images of Primary liver neuroendocrine Tumor "18f Fluorodeoxygl...

<bing.com/images>



See all images >

18F-fluorodeoxyglucose positron emission tomography ...

<https://journals.lww.com/md-journal/Fulltext/2020/...>

Jul 24, 2020 · ositron emission tomography/computed tomography (PET/CT), it may be necessary to perform FDG PET/CT for immediate diagnosis and treatment of DNM. To the best of our knowledge, this...

Primary neuroendocrine carcinoma of breast with liver and ...

<https://www.ncbi.nlm.nih.gov/pmc/articles/PMC3928748>

We **report** the **case** of a 45-year-old woman presented with jaundice and evaluated to have **liver** metastasis from **neuroendocrine** origin. She underwent whole body **positron emission**...

Cited by: 2

Author: Koramadai Karuppusamy Kamaleshwaran, ...

Publish Year: 2014