

## Match Overview

1	Internet 47 words crawled on 04-Oct-2020 <a href="http://www.wjnet.com">www.wjnet.com</a>	2%
2	Internet 12 words crawled on 19-Aug-2020 <a href="http://mafiadoc.com">mafiadoc.com</a>	1%

**Name of Journal:** *World Journal of Clinical Cases*

**Manuscript NO:** 67965

**Manuscript Type:** CASE REPORT

**Menetrier's disease and differential diagnosis: A case report**

Hou-Hong Wang, Can-Can Zhao, Xiao-Lei Wang, Ze-Nong Cheng, Zong-Yu Xie

### Abstract

#### BACKGROUND

Gastric mucosal hypertrophy, also known as Menetrier's disease (MD), is more common in men over 50 years of age, and the cause is unknown. The symptoms of the disease are atypical, mostly accompanied by hypoproteinemia and edema, and sometimes

A case of giant gastric hypertrophy



ALL

IMAGES

VIDEOS

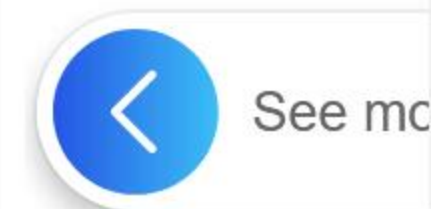
3,920,000 Results

Any time ▼

A diagnosis of giant hypertrophic gastritis may be suspected in individuals with large gastric folds. Large gastric folds may be diagnosed by an endoscopy, a procedure in which a thin, flexible tube (endoscope) is inserted through the mouth and used to examine the interior of the stomach and obtain tissue samples for microscopic study (biopsy).

Gastritis, Giant Hypertrophic - NORD (National ...

 [rarediseases.org/rare-diseases/gastritis-giant-hypertrophic/](https://rarediseases.org/rare-diseases/gastritis-giant-hypertrophic/)



Menetrier's disease and differential diagnosis: A case report



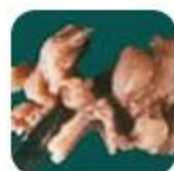ALL

IMAGES

VIDEOS

9,850,000 Results

Any time ▾



## Ménétrier's disease

Rare Acquired Premalignant Disease



**Differential Diagnosis**

Classification

Epidemiology

Management



Imaging differential considerations for diffuse rugal thickening include 1. gastric lymphoma / may also occur as part of post-transplant lymphoproliferative disorder affecting the stomach 2. forms of gastritis 1. infective gastritis 2. radiation gastritis 3. eosinophilic gastritis...

[See more on radiopaedia.org](https://radiopaedia.org)

W

See

2,370,000 Results

Any time ▾



## Ménétrier's disease

Rare Acquired Premalignant Disease



Differential Diagnosis

Classification

Epidemiology

Management



Imaging differential considerations for diffuse rugal thickening include 1. gastric lymphoma / may also occur as part of post-transplant lymphoproliferative disorder affecting the stomach 2. forms of gastritis 1. infective gastritis 2. radiation gastritis 3. eosinophilic gastritis...

[See more on radiopaedia.org](#)

The condition needs to be differentiated from other forms of hypertrophic gastropathy such as Zollinger-Ellison syndrome, hypertrophic hypersecretory gastropathy, lymphocytic gastritis, or gastric carcinoma.[5, 6]

[See more on patient.info](#)

## Ménétrier's disease

Rare Acquired Premalignant Disease

Symptoms

Diagnosis

Causes

Treatments



Ménétrier disease is a rare, acquired, premalignant disease of the stomach characterized by massive gastric folds, excessive mucous production with resultant protein loss, and little or no acid production. The disorder is associated with excessive secretion of transforming growth factor alpha. It is named after a French physician Pierre Eugène Ménétrier, 1859–1935.

 [Wikipedia](#)

Data from: Wikipedia

[Suggest an edit](#)

### [Menetrier's disease: a case report].

<https://www.ncbi.nlm.nih.gov/pubmed/11471452>

[Menetrier's disease: a case report]. [Article in French] Elloumi H, Belhadj N, Kharrat J, Mechergui R, Letaief A, Ben Ayed M, Ghorbel A. **Menetrier's disease** is an uncommon reason of hypertrophic gastropathy. The **diagnosis** is suspected when clinic, endoscopic and radiologic criteria are associated and is confirmed by histologic features which ...

**Author:** H Elloumi, N Belhadj, J Kharrat, R Mech...

**Publish Year:** 2001

### Ménétrier's disease presenting as recurrent unprovoked ...

<https://www.ncbi.nlm.nih.gov/pubmed/30651128>

Jan 17, 2019 · CASE PRESENTATION: We **report** the **case** of a 40-year-old white man who presented with unprovoked deep venous thrombosis, pulmonary embolism, and renal vein thrombosis. Upon receiving therapeutic anticoagulation, he developed severe gastrointestinal bleeding, and endoscopic evaluation led to a **diagnosis** of **Ménétrier's disease**.

**Cited by:** 5

**Author:** H. Karl Greenblatt, Brave K. Nguyen

**Publish Year:** 2019