

国内版 国际版

Microsoft Bing

Synchronous concomitant pancreatic acinar cell carcinoma and ga

Sign in

ALL IMAGES VIDEOS

7,640 Results Any time

Synchronous occurrence of carcinoid, signet-ring cell ...

<https://www.ncbi.nlm.nih.gov/pmc/articles/PMC4087791>

Nov 28, 2006 We presented an unusual case with coexistence of carcinoid, signet-ring cell carcinoma (SRC) and heterotopic pancreatic tissue in stomach. Gastroscopic examination of this 63-year-old male patient showed multiple protrusions in gastric corpus near the greater curvature, identified by subsequent biopsy as carcinoid.

Cited by: 7 Author: Lin Yang, Hong-Tu Zhang, Xun Zhang, Y... Publish Year: 2006

Synchronous occurrence of carcinoid, signet-ring cell ...

<https://europepmc.org/abstract/MED/17131492>

Nov 01, 2006 Synchronous occurrence of carcinoid, signet-ring cell carcinoma and heterotopic pancreatic tissue in stomach: A case report and literature review. Lin Yang Department of Pathology, Cancer Hospital, Chinese Academy of Medical Sciences ...

Cited by: 7 Author: Lin Yang, Hong-Tu Zhang, Xun Zhang, Y... Publish Year: 2006

(PDF) Synchronous occurrence of carcinoid, signet-ring ...

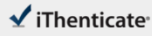
<https://www.researchgate.net/publication/6668009...>

Synchronous occurrence of carcinoid, signet-ring cell carcinoma and heterotopic pancreatic tissue in stomach: A case report and literature review December 2006 World Journal of Gastroenterology 12 ...

Acinar cell carcinoma arising in the stomach: A case

Search Tools

Turn off Hover Translation (关闭翻译)



66765_Auto_Edited.docx

Quotes Excluded
Bibliography Excluded

76%

Match Overview

- | Rank | Source | Words | Percentage |
|------|----------|------------|------------|
| 1 | Crossref | 2142 words | 74% |
| 2 | Crossref | 15 words | 1% |
| 3 | Internet | 14 words | 1% |
| 4 | Internet | 12 words | 1% |

Name of Journal: *World Journal of Clinical Cases*

Manuscript NO: 66765

Manuscript Type: CASE REPORT

Synchronous concomitant pancreatic acinar cell carcinoma and gastric adenocarcinoma: a case report and literature review.

Fang T et al. Synchronous concomitant pancreatic and gastric cancer

Tian Fang, TingTing Liang, YiZhuo Wang, HaiTao Wu, ShuHan Liu, Chang Wang

国内版

国际版

Synchronous concomitant pancreatic acinar cell carcin and gastric



ALL

IMAGES

VIDEOS

10,100 Results

Any time ▾

Including results for **synchronous concomitant pancreatic acinar cell carcinoma** and **gastric adenocarcinoma** a case report and review of literature.

Do you want results only for Synchronous concomitant pancreatic acinar cell carcin and gastric adenocarcinoma: A case report and review of literature?

Synchronous occurrence of carcinoid, signet-ring cell ...

<https://www.ncbi.nlm.nih.gov/pmc/articles/PMC4087791>

Nov 28, 2006 · We presented an unusual case with coexistence of carcinoid, signet-ring cell carcinoma (SRC) and heterotopic pancreatic tissue in stomach. Gastroscopic examination of this 63-year-old male patient showed multiple protrusions in gastric corpus near the greater curvature, identified by subsequent biopsy as carcinoid.

Cited by: 7

Author: Lin Yang, Hong-Tu Zhang, Xun Zhang, Yu...

Publish Year: 2006

Synchronous Epithelial and Neuroendocrine Cancers of the ...

<https://www.sciencedirect.com/science/article/pii/S1533002811000144>

Jun 01, 2011 · Gastric collision tumor of large cell neuroendocrine carcinoma and adenocarcinoma—a case report. ... a case report and literature review—synchronous pancreatic and bile duct tumors. ... Immunohistochemical characterization of an amphicrine mucinous islet-cell carcinoma of the pancreas: Case report. APMIS, 100 (1992), pp. 335-340.

Cited by: 1

Author: Derek G. Power, Jinru Shia, Peter J. Alle...

Publish Year: 2011

Pancreatic-type acinar cell carcinoma of the stomach ...

<https://www.sciencedirect.com/science/article/pii/S0046817708004796>

May 01, 2009 · Acinar cell carcinoma is an uncommon type of carcinoma of the pancreas that can exceptionally arise in ectopic pancreatic tissue. Herein, we report a case of a 52-year-old man with pancreatic-type acinar cell carcinoma of the stomach and concomitant pancreatic metaplasia of the adjacent nonneoplastic gastric mucosa.

Cited by: 23

Author: Andrea Ambrosini-Spaltro, Oscar Potì, Mi...

Publish Year: 2009

Acinar cystic transformation of the pancreas: Report of a ...

<https://www.sciencedirect.com/science/article/pii/S0344033820302110>