

12,000 Results

### An unusual presentation of gastric fistula following ...

<https://www.sciencedirect.com/science/article/pii/S2210261219300458>

Jan 01, 2019 · Jan 01, 2019 · Peptic **perforation** repair is a common **stomach** surgery. This surgery has not been associated with delayed onset gastrocutaneous **fistula formation**. However such a complication has been reported following a variety of other **stomach** surgeries. We are reporting this **case** as it is a rare complication. Also its **diagnosis** and management is challenging.

5/5 ★★★★★ (1) Author: Mithilesh Kumar Sinha, Sudipta Mohakud, ...

Publish Year: 2019

### Internet Scientific Publications

[ispub.com/IJGE/7/2/6134](http://ispub.com/IJGE/7/2/6134) ▼

The **diagnosis** of **gastric-pleural fistula** is usually made by upper endoscopy, radiographic contrast examination, or at surgery (10). We describe a case of a solitary diverticulum of the posterior wall of the **gastric antrum** complicated by the onset of an abscess of the right hepatic lobe and subsequently by a **pleural fistula** with pleural effusion.

Cited by: 1

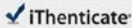
Author: Rocco Orlando, Fabio Pomerri, Flavio Lirussi

Publish Year: 2008

13 Aug 2021 04:17:01

993 words - 6 matches - 4 sources

FAQ

 iThenticate

68422\_Auto\_Edited - IT check.docx

Quoted Excluded  
Bibliography Excluded  
8%  
08/08/21

**Name of Journal:** *World Journal of Clinical Cases*

**Manuscript NO:** 68422

**Manuscript Type:** CASE REPORT

**Diagnosis of upper gastrointestinal perforation complicated with fistula formation and subphrenic abscess by contrast-enhanced ultrasound: case report**

Gastrointestinal perforation diagnosed by CEUS

Tingting Qiu, Rong Fu, Yan Luo, Wen-Wu Ling

Match Overview

1

Crossref 21 words  
Di-Nao Xu, Wen Zheng, Kai Li, Zhong-Dian Su, Ying-Lin Li, ng, Qing-Jin Zeng, Huan-Yi Guo, Rong-Qin Zheng, "Intracav

3%

2

Internet 19 words  
created on 16-Jul-2021  
www.vjgnet.com

2%

3

Internet 18 words  
created on 25-Apr-2020  
thieme-connect.com

2%

4

Crossref 17 words  
Nicola DeAngelis, Salvatore Di Savino, Oreste Ciarra, M  
assimo Sartoli et al. "2017 WSES guidelines for the mana...

2%

PAUSE 1 OF 6

Test-Only Report

国内版

国际版

Diagnosis of upper gastrointestinal perforation complicated with fi



ALL

IMAGES

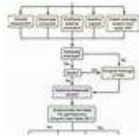VIDEOS

10,900 Results

Any time ▾

## Abdominal Abscesses and Gastrointestinal Fistulas ...

<https://clinicalgate.com/abdominal-abscesses-and-gastrointestinal-fistulas> ▾



May 16, 2015 · In 60% to 80% of cases, intra-abdominal abscess formation is associated with perforated hollow viscera, whether secondary to inflammatory disease such as appendicitis or diverticulitis or as a consequence of penetrating or blunt trauma...

Estimated Reading Time: 14 mins

## Internet Scientific Publications

[ispub.com/IJGE/7/2/6134](https://ispub.com/IJGE/7/2/6134) ▾

The diagnosis of gastric-pleural fistula is usually made by upper endoscopy, radiographic contrast examination, or at surgery (10). We describe a case of a solitary diverticulum of the posterior wall of the gastric antrum complicated by the onset of an abscess of the right hepatic lobe and subsequently by a pleural fistula with pleural effusion.

Cited by: 1

Author: Rocco Orlando, Fabio Pomerri, Flavio Liru...

Publish Year: 2008

### PEOPLE ALSO ASK

What are the symptoms of a gastrointestinal perforation? ▾

How is computed tomography used to diagnose abdominal abscess? ▾

Where to scan for small bowel perforation? ▾

How to tell if you have a gastrointestinal fistula? ▾

Feedback

## Bronchobiliary fistula: a rare postoperative complication ...

<https://casereports.bmj.com/content/14/7/e243198> ▾

Jul 01, 2021 · The documented complications of spilled gallstones include abscess formation, bacteremia, small bowel obstruction, granulomas, small bowel fistula, chest wall fistula and incarceration within a hernial sac.6 These complications can present within a few months or can take up to 20 years to manifest. In our patient, the time period between the laparoscopic cholecystectomy and