

31,100 Results

Any time ▾

Heterotopic pregnancy following ovulation induction by ...<https://pubmed.ncbi.nlm.nih.gov/16463167>

We report a combined intra-uterine and unruptured tubal pregnancy following ovulation induction by clomiphene citrate (CC) and timed intercourse. The diagnosis of heterotopic pregnancy (HP) is the major

Cited by: 6

Author: M. Murat Naki, Cevahir Tekcan, Arzu Uysal, ...

Publish Year: 2006

Findings that shed new light on the possible pathogenesis ...<https://www.ncbi.nlm.nih.gov/pmc/articles/PMC3047280>

Apr 26, 2010 · In vitro fertilisation and embryo transfer for bilateral salpingectomies results in a ruptured ovarian ectopic pregnancy due to a tubal stump fistula: a case report and review of the literature.

Cited by: 7

Author: Srividya Seshadri, Paul Shirley, Thiagarajan ...

Publish Year: 2010

PEOPLE ALSO ASK

How is ovulation induction used to treat infertility? ▾

Is there a mini review of ovulation induction? ▾

Who is eligible for induction of ovulation? ▾

[Feedback](#)**Superfetation after ovulation induction and intrauterine ...**[https://www.rbmojournal.com/article/S1472-6483\(10\)00053-2/fulltext](https://www.rbmojournal.com/article/S1472-6483(10)00053-2/fulltext)

Mar 08, 2010 · This report describes the first case of superfetation after ovarian stimulation with gonadotrophins and intrauterine insemination (IUI) that were performed in the presence of an...

Cited by: 6

Author: Teresa Lantieri, Alberto Revelli, Pietro Gagli...

Publish Year: 2010

Bilateral ovarian maldescent: Unusual cause of infertility ...<https://www.ncbi.nlm.nih.gov/pubmed/27094464>

Bilateral ovarian maldescent: Unusual cause of infertility - A case report and literature review. ... After

国内版 国际版

Microsoft Bing

Ovarian pregnancy rupture following ovulation induction and intra



ALL IMAGES VIDEOS

9,840 Results Any time ▾ Open links in new tab ☒

[Superfetation after ovulation induction and intrauterine ...](#)

[https://www.rbmojournal.com/article/S1472-6483\(10\)00053-2/fulltext](https://www.rbmojournal.com/article/S1472-6483(10)00053-2/fulltext)

Mar 08, 2010 · This report describes the first case of superfetation **after ovarian stimulation** with **gonadotrophins and intrauterine insemination (IUI)** that were performed in the presence of an undiagnosed tubal pregnancy. A 32-year-old woman who underwent repeated attempts of **ovarian stimulation** and IUI was hospitalized for severe pelvic pain and submitted to laparoscopic salpingectomy because **of ruptured** ...

Cited by: 6 Author: Teresa Lantieri, Alberto Revelli, Pietro Gag...
Publish Year: 2010

[Superfetation after ovulation induction and intrauterine ...](#)

<https://www.sciencedirect.com/science/article/pii/S1472648310000532>

May 01, 2010 · Abstract. This report describes the first **case** of superfetation **after ovarian stimulation** with gonadotrophins and **intrauterine insemination (IUI)** that were performed in the presence of an undiagnosed tubal **pregnancy**. A 32-year-old woman who underwent repeated attempts of **ovarian stimulation** and IUI was hospitalized for severe pelvic pain and submitted to laparoscopic salpingectomy because **of ruptured** ...

Cited by: 6 Author: Teresa Lantieri, Alberto Revelli, Pietro Gag...
Publish Year: 2010

[Pregnancy after ovarian stimulation and intrauterine ...](#)

<https://www.ncbi.nlm.nih.gov/pubmed/9437597>

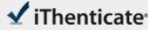
Pregnancy after ovarian stimulation and intrauterine insemination in a woman with cavernous macrohemangioma of the liver. **A case report.** Spitzer D(1), Krainz R, Graf AH, Menzel C, Staudach A. Author information: (1)Department of Obstetrics and Gynecology, Salzburg General Hospital, Austria.

Cited by: 17 Author: Spitzer D, Krainz R, Graf Ah, Menzel C, St...
Publish Year: 1997

25-Mar-2021 05:35PM

1937 words • 6 matches • 5 sources

FAQ

iThenticate®

68883_Auto_Edited - 副本.docx

Quotient Excluded
Bibliography Included

5%
0.000000

Match Overview

1

Internet 41 words
crawled on 27-Oct-2020
Rpublishing.blob.core.windows.net

2%

2

Crossref 17 words
Tung-Yao Chang, Hsiao-Gon Wang, Chen-Yu Chen, Chih-Ping Chen, Chin-Yuan Tzen, San-Lih Yu, Su-Chen Kuo. "Primary ...

1%

3

Crossref 15 words
Turgut Aydin, Burak Yozcel, Husseyin Aksoy, Suheyla Ekemen. " Successful laparoscopic management of a rare complication

1%

4

Crossref 13 words
Francesco Piotti, Alessandra Di Giovanni, Cosimo Oliva, Francesco Battaglia, Giovanni Piotti. "Bilateral ovarian pregnancy ...

1%

5

Crossref 13 words
Srinisha Rao Gundabattula, Padmasree Resapu, Kameswari Surampudi, Tarakeswari Surapaneni, Michelle De Padua. "Ovari

1%

4

Name of Journal: *World Journal of Clinical Cases*

Manuscript NO: 68883

Manuscript Type: CASE REPORT

Ovarian pregnancy rupture following ovulation induction and intrauterine insemination: A case report

Wu B *et al.* Ovarian pregnancy rupture after IUI

Bin Wu, Ke Li, Xiao-Fen Chen, Jie Zhang, Jing Wang, Yue Xiang, Hong-Gui Zhou

国内版

国际版

Ovarian pregnancy rupture following ovulation induction and intra



ALL

IMAGES

VIDEOS

9,670 Results

Any time ▼

Superfetation after ovulation induction and intrauterine ...

[https://www.rbmojournal.com/article/S1472-6483\(10\)00053-2/fulltext](https://www.rbmojournal.com/article/S1472-6483(10)00053-2/fulltext)

Mar 08, 2010 · This report describes the first case of superfetation after ovarian stimulation with gonadotrophins and intrauterine insemination (IUI) that were performed in the presence of an undiagnosed tubal pregnancy. A 32-year-old woman who underwent repeated attempts of ovarian stimulation and IUI was hospitalized for severe pelvic pain and submitted to laparoscopic salpingectomy because of ruptured ...

Cited by: 6

Author: Teresa Lantieri, Alberto Revelli, Pietro Ga...

Publish Year: 2010

Superfetation after ovulation induction and intrauterine ...

<https://www.sciencedirect.com/science/article/pii/S1472648310000532>

May 01, 2010 · Abstract. This report describes the first case of superfetation after ovarian stimulation with gonadotrophins and intrauterine insemination (IUI) that were performed in the presence of an undiagnosed tubal pregnancy. A 32-year-old woman who underwent repeated attempts of ovarian stimulation and IUI was hospitalized for severe pelvic pain and submitted to laparoscopic salpingectomy because of ruptured ...

Cited by: 6

Author: Teresa Lantieri, Alberto Revelli, Pietro Ga...

Publish Year: 2010

Pregnancy after ovarian stimulation and intrauterine ...

<https://www.ncbi.nlm.nih.gov/pubmed/9437597>

Pregnancy after ovarian stimulation and intrauterine insemination in a woman with cavernous macrohemangioma of the liver. A case report. Spitzer D(1), Krainz R, Graf AH, Menzel C, Staudach A. Author information: (1)Department of Obstetrics and Gynecology, Salzburg General Hospital, Austria.

Cited by: 17

Author: Spitzer D, Krainz R, Graf Ah, Menzel C, ...

Publish Year: 1997

[PDF] Superfetation after ovulation induction and intrauterine ...

[https://www.rbmojournal.com/article/S1472-6483\(10\)00053-2/pdf](https://www.rbmojournal.com/article/S1472-6483(10)00053-2/pdf)

The present report describes the first case of superfetation after ovarian stimulation and intrauterine insemination (IUI) in a woman with an ongoing, undiagnosed tubal pregnancy. Case report A 32-year-old, nulliparous woman was referred to the repro-ductive medicine centre after 2 ...