

[国内版](#)[国际版](#)

The present state of EUS-FNA for diagnosing autoimmune pancreatitis type :

[Sign in](#)[All](#)[Images](#)[Videos](#)[翻译成中文](#)[关闭取词](#)[Make Bing your s](#)

29,300 Results

Any time ▾

## EUS in the Diagnosis of Autoimmune Pancreatitis | ...

<https://www.pancreapedia.org/reviews/eus-in-diagnosis-of...> ▾

Kanno A, Ishida K, Hamada S, Fujishima F, Unno J, Kume K, Kikuta K, Hirota M, Masamune A, Satoh K, Notohara K, and Shimosegawa T. **Diagnosis of autoimmune pancreatitis** by EUS-FNA by using a 22-gauge needle based on the International Consensus Diagnostic Criteria.

**Author:** Larissa L. Fujii, Michael J. Levy **Publish Year:** 2013

## Endoscopic ultrasound-guided fine needle aspiration in the ...

[www.ncbi.nlm.nih.gov](http://www.ncbi.nlm.nih.gov) › ... › v.18(29); 2012 Aug 7

Aug 07, 2012 · Endoscopic ultrasound-guided fine needle aspiration in the differentiation of **type 1** and **type 2 autoimmune pancreatitis**. Takuya ... There are reports on the usefulness of EUS-FNA in the diagnosis of ... Yatabe Y, Koshikawa T. Endoscopic ultrasound-guided fine-needle aspiration biopsy (EUS-FNAB): past, **present**, and future. J ...

**Cited by:** 29 **Author:** Takuya Ishikawa, Akihiro Itoh, Hiroki Kaw...

**Publish Year:** 2012

## IgG4-unrelated type 1 autoimmune pancreatitis

[www.ncbi.nlm.nih.gov](http://www.ncbi.nlm.nih.gov) › ... › v.21(33); 2015 Sep 7

Sep 07, 2015 · The patient was diagnosed as having **type 1 autoimmune pancreatitis** (AIP) based on the International Consensus **Diagnostic** Criteria. Therefore, we encountered a case of compatible **type 1** AIP without elevated levels of serum IgG4 or IgG4-positive plasma cells. This case suggests that AIP phenotypes are not always associated with IgG4.

**Cited by:** 3 **Author:** Eriko Nakano, Atsushi Kanno, Atsushi M...

**Publish Year:** 2015

## Endoscopic ultrasound guided 22 gauge core needle biopsy ...

## Autoimmune pancreatitis

Autoimmune pancreatitis is an increasingly recognized type of chronic pancreatitis that can be difficult to distinguish from pancreatic carcinoma but which responds to treatment with corticosteroids, particularly prednisone. There are two categories of AIP: Type 1 and Type 2, each with distinct clinical profiles.



Wikipedia

Data from: [Wikipedia](#)

[Suggest an edit](#)

**Name of Journal:** *World Journal of Meta-Analysis*

**Manuscript NO:** 47552

**Manuscript Type:** MINIREVIEWS


**Present state of endoscopic ultrasonography-guided fine needle aspiration for  
the diagnosis of autoimmune pancreatitis type 1**

1

Mitsuru Sugimoto, Tadayuki Takagi, Rei Suzuki, Naoki Konno, Hiroyuki Asama,

Yoshiyuki Sugimoto, Tadayuki Takagi, Rei Suzuki, Naoki Konno, Hiroyuki Asama,

## Match Overview



1

**Internet** 56 words  
crawled on 25-Jul-2018  
[www.wjgnet.com](http://www.wjgnet.com)

3%

2

**Crossref** 54 words  
Mitsuru Sugimoto, Erina Suzuki, Kazuhiro Tasaki, Yuko Hashimoto, Hiromasa Ohira. "Chapter 11 Gastrointestinal Involvement

3%

3

**Crossref** 20 words  
Mitsuru Sugimoto, Tadayuki Takagi, Rei Suzuki, Naoki Konno, et al. "Efficacy of Steroid Pulse Therapy for Autoimmune Pancreatitis

1%

4

**Crossref** 20 words  
"Gastrointestinal and Hepatic Manifestations of Rheumatic Diseases", Springer Nature, 2019

1%

5

**Crossref** 17 words  
Ryu, Ji Kon. "Controversial Issues of Recent Diagnostic Criteria of Type 1 Autoimmune Pancreatitis", The Korean Journal of

1%



国内版

国际版

Present state of endoscopic ultrasonography-guided fine needle aspiration for the



All

Images

Videos

翻译成中文

关闭取词

2,900 Results

Any time ▼

## Immunohistochemical analysis of p53 and MIB-1 in tissue ...

<https://www.researchgate.net/publication/297577815...>

The **effectiveness** of **endoscopic ultrasonography-guided fine-needle aspiration (EUS-FNA)** has not been fully evaluated in the **diagnosis** of **autoimmune pancreatitis (AIP)**.

## Molecular Biologic Approach to the Diagnosis of Pancreatic ...

[www.ncbi.nlm.nih.gov](http://www.ncbi.nlm.nih.gov) › ... › Gastroenterol Res Pract › v.2012; 2012

**EUS-FNA** is currently **used** for the **diagnosis** and staging of pancreatic tumors. The **sensitivity** of **EUS-FNA** for **pancreatic malignancy** ranges from 75% to 94%, and its specificity approaches 100% in most studies. However, EUS-FNA has some limitations in the **diagnosis** of ...

Cited by: 14

Author: Kiyohito Kato, Hideki Kamada, Takayuki ...

Publish Year: 2012

## Role of pancreatic endoscopic ultrasonography in 2010

[www.ncbi.nlm.nih.gov](http://www.ncbi.nlm.nih.gov) › ... › v.2(10); 2010 Oct 16

Oct 16, 2010 · **Endoscopic ultrasonography (EUS)** was introduced 25 years ago aiming at better visualization of the pancreas compared to transabdominal ultrasonography. This update discusses the **current** evidence in 2010 concerning the role of **EUS** in the clinical management of patients with pancreatic disease. Major ...

Cited by: 3

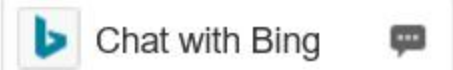Author: Ioannis S Papanikolaou, Pantelis S Karat...

Publish Year: 2010

## Role of pancreatic endoscopic ultrasonography in 2010

<http://www.wjnet.com/1040-5100/5-11-2010/005.htm>



[国内版](#)[国际版](#)

Present state of endoscopic ultrasonography-guided fine needle aspiration for the

[All](#)[Images](#)[Videos](#)[翻译成中文](#)[开启取词](#)

2,950 Results

Any time ▾

## Molecular Biologic Approach to the Diagnosis of Pancreatic ...

[www.ncbi.nlm.nih.gov](#) > ... > Gastroenterol Res Pract > v.2012; 2012

**EUS-FNA** is currently **used** for the **diagnosis** and staging of pancreatic tumors. The **sensitivity** of **EUS-FNA** for **pancreatic malignancy** ranges from 75% to 94%, and its specificity approaches 100% in most studies. However, EUS-FNA has some limitations in the **diagnosis** of ...

**Cited by:** 14

**Author:** Kiyohito Kato, Hideki Kamada, Takayuki ...

**Publish Year:** 2012

## Immunohistochemical analysis of p53 and MIB-1 in tissue ...

<https://www.researchgate.net/publication/297577815...>

The **effectiveness** of **endoscopic ultrasonography-guided fine-needle aspiration (EUS-FNA)** has not been fully evaluated in the **diagnosis** of **autoimmune pancreatitis (AIP)**.

## (PDF) Endoscopic Ultrasound-guided Fine-Needle Aspiration ...

[https://www.researchgate.net/publication/262072006\\_Endoscopic...](https://www.researchgate.net/publication/262072006_Endoscopic...)

PDF | Mutation of the KRAS oncogene is **present** in 75% to 95% of pancreatic cancer tissues. This study aimed to evaluate whether **endoscopic** ultrasound-guided **fine-needle aspiration (EUS-FNA)** ...

## Role of pancreatic endoscopic ultrasonography in 2010

<https://www.wjgnet.com/1948-5190/full/v2/i10/335.htm> ▾

**EUS-fine needle aspiration (EUS-FNA)** has been assessed to establish a tissue **diagnosis**[25-27], and further analyses from the specimens such as microsatellite loss analysis has been recently performed and is thought to be correlated to prognosis.

**Cited by:** 3

**Author:** Ioannis S Papanikolaou, Pantelis S Karat...

**Publish Year:** 2010

## Selected Expanded Abstracts from Suizou, the Journal of ...

[journals.lww.com](#) > Home > July 2003 - Volume 27 - Issue 1

<https://www.ncbi.nlm.nih.gov/pmc/articles/PMC3503278/>

**SUIZOU 17(5): The clinical utility of endoscopic ultrasound-guided fine needle aspiration (EUS-**