



Sphincter ultrasound lesions after transanal endoscopic surgery (TEO/TI)



网页

图片

新闻

购物

视频

更多

搜索工具

找到约 31,600 条结果 (用时 0.63 秒)

Transanal Endoscopic Microsurgery for Rectal Tumors: A ...

www.ncbi.nlm.nih.gov > ... > PubMed Central (PMC) ▾ 翻译此页

作者: H Kunitake - 2012 - 被引用次数: 26 - 相关文章

Since its introduction in 1983, **transanal endoscopic microsurgery (TEM)** has emerged ...

In addition, over **two** decades of scientific data support the use of **TEM** as a viable ...

Both endorectal **ultrasound** or MRI can be used to determine the **lesion** The

recurrence rate **following TEM** for T1 **lesions** ranges from 0% to 11%.16 ...

Transanal endoscopic surgery in rectal cancer

www.ncbi.nlm.nih.gov > ... > PubMed Central (PMC) ▾ 翻译此页

作者: X Serra-Aracil - 2014 - 被引用次数: 9 - 相关文章

2014年9月7日 - **Transanal endoscopic microsurgery (TEM)** allows preservation of the ...

this endoscopic procedure allows preservation of the anal **sphincters** ... The bladder

catheter is withdrawn **after surgery** and the patient is mobilized **after** eight hours. site

of the **lesion**, a maneuver that can be performed with **TEM/TEO**.

Browse the Registry - Research Registry

www.researchregistry.com/browse-the-registry.html ▾ 翻译此页

... 2015 7:00, view, researchregistry362, Xavier Serra-Aracil, **SPHINCTER ULTRASOUND**

LESIONS AFTER TRANSANAL ENDOSCOPIC SURGERY (TEO/TEM) ...

[PDF] Transanal Endoscopic Microsurgery - State of the Art - In...

www.intechopen.com/download/pdf/21162 ▾ 翻译此页

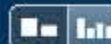2011年9月22日 - **Transanal endoscopic microsurgery (TEM)** came into practice in ...

lesions with their proximal margin located as far as 20 cm from the ... **two** ports serving

for water irrigation and CO2 insufflation (figure 5). **after** resection, to evaluate the

safety margins before fixation with formalin. ... Endorectal **ultrasound**.

Match Overview



There are no matching sources for this report.

Name of Journal: World Journal of Gastroenterology

ESPS Manuscript NO: 17941

Manuscript Type: Prospective Study

Sphincter ultrasound lesions after transanal endoscopic surgery (TEO/TEM)

Mora López Laura, Serra-Aracil Xavier, Navarro Soto Salvador


Abstract

AIM: Ultrasound study to assess the morphological impact of transanal endoscopic surgery on the sphincter apparatus, using the modified Starck classification.

METHODS: Prospective, observational study of 118 consecutive patients undergoing TEO/TEM from March 2013 to May 2014. All patients underwent endoanal ultrasound prior to surgery and one month and four months post-surgery in order to measure sphincter width, to identify sphincter defects and to quantify them in terms of level of anal canal affected, depth and size. To assess the lesions we applied the "modified" Starck classification, which incorporates the variable "sphincter fragmentation". The results were correlated with the Wexner incontinence questionnaire.

RESULTS: Of the 118 patients, twelve who presented sphincter lesions on the



Sphincter ultrasound lesions after transanal endoscopic surgery (TEO/TI) 



网页 图片 新闻 视频 更多 搜索工具

找到约 15,000 条结果 (用时 0.58 秒)

Transanal Endoscopic Microsurgery for Rectal Tumors: A ...

www.ncbi.nlm.nih.gov > ... > PubMed Central (PMC) ▾ [翻译此页](#)

作者: H Kunitake - 2012 - 被引用次数: 26 - 相关文章

Since its introduction in 1983, **transanal endoscopic microsurgery (TEM)** has emerged ...

In addition, over **two** decades of scientific data support the use of **TEM** as a viable ...

Both endorectal **ultrasound** or MRI can be used to determine the **lesion** The

recurrence rate **following TEM** for T1 **lesions** ranges from 0% to 11%.16 ...

Transanal endoscopic surgery in rectal cancer

www.ncbi.nlm.nih.gov > ... > PubMed Central (PMC) ▾ [翻译此页](#)

作者: X Serra-Aracil - 2014 - 被引用次数: 9 - 相关文章

2014年9月7日 - **Transanal endoscopic microsurgery (TEM)** allows preservation of the ...

this endoscopic procedure allows preservation of the anal **sphincters** ... The bladder

catheter is withdrawn **after surgery** and the patient is mobilized **after** eight hours. site

of the **lesion**, a maneuver that can be performed with **TEM/TEO**.

Browse the Registry - Research Registry

www.researchregistry.com/browse-the-registry.html ▾ [翻译此页](#)

... 2015 7:00, view, researchregistry362, Xavier Serra-Aracil, **SPHINCTER ULTRASOUND**

LESIONS AFTER TRANSANAL ENDOSCOPIC SURGERY (TEO/TEM) ...

Transanal endoscopic operation: a new proposal - SciELO

www.scielo.br/scielo.php?script=sci_arttext&pid=S0102... ▾ [翻译此页](#)

作者: JJR Rocha - 2008 - 被引用次数: 5 - 相关文章

For local rectal cancer **surgical** treatment, the **TEM** has been used since 1983 with ...

The rectal touch, rectoscopy, endorectal **ultrasound** and nuclear magnetic resonance are

.... Technical Steps of the **Transanal Endoscopic Operation (TEO)** ... **After the lesion**



Sphincter ultrasound lesions after transanal endoscopic surgery (TEO/TEM) ▾



学术搜索

获得 3 条结果 (用时0.06秒)

文章

我的图书馆

时间不限

2015以来

2014以来

2011以来

自定义范围...

按相关性排序

按日期排序

搜索所有网页

中文网页

简体中文网页

☒ 包括专利

☒ 包含引用

创建快讯

小提示：只搜索中文(简体)结果，可在 学术搜索设置 指定搜索语言

Study of anorectal function after transanal endoscopic surgery

LM López, XS Aracil, JH Bosch, P Rebas... - ... Journal of Surgery, 2015 - Elsevier

... Of all the tests available for diagnosing incontinence (endoanal ultrasound, nerve stimulation, electromyography, defecography and anal manometry) [24], we chose ... These studies demonstrated morphological alterations in the sphincters, but did not assess sphincter function ...

相关文章 所有 6 个版本 引用 保存

Laura Melina Fernandez, Guilherme Pagin São Julião, and Rodrigo Oliva Perez

A Habr-Gama, MN Figueiredo - Modern Management of Cancer of the Rectum - Springer

... For anterior lesions, posterior incision of the rectum is required, allowing resection under ... accuracy is still far from 100%, magnetic resonance (MR) and endorectal ultrasound have been ... in the event of a local recurrence, salvage with TME and sphincter preservation (when ...

相关文章 引用 保存

Local Excision of Rectal Cancer

A Habr-Gama, MN Figueiredo, LM Fernandez... - Modern Management of ..., 2015 - Springer

... For anterior lesions, posterior incision of the rectum is required, allowing resection under direct ... accuracy is still far from 100 %, magnetic resonance (MR) and endorectal ultrasound have been ... the event of a local recurrence, salvage with TME and sphincter preservation (when ...

相关文章 所有 2 个版本 引用 保存

创建快讯

journal-surgery.net 中的 [HTML]

关于 Google 学术搜索

隐私权

条款

提供反馈