

No items found.

Search details

((("ileus"[MeSH Terms] OR "ileus"[All Fields]) AND ("causality"[MeSH Terms] OR "causality"[All Fields] OR "caused"[All Fields] OR "caused by"[All Fields]) AND ("cholesterol"[MeSH

Search

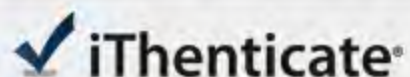
[See more...](#)

Recent Activity

[Turn Off](#) [Clear](#)

- K-ras mutations in colorectal adenocarcinomas and neighbouring PubMed
- ileus caused by cholesterol crystal embolization : A case report (0) PubMed
- 10070310[uid] (1) PubMed
- High Density Lipoprotein AND (HDL) AND Another Cog in the Colon C... (0) PubMed
- Ras oncogene activation in benign and malignant colorectal tumors... (1) PubMed

[See more...](#)



23214-Review

BY SHUNJIRO AZUMA

Quotes Excluded
Bibliography Excluded7%
SIMILAR

Name of journal: World Journal of Gastroenterology

ESPS Manuscript NO: 23214

Manuscript Type: CASE REPORT

Ileus caused by cholesterol crystal embolization: A case report

Shunjiro Azuma, Maiko Ikenouchi, ⁴Takuji Akamatsu, Takeshi Seta, Shunji Urai,

Yoshito Uenoyama, Yukitaka Yamashita

Match Overview

- | Match Number | Source | Words | Similarity |
|--------------|--|----------|------------|
| 1 | CrossCheck | 55 words | 4% |
| | Gaetano Panniello. "Spontaneous Cutaneous Cholesterol Crystal Embolism With Focal Clinical Symptomatology: Re | | |
| 2 | CrossCheck | 21 words | 1% |
| | Higo, Seiichiro, Akio Hirama, Kae Ueda, Akiko Mii, Tomohiro Kaneko, Kouichi Utsumi, Yasuhiko Iino, and Yasuo Katay | | |
| 3 | CrossCheck | 17 words | 1% |
| | Ishiyama, Katsuya, Toshinobu Sato, and Yoshio Taguma. "Low-Density Lipoprotein Apheresis Ameliorates Renal Pro | | |
| 4 | Publications | 10 words | 1% |
| | "Recent Findings in Hepatocellular Carcinoma Described by K. Hatamaru and Colleagues (Pulmonary embol", Obesi | | |

Ileus caused by cholesterol crystal embolization: A case report

全部

图片

视频

新闻

购物

地图

图书

找到约 32,900 条结果

时间不限

过去 1 小时内
过去 24 小时内
过去 1 周内
过去 1 个月内
过去 1 年内

所有结果

精确匹配

[Google 学术: Ileus caused by cholesterol crystal embolization: A case report](#)

[Cholesterol crystal embolisation to the alimentary tract](#) - Moolenaar - 被引用次数: 64

[CT of Acute Bowel Ischemia 1](#) - Wiesner - 被引用次数: 425

[... due to systemic cholesterol atheromatous embolism](#) - Fujiyama - 被引用次数: 20

[PDF] [Cholesterol crystal embolisation to the alimentary](#)
[europepmc.org/articles/PMC1383022/pdf/gut00503-0048.pdf](#) ▾

15 Aug 1995 ... The features of **cholesterol crystal emboli**- sation (CCE) to ... patients. In the remaining **cases**, ischaemic ... clinical **presentation due to** the ensuing Dyspepsia. 1 (1-4). CCE in fundo. 1 (1-4). **Ileus**. 1 (1-4). Pancreatitis. 1 (1-4).

[PDF] [Gastrointestinal Complications of Abdominal Aortic ... - InTech](#)
[www.intechopen.com/download/pdf/19561](#) ▾

12 Sep 2011 ... abdominal aneurysm (AAA) are uncommon they are **associated with** a significant increase in patient ... increases to 10% in **cases** of open repair of a ruptured AAA. Many **studies** suggest that **ileus** is the result of an inhibition of intestinal **Embolization** of **cholesterol crystals** can lead to ischaemia of the ...

[Cholesterol Emboli: CES information. Cholesterol embolism | Patient](#)
[patient.info/doctor/Cholesterol-Emboli.htm](#) ▾

Synonyms: cholesterol **embolism** syndrome (CES), **cholesterol crystal** ... Acute respiratory

[全部](#)[图片](#)[新闻](#)[视频](#)[购物](#)[更多 ▾](#)[搜索工具](#)

找到约 33,000 条结果 (用时 0.52 秒)

Google 学术 : Ileus caused by cholesterol crystal embolization: A case report

Cholesterol crystal embolisation to the alimentary tract. - Moolenaar - 被引用次数 : 64

CT of Acute Bowel Ischemia 1 - Wiesner - 被引用次数 : 425

... due to systemic cholesterol atheromatous embolism. - Fujiyama - 被引用次数 : 20

[PDF] Cholesterol crystal embolisation to the alimentary

europepmc.org/articles/PMC1383022/pdf/gut00503-0048.pdf ▾ 翻译此页

作者 : W Moolenaar - 1996 - 被引用次数 : 64 - 相关文章

1995年8月15日 - The features of cholesterol crystal embolisation (CCE) to ... patients. In the remaining cases, ischaemic ... clinical presentation due to the ensuing Dyspepsia. 1 (1-4). CCE in fundo. 1 (1-4). Ileus. 1 (1-4). Pancreatitis. 1 (1-4).

[PDF] Gastrointestinal Complications of Abdominal Aortic ... - In...

www.intechopen.com/download/pdf/19561 ▾ 翻译此页

2011年9月12日 - abdominal aneurysm (AAA) are uncommon they are associated with a significant increase in patient ... increases to 10% in cases of open repair of a ruptured AAA. Many studies suggest that ileus is the result of an inhibition of intestinal Embolization of cholesterol crystals can lead to ischaemia of the ...

Cholesterol embolism - Wikipedia, the free encyclopedia

https://en.wikipedia.org/wiki/Cholesterol_embolism ▾ 翻译此页

Cholesterol embolism (often cholesterol crystal embolism or atheroembolism,